WCBIP 2020 SHANGHAI

The 21st World Congress of Bronchology and Interventional Pulmonology
& The 8th National Interventional Pulmonology Congress of Chinese Medical Association

第21届世界支气管和介入呼吸病学大会
暨中华医学会第八届呼吸内镜和介入呼吸病学学术研讨会

New Land New Scope

November 19–22, 2020

Virtual Congress

Sponsored by

The World Association for Bronchology and Interventional Pulmonology (WABIP)

Chinese Medical Association (CMA)

Chinese Thoracic Society (CTS)

新一代 CMOS+LED
无光纤电子镜
FLEXIBLE VIDEO BRONCHOSCOPE

SEESHEEN

BRscope

AF Series

- 手持式/轻便/灵巧
  Handy type/ Fast/Convenient

规格 OD/ID(Unit:mm)


2.8 / 1.2


3.1 / 1.2


4.2 / 2.0


4.9 / 2.2


5.2 / 2.6


5.5 / 2.8


5.8 / 3.0

SEESHEEN.COM

珠海视新医用科技有限公司
ZHUHAI SEESHEEN MEDICAL TECHNOLOGY CO., LTD.

联系我们 Contact us
谭经理 136 0036 0851（中国China）
Ivan Wang intl@seesheen.com（国际international）

目录

OR-001
Temporarily self-expanding covered metallic stents: a bridge to the silicone stent implantation in management of difficult post-tuberculous bronchial stenosis

Feng,Jiaxin、Li,Shiue、Zhou,Ziqing、Chen,Yu、Zhong,Shanghai、Chen,Xiaobo、Tang,Chungli
The First Affiliated Hospital of Guangzhou Medical University

Objective: To evaluate the efficacy and safety of temporarily covered self-expanding metallic stents (SEMS) as a bridge to the silicone stent implantation in treatment of difficult PTBS.

Methods: We reviewed the clinical data of all the PTBS patients who treated with airway stents from September 2015 to May 2019 at the First Affiliated Hospital of Guangdong Medical University.

Results: Fifty-eight patients were included in the study. Seven patients had silicone stents insertion immediately after dilation of the stenotic bronchial, but 2 out of 15 (13.3%) silicone stents failed deploying fully and were replaced by SEMS. A total of 45 temporarily SEMSs were placed for an interval of 28.4±11.1 days in 45 out of 58 patients before silicone stenting. The mean luminal diameter increased from 2 (0-3) mm to 6 (5-7) mm post-dilation and further increased to 9 (8-12) mm (All $P<0.05$) after removal of the SEMS. There were no SEMS-related major complications and all the SEMS were removed followed by successfully silicone stents insertion. Subgroup analysis showed that temporarily SEMS placement did not influence the clinical outcome of silicone stents insertion.

Conclusion: Temporarily SEMS insertion as a bridge to silicone stent insertion is a unique and feasible procedure to re-establish the stenotic airway by providing a continuous dilation effect against the wall of the stricture. It helps to reduce complication an increase easiness of silicone stent insertion in patients with severe difficulty post-TB stenosis.

OR-002
THE RISK OF BLEEDING AFTER THORACENTESIS IN ADULT FILIPINOS TAKING ANTIPLATELETS: A SINGLE-CENTER CROSS-SECTIONAL STUDY

Ong,Angela Roberta、Santos,Elaine、Jay,Datukan、San Juan,Milanie
St. Luke's Medical Center

Objective: It is the aim of the authors to compare bleeding parameters and bleeding events among antiplatelet users undergoing thoracentesis as part of an institution-based protocol development.

Methods: Bleeding parameters and bleeding events recorded among adult patients who continued antiplatelet use were compared with those who discontinued antiplatelets for ≥ 5 days prior to ultrasound-guided thoracentesis at St. Luke's Medical Center-Global City, Philippines from January 2016-December 2018 through chart reviews. Student's t-test (continuous variables) and chi-square test or Fisher exact test (categorical variables) were used to detect statistical differences between the two groups.

Results: Forty-eight of 111 charts were included. Those who continued (n=33) and discontinued antiplatelet use (n=15) are not significantly different in age, sex, type of antiplatelet, indication for antiplatelet, and co-morbid conditions (Table 1). Almost all patients have platelet counts > 100,000 (94% vs 93%, $p > 0.999$). The mean PT (14.33 vs 13.55, $p=0.502$) and mean PTT (32.21 vs 36.18, $p=0.208$) were not significantly different between groups. While

there are significantly more patients who continued antiplatelets with sero-sanguinous and sanguinous effusion (sero-sanguinous: 90.48% vs 9.52%; sanguinous: 60% vs 40%, p= 0.009), there is no significant difference in major bleeding outcomes. There was only one incident of hemoglobin reduction > 2 g/dL in a 72-year old female Filipino diagnosed with stage IV lung cancer, post-non-ST elevation acute coronary syndrome, and post-percutaneous coronary intervention on dual antiplatelet therapy (aspirin, clopidogrel), with 1,800 mL of sanguineous effusion drained. This patient has discontinued antiplatelet therapy more than five days prior to procedure.

Conclusion: There is no sufficient evide nce to support the discontinuation of antiplatelet therapy prior to ultrasound-guided thoracentesis. Because of sample size limitations, however, further studies are recommended before the results may be applicable to the general population.

OR-003

A Nomogram to Predict Risk of Postintubation Tracheal Stenosis

Chen,Difei、Li,ShiYue
The First Affiliated Hospital of Guangzhou Medical University

Objective: Postintubation tracheal stenosis (PITS) is an iatrogenic lesion. Most common cause is intubation of the airway, which can result in ischemia, necrosis and cicatricial healing. Recently, with an understanding of tracheal intubation and tracheal structure, low pressure cuff and routinely monitor intracuff pressure were used to prevent airway stenosis. However, PITS is still occur in intensive care units despite technological innovations. So we developed and internally validated a Nomogram to identify risk factors for PITS and determine if there were patient characteristics that could serve as prognostic indicators of clinical outcomes in this patient population.

Methods: This was a multicenter retrospective study. After 3 years follow up, 434 patients who treated with tracheal cannula from district hospitals and 60 PITS suspected patients who referred to The first affiliated hospital of Guangzhou Medical University were included in this study. Retrospective Data were used to establish and calibrate a Nomogram for risk of PITS based on multivariate logistic regression. Tracheal stenosis were diagnosed by bronchoscope. Patients who experienced tracheal stenosis (stenosis group) were compared with those who did not experience stenosis (non-stenosis group). Model discrimination was estimated by C-index. Calibration that assessed by agreement between predicted and record stenosis rate was shown as calibration plot. Moreover, we conducted the receiver operator characteristic curve (ROC) to evaluate the clinical value of the Nomogram.

Results: The final multivariate regression model included age（OR=0.974，p<0.05）, sex（OR=0.688，p<0.05）, diabetes（OR=4.466，p<0.001） and Duration of intubation（OR=12.551，p<0.001）. A Nomogram was developed as a graphical representation of the model and had good calibration and discrimination (with C-index 0.854). The cutoff of ROC was 0.099 according to the Youdan index.

Conclusion: As a non-invasive prediction tool, our Nomogram shows favorable predictive accuracy for risk of tracheal stenosis in patients under tracheal intubation. Once predict probability over 0.1, which was considered as high risk of PITS.

OR-004

How Rapid Can Rapid On-site Cytology Evaluation (ROSE) Be - Our Experience With Toluidine Blue Staining - Concordance Between ROSE and Final Cytological Diagnosis On EBUS TBNA Samples

Shah,Umang C、Shah,Arpan C
Pranayam Lung and Heart Institute, Vadodara, Gujarat, India

Objective: Patients with Mediastinal Lymphadenopathy or Nodal Mass undergoing EBUS TBNA for diagnosis, decisions are based on rapid on-site evaluation (ROSE) findings. We aimed to analyze the clinical utility of Toluidine blue staining on EBUS TBNA samples and concordance rate between ROSE diagnosis and final HPE diagnosis.

Methods: Diagnosis concordance was defined as cases where lymph nodes (LNs) presented the same diagnosis in ROSE and final diagnosis. The smear submitted for ROSE was stained using toluidine blue stain. The diagnosis and specimen adequacy in ROSE was compared with that of the final cytology report.

Results: 320 patients were included and 1537 lymph nodes samples. ROSE diagnosis was concordant with final diagnosis in 1486 (96.68%) LNs and non-concordant in 51 (3.31%). Unsatisfactory ROSE diagnosis was more likely to be non-concordant (82.8 vs 17.1%) than a ROSE satisfactory diagnosis (97.4 vs 2.3%) or normal node diagnosis (98.1 vs 1.9%) ($P < .0001$). The sensitivity, specificity, NPV, PPV, and overall accuracy of ROSE were 0.84, 0.98, 0.97, 0.98, and 0.97, respectively. Differences in diagnosis concordance rate between pathologist ($P < .023$), cell block preparations ($P < .03$), number of passes and TBNA slides were seen.

Conclusion: TBNA slides during ROSE if stained with H & E stains will at least take 3 - 4 mins for diagnosis and in turn will be cumbersome to wait for next TBNA pass which will take more time for procedure to finish whereas TBNA slides stained with Toluidine blue will give us Cyto-Pathological diagnosis in less than 1 sec of microscopic examination which will diminish complications and helps to obtain adequate tissue rapidly in critically ill – hypoxic patient. ROSE diagnosis has a high concordance with the final diagnosis, reducing procedure time and optimizing sample for molecular profiling.

OR-005

The Clinical Application of TBNA and EBUS-TBNA in Children with Mediastinal and Hilar Lymphadenectasis

Li,Cong1、Wang,Ko-Pen2、Ye,Leping1
1. Peking University First Hospital
2. Johns Hopkins Hospital

Objective: To explore the clinical value and safety of Transbronchial Needle Aspiration (TBNA) and Endobronchial Ultrasound-guided transbronchial Needle Aspiration (EBUS-TBNA) for children with mediastinal and hilar lymphadenectasis, and to improve the pediatricians' s understanding of TBNA.

Methods: We observed the effectiveness and safety of TBNA and EBUS-TBNA in children through retrospectively analyzing the clinical data (including the first domestic case) of 7 children who had admitted to the mediastinum and hilar lymphadenectasis for unknown reasons and undergone TBNA with the age of 3 to 11 years old from October 2013 to September 2019 , which emphasized the importance of gaining proficiency in the anatomy of mediastinal and hilar lymph node positioning and the operation skills of TBNA and EBUS-TBNA.

Results: All 7 patients had significant mediastinal and hilar lymphadenectasis. They were given routine bronchoscopy for children + mediastinal lymph nodes and hilar lymph nodes TBNA (TBNA in 6 cases and EBUS-TBNA in a 6-year-old child)), the specimen smear was sent for pathological cytology and acid-fast bacilli, bacteria and fungi examination and culture to assist in the diagnosis of the cause. The surgical procedure was smooth and no complications occurred during or after the operation. The 7 children were diagnosed with 3 cases of primary pulmonary tuberculosis, among them,1 case of primary syndrome, 1 case with right pleural effusion, and 2 cases with bronchial tuberculosis; 2 cases of mycoplasma pneumoniae pneumonia; 1 case of EBV associated broncholymphohyperplasia and 1 case of chronic bacterial pneumonia, and helped to rule out lymphoma.

Conclusion: TBNA and EBUS-TBNA are minimally invasive, effective and low-risk procedures, which are safe and effective in the diagnosis of mediastinal or hilar lymphadenectasis in children, especially in the diagnosis of respiratory infectious diseases in children, which is worthy of further exploration and promotion.

OR-006

Diagnostic accuracy and safety of electromagnetic navigation bronchoscopy for percutaneously inaccessible lung nodules

Oh,Ju Hyun1、Ji,Wonjun1、Hwang,Hee Sang 2、Jang,Se Jin 2、Oh,Sang Young3、Kim,Mi Young 3、Choi,Chang-Min 1,4、Kim,Woo Sung1、Lee,Cheol4

1. Department of Pulmonary and Critical Care Medicine, Asan Medical Center, University of Ulsan College of Medicine, Seoul, South Korea
2. Department of Pathology, Asan Medical Center, University of Ulsan College of Medicine, Seoul, South Korea
3. Department of Radiology, Asan Medical Center, University of Ulsan College of Medicine, Seoul, South Korea
4. Department of Oncology, Asan Medical Center, University of Ulsan College of Medicine, Seoul, South Korea

Objective: Although electromagnetic navigation bronchoscopy (ENB) is a useful emerging technique to evaluate peripheral lung lesions, little is known about its accuracy and safety in diagnosing pulmonary nodules that cannot be accessed using a percutaneous transthoracic needle biopsy (PCNB).

Methods: As a single center retrospective study, we selected the patients with peripheral pulmonary nodules which were difficult to undergo biopsy by PCNB methods. Patients who had endobronchial lesions observed by conventional bronchoscopy before ENB were excluded. We performed ENB under moderate sedation for histologic diagnosis.

Results: ENB guided biopsy was conducted for 132 pulmonary nodules in 122 patients between September 2017 and April 2020. The median age of study population was 66 years (range 35-90), the proportion of male was 64.5% (78 of 122). The mean diameter of lung nodules was 26.6± 11.8 mm. About half of the nodules were found in upper lobe (50.0%) and 57.6% (76 of 132) of nodules were solid. The rate of successful lesion access using ENB was 91.7% (121/132) and 11 cases were failed due to anatomical difficulties through the bronchoscopy. The mean procedure time was 18.2±8.4 mins. The Diagnostic yield of ENB guided biopsy was 55.4% (67/121) and diagnostic accuracy was 80% (64/80). Nodule size (Odd ratio (OR) 1.07, 95% confidential interval (CI) 1.02-1.12, p=0.003), positive airbroncho-sign (OR 2.53, 95% CI 1.09-5.87, p=0.03), and mean procedure time (OR 0.94, 95% CI 0.90-0.99, p=0.036) were significantly associated with diagnostic yields, while location of the nodule and shape of nodule were not related in multivariable analysis. Interestingly, the diagnosis yield was showed a gradual increased pattern as over 60 cases. The sensitivity for malignancy was 72% (54 of 75). 15 patients (12.3%) were experienced the biopsy related complication events. The pneumothorax occurred in 4 patients (3.3%), and a half of them underwent the chest tube drainage. Although the bleeding complication occurred in 11 patients (9.0%), only 3 patients (2.5%) showed moderate bleeding. There was no major bleeding or death related to the procedure.

Conclusion: In this study, ENB guided biopsy showed an increased pattern of the diagnostic yield according to experience accumulation, and good safety profile to evaluate peripheral pulmonary nodules even if percutaneous approach was difficult and dangerous.

OR-007

The Diagnostic Yield and Safety of Transbronchial Cryobiopsy in Interstitial Lung Disease: A Perspective National Multicenter Real World Study

Chen,Xiaobo、Li,Shiyue

Objective: Transbronchial cryobiopsy (TBCB) has been widely used for the diagnosis of lung diseases, especially for interstitial lung disease (ILD). Most of the clinical reports have shown that the TBCB had good efficacy and safety in the diagnosis of the ILD. But the diagnostic yield between publishes was quite different. Therefore, we conducted a prospective national multicenter study to investigate the efficacy and safety of TBCB in the diagnosis of ILD in the real world.

Methods: Prospective national multicenter real-world study was conducted from August 2018 to August 2019. Patients of ILD with unknown etiology undergoing TBCB were enrolled in 20 hospitals from 12 provinces or municipalities. The diagnostic yield and complications were analyzed.

Results: A total of 373 patients with a mean age of (52.6 + 12.4) years from 20 hospitals were enrolled. Cases of them were male and the other 179 cases were female. The PH, PCO2 and P aO2 of artery blood gas analysis were (7.41 ± 0.03), (39.9±5.4) mmHg, (86.3±23.7) mmHg respectively. The FEV1 and FVC and DLCO of lung function were (70.6 + 25.6) % predicted, (71.1 + 25.1) % predicted, (53.5 + 28.8) % predicted respectively. The freezing time was ranged from 3 s to 10 s. The (3.7±1.1) specimens were collected per patient. The sample size is (17.3±9.6) mm2. The incidence rates of grade 0, grade 1 and grade 2 bleeding were 19.0%, 23.3% , and 57.6%, respectively. The incidence of pneumothorax was 4.8%. The proportion of definite pathological diagnosis, possible pathological diagnosis, and unclassified diagnosis were 62.5%, 5.6%, and 31.9% respectively. The diagnostic yield of MDD in 20 hospitals was ranged from 20% to 87.5%. The overall MDD diagnostic yield was 63.5%. The number of TBCB by 1.9mm and 2.4mm cryoprobe was 326 cases and 47 cases respectively. The incidence of grade 2 bleeding with 1.9mm and 2.4mm cryoprobe was 58.6% and 55.3% respectively and The incidence of pneumothorax was 1.5% and 10.6% respectively ($p<0.05$). The diagnostic yield of MDD by 1.9mm and 2.4mm cryoprobe was 65.6% and 48.9%, respectively ($p<0.05$). According to the number of obtaining specimens, patients were divided into five groups: one sample group(group 1), two samples group(group 2), three samples group (group 3), four samples group (group 4), five samples group(group 5). The number of cases in group 1 to 5 is 44 cases, 108 cases, 98 cases, 114 cases, 9 cases respectively. There were no serious fatal hemorrhage and the incidences of pneumothorax were 22.2%, 2.3%, 6.5%, 6.1% and 2.5% respectively in group 1 to 5. The diagnostic yield of MDD in group 1 to 5 were 33.3%, 43.2%, 56.5%, 67.3% and 77.2% respectively and the differences of the MDD diagnostic yield between different groups were significant ($p < 0.05$).

Conclusion: The diagnostic yield of TBCB in ILD varies greatly in the real world in our country, and the overall diagnostic yield is not ideal. Therefore, it is necessary to establish standardized procedures and standard training of TBCB to improve the efficacy and safety. It is recommended that using a 1.9mm cryoprobe and obtaining five specimens per patient could be achieved a better diagnostic yield and without a significant increase of complication.

OR-008

The optimal freezing time of transbronchial criobiopsy in the diagnosis of interstitial lung disease: A prospective randomized controlled trial

Chen,Xiaobo、Li,Shiyue

Objective: To compare the efficacy and safety of transbronchial criobiopsy(TBCB) in interstitial lung disease (ILD) with different freezing times. This study is aimed to explore the optimal freezing time of TBCB in ILD.

Methods: A prospective randomized controlled study was conducted in the First Affiliated Hospital of Guangzhou Medical University from May 2019 to February 2020. The patients with unknown ILD who were needed cryobiopsy for definite diagnosis were enrolled. According to different freezing time, patients were randomly divided into 4 groups (3s, 4s, 5s and 6s groups). All procedures were performed under general anesthesia with tracheal intubation. Five samples were obtained in every patient with the cooling gas pressure of 60 bar. The specimen size, complications, pathological and MDD diagnostic yield were collected and analyzed

Results: A total of 100 patients were enrolled and randomly separated to four groups. There were no significant differences in baseline of the mean ages, artery blood gas analyzed (PH, PCO2, PaO2) and pulmonary function (FEV1, FVC, and DLCO) between four groups ($p > 0.05$). The specimen sizes of 3 s, 4 s, 5 s, and 6 s group were (12.1 ± 4.4) mm2, (16.1 ± 4.6) mm2, (21.4 ± 5.3) mm2 and (21.8 ± 3.3) mm2 respectively. The specimen size was positively correlated with the freezing time. No severe fatal bleeding (grade 3) occurred in four groups. The rates of moderate bleeding (grade 2) in the 3s, 4s, 5s, and 6s group were 11.0%, 26.4%, 31.7% and 45.2% respectively. The incidence of mild bleeding (grade 0 and 1) were 89.0%, 73.6%, 68.3% and 54.8% respectively. Pneumothorax occurred once in 4s, 5s, and 6s group respectively. The proportions of definite pathological diagnosis in 3s, 4s, 5s, and 6s group were 60%, 80%, 84%, and 96% respectively. The proportions of probable pathological diagnosis in 3s, 4s, 5s, and 6s group were 8%, 8%, 16% and 4% respectively($p<0.05$). The proportions of unclassify pathological diagnosis in 3s, 4s, 5s, and 6s group were 32%, 4%, 8% and 0% respectively($p<0.05$). The infinite multidisciplinary discuss (MDD) diagnosis in 3s, 4s, 5s and 6s group were 56%, 84%, 88% and 92% respectively($p<0.05$), but there were no significant differences between the 4s, 5s and 6s group.

Conclusion: The size of specimens, the severity of bleeding, and the diagnostic efficiency by TBCB in ILD were all related to the freezing time. It is recommended that the initial freezing time of TBCB in ILD is 4s with the gas pressure of 60 bar, which can obtain better diagnostic efficiency and a smaller incidence of complications.

OR-009

Efficacy and safety of iodopovidone pleurodesis for the treatment of malignant pleural effusion

Zhang,Wei、Wang,Xi 、Jin,Zhe 、Cheng,Yuan、Huang,Junjun、Hu,Yan、Hu,Zhanwei、Liao,Jiping、Zhang,Hong、Wang,Guangfa
北京大学第一医院

Objective: To determine the efficacy and safety of iodopovidone pleurodesis in the treatment of malignant pleural effusions, and compare the difference between different chest tube sizes.

Methods: MPE patients treated with iodopovidone pleurodesis in Peking University First Hospital from May 2010 to May 2019 were retrospectively reviewed. Demographic data, Pathological types of the malignancies, clinical features, and laboratory results of the effusions, as well as the size of the chest tubes used, duration of chest tube drainage following the procedure, adverse effects, and long term outcome were analyzed.

Results: There were 39 cases altogether (male 22 cases, female 17 cases, age 28-86), median follow up time was 55 days (29-282). Pleural effusion was on the left side in 16 cases (41.0%), and on the right side in 23 cases (59.0%). MPE was caused by pleural metastasis of pulmonary adenocarcinoma in 27 cases, squamous cell lung cancer in 3 cases, malignant mesothelioma in 3 cases, pleural metastasis of breast cancer in 2 cases, and metastasis of ovarian cancer, stomach adenocarcinoma, squamous cell thymic cancer and osteogenic sarcoma in 1 case respectively. Pleurodesis was successfully achieved in 28 cases, the overall success rate was 71.8%. The median duration of chest tube drainage was 3 days. 28 cases (71.8%) had fever after the procedure, and lasted for 3 (1-11) days; 27 cases (69.2%) had noncardiogenic chest pain; 10 cases (25.6%) had nausea with vomit in 5 cases, and hypotension in 3 cases (7.7%) respectively following the procedure. Incomplete ileus and local skin and soft tissue infection were observed in 1 case respectively. In 1 case the iodopovidone was not able to be drained after the chest tube was clipped for 2h. All the adverse effects were relieved easily with treatment. There was no significant difference in the success rate and the duration of chest tube drainage between 14F and 24F chest tube ($P > 0.05$, respectively); The incidence of fever, noncardiogenic chest pain was higher with 24F ($P<0.05$, respectively), and there was no significant difference in the incidence of nausea, vomit and hypotension ($P > 0.05$, respectively).

Conclusion: Iodopovidone pleurodesis is a safe and effective treatment for MPE. The size of the drainage chest tube does not affect the efficacy of the procedure. Larger chest tube size is related to more complications.

OR-010

Comparison of the effects of bronchial thermoplasty and frozen balloon ablation therapy on airway smooth muscle

Li,Xuan
Shanghai Tenth People's Hospital

Objective: We aimed to compare the effects of bronchial thermoplasty (BT) and frozen balloon ablation therapy in airway smooth muscle (ASM) ablation.

Methods: Effects of haematoxylin and eosin, Masson, and immunohistochemical staining on bronchial smooth muscle thickness, collagen production, and M3 receptor expression were compared at 1 month between BT and frozen balloon ablation.

Results: BT, 7-second, 30-second, and control groups had significantly different smooth muscle thickness, collagen fibre mean optical density and smooth muscle M3 receptor expression. Compared with the controls(58.89±5.377 μm2/μm), 7- and 30-second groups (17.57± 6.796 μm2/ μm, 30.52±3.464 μm2/ μm) had significantly decreased ASM thickness (P<0.01). Compared with the controls(0.02059±0.004891), 7- and 30-second groups (0.1017±0.0102, 0.1248±0.01637) had increased collagen fibres (P<0.0001). There was no significant difference in bronchial smooth muscle thickness and collagen fibre formation between the BT and control groups (P>0.05). Compared with the control group(0.1067±0.00449), mean optical density of the smooth muscle M3 receptor was significantly decreased in the other three groups (0.02368±0.003388, 0.03273±0.00798 and 0.06478±0.003348,P<0.0001).

Conclusion: The frozen balloon treatment has the effect of ablating bronchial smooth muscle. Its ablation effect is more obvious than BT and its onset time is short. The neural mechanism participates in the mechanism of BT and frozen balloon treatment.

OR-011

In vitro study on the effect of different clamping methods on the learning curve of bronchial occlusion

Wu,Weide、Wu,Weijing、Zeng,Yiming、Lin,Huihuang、Liu,Yanhui
Second affiliated Hospital of Fujian Medical University

Objective: The purpose of our study is exploring the effect of different methods clamping bronchial silicone plug on the learning curve of bronchial occlusion in ex vivo pig lungs. And we compare the advantages and disadvantages of three different clamping methods of bronchial plug for bronchial occlusion.

Methods: The ex vivo pig lungs were occluded by four novice operators of bronchial occlusion in our study. Three different clamping methods of bronchial plug were used by operator to block bronchus, as follows: Method A: bottom coil clamping, Method B: tip knot clamping, Method C: bottom protuberance clamping. Under the guidance of bronchoscope, the operator used bronchial plug to occlude the pig lung's segmental bronchus of the cranial lobe, by different clamping methods, with the help of biopsy forceps. Each operator counted the operation time of each method for a total of 30 times. When the bronchial plug coundn't be blocked in place, or the bronchoscope withdraws from the lumen for various reasons during the operation, it was defined as failure. Recording the operation time and the failure rate. The data were statistically analyzed at last.

Results: According to the CUSUM, the inflection points on the learning curve of three clamping methods for bronchial occlusion (Method A, Method B, Method C) were 20, 15 and 20.In the whole learning process, the failure rate of Method A was 23.6%, that of Method B was 11.1%, and that of Method C was 28.1%. There was a significant

difference in the failure rate of bronchial occlusion by the three methods (P<0.05).In the stage of Mastery, the median time of bronchial occlusion by Method A was 8 seconds, that by Method B was 7 seconds, and that by Method C was 8 seconds. The overall distribution of bronchial occlusion operation time of these three clamping methods was the same (P>0.05), However, at the end of the learning period, the failure rates of Method A, Method B and Method C were 33.8%, 10% and 27.4%, which was statistically different (P < 0.05).The bronchial plug was clamped in the pig lung by the three methods when the bronchial plug fell off in the pig lung during the operation, and it was directly occluded for 10 times. The time limit was 2 minutes. The failure rate of Method A was 90%, that of Method B was 30%. that of Method C was 80%. The difference was statistically significant (P < 0.05).

Conclusion: In general, compared with Method A and Method C, the learning period of bronchial occlusion by Method B is shorter. The Method B is easier to learn. The failure rate of Method B is lower. The operating time of Method B is similar to that of Method A and Method C in the stage of Mastery. The failure rate of Method B in remedial operation is lower, it is better than the other two methods. We recommend Method B for clinical learning and promotion.

OR-012

USE OF POLYVINYL ALCOHOL SPONGE AND CYANOACRYLATE GLUE IN THE TREATMENT OF BRONCHOPLEURAL FISTULA.

Galluccio,Giovanni、Lucantoni,Gabriele、Romani,Sofia、Dello Iacono,Raffaele、Batzella,Sandro
Center of Thoracic Endoscopy, San Camillo – Forlanini Hospital

Objective: Bronchopleural fistulas represent a relatively frequent complication of pulmonary resections (1.8%) that may lead to patients' death. This pathology may be treated by pleural drainage, open surgery, endoscopy, depending on the morphology of the fistulas, on the site, on the time of onset after resection. An endoscopic less invasive treatment may be desirable especially in suffering patients with co morbidities, in whom a new surgery may be risky. Otherwise the endoscopic approach is sometimes difficult, depending on the dimensions of the leak. Many different techniques have been proposed, with a good rate of success in smaller and recent fistulas. In larger and older ones an effective may be difficult to achieve, and complex procedures have been proposed.

The authors present a new method, that proved to be efficient in a series of patients also in larger and chronic fistulas.

Methods: through a rigid bronchoscope, a small cylinder of PVA (polyvinyl alcohol) sponge is inserted to the fistula and then charged with a very fluid, slow activated cyanoacrylate. The cylinder increases its volume by two to four times, acquiring an hourglass shape, while the cyanoacrylate gradually polymerizes and solidifies, with tight adherence to the walls of the fistula. The immediate result is the occlusion of it, but the sponge also induces inflammatory reaction, as a foreign body, which brings ,in the following weeks, to a granuloma (Figure 1).

Results: We treated 7 patients with post resection fistulas ranging from 4 to 8 mm. The site was the bronchial surgical suture in 6/7 patients and in one case the right wall of distal trachea, after N4R lymphectomy. A complete occlusion of the fistulas was achieved in 7/7 patients and a definitive result in 5/7. The procedure took 40±5 minutes to be performed. The mean hospital stay was 2 days. No severe complications occurred after the interventional endoscopic procedures.

Conclusion: The new technique we experienced may represent an effective treatment in patients with larger fistulas, but also on difficult sites like trachea.

OR-013

Feafesibility and long term safety of Ho:YAG laser lithoptysis in broncholithiasis patients

Cheng,Yuan、Wang,Guangfa、Zhang,Wei、Zhang,Hong
Peking University First Hospital

Objective: Broncholithiasis are rare disease which related to granulomatous infection, such as tuberculosis, histoplasmosis, fungus, actinomycosis and nocardiosis. Whether treatment is needed depends on the symptoms due to airway obstruction, such as cough, hemoptysis, dyspnea, recurrent pneumonia. Most report of theraputic bronchoscopy treat as foreign body, foreign body forceps or rigid forceps , Fogarty balloon are used to remove broncholiths. Bronchoscopic removal is often difficult, especially for large or transluminal broncholith. Only little experience with laser lithotripsy，The appropriate type of laser and parameters are unclear. With the experience of urology lithotripsy in the treatment of urinary calculi, we tried to use holmium laser (Ho:YAG) lithotripsy, as reported below.

Methods: A retrospective analysis of the clinical data and follow up of 13 broncholithiasis patients who underwent Ho:YAG laser lithotripsy from May 2012 to June 2018.Parameter settings of Laser were recorded .

Results: 13 patients （2 males and 11 females），19 times of lithotripsy procedures were performed. All of broncholithiasis were successfully removed. All the procedures were under rigid bronchoscope with general anesthesia .Ho:YAG laser lithotripsy set the initial pulse frequency of 5 Hz, pulse energy 0.8 J, with gradually increase the frequency and energy .The frequency range is 5~15 Hz, energy range 0.8~1.6 J in these procedures. hemorrhage , bronchial esophageal fistula and infection was most common acute complications.All cases were followed up until March 2019, with a maximum follow-up of 8 years and a minimum of 1 year. All patients survived, clinical symptoms disappeared, and no long-term complications.

Conclusion: Ho:YAG laser lithoptysis in broncholithiasis treatment is effective and safe in long term follow up.

OR-014

Utilization of AI in virtual bronchoscopic navigation

Kunisaki,Mamoru、Shinagawa,Naofumi、Takashima,Yuta、Furuta,Megumi、Shoji,Tetsuaki、Mizugaki,Hidenori、Asahina,Hajime、Kikuchi,Eiki、Kikuchi,Junko、Sakakibara,JK、Konno,Satoshi
First Department of Medicine， School of Medicine， Hokkaido University Hospital

Objective: Background: We have previously shown the usefulness of virtual bronchoscopic navigation (VBN) for diagnosing peripheral pulmonary nodules. In VBN system, the airway is automatically extracted from CT data; however, small airway is sometimes not detected enough in peripheral area. For such a case, we can add a bronchial route manually to the target lesion on DirectPath® (DP®, Cybernet Systems, Tokyo, Japan). In our analysis from October 2016 to May 2018, we found that manual extraction of +1 order or higher was required in 53 of 101 cases in DP®ver2.0. So we are developing DP®ver3.0 with deep learning using artificial intelligence (AI), aiming at reaching lesions only by automatic extraction to simplify image creation.

Objective: We compared the automatic extraction ability with DP®ver3.0 and ver2.0. currently on the market.

Methods: Of the 55 patients who underwent bronchoscopy at Hokkaido University Hospital from October to December 2019, 42 patients with peripheral lung involvement were included. Using DP®ver3.0 and ver2.0 in all cases, images were created up to the point where the lesion was reached, and the bronchial order automatically extracted and the success or failure of reaching the lesion with only the automatic extraction were compared retrospectively.

Results: Median diameter of the target lesion was 22mm (median; range:6-42mm). The virtual bronchoscopic

image was constructed to 6th generation bronchus (median; range:3-9). DP®ver3.0 and ver2.0 automatic extraction bronchus were 5th generation bronchus (median; range:3-7) / 5th generation bronchus (median; range:1-7).The time required for automatic extraction was 22 minutes (median; 15-27) / 16 minutes (median; 11-22).Although the automatic extraction ability was similar in many cases, 8 (19%) could reach the lesion by automatic extraction only in DP®ver3.0 and 4 (9%) only in ver2.0. The extraction time was longer in DP®ver3.0 in all cases.

Conclusion: In DP®ver3.0 using AI, there were many cases that could reach the lesion only by automatic extraction than ver2.0, but further accumulation of cases is necessary in the future.

OR-015

Endoscopic Management of Post-tracheotomy Tracheal Stenosis: Ten-years' Experiences From A Pulmonary Interventional Center in China

Chen,Feng、Zhang,Jie
Beijing Tiantan Hospital affiliated to Capital Medical University

Objective: To summarize the endoscopic management of adult post-tracheotomy tracheal stenosis,to identify predictors of a successful outcome.

Methods: Eighty-seven consecutive patients with post-tracheotomy tracheal stenosis admitted in our hospital between June 2009 to June 2019 were enrolled into our study. we identified 32,34 and 21 patients with a stenosis above, around and under the tracheostoma, respectively,we defined them type 1,type 2 and type 3.Baseline characteristics of patients, morphological characteristics of tracheal stenosis according to a newly developed classification system, the treatment details, decannulation and prognosis were collected. Cox regression was used to identified the predictors of endoscopic success.

Results: There were fifty-seven male patients and thirty female patients in this study,the average age was 48.0±17.4 years, the average length of stenosis was 1.77 (1.0-2.2)cm. 90.8% of lesions were tracheal stenosis and 9.2% were subglottic stenosis.83.9% of patients had a stenosis over 50%. Different treatments were applied in the three types of patients, for Type1 patients,the main treatments include reducing edema of local tracheal mucosa and insertion of silicone stent or Montgomery T-tube,for Type 2 patients, removing the granulation tissue and local cryotherapy were needed and for type 3 patients, balloon dilatation, local cryotherapy and stent placement were crucial procedures.47.1% of the patients were successfully extubated and achieved a cure and patients in type 2 had the highest rate of decannulation(25 of 34,73.5%).Log-rank test indentified local use of paclitaxel,the type of tracheal stenosis(intralumina), consciousness of patients(people who have clear mind),location of tracheal stenosis(Type 2 patients) and degree of tracheal stenosis(＜ 90%) are predictors of endoscopic success.In Cox regression, the local topical use of paclitaxel and a better state of consciousness were predictors of t endoscopic success.

Conclusion: Endoscopic treatment is effective for most patients with post-tracheotomy tracheal stenosis, appropriate treatments should be taken according to the location and type of tracheal stenosis. Local use of paclitaxel could be an effective treatment for tracheal stenosis.

OR-016

The application of transbronchial lung cryobiopsy and uniportal and tubeless video-assisted thoracic surgery in the multidisciplinary diagnosis of interstitial lung disease—a real world prospective study

Han,Qian、Xiaobo,Chen、Shiyue,Li、Qun,Luo
State Key Laboratory of Respiratory Disease, National Clinical Center for Respiratory Disease, Guangzhou Institute of Respiratory Health The First Affiliated Hospital of Guangzhou Medical University

Objective: Objective: To illustrate the application of transbronchial lung cryobiopsy (TBLC) and uniportal and tubeless video-assisted thoracic surgery (UT-VATS) in the diagnostic algorithm of interstitial lung disease (ILD).

Methods: Methods: This prospective study included 137 patients admitted to interstitial lung disease center of The First Affiliated Hospital of Guangzhou Medical University from November 2018 to Mar 2019 without definite diagnosis after multidisciplinary discussion (MDD) on clinical and radiological data. As indicated by the MDD, 67 patients underwent UT-VATS and 70 underwent TBLC. The specificity of pathological information and its contribution to final MDD diagnosis were evaluated, the post-operative complications and hospitalization expense were compared.

Results: Results: The spirometry parameters (including FVC, FEV1 and DLCO%) in UT-VATS were better than in TBLC group. UT-VATS provided more specific pathological results compared with TBLC (85.7 vs 73.7%, p=0.06). Moreover, UT-VATS, in the whole ILD spectrum, was more likely to alter the initial clinical-radiological diagnosis (34.3 vs 12.9%, p=0.003) and provided more informative results to the final MDD diagnosis compared to TBLC (91.0 vs 80%, p=0.06). Pathological information via UT-VATS was more clinically useful than TBLC for cases initially diagnosed as undefined idiopathic interstitial pneumonia (UIIP), yet they contributed similarly to cases initially diagnosed as interstitial pneumonia with auto-immune features (IPAF)/connective tissue disease-related ILD (CTD-ILD). The safety of UT-VATS was comparable with TBLC while the latter cost less during the hospitalization (US$4,855.7 vs US$3,590.9, p<0.001).

Conclusions: Under current multidisciplinary discussion option, UT-VATS appeared more informative in cases initially diagnosed as UIIP; while TBLC may contribute similarly to final MDD diagnosis as UT-VATS in patients initially diagnosed as IPAF/CTD-ILD. TBLC could be considered in patients with more severe pulmonary dysfunction and those cannot afford relatively high medical cost. This study may pave the road for future studies investigating the diagnostic efficacy of different biopsy methods in a certain ILD subtype.

OR-017

Initial experience of radial probe guided cryobiopsy for diagnosis of peripheral lung lesion

Vallandramam,Pattabhiraman、Srinivasan,Arjun、Sivaramakrishnan,Mahadevan、Shankaranarayanan,Annapoorni、Natarajan,Balasubramaniyam
Royal Care Super speciality Hospital

Objective: To evaluate the feasibility, safety and yield of radial probe (RP) guided cryobiopsy of well-defined peripheral lung lesion.

Methods: Retrospective analysis of records of patients undergoing bronchoscopic cryobiopsy for undiagnosed peripheral lung lesion between February 2019 and December 2019 at a tertiary care referral centre. All procedures were carried out under general anaesthesia through laryngeal mask airway with radial probe and 1.9 mm cryoprobe

being introduced sequentially through a guide sheath under fluoroscopic guidance.Some of the patients had navigation Bronchoscopy to enhance accuracy.

Results: A total of 67 cryo transbronchial biopsies were carried out during the study period. Of these, 13 procedures (all men; mean age: 55.1 years, range 35-77 years) were done for peripheral lung lesions and rest were done for diagnosis of diffuse parenchymal lung disease. The mean diameter of lesions was 2.67cm (range 1.5 – 4.9 cm). Lesion was concentric to the probe in 10 and eccentric in 3 patients. Navigation bronchoscopy was used in 6 of the 13 patients. Specific diagnosis was achieved in 10 patients (diagnostic yield 76.9%; malignancy 8 and tuberculosis 2). Of the 3 patients where specific diagnosis was not achieved, 2 had non-specific inflammation of which one showed spontaneous resolution on follow up and one was lost to follow up. In one patient sample was non representative and was diagnosed as malignancy on CT guided biopsy. Bleeding was the most common complication seen in 6 of the 13 patients (46.15 %; mild in 3 and moderate in 3) and there was no pneumothorax. All patients tolerated the procedure well and were discharged on the same day.

Conclusion: Radial probe guided cryobiopsy is an additional tool to improve diagnostic yield of peripheral lung lesion without risk of pneumothorax. This procedure however carries higher risk of bleed which the operator needs to be ready to handle.

OR-018

Endoscopic lung volume reduction with combined Implantation of endbronchial and intrabronchial valves in patients with severe lung emphysema

Eberhardt,Ralf1,2、Derossi,Susanne1、Schuhmann,Maren1、Kontogianni,Konstantina1,2、Gompelmann,Daniela1,2、Heussel,Claus-Peter1,2、Herth,Felix JF1,2
1. Thoraxklinik at the University Heidelberg
2. Translational Research Center (TLRC) Heidelberg, German Center for Lung Research (DZL), Germany

Objective: Endoscopic valve implantation for endoscopic lung volume reduction (ELVR) is an established treatment option in patients with severe lung emphysema. Two types of these one-way valves are available: endobronchial (Zephyr®, Pulmonx, Inc., Neuchatel, Switzerland) and intrabronchial valves (IBV, Spiration®, Olympus, Tokyo, Japan). Various randomized controlled trials demonstrate the feasibilty and effectiveness of both EBV and IBV. In some patients – mostly due to anatomical reasons – it is neccessary to use both types of valves. The goal of this study was to evaluate the feasibilty and safety of this combined approach.

Methods: All patients, who have been treated in a combined approach with the primary use of EBV and IBV between 2013 and 2018 in the Thoraxklinik at the University Heidelberg, Germany, have been enrolled in this retrospective analysis. Significant collateral ventilation was excluded by fissure analysis and/or endoscopic Chartis® assessment. Data of pulmonary function (FEV1 and RV), exercise capacity (6-MWT) und dyspnoe score (mMRC) 30, 90, 180 and 365 days after valve treatment were collected and compared to baseline. Complications like postinterventional pneumothorax were gathered.

Results: Data of 44 patients have been available. 42 patients have been treated in the lower lobes (20 right lower lobe, 22 left lower lobe), whereas the right and the left upper lobe have been the target lobe only once. In average 1.8 EBV and 1.1 IBV have been used. The emphysema distribution was heterogeneous in 38 patients (86.4 %) and homogeneous in 6 cases (13.6 %).

The mean target lung volume reduction (TLVR) in all cases was 687 cm3. This leads to improvements in FEV1 (+ 0.11 l), RV (- 0.99 l), 6-MWT (+ 64 m) as well as in mMRC (- 0.5 points) 90 days after ELVR with combined use of EBV and IBV. Benefits in the different parameters have been seen up to 365 days after ELVR. The pneumothorax rate

was 9% (4 of 44 patients).

Conclusion: The combined use of EBV and IBV for vale implantation is feasible and safe and therefore a possible approach for patients with severe emphysema, if the anatomy of the bronchial tree makes this neccessary. The patients will improve similar in pulmonary function, exercise capacity and dyspnoe score compared to the exclusive use of one valve type. Furthermore the pneumothorax rate seems not be increased.

OR-019

Diagnostic Yield of Electromagnetic Navigation Bronchoscopy in Subcentimetric Pulmonary Nodules

Flandes,Javier1、Morales,Mauricio 1,2、Izquierdo,Ainhoa1、Chowkri,Marwan1、Gimenez,Andres1、Fernandez-Navamuel,Iker1、Alfayate,Javier1
1. Hospital Universitario Fundaci ó n Jim é nez D í az
2. Hospital Universitario Dr. Jos é Eleuterio Gonz á lez

Objective: Observational retrospective single-center study was conducted to determine diagnostic yield and medical decision concordance addressing subcentimetric nodules with ENB in a third-level general hospital.

Methods: Electromagnetic Navigation Bronchoscopy was performed using SuperDimension / Bronchus system in 385 patients during the period from November 2011 to November 2019. In a sub-population analysis from our data (N=54) patients with subcentimetric pulmonary nodules where included. Demographic data, nodule characteristics, and complications related to the procedure have also been described.

Results: The mean age of patients was 68 ± 9 years old with male predominance (55%); Mean nodule size was 7.39 ± 1.35 mm. ENB diagnostic yield was 44% (n=22): 8 (36.3%) were malignant (75% had bronchus sign) and 14 (63.6%) were infectious/inflammatory nodules (mean follow-up of 24 ± 2 months). Adenocarcinoma was the most prevalent malignancy (87.5%)

ENB was not diagnostic in 28 (56%) cases, in which a second procedure or surgery was performed for assessment of diagnosis or final treatment. In 4 cases no clear diagnostic was obtained and they underwent SBRT because of high comorbidity and suspected malignancy without confirmed diagnosis.

Pneumothorax occurred in 3 (5.5%) patients, all of them with extremely peripheral lesions and required chest tube placement; there was no case of pneumonia or exacerbation related to the procedure.

Conclusion: ENB it’s a safe procedure with a low diagnostic yield in subcentimetric nodules, it should be reserved for selected cases with high pre-clinical malignant suspicious and ideally when bronchus sign is present.

Medical: decisions were in line with ENB diagnostic in 60% of cases, this can be explained by the high pre-clinical suspicious of the lesion.

To our knowledge this is the first study addressing subcentimetric peripheral lesions using this technic. With these types of lesions it is difficult to make a decision mainly because of the poor uptake in PET-CT scan.

OR-020

A Study of The Efficacy And Safety of Giant Emphysematous Bulla Volume Reduction via Medical Thoracoscope

Zhang,Hua、Zhang,Wei、Ge,Changsheng、Wang,Lei、Xue,Guangwei、Liu,Zongtao、Wang,Mengyao、Xu,Weiwei、Gao,Yan、Duan,Cunling、Wang,Yunjie
Ri Zhao Hospital of Traditional Chinese Medicine

Objective: Giant emphysematous bulla（GEB）is a rare pulmonary disease of bullae. Surgical intervention (e.g. video-assisted thoracic surgery,open bullectomy) is preferred for the treatment of GEB and the efficacy is satisfactory for appropriate patients.But it fails to achieve an ideal goal of minimal damage and may be unsuitable for high-risk patients.Endobronchial valve (EBV) is minimally invasive but not widely used to treat GEB.The collapse failures by collateral ventilation may lead to decreased efficacy.In addition to complications from long-term intraairway foreign bodies, EBV-induced atelectasis cannot be accurately confined to GEB and may sacrifice potential functional lung tissue.We explored the efficacy and safety of GEB volume reduction via medical thoracoscope(MT),referred to as “one thoracoscope plus one needle”.

Methods: This was a prospective,single-arm study conducted between July 2018 and April 2020 in Ri Zhao Hospital of TCM. It was performed under general anaesthesia with a double lumen endobronchial tube.During single lung ventilation,the MT entered the pleural cavity at a predetermined point according to the preoperative chest CT. ① After the comprehensive exploration of pleural cavity and adhesiolysis，the puncture needle was inserted in the chest wall corresponding to the target GEB and guided by MT to puncture the GEB.Most of the air in GEB was extracted through the needle. ② Medical glue(4~10ml) was injected into the GEB via the needle evenly from different angles. ③ The residual gas in the GEB was completely extracted and the needle was pulled out before the glue solidified. ④ The wall of the GEB was compacted with long forceps until it was completely hardened. ⑤ The lung expansion test was performed.If the bulla was still partially swollen,the steps ①～④ were repeated. ⑥ The drainage tube was placed routinely.

Results: Thirty-three patients were included. The CT showed the GEB volume was reduced by more than 90% in 30 patients while more than 75% in the other 3 patients after operation. Arterial blood gas analysis showed pH increased from 7.42±0.03 to 7.44±0.04($P < 0.05$) and PaCO2 decreased from 48.83±8.24 mmHg to 45.85±7.80mmHg ($P < 0.05$).The 6-Minute Walk Test(6MWT) increased from 231.55±161.41m to 288.10±126.18m ($P < 0.05$).The degree of dyspnea improved significantly（$P < 0.05$）.Ten patients had reached the time of half a year postoperatively. And in these patients, PaCO2 decreased from 49.40 ± 6.90mmHg to 42.90±4.77mmHg($P < 0.05$) at half a year follow-up while oxygenation index increased from 290.58±74.90 to 366.09±45.45 ($P < 0.05$) .The 6MWT increased from 200.78±153.53m to 399.33±76.60m ($P < 0.05$).The degree of dyspnea also improved significantly（$P < 0.05$）.Compared with the time of discharge,the GEB volume tended to be further reduced while the 6MWT,PaO2 and oxygenation index were further improved（$P < 0.05$） at half a year follow-up.One case of preoperatively existing pneumonia progressed and one case of infection in the pleural cavity occurred postoperatively. And both patients recovered after treatments.

Conclusion: “One thoracoscope plus one needle” is effective,safe and minimally invasive. And the efficacy may become more pronounced over time.

OR-021

Chinese experts consensus on the standardized procedure and technique of transbronchial cryobiopsy

Guo,Shuliang1、Li,Qiang2、Jiang,Jinyue1、Luo,Fengming3、Li,Yishi1、Jin,Faguang1、Liu,Xinzhu1、Wang,Hongwu4、Chen,Ping1、Bai,Chong5、Dai,Haiyun1、Huang,Haidong5、Ye,Xianwei6、Yi,Xianghua7、Zhang,Jie8、Wang,Changhui9、Ke,Mingyao10、Sun,Jiayuan11、Feng,Jing12、Zhou,Hongmei13、Wu,Youru14、Wang,Zhen15、Ma,Yun16、Li,Jing17、Lv,Liping18、Xie,Baosong19、Hohenforst-Schmidt,Wolfgang 20、Ding,Weimin21、Wang,Xiaoping22、Yang,Junyong23、Cai,Qingshan24、Sun,Peng25、Luo,Zhuang26、Giri,Mohan1

1. The First Affiliated Hospital of Chongqing Medical University
2. Shanghai East Hospital, Tong Ji University
3. West China Hospital, Sichuan University
4. Emergency General Hospital
5. Changhai Hospital, The Second Military Medical University
6. Guizhou Provincial People's Hospital
7. Tongji Hospital of Tongji University
8. Beijing Tiantan Hospital, Capital Medical University
9. Shanghai Tenth People's Hospital, Tongji University
10. The Second Affiliated Hospital of Xiamen Medical College
11. Shanghai Chest Hospital, Shanghai Jiao Tong University
12. General Hospital, Tianjin Medical University
13. Zhongshan Hospital Affiliated to Guangdong Medical University
14. Mianyang Central Hospital
15. Beijing Chao-yang Hospital, Capital Medical University
16. Henan Provincial People's Hospital
17. Guangdong Provincial People's Hospital
18. Anhui Chest Hospital
19. Fujian Provincial Hospital
20. "Hof" Clinics, University of Erlangen
21. Beijing Chest Hospital, Capital Medical University
22. Shandong Provincial Chest Hospital
23. Xinjiang Chest Hospital
24. Hangzhou Red Cross Hospital
25. Jilin Tuberculosis Hospital
26. First Affiliated Hospital of Kunming Medical University

Objective: Transbronchial cryobiopsy (TBCB) is a technique to obtain frozen samples of lung tissue from the distal bronchioles, in which the tissue surrounding the tip of a cryoprobe inserted through the bronchoscope is frozen with a rapid freezing process and abruptly pulled away from adherent tissue. The advantages of TBCB are improved diagnostic yield, reduced trauma, large and high-quality specimens, potentially decreased complications, and lower cost in comparison to surgical lung biopsy. TBCB is mainly used for the etiological diagnosis of diffuse parenchymal lung diseases (DPLD). Additionally, it can be used for biopsy of peripheral lung lesions. TBCB has been widely used as a new diagnostic tool in Europe since 2009 (1), and has been used in some highly specialized interventional centers in China since 2015.

Methods: However, the procedure of TBCB has not been standardized. There are still disagreements among pulmonologists internationally and in China regarding operation methods, biopsy sites, number of biopsy specimens, types of frozen probes, freezing time and specimen handling, and there is urgent need for procedural standardization of TBCB for effectiveness and safety.

Results: This work is an evidence- and expert-based consensus on the procedure and technique of TBCB, which is a collaborative effort of the Working Committee on Interventional Pulmonology, Respiratory Physicians' Branch

of Chinese Medical Doctor Association, Committee of Interventional Pulmonology, Chinese Society for Tuberculosis, Chinese Medical Association, and the Chinese Western Association of Interventional Pulmonology.

Conclusion: We hope it will contribute to the transition of the etiologic diagnosis of DPLD from the clinico-radiologic (CR) model to the clinico-radiologic-pathologic (CRP) model, which hopefully will increase the rate of etiologic diagnosis of DPLD, and improves the effectiveness, safety and standardization of the procedure and technique of TBCB to ensure diagnostic yield.

OR-022

A preliminary study on the application of optical coherence tomography in the diagnosis of central bronchial lesions

Zhu,Qiang、Yang,Zhen、Jia,Yanhong、Li,Lina、Guo,Mingxue、Zou,Chenxi、Xu,Yi、Wang,Huishuang、Chen,Liangan
Department of Respiratory Medicine, The first medical center of the Chinese PLA General Hospital

Objective: Optical coherence tomography (OCT), a high-resolution Optical imaging technique which has been developed recently, can show the histological structure of bronchus clearly with the principle of Optical interference. This study aimed to explore the criteria of OCT interpretation for differentiating between benign and malignant lesions and predicting the pathological classification of lung cancer in central bronchial lesions, and to evaluate its clinical value.

Methods: This prospective study included patients with central bronchial lesions confirmed by chest CT. All the patients were found to have central bronchial lesion using both white-light bronchoscopy and auto-fluorescence bronchoscopy. After locating the lesion, OCT examination was performed immediately and all the images were stored simultaneously. Routine biopsy was performed at the same site and then the samples were sent for histology examination. Using pathological results as reference, the OCT image characteristics were analyzed by three clinicians who were trained by professional OCT image analysts, and the interpretation criteria for the differentiation between benign and malignant lesions and prediction of the pathological classification of lung cancer in central bronchial lesions was established in this process.

Results: A total of 121 patients were included in this study, 16 cases of benign lesions and 105 cases of malignant lesions. The sensitivity and specificity of the OCT imaging criteria for the differentiation between benign and malignant lesions in central bronchus were 97.14% and 81.25%, respectively, and the accuracy was significantly higher than that of auto-fluorescent bronchoscopy (89.2% vs 51.5%). The sensitivity and specificity for diagnosing SCC, lung adenocarcinoma and small cell lung cancer were 96.15% and 93.75%, 84.97% and 100%, and 91.18% and 93.75%, respectively.

Conclusion: As a non-biopsy technique, OCT was found to have a high accuracy of differentiating between benign and malignant lesions and predicting the pathological classification of lung cancer in central bronchial lesions. Although OCT cannot replace histological biopsy completely at present, it is still of great value for patients without accurate histological results.

OR-023

Massive airway hemorrhage in New York City

Palka,Wojciech1、Husta,Bryan2、Lessnau,Klaus1、Lazzaro,Richard1
1. Lenox Hill Hospital – Northwell Health
2. Memorial Sloan Kettering Cancer Center

Objective: We seek to improve outcomes in patients with massive airway hemorrhage. We offer a cookbook approach to management based on current literature and our own experience. Severe lung bleeding is a nightmare for the pulmonologist in the city with the highest number of malpractice lawyers in the world. There is no established universal algorithmic approach. Mortality is from asphyxiation and airway occlusion rather than from exsanguination. Diagnostic and therapeutic recommendations and proceedings vary; there is a need for a "standard-of-care" approach prior to such catastrophe.

Methods: This presentation includes cases and actions from a joint experience of more than sixty years together with literature review.

Results: The considerations are: rigid versus flexible bronchoscopy, emergent tracheostomy, dual bronchoscopy, hemostasis techniques and occlusion devices. A combination of the above seems to be optimal. Anticipation of a potential disaster, whether iatrogenic or spontaneous, is emphasized.

Conclusion: The single most important factor is the presence of more than one experienced interventional pulmonologist in such high-complexity emergencies; however, one must assume the position of a leader, despite the presence of potentially numerous advisors at the patient's bedside.

OR-024

Incidents and complications related to intercostal tube drainage in a regional hospital of Hong Kong

Chan,Wai Man Johnny、Law,Wai Lam、O,Wing Hing、Lit,Pik Kee Maggie、Lee,Kuen Han、Ng,Chun Kong
Department of Medicine, Queen Elizabeth Hospital,

Objective: Intercostal tube drainage in a common but invasive bedside procedure. Most earlier published studies were based on retrospective chart analysis. We aimed to prospectively study the indications, practice and incidents/complications related to the procedure in an acute medical unit of a regional hospital in Hong Kong.

Methods: A prospective study was carried out in a 6-month period from 12/2009 to 5/2010. All admissions to Department of Medicine in Queen Elizabeth Hospital (QEH) during that period were screened by specialty nurses and those with intercostal tube drainage were noted. Information including patient epidemiology, underlying pleural diseases indicating for intercostal tube drainage, tube size, complications and incidents (if any) etc., were recorded in pre-designed charts upon discharge or transferral to convalescent hospitals.

Results: 132 patients (98 males) underwent intercostal drainage during that period. Mean age 66.7 +/- 17.6. There were 60 pneumothoraces (45.5%), 40 malignant effusions (30.3%) and 27 parapneumonic/tuberculous effusions or empyema (24.2%). 22 (16.7%) had underlying non-respiratory co-morbidities, most common being hypertension and ischaemic heart disease. 36 (27.3%) had underlying respiratory diseases, most common being COPD and lung cancer. 36 (27.2%) were on either aspirin (32) or anticoagulants (4). Before the procedure, chest radiographs and CT thorax were available in 131 (99.2%) and 19 (14.4% respectively. Ultrasound was utilized in 51 (38.6%). The procedures were performed by doctors more than 10 years after registration in 56 (42.4%) patients, and by those with less than 3 years in

26 (19.7%). The procedure were performed within "safety triangle" in 57 (43.2%) and with small bore (<=14F) tubes in 35 (26.5%). Incidents / complications were noted in 43 (32.6%), with early (within 24 hours of placement) being 15 (34.9%). Re-insertion of tube after removal in the same episode was found in 23 (17.4%). Commonest complications were subcutaneous emphysema (18, 13.6%), blockage /kinking (13, 9.8%), dislodgement (12, 9.1%) and insertional problems in 6 (4.5%). Almost half of incidents / complications resolved spontaenously (21, 48.8%). No deaths were directly related to tube insertion. Performance of the procedure by a young (< 3 year post-registration) trainee was found to be significantly associated with increased risk of incidents/complications.

Conclusion: Incidents/complications related to intercostal tube insertion were common. This real-life study, carried out in an acute regional hospital in a metropolitan city, reflected practices that deviated from international guidelines. Training and due supervision of young doctors with the procedure appear important.

OR-025

Clinical application of photodynamic therapy for lung cancer in China

Wang,Hongwu、Zou,Heng、Zhou,Yunzhi、Zhang,Nan、Tao,Meimei、Wang,Zhina
Emergency General Hospital

Objective: With the development of interventional pulmonology, photodynamic therapy (PDT) is gradually being used in the treatment of lung cancer because of its low level of trauma, high specificity, and compatibility with traditional or common therapies. This study aims to further disseminate China’s experience.

Methods: Introduce the development, indications, contraindications, complications, operation process and skills of PDT in the treatment of lung cancer.

Results: PDT can be applied in treatment of early airway tumors and palliative treatment. Operation process includes photosensitizer skin testing, administration of photosensitizer, the selection of dosage of the drug and lighting parameters, efficacy evaluation, complications and preventative measures. In addition, PDT also can be combined with bronchoscopy interventional cytoreductive surgery.

Conclusion: PDT is a safe, easy to adopt, and effective technique for the treatment of lung cancer.

OR-026

The exploration of lung cryobiopsy in the diagnostic value of peripheral nodules

Huang,Rui、Yang,Minyu、Liao,Junxiong、Ke,Mingyao
The Second Affiliated Hospital of Xiamen Medical College

Objective: The biopsy of peripheral pulmonary nodules is of great importance to detect early lung cancer. We aimed to investigate the diagnostic rate and operation safety of lung cryobiopsy on peripheral pulmonary nodules.

Methods: A retrospective analysis was conducted on 42 cases of peripheral pulmonary nodules (8mm < the largest diameter of nodules ≤ 30mm) examined by trans-bronchial cryobiopsy technique admitted to Second Affiliated Hospital of Xiamen Medical College from November 2017 to February 2019. Among the 42 patients, 22 were male and 20 were female, with an average age of 64.3 ± 10.3 years. The average nodule size was 22.4 ± 3.4 mm. Recorded the size and location of nodules and divided them into 2 groups according to the size of nodules（8mm < diameter of nodules ≤20mm, 20mm < diameter of nodules ≤ 30mm）.First, a rigid bronchoscope was inserted under general anesthesia to establish a channel, and radial ultrasound was used to detect the location of the lesion, and then a lung cryobiopsy was performed on the nodules after pinpointing by the C-arm machine. Finally, the positive rate of the pathology, the size of frozen specimens and the complications of lung cryobiopsy were counted.

Results: A total of 157 tissues were removed from peripheral pulmonary nodules in 42 cases by lung cryobiopsy, with a size of 3-10mm and an average diameter of 5.45 ± 0.9 mm. A total of 31 cases were diagnosed, of which 26 were malignant tumors, 3 were non-specific inflammatory nodules, 2 were tuberculosis, and the diagnosis rate was 73.8 %. 11 cases were not diagnosed. The positive rates of the two groups of specimens were 55.5 % and 87.5 %, respectively. Of the 42 cases, there was moderate bleeding in 3 cases, mild bleeding in 35 cases and no bleeding in 4 cases. Two cases of pneumothorax occurred. No mediastinal emphysema occurred in 42 cases.

Conclusion: There were high positive diagnostic rate, large number of specimens, fewer complications and more safety of lung cryobiopsy using rigid bronchoscopy on peripheral pulmonary nodules.

OR-027

Next generation sequencing of tissue and circulating tumor DNA: Resistance mechanisms to EGFR targeted therapy in a cohort of patients with advanced non-small cell lung cancer

Zhang,Yujun、Xiong,Liwen、Xie,Fangfang、Zhi,Xinxin 、Zheng,Xiaoxuan、Li,Ying 、Zhu,Lei、Sun,Jiayuan
Shanghai Chest Hospital， Shanghai Jiao Tong University

Objective: Epidermal growth factor receptor-tyrosine kinase inhibitor (EGFR-TKI) has been considered as an effective treatment in epidermal growth factor receptor- mutant (EGFR-mutant) advanced non-small cell lung cancer (NSCLC). However, most patients develop acquired resistance eventually. Here, we compared and analyzed the genetic alterations between tissue assay and circulating tumor DNA (ctDNA), and further explored the resistance mechanisms after EGFR-TKI treatment.

Methods: Amplification refractory mutation system-polymerase chain reaction (ARMS-PCR), Cobas® ARMS-PCR and next generation sequencing (NGS) were performed on tissue samples after pathological diagnosis. Digital droplet PCR (ddPCR) and NGS were performed on plasma samples. The association between genetic alterations and

clinical outcomes was analyzed retrospectively.

Results: Thirty-seven patients were included. The success rate of re-biopsy was 91.89% (34/37). The total detection rate of EGFR T790M was 62.16% (23/37) and the consistency between tissue and ctDNA was 78.26% (18/23). Thirty-four patients were analyzed retrospectively. Twenty-four patients harbored concomitant mutations. Moreover, tissue re-biopsy at resistance showed 21 patients (21/34, 61.76%) had concomitant T790M mutation, 4 with MET amplification and 4 with PIK3CA mutation. Patients with T790M mutation (p=0.010 & p=0.017) or third-generation EGFR-TKI treatment (p<0.0001 & p=0.073) showed better progression-free survival (PFS) and overall survival (OS). Interestingly, concomitant genetic alterations were significantly associated with a worse prognosis for patients with T790M mutation receiving third- generation EGFR-TKIs (p=0.037).

Conclusion: In conclusion, using multi-platforms to perform detection of EGFR T790M mutation on EGFR-TKI resistant re-biopsy tissues and blood samples is feasible, and the consistency of tissue and blood detection mutation is high which provide complementary results. And concomitant genetic alterations may affect response to treatment and decision of sequential therapy strategy.

OR-028

Uniportal total pleural covering with absorbable cellulose mesh for secondary pneumothorax in three patients with Birt-Hogg-Dubé syndrome or lymphangioleiomyomatosis

Mizobuchi,Teruaki、Nagato,Kaoru、Ishibashi,Fumihiro
Social Welfare Organization Saiseikai Imperial Gift Foundation， Chibaken Saiseikai Narashino Hospital

Objective: Spontaneous pneumothorax is a major and frequently recurrent complication of lymphangioleiomyomatosis (LAM) or Birt-Hogg-Dubé syndrome (BHDS), because of wide-spread multiple lung cysts, which cannot all be removed surgically. Recently, total pleural covering (TPC) via 4-port video-assisted thoracic surgery (4P-VATS) was reported as a new surgical procedure, which covers the entire surface of the lungs with sheets of absorbable cellulose mesh (ACM), which successfully reduced recurrence of postoperative pneumothorax both in LAM or BHDS patients. Thanks to the advancement of uniportal video-assisted thoracic surgery (U-VATS) techniques and instruments in recent years, U-VATS TPC has become feasible.

Methods: Case 1: A 40-year-old woman suffering from multiple lung cysts followed by secondary pneumothorax of the left, underwent U-VATS TPC. The pathological finding showed LAM nodules, resulting in a diagnosis of LAM. Case 2: A 45-year-old woman suffering from numerous lung cysts and bilateral pneumothorax, underwent 4P-VATS TPC of the right 3 years ago and U-VATS TPC of the left this time. She was diagnosed as BHDS according to modified Menko’s criteria for BHDS. Case 3: A 40-year-old man suffering from bilateral multiple lung cysts followed by secondary pneumothorax of the right, underwent U-VATS TPC. He was diagnosed as BHDS similarly.

Results: Postoperative courses of all the three were excellent without significant postoperative complications (≥ grade 3) or ipsilateral recurrence of pneumothorax during the median follow-up period of 152 (8-186) days.

Conclusion: U-VATS TPC may become a good surgical candidate for intractable pneumothorax in patients with BHDS or LAM.

OR-029

Endobronchial Zephyr Valves : 1st multicenter Retrospective study on the 2 step approach

EGENOD,Thomas1、GUIBERT,Nicolas2、AMAR,Yoann3、KESSLER,Romain4、TOUBLANC,Benedicte5、FAVROLT,Nicolas6、BRIAULT,Amandine 7、DUTAU,Herv é 8、WALLYN,Benoit9、VERGNON,Jean-Michel10、DUSSELIER,Matthieu1

1. Dupuytren University Hospital, Limoges
2. Toulouse University Hospital
3. Saint Joseph Clinic, Marseille
4. Strasbourg University Hospital
5. Amiens, University Hospital
6. Dijon University Hospital
7. Grenoble University Hospital
8. Marseille University Hospital
9. Lille University Hospital
10. Saint Etienne University Hospital

Objective: To assess whether the placement of Zephyr endobronchial valves throughout 2 procedures instead of 1 minor the frequency of pneumothorax without lowering the benefits of such treatment.

Methods: This retrospective study was conducted in 15 pulmonology department in France. All the patients met the inclusion criteria of the recommendation set by the expert panel on the Endoscopic Lung Volume Reduction (ELVR) updated in 2019. As recommended, all the scan were analyzed with the StratX© (PulmonX Corporation, Redwood city, CA) protocol, and completed by a Chartis© (PulmonX Corporation, Redwood city, CA) in case of questionable fissure. During the first procedure, all but the most proximal sub-segment of the targeted lobe were occluded. One month after, EBV were placed in the bronchus of the last subsegment. All patients were evaluated before and 3 months after the second procedure.

Results: Between March 2018 and December 2019, 95 patients received EBV treatment. 12 patients (12.5%) presented a pneumothorax (3 after the 1st step and 9 after the 2nd procedure). Beside pneumothorax, the main adverse event were exacerbation (21%) and pneumonia (5%). No death were reported. Significant improvement were found for Forced Expiratory Volume in 1 second (14.6 ± 25.3%), Residual Volume (- 0.69 ± 2.1L), 6 Minute Walk Test (34.8 ± 45.9m), BODE Score (-1.41 ± 1.41pts), and modified Medical Research Council dyspnea scale (-0.85 ± 0.7pts).Our results are similar to the ones previously published with the usual 1 time procedure (Table 1). Some patients seemed to improve their lung capacity after the first procedure.

Conclusion: Placing EBV during 2 procedures instead of one led to a significant decrease of post treatment pneumothoraces without increasing the rate of other complications. It does not seem to alter the benefits of such therapy for severe emphysema. These results must be confirmed by a multicenter, prospective, randomized, controlled study.

OR-030

Insertion and fixation of gold markers using disposable insertion system for real-time tumor-tracking proton therapy against lung cancer

Takashima,Yuta1、Shinagawa,Naofumi1、Kunisaki,Mamoru1、Mizugaki,Hidenori 1、Asahina,Hajime 1、Kikuchi,Eiki1、Kikuchi,Junko 1、Sakakibara-Konishi,Jun 1、Katoh,Norio2、Taguchi,Hiroshi2、Aoyama,Hidefumi 2、Konno,Satoshi1
1. First Department of Medicine, Hokkaido University Hospital, Sapporo, Japan
2. Department of Radiation Oncology, Faculty of Medicine, Hokkaido University, Sapporo, Japan

Objective: We have previously shown efficacy of real-time tumor-tracking radiotherapy (RTRT) using disposable gold marker insertion system for patients with peripheral non-small cell lung cancer. In our institution, we have initiated proton therapy against lung cancer since 2015 and also have performed insertion and fixation of gold markers for real-time tumor-tracking proton therapy. Although the duration of proton therapy is longer than that of radiotherapy, the fixation rate of gold markers in proton therapy is as yet unclear. In this study, we retrospectively analyzed the fixation rate of gold markers for proton therapy.

Methods: Between January 2015 to December 2019, gold markers were inserted into 13 patients with lung cancer using disposable insertion system (FMR-201CR, Olympus) for proton therapy. We attempted to insert 4 gold markers into each person. We analyzed the fixation rate of gold markers by Chest X-ray film. The distance between gold markers and chest wall were measured on computed tomography (CT) images retrospectively.

Results: The average size of the lesions was 28.5±10.5 (mean ± SD) mm. Of 13 lesions, 4 were in right upper lobe, 1 was in right middle lobe, 3 were in right lower lobe, 5 were in left upper lobe. In 51 inserted gold markers, 40 (78%) were fixed throughout the treatment period. The fixation rates of markers were 87% (13/15) in right upper lobe, 83% (5/6) in right middle lobe, 70% (7/10) in right lower lobe, 75% (15/20) in left upper lobe. The distance between the dropped-out markers and chest wall was longer than that of the fixed markers (13.7mm vs. 9.8mm), although the difference was not statistically significant (P=0.07). All the patients tolerated this procedure without any serious complications. Real-time tracking of the markers for proton therapy was successfully performed in all cases.

Conclusion: We have safely performed insertion and fixation of gold markers for real-time tumor-tracking proton therapy against lung cancer.

OR-031

Prospective Evaluation of additional EUS-B of the Left Adrenal Gland to Routine Lung Cancer Staging

Darwiche,Kaid1、Becker,Jonathan1、Hautzel,Hubertus1、Hager,Thomas2、Stenzel,Elena3、Winantea,Jane1、Karpf-Wissel,R ü diger1、Funke,Faustina1、Hibare,Kedar4,1、Eisenmann,Stephan5,1
1. Ruhrlandklinik – University Medicine Essen, Germany
2. Institute of Pathology – University Medicine Essen, Germany
3. Department of Diagnostic and Interventional Radiology and Neuroradiology – University Medicine Essen, Germany
4. Narayana Health City – Mazumdar Shaw Medical Center, Bangalore, India
5. Department of Pneumology, University Hospital of Martin Luther University, Halle (Saale), Germany

Objective: Endobronchial ultrasound with transbronchial needle aspiration (EBUS-TBNA) increases the diagnostic yield of lung cancer staging. The left adrenal gland is a common site for lung cancer metastasis. The modality of transesophageal examination with an EBUS bronchoscope (EUS-B) routinely for left adrenal gland has not been assessed. The aim of this study is to prospectively assess the impact of evaluation with EUS-B and if necessary tissue sampling of the left adrenal gland to an EBUS-procedure.

Methods: Patients referred for EBUS between March and August 2017 had assessment of the left adrenal gland via EUS-B. Fine- needle aspiration (FNA) was performed in cases with a suspicious left adrenal gland. Detection rate, procedure time, and the learning curve of four experienced EBUS-bronchoscopists was assessed, plus diagnostic accuracy and complication rate of FNA.

Results: 313 consecutive patients were included. The overall left adrenal gland detection rate was 87.5%. After the initial learning curve, the detection rate for all four bronchoscopists was >93%. The detection rate did not correlate with any patient characteristics. EUS-B-FNA revealed nine left adrenal gland metastases, with sensitivity, specificity and accuracy of 75%, 100%, and 99%, respectively. Mean EUS-B operation time was 194.4 sec, with 594.8 sec for FNA. Mean operation time for combined EBUS/EUS-B was 25 min 51 sec. The mean number of needle passes through the left adrenal gland was 3.3. There were no FNA-associated complications. In one case, transient mediastinal emphysema was noted after failed intubation of the upper esophagus, which resolved spontaneously and did not prolong hospital stay.

Conclusion: Evaluation of the left adrenal gland with EUS-B could routinely be included in an EBUS procedure if necessary. A high detection rate can be achieved after an initial learning period. FNA of the left adrenal gland was feasible and safe. EUS-B of the left adrenal gland could be integrated into the usual EBUS/EUS-B procedure in lung cancer staging workup.

OR-032

Bronchoscopic Lung Volume Reduction with Zephyr Endobronchial Valves Positively Impacts Patient Quality of Life

Dransfield,Mark1、Bhatt,Surya1、Slebos,Dirk-Jan 2、Klooster,Karin 2、Sciurba,Frank 3、Shah,Pallav 4、Garner,Justin 4、Radhakrishnan,Sri5、Shargill,Narinder5、Marchetti,Nathaniel6、Criner,Gerard6

1. University of Alabama at Birmingham
2. University of Groningen
3. University of Pittsburgh
4. Royal Brompton Hospital and Imperial College
5. Pulmonx Corporation
6. Temple University

Objective: Background: In carefully selected hyperinflated severe emphysema patients, Bronchoscopic Lung Volume Reduction (BLVR) with the Zephyr® Valve improves lung function, exercise tolerance and overall quality of life. Post-hoc analyses were conducted to evaluate the impact of BLVR on patient reported outcomes (PROs) including multidimensional measures of dyspnea and quality of life in patients enrolled in the LIBERATE Study.

Methods : The study cohort comprised of 190 severe heterogeneous emphysema patients (2:1 randomization (Zephyr Valve to Standard of Care (SoC)) with little to no collateral ventilation (CV) in the lobe targeted for treatment. Fifty-three percent (53%) of the cohort was female. Mean clinical characteristics at baseline were forced expiratory volume (FEV1) 27.4% predicted; Residual Volume (RV) 225% predicted; St George's Respiratory Questionnaire (SGRQ) score 54.49 points and COPD Assessment Test (CAT) score 19.2 points. Changes from baseline to 12 months for the Zephyr Valve and SoC groups were compared for the total score and individual domain scores of the SGRQ, total score and individual questions of the CAT and the Focal and individual component scores of the Transitional Dyspnea Index (TDI). The responder rate for the modified Medical Research Council Dyspnea Scale (mMRC) based on a ≥1 point improvement was assessed.

Results: All three patient reported outcomes showed clinically meaningful and statistically significant improvements in Zephyr Valve patients compared to SoC patients. The difference between the Zephyr Valve and SoC groups for the changes from Baseline to 12 months were -7.05 points for SGRQ, -3.1 points for CAT, and +4.3 points for TDI Focal score. For the SGRQ improvement, the "Impacts" and "Activity" domains were the main contributors ($p=0.004$, and $p<0.001$, respectively). Improvements in CAT were driven by improvements in breathlessness ($p=0.002$), chest tightness ($p=0.029$), energy level ($p=0.014$), activities ($p<0.001$) and more confidence when leaving home ($p=0.024$). All three TDI measures of "Effort", "Task" and "Functional impairment" were improved ($p<0.001$). a higher proportion of Zephyr Valve patients had an improvement of ≥1 point in the mMRC Dyspnea Scale compared to the SoC group ($P<0.001$).

Conclusion: Data from the LIBERATE study demonstrates that the Zephyr Valve significantly improves multidimensional measures of dyspnea and quality of life, enabling patients to have increased energy level and an ability to be more active.

OR-033

Inhibitory effect of external radiotherapy on granulation tissue proliferation after stenting in rabbit model of benign tracheal stenosis

Li,Zongming、Zhang,Quanhui、Han,Xinwei、Jiao,Dechao、Ren,Kewei、Lu,Huibin
The First Affiliated Hospital of Zhengzhou University

Objective: To explore the effectiveness of external radiotherapy in inhibiting the proliferation of granulation tissue after stent implantation in rabbit model of benign tracheal stenosis.

Methods: Thirty-two New Zealand big ear rabbits aged 4 months, weighing 2.5-3 kg, were used to establish animal models of benign tracheal stenosis by tracheotomy combined with nylon brush scraping. The bare nickel-titanium alloy stent was implanted under fluoroscopy, and then was randomly divided into 20Gy group, 30Gy group, 40Gy group and control group, with 8 in each group. In the 20Gy group, the fractionated dose was 7Gy/d for 2 times; in the 30Gy group, the fractionated dose was 7Gy/d for 3 times; and in the 40Gy group, the fractionated dose was 8Gy/d for 3 times, with an interval of 5 days. Four rats in each group were executed at 4 and 8 weeks after irradiation, and chest CT scan was performed before execution to record the degree of tracheal stenosis.

Results: Thirty stenosis models survived after 4 weeks, one died of infection, and one died of respiratory failure caused by tracheal mucosal edema. Two more were successful. The stenosis rate ranged from 42% to 85%. After 4 weeks and 8 weeks of irradiation, the average tracheal stenosis rates in 20Gy group were (46.7±4.8)% and (52.9±3.6)%, in 30Gy group were (36.2±4.7)% and (39.8±4.5)%, in 40Gy group, the average tracheal stenosis rates were (31.9±5.7)% and (34.8±5.2)%, respectively. The average tracheal stenosis rate in the control group was (65.5±2.6)% and (80.7±3.8)% after 4 and 8 weeks of tracheal stent implantation. There were significant differences between the three experimental groups and the control group ($p < 0.05$); The degree of tracheal stenosis in 20Gy group was significantly different from that in 30Gy group and 40Gy group ($p < 0.05$); there was no significant difference in the degree of tracheal stenosis between 30Gy group and 40Gy group ($p > 0.05$). One rabbit in the 40Gy group died after in vitro irradiation.

Conclusion: External radiation therapy can effectively inhibit the proliferation of mucosal granulation tissue after airway stent implantation, and the 30Gy fractional irradiation scheme is recommended.

OR-034

Evaluation of Postoperative Bronchitis with Linked Color Imaging

Yamamoto,Shinichi、Negishi,Hideki、Shibano,Tomoki、Yamana,Hikaru、Ozeki,Masaki、Mitsuda,Sayaka、Kanai,Yoshihiko、Otani,Shinichi、Endo,Shunsuke
Jichi Medical University

Objective: Postoperative bronchitis sometimes occurs after anatomical lung resection with lymph node dissection such as pneumonectomy, lobectomy and segmentectomy. Reddish change, edema and ulcerative change of the bronchial epithelium are sometimes observed in the postoperative bronchi and in some cases there are severe complications such as bronchopleural fistula. Early detection of postoperative bronchitis is needed to prevent life-threatening complications.

Linked color imaging (LCI), which is a novel image-enhanced endoscopy technology by simultaneously using narrow-band short wavelength light and white light in an appropriate balance, can enhance the difference of the hue in endoscopic images. The bright images of LCI can be maintained because of the availability of white light imaging (WLI) plus narrow band wavelength light. This unique image processing can make the red region more red and the white region whiter. Epithelial and subepithelial color changes are enhanced with LCI so that epithelial inflammatory lesions and vascularity of epithelium are more easily detected.

The purpose of this study is to evaluate the grade of postoperative bronchitis and to clarify the difference between LCI findings of bronchial stumps and WLI findings.

Methods: Four hundred seventy-six patients underwent bronchoscopy after anatomical lung resection such as pneumonectomy, lobectomy and segmentectomy for lung cancer from January 2018 to November 2019 at our institution. Systematic bronchoscopy was performed around postoperative day 7. The degree of inflammatory changes was classified into 5 grades depending on the redness, edema and ulceration of bronchial epithelium with WLI and LCI, respectively. Repeated bronchoscopy was performed in cases of severe postoperative bronchitis such as edema and ulceration on the bronchial epithelium, especially the bronchial stump until bronchitis was cured.

Results: The number of patients greater than or equal to grade 2 with LCI was larger than with WLI. The extent of inflammatory change was clearly detected with LCI compared with WLI. Thirty cases out of 476 had ulcerative change of the bronchial epithelium around the bronchial stumps. The vasculatures of the bronchial epithelium tended to be unclear as the inflammatory changes became severe. Follow-up LCI revealed more bronchial vascularity than WLI.

Conclusion: LCI is more sensitive than WLI for detecting inflammatory changes and evaluating the healing process of the bronchial epithelium regarding postoperative bronchitis.

OR-035

Convex probe EBUS bronchoscopy guided placement of fiducial marker in oligo-metastatic mediastinal lymph nodes for CyberKnife stereotactic body radiotherapy - Safety and feasibility

Ramarmuty,Hema1,2、Yagnik,Lokesh1、Sidhu,Calvin1、Morey,Sue1,3、Philips,Martin1、Thomas,Rajesh1,3,4
1. Sir Charles Gairdner Hospital
2. Queen Elizabeth Hospital, Sabah, Malaysia
3. Institute for Respiratory Health, Perth, Australia
4. University of Western Australia, Perth, Australia

Objective: To describe the safety and feasibility of placing FM in mediastinal and hilar lymph nodes using a modified real-time CP-EBUS bronchoscopy technique.

Methods: A retrospective reviewwas performed of all patients who underwent CP-EBUS guided placement of FM in thoracic lymph nodes for CyberKnife SBRT at Sir Charles Gairdner Hospital, Perth (2014-2019). Demographics, tumour aetiology, tumour/node location, outcomes and adverse effects were recorded. A 4x0.035mm straight gold FM, front-loaded into a standard 21G TBNA needle, was inserted into the target lesion under real-time EBUS guidance.

Results: 10 patients(females 6; age 58 years [IQR 41-78])underwent CP-EBUS guided FM placement in 13 central nodes (4R - 7; 10R - 2; 11R - 2; 7 - 1; 2R - 1). Colorectal carcinoma (n=6) and renal cell carcinoma (n=3) were the most common primary malignancy. Two FMs were placed in the target node in four cases; in the remaining nine cases, one FM was placed in target node. One patient had three separate FM placement procedures for three malignant nodes over a four-year period. In another patient, FM was inserted in two separate nodes during a single bronchoscopy sitting.Post-insertion, the FM was displaced in two patients before commencement of CyberKnife SBRT; In one patient, it was successfully replaced by repeating the procedure. No other immediate or late local/systemic complication was recorded. CyberKnife SBRT planning/treatment was successfully completed for 12/13 malignant nodes.

Conclusion: CP-EBUS bronchoscopy guided FM placement in oligo-metastatic mediastinal lymph nodes for CyberKnife SBRT is safe and feasible

OR-036

Study on selecting metallic stents of different sizes and related complications

Li,Xiaoxiao、Jiang,Junhong
The First Affiliated Hospital of Soochow University

Objective: In this study, 6 mm*30 mm tracheal stents ((ratio of stent to trachea 0.95-1.06:1) and 8 mm*30 mm tracheal stents (ratio of stent to trachea 1.27-1.42:1) produced by Micro—Tech，Nanjing were placed in the animal model of tracheal stenosis, and the changes of complications with time were observed. This provides a theoretical basis for clinical selection of appropriate diameter of tracheal stents.

Methods: Forty-five 4-month-old healthy New Zealand white rabbits were used to form airway stenosis of more than 50%. The rabbits were randomly divided into two groups: Group A (n = 21) implanted with 6 mm*30 mm tracheal stents, Group B (n = 24) implanted with 8 mm*30 mm tracheal stents. Granulation hyperplasia and sputum retention were observed under bronchoscope at 2,4,8 and 12 weeks. Three rabbits were sacrificed every two weeks to observe the

thickening of tracheal wall, mucosa and restenosis at both ends of the stents. After 12 weeks, all rabbits were sacrificed and all specimens were reserved for subsequent pathology and detection of inflammatory factors.

Results: 1. A small amount of granulation was observed inside the stents and at both ends of the stents at 2 weeks, which did not cause luminal stenosis. At the 4th week, the granulation was further proliferated, and the scar contracture at both ends of the stents began to appear in group B. At the 8th week, the granulation was lighter than before. Epithelialization began to occur in both groups. The scar contracture at both ends of the stents were further aggravated in group B. The scar contracture and granulation existed at the same time. There was no obvious scar contracture at both ends in group A. At 12 weeks, complete epithelialization was observed in both stents, and scar contracture at both ends was further aggravated in group B. 2. Within 12 weeks after stent indwelling, the incidence of tracheal deformation and scar contracture at both ends of 8 mm stent (45.8%) was significantly higher than that of 6 mm stent (9.5%), with P value of 0.019. The incidence of granulation hyperplasia of 8 mm stent (75.0%) was also higher than that of 6 mm stent (52.4%), and the incidence of stenosis greater than 50% (61.1%) was higher than that of 6 mm stent (45.5%).

Conclusion: The diameter of the stent was selected according to CT. The diameter of the stent close to the physiological diameter can reduce the stent related complications.

OR-037

Contributive changes of pulmonary biopsy by crioprobe in patients with acute respiratory insufficiency

Las Heras,Marcos、Carboni Bisso,Indalecio、Videla,Carlos、San Rom á n,Eduardo
Hospital Italiano de Buenos Aires

Objective: Investigate the impact and safety of pulmonary biopsy by cryoprobe in patients with acute respiratory insufficiency in which a previous broncoalveolar cleansing was performed with a negative result. In addition to that, the purpose of this study is to establish the proportion of safety and complications of this technique.

Methods: Retrospective study. Electronic clinic histories of patients with acute respiratory insufficiency were evaluated. In all of them a pulmonary biopsy with criprobe was performed at Hospital Italiano de Buenos Aires between the month of may of 2016 and july of 2019.

Results: Pulmonary biopsies by cryoprobe were performed in 15 patients. 53.3% were male with an average age of 54 ± 21, APACHE II average 17. All biopsies were performed with cryoprobe of 1.9 mm with flexible bronchoscopes. All patients had etiologic diagnosis, being the most frequent alveolar diffuse damage in 46.6% (7) of the cases, infection in 26.6% (4), drug toxicity 13.3% (2), rejection 6.6% (1) and cancer in 6.6% (1).

An average of 4 biopsies per patient were taken in a procedure of 40 minute long. All biopsies were performed in the intensive care unit, trying to avoid patient transfer and potential complications. Most frequent complications include bleeding in 86.6% of the cases; 69% of which was considered type I bleeding (no intervention required) and 30.7% type II (required endoscopic maneuvers). 40% of the patients presented transitory hypoxemia during procedure. One patient with previous cavitated injuries presented pneumotorax and required drainage. 80% of the patients changed established treatment due to the pulmonary biopsy.

Conclusion: Surgical pulmonary biopsy improves diagnosis and treatment in patients with acute respiratory insufficiency. However, it has been relegated due to its complications and complexity. The advent of new techniques such as pulmonary biopsy by cryoprobe applied to a definite group of patients opens a promising landscape with less proportion of pneumothorax and bleeding, improving results. Further studies are needed to better know the safety of this technique and its consequences in such a definite population.

OR-038

Clinical analysis of 9 cases of lung cancer with mediastinal lymph node metastasis treated by the implantation of 125I seeds by EBUS-TBNA technique

Wu,Kai、Jiang,Junhong
The First Affiliated Hospital of Soochow University

Objective: To investigate the clinical efficacy and feasibility of the implantation of 125I seeds by EBUS-TBNA technique in the treatment of mediastinal lymph node metastasis of lung cancer.

Methods: A retrospective analysis of clinical data and survival of 9 patients with mediastinal lymph node metastasis of lung cancer treated with the implantation of radioactive seeds in the Department of Respiratory Medicine of the First Affiliated Hospital of Soochow University from March 2015 to January 2019.

Results: All 9 IV stage lung cancer patients ,including 6 cases of adenocarcinoma and 3 cases of squamous cell carcinoma; 8 cases progressed after third-line treatment, and 1 case of 85-year-old patient progressed after first-line treatment, including 7 males and 2 females, aged 65-85 years. 1 operated under laryngeal mask anesthesia, 8 cases operated under local anesthesia, 9 cases of mediastinal lymph node seeds implantation were guided by EBUS, of which 2 cases were combined with fluoroscope, used COOK319 puncture needle, 125I seed activity was selected to be 0.5 mCi, TPS planning was performed routinely before surgery, and the number of seeds that may need to be implanted was estimated. The implantation sites included right anterior tracheal lymph node in 3 cases, left anterior tracheal lymph node in 1 case, subcarinal lymph node in 4 cases, and left main bronchus lymph node in 1 case. The total number of implanted particles was 6-21, with the preoperative planned anastomosis rate of 24.5%. The local effective rate was 6/8 (75%) in 1 month after treatment, which was invalid in 2 cases and failed in 1 case. After implantation, dysphagia was significantly relieved in 3 cases. PFS was 3.8 months (1-6 months) after implantation. There was no significant complication during operation. One case showed interstitial pneumonia 2 months after implantation, which was effective after hormone therapy.

Conclusion: Radioactive 125I seeds implanted into mediastinal lymph nodes by EBUS-TBNA technique is feasible, and combined with fluoroscope is more conducive to reasonable particle placement. This technique is effective and safe in the treatment of mediastinal lymph node metastasis of lung cancer.

OR-039

Clinical effectiveness and safety of Analgosedation in flexible fiberoptic bronchoscopy

Park,SeungYong、Lee,HeungBum
Chonbuk National University Hospital

Objective: Limited data are available regarding the efficacy and safety of remifentanil sedation for diagnostic bronchoscopy. The aim of this study was to evaluate clinical efficacy and safety of remifentanil by comparing it with the conventional drugs with midazolam and propofol.

Methods: A retrospective study of 186 patients who underwent diagnostic bronchoscopy at Chonbuk national university hospital was performed. Patients were classified into remifentanil group and midazolam and propofol group according to the drugs used during bronchoscopy.

Results: Of the 186 patients, 111 patients received remifentanil and 75 received midazolam and propofol. The proportion of patients who needed only endobronchial inspection was significantly higher in midazolam and propofol group than in remifentanil group (93.3% vs. 71.2%; $P < 0.001$). In contrast, the proportion of patients who needed more invasive precedures such as bronchoscopic biopsy, bronchoalveolar lavage, or transbronchial lung biopsy was significantly higher in remifentanil group than in midazolam and propofol group (27.8% vs. 6.7%; $P < 0.001$). There was no significant difference in the occurrence of safety events such as desaturation, hypotension, and arrhythmia between the two groups. The recovery time was significantly shorter in remifentanil group than in midazolam and propofol group (mean 6.4 min vs. 11.6 min, $P < 0.001$).

Conclusion: Despite higher proportion of patients who underwent more invasive procedures in remifentanil group than in midazolam and propofol group, there was no significant difference in the occurrence of safety events with faster recovery time in remifentanil group.

OR-040

Study on the application of nasal probe test in flexible bronchoscopy under topical anesthesia

Zhu,Wenjun、Luo,Fengming
West China Hospital， Sichuan University

Objective: The goal of this study was to explore whether nasal probe test in flexible bronchoscopy can optimize the operation process, improve comfort and reduce complications.

Methods: From June 2018 to march 2019, 300 patients requiring diagnostic bronchoscopy from West China Hospital of Sichuan University were randomly divided into cotton swabs+normal saline group，cotton swabs+adrenaline+lidocaine group and control group according to random number table.The patients of cotton swabs+normal saline group and cotton swabs+adrenaline+lidocaine group were given disposable sterile medical cotton swabs soaked in normal saline and disposable sterile medical cotton swabs soaked in 1‰ adrenaline and 2% lidocaine to probe the nasal cavity before the flexible bronchoscopy procedure, while the patients of control group were given the routine nursing without other intervention measures. Primary endpoints were nasal cavity-glottis time and the number of operations required for success. Secondary endpoints included insertion nasal meatus and nasal cavity, bleeding at the insertion site, whether to use hemostatic. A100-point VAS questionnaire were used to determine

pain,foreign body sensation and comfort degree toward flexible bronchoscopy. At the same time, a 5-point VAS questionnaire was used to assess the smoothness of the operation of the flexible bronchoscopy.

Results: three hundred patients were included in the study (n = 100 in each group). Patients required shorter nasal cavity-glottis time (cotton swabs+normal saline group:1.3116±0.299,cotton swabs+adrenaline+lidocaine group:1.2551±0.2773 versus control group :1.4035±0.3263,p=0.002) and fewer numbers of operations required for success (X2values:18.207,p<0.001) when given nasal probe test. what's more, the safety of cotton swabs+adrenaline+lidocaine group is superior to cotton swabs+normal saline group and control group in flexible bronchoscopy under local anesthesia, especially in reducing nasal bleeding (X2values7.792, p=0.005; X2values11.060, p=0.001). Whereas no differences in the tolerance and smoothness scores were observed among the three groups (all p > 0.05).

Conclusion: flexible bronchoscopy via nasal probe test was superior security under topical anesthesia and was associated with reduced nasal cavity-glottis time, better success rate during the procedure compared to conventional nasal bronchoscopy without nasal probe test.

OR-041

Efficacy and influence factors of interventional bronchoscopy for the treatment of scarring airway stenosis

Wang,Ting、Zhang,Jie、Qiu,Xiaojian、Wang,Juan、Pei,Yinghua、Wang,Yuling
Beijing Tian Tan Hospital, Capital Medical University

Objective: Although an effective therapeutic modality for scarring airway stenosis, the efficacy of interventional bronchoscopy differs among different studies. Factors associated with the achievement of clinical success and the variables associated with airway restenosis are not clearly understood.

Methods: 301 scarring airway stenosis patients from 18 tertiary hospitals, who were treated by interventional bronchoscopy were reviewed retrospectively. Airway stenosis characteristics, patients' performance status at baseline and after interventional bronchoscopy and interval days between the first two interventional bronchoscopy treatment (maintained patency time) were recorded. Factors that influence the efficacy of interventional bronchoscopy and maintain patency time were evaluated.

Results: Stenosis sites (P=0.032), dyspnea index (P < 0.001), and interventional method (P=0.005) were independent predictors associated with the efficacy of interventional bronchoscopy treatment. Stenosis sites (P < 0.001), stenosis grade (P=0.001), anesthesia method (P < 0.001), and local drug usage (P < 0.001) were independent predictors associated with the maintained patency time after first interventional bronchoscopy treatment.

Conclusion: Attention should be paid to factors that influence treatment efficacy and durable outcomes, following interventional bronchoscopy. These factors may help assist the clinician in patient selection, methods of intervention and follow up timeframes.

OR-042

Proteomic profiling of Biomarkers by MALDI-TOF Mass Spectrometry for Diagnosis of Tracheobronchial Stenosis after Endobronchial Tuberculosis

Qiu,Xiaojian、Zhang,Jie
Department of Pulmonary Diseases, Beijing Tian Tan Hospital

Objective: Endobronchial tuberculosis leads to airway stenosis, irreversible airway damage, and even death of the sufferers. This study aimed to identify biomarkers for the diagnosis of tracheobronchial stenosis (TBS) secondary to endobronchial tuberculosis.

Methods: A cohort of patients was recruited, including patients with TBS after endobronchial tuberculosis, early-stage lung cancer (ESLC), and healthy controls subjected to tracheal intubation and tracheotomy (TIT). Proteomic profiling was conducted to gain insights into the mechanisms of the pathological processes. Differentially expressed proteins in the serum and bronchial alveolar lavage fluid (BALF) from the TBS patients were detected by MALDI-TOF MS assay. Subsequently, ELISA test was performed to validate the changes of protein levels.

Results: MALDI-TOF MS revealed that Eight peptides, including MYADM, KRT18, FGA, AGT, APOAI, CLU and two uncharacterized peptides in serum, and nine peptides, including ASL, APOAI, AGT and five uncharacterized peptides in BALF were differentially expressed (MW range of 1000 – 10,000 Da) in the TBS group compared with TIT group. The results of ELISA assay showed that they had the similar changing trend as that in the proteomic profiling.

Conclusion: We identified proteins that may provide potential biomarkers and give new insights into the molecular mechanisms underlying TBS after endobronchial tuberculosis.

OR-043

Bronchoscopic Treatment of Tracheobronchial Fistula after Thoracic Surgery with Autologous Platelet-Rich Plasma

Wu,Meirong1,2、Lin,Huihuang1,2、Shi,Liyong1,2、Huang,Linlin1,2、Zhuang,Yawen1,2、Zeng,Yiming1,2
1. Second Affiliated Hospital of Fujian Medical University
2. Respiratory Medicine Center of Fujian Province

Objective: Tracheobronchial fistula is a challenging management condition. Several bronchoscopic procedures have been tried for fistula closure. Autologous platelet-rich plasma (auto-PRP), which is readily available in clinical practice, has been demonstrated effective in promoting wound healing. In this research, we submucosally inject auto-PRP around the fistula to close the tracheobronchial fistula.

Methods: Auto-PRP was obtained after performing double centrifugation of blood by the Landesberg method. After anesthesia, the bronchoscope was introduced into the trachea. Auto-PRP (1.5-4 ml; platelets/ml: 1.530 ± 0.591 × 106 /ml, mean ± SD) was injected into the submucosa around the fistula. The first three injections were designated to perform every 4-7 days, and the subsequent injections were based on the patients' condition. Patients who are defined as cure should first fully compatible with the following criteria: ① without clinical symptoms of TBF; ② no air or fluid leak via the chest tube; ③ a significant volume reduction of the cavity under CT scan. Then the cure could be further categorized into bronchoscopic cure and clinical cure. Bronchoscopic cure refers to completely fistula closure under bronchoscope while clinical cure refers to significant fistula contraction under bronchoscope.

Results: We report three cases of TBF treated with auto-PRP. Patients' data were illustrated in Table 1. After

auto-PRP treatment, all three patients were successfully treated including two bronchoscopic cures and one clinical cure. No treatment-related complications and fistula-related symptoms were detected. Case 1 received two auto-PRP injections and a membranous covered stent was placed in the trachea during the second treatment. Seventeen weeks later, the defect completely healed. The stent was removed and the patient was extubated. Case 2 underwent six times of auto-PRP injections and the fistula was completely closed. The entire treatment lasted fifteen weeks. A chest tube was inserted in case 3 and air leakage was found. After four times of auto-PRP injections, the fistula was almost closed under bronchoscopy, and there was no air leak or effusion observed. The patient was judged as clinical cure and the chest tube was successfully removed.

Conclusion: This is the first-in-human successful application of auto-PRP for fistula closure, which may offer a valuable therapeutic alternative. More studies about the role of auto-PRP in the treatment of the fistulas are needed.

OR-044

3D-engineered personalized airway stent (“custom GINA stent”): introduction and evaluation in a pig model of tracheal stenosis

Lee,Taehoon1、Lim,Soyeoun2、Ahn,Jong Joon1、Jegal,Yangjin1、Seo,Kwang Won1、Ra,Seung Won1、Pak,Chuiyong1、Bae,Soohyun1、Kim,Don Han3、Yoon,Ho Il4、Kim,Jin Hyoung1
1. Department of Internal Medicine, Ulsan University Hospital, University of Ulsan College of Medicine
2. Department of Radiology, Ulsan University Hospital, University of Ulsan College of Medicine
3. Department of Digital Contents Design, University of Ulsan College of Design and Architecture, Ulsan, Korea
4. Department of Internal Medicine, Seoul National University Bundang Hospital, Seoul National University College of Medicine, Seongnam, Korea

Objective: Bronchoscopic treatments of airway stenosis have been evolving. We formerly reported the new silicone airway stent (GINA stent). GINA stent has anti-migration designs, smooth ends for minimalizing granulation tissue, and radioopaqueness. We herein report “custom GINA stent”, which is a 3D-engineered personalized airway silicone stent made with GINA stent as a backbone. Objectives of the present study are to introduce the production process of custom GINA stent, and to know its feasibility by evaluating short term (3 weeks) performance in a pig model of tracheal stenosis.

Methods: Two female farm pigs (12 weeks old, 40-45kg, 16-20mm of tracheal size) were used. Baseline CT scan was done for stent production, then tracheal stenosis was induced by electrocautery. Using 3D-engineering technology, the mold of stent was fabricated, and the stent was made by injection molding method. When the stent was manufactured, it was inserted through a rigid bronchoscope under general anesthesia. Short term (3 weeks) stent performance was evaluated in terms of migration, granulation (at both ends), and mucostasis.

Results: In the first pig, it took 16 days to manufacture the custom GINA stent. In the second pig, the production time was reduced to 7 days. For short term (3 weeks) performance of custom GINA stent, no migration, granulation (at both ends), or mucostasis was occurred in all 2 pigs.

Conclusion: In the present study, we developed a personalized airway stent (custom GINA stent) using 3D-engineering within 7 days. In terms of stent performance, it showed perfect results for a short period (3 weeks) in a pig model. Our results should also be demonstrated in clinical trials in humans. *This abstract was presented at domestic conference in South Korea (on 8-NOV-2019).

OR-045

β - Elemene regulate the function of human airway granulation fibroblasts via the MIR143HG/ miR-1275 /ILK axis: new drug,new target

Zhang,Guoying、Xue,Cheng、Hong,Lingling、Zhu,Zhixing、Lin,Lianshun、Zheng,Yiming
Second Affiliated Hospital of Fujian Medical University， Respiratory Medicine Center of Fujian Province

Objective: To investigate the effects of β - elemene on proliferation, migration and phenotypic Transition of human airway granulation fibroblasts and its underlying molecular mechanism,sequentially to find molecular targets for drug therapy of benign airway stenosis.

Methods: 1. LncRNA 4.0 microarray was applied to screen the differentially expressed mRNA/ LncRNA of primary human airway granulation fibroblasts before and after the intervention of β - elemene, then the target pathway was selected through bioinformatics analysis (KEGG pathway enrichment, GO analysis, target gene prediction from database). 2. QRT-PCR and Western Blotting verified the expression of genes modulating proliferation, migration and phenotype transition of myofibroblasts in the downstream of the target pathway, and CCK8 proliferation assay,Flow cytometry, Wound healing assay, Transwell assay and Cytoskeletal immunofluorescence assay were employed to assess changes in cell function. The "Gain and lost of function","function-phenotypy rescue experiment" was implied to validated that β - elemene exert its efficacy through the target pathway (compared with the conventional treatment drug, paclitaxel).3. According to "CeRNA(competing endogenous RNAs) hypothesis "and qRT-PCR verification, the CeRNA network regulated by β - elemene was constructed, and the competitive combination among lncRNA/ miRNA/ target gene was verified by "three factor-Dual Luciferase Assay".Combinatorial intervention with multiple variables, including β-elemene, lncRNA, microRNA, mRNA, target gene over-expression plasmid, siRNA, miRNA mimics/inhibtor and pathway inhibitor, were employed for further validate that CeRNA/target pathway mediates β - elemene's regulatory mechanism.

Results: 1. The differentially expressed genes in primary human airway granulation fibroblasts before and after the intervention of β - elemene were enriched in ILK/GSK3β pathway.The ILK/GSK3β pathway is activated in human airway granulation fibroblasts compared to normal human airway fibroblasts. 2. ILK/GSK3β downstream genes like CyclinD1, E-Cadherin, and alpha-SMA were down regulated by β-elemene so as to affect their corresponding functions like proliferation, migration and phenotype transition of myofibroblasts in human airway granulation fibroblasts. This mechanism is different from the action of traditional therapeutic drug,triamcinolone acetonide.3. MIR143HG/ miR-1275 /ILK in human airway granulation fibroblasts are each other's CeRNA, and attenuation of MIR143HG by β - elemene can further inhibit the proliferation, migration and phenotype transition of human airway granulation fibroblasts.

Conclusion: Via the MIR143HG/ miR-1275 /ILK axis, β - elemene inhibits the proliferation, migration, and phenotypic transition of human airway granulation fibroblasts. The elucidated regulatory mechanism and target of action may provide theoretical basis and inspiration for the development of new drug treatment for benign airway stenosis.

OR-046

Comparison of Transbronchial Needle Aspiration with and without Ultrasound Guidance for Diagnosing Benign Lymph Node Adenopathy

Xia,Yang1、Shen,Hui1,3、Lou,Lingyun1,4、Chen,Ting2、Wang,Bin3、Xu,Zhihao4、Shen,Huahao1、Li,Wen1
1. Department of Respiratory and Critical Care Medicine, Second Affiliated Hospital of Zhejiang University School of Medicine, Hangzhou, Zhejiang, 310009, China.
2. Department of Endoscopic Center, Second Affiliated Hospital of Zhejiang University School of Medicine, Hangzhou, Zhejiang, 310009, China.
3. Department of Respiratory and Critical Care Medicine, Huzhou Central Hospital, Huzhou, Zhejiang, 313000, China.
4. Department of Respiratory and Critical Care Medicine, Fouth Affiliated Hospital of Zhejiang University School of Medicine, Yiwu, Zhejiang, 322000, China.

Objective: Transbronchial needle aspiration (TBNA) is a minimally invasive procedure performed to diagnose lymph node (LN) adenopathy. TBNA with and without endobronchial ultrasound (EBUS) guidance is associated with a high diagnostic yield in patients with malignant LN enlargement, but the value for diagnosing benign LN enlargement has been less thoroughly investigated.

Methods: We retrospectively evaluated 3540 patients with mediastinal and hilar LN enlargement who received TBNA. 166 patients with benign mediastinal lymphadenopathy were eventually included and 293 LNs were biopsied. A positive result was defined as a specific histological abnormality. Conventional TBNA (cTBNA) and EBUS-TBNA, as well as cTBNA and transbronchial forceps biopsy (TBFB), were compared. The subgroup analysis was stratified by disease type and LN size.

Results: A diagnosis was made in 76.84% of the EBUS-TBNA patients and 61.31% of the cTBNA patients ($P < 0.05$). EBUS-TBNA was superior to cTBNA for both granulomatous (65.18% vs. 45.45%, $P < 0.05$) and non-granulomatous disease (96.92% vs. 84.06%, $P < 0.05$). In contrast, the diagnostic yield of EBUS-TBNA was higher than that of cTBNA for LNs < 20 mm (79.44% vs. 64.29%, $P < 0.05$), but for LNs > 20 mm the difference was marginal. These findings were confirmed in a group of independent patients who received cTBNA plus EBUS-TBNA. The diagnostic yield did not differ between cTBNA and TBFB, but significantly increased to 76.67% when both modalities were employed.

Conclusion: EBUS-TBNA is the preferred minimally invasive diagnostic method for diagnosing benign mediastinal LN disease. Combined cTBNA and TBFB is a safe and feasible alternative when EBUS is unavailable.

OR-047

Diagnostic value of virtual bronchoscopic navigation in the bronchial tuberculosis induced central airway stenosis

Gu,Ye、Cheng,Li Ping、Gui,Xu Wei、Fang,Yong、Wang,Hao、Sha,Wei
同济大学附属肺科医院 / 上海市肺科医院

Objective: This study aimed to explore the clinical value of virtual bronchoscopic navigation (VBN) in the diagnosis of benign central airway stenosis (CAS) secondary to tracheobronchial tuberculosis (TBT).

Methods: 68 patients with benign CAS caused by TBT were recruited between July 2015 and December 2017. The location, length and diameter of stenosis were independently determined by VBN and electronic bronchoscopy (EOB), and the sensitivity and specificity of VBN in identifying stenosis were assessed with EOB as the gold standard.

Results: The overall coincidence rate was 100% between EOB and VBN. A total of 188 sites were selected from the central airway, and the stenosis was graded into 0%, ≤25%, 26%-50%, 51%-75%, 76%-90% and >90%. EOB was used as the gold standard, and the sensitivity of VBN in determining the degree of stenosis was 100%, 80.00%, 100%, 100.00% and 100.00%, respectively, the specificity was 99.14%, 100%, 100%, 100% and 100%, respectively and the accuracy rate was 99.45%, 99.45%, 100%, 100% and 100%, respectively. The length of airway stenosis on EOB was divided into <1 cm, 1-3 cm, 3-5 cm and >5 cm. There was no significant difference in the length of airway stenosis between VBN and EOB. In 3 patients received stent placement, VBN was able to accurately assess the post-operative expansion.

Conclusion: VBN is helpful for the diagnosis of TBT induced CBS and may provide important information on the location, morphology, and extent and degree of stenosis for further EOB examination and interventional therapy. VBN is recommended for patients with TBT and those with contradictions to bronchoscopy, and regular follow up of stable TBT.

OR-048

A novel way of pleural biopsy

Shi,Liyong、Chen,Xiaoyang、Zeng,Yiming
The 2nd affiliated hospital of Fujian Medical University

Objective: This study aims to achieve reverse direction of pleural biopsy and find an effective way to diagnose pleural diseases.

Methods: ① One male New Zealand rabbit was subjected to X-ray guided pneumornocentesis with one lung as the experimental side introduced the needle and pillow core of the device into the chest cavity to get a sense of breakthrough after the routine location of the puncture point and the disinfection of the cloth, withdrew from the pillow core, and established an artificial pneumothorax model.

② Under the guidance of X-ray, make the puncture needle enter the range of 0.5-1.0cm in the chest cavity, fix the device, avoid the puncture needle entering the chest cavity too deep, after exiting the pillow core, insert the biopsy forceps of the device along the outer sleeve needle, continue to enter the biopsy forceps while operating the steering handle, so that the biopsy forceps gradually turn to realize the opposite direction alignment with the parietal pleura.

③ Under the control of the operating handle, when the wire on one side is extended, the wire on the other side is shortened to realize the turning of the biopsy clamp. When the end of the biopsy clamp touches the parietal pleura, the biopsy handle is operated for biopsy.

④ After biopsy, exit the biopsy forceps, and when re-entering the biopsy forceps, change the direction of the biopsy forceps entering the chest cavity, so as to achieve different parts of the second biopsy and the last biopsy, and achieve multi-directional and multi-site biopsy.

Results: This way of plural biopsy overcomes the limitation of pleural biopsy and solves the different problems of current methods of pleural biopsy.

Conclusion: In this experiment, the innovative and reverse puncture direction pleural biopsy made multi-directional and multi-site biopsy, which can be applied to the X-ray operation and blind examination that improving the accuracy rate of diagnosis, save costs, avoiding surgical trauma, and also suitable for use in primary level hospitals.

OR-049

Bronchial Thermoplasty in patients with Dynamic Hyperinflation

Guibert,Nicolas、Guilleminault,Laurent 、Dupuis,Marion、Noel Savina,Elise、Plat,Gavin、Mhanna,Laurent、Fumat,Romane 、Hermant,Christophe 、Didier,Alain
Toulouse University Hospital

Objective: Bronchial thermoplasty (BT) has been recently approved for the management of severe asthma. This procedure improves respiratory symptoms and quality of life (QOL), but also decreases the rate of asthma exacerbations. However, a better understanding of the underlying mechanisms of BT is needed to improve patient selection. No strong marker of response has yet been identified, and there is a peculiar discrepancy between significant symptom improvements and the lack of clear change in forced expiratory volume in 1 second (FEV1). We hypothesized that the decrease in airway smooth muscle mass would be particularly efficient in patients harboring dynamic hyperinflation (DHI) at exercise, and that this functional criteria could be used to better select patients.

Methods: Patients with severe asthma (GINA criteria) and DHI (decrease ≥ 500 ml in maximal inspiratory capacity at exercise) were included in the study (NCT02618551). Symptom control (ACQ), QOL (AQLQ), FEV1, and DHI were assessed before and 3 months after BT and will be assessed at 12 months. An exploratory analysis of the structural changes in the bronchial wall in pretreated areas using probe-based confocal LASER endomicroscopy (pCLE) was also performed at the second procedure.

Results: 13 patients were included in the study at the time of analysis, but data at 3 months were only available for 8 patients (data for all 13 patients will be available at the meeting). The main results are summarized in the table. 6/8 patients improved DHI after BT (absolute median change -525 ml). We observed an improvement in FEV1 in 5/8 patients, including 2 increases of ≥ 1000 ml (median +160 ml). VO2 peak change was only available for 4 patients, and was improved in 2 of them. ACQ (median +13.8 variation) and AQLQ (median +2 variation) were significantly improved. Smooth muscle mass could not be assessed by pCLE but we report an increased auto-fluorescence in the interstitial layer after BT, potentially corresponding to bronchial healing. pCLE was also used to calculate the distance to the alveolar level and thus guide the treatment.

Conclusion: These preliminary results in a small series suggest compelling outcomes in a population selected based upon the presence of a DHI, and a positive effect on this phenomenon. We also report for the first time the structural changes induced by BT using pCLE. Further endeavors are needed to improve our understanding of the pathophysiology of BT but DHI may be a predictive marker of response to BT

OR-050

Treatment of complex airway stenoses using patient-specific 3D-engineered stents

Guibert,Nicolas1、Moreno,Benjamin2、Plat,Gavin1、Didier,Alain1、Mhanna,Laurent 1、Leyx,Pierre2、Mazieres,Julien1、Hermant,Christophe1
1. Toulouse University Hospital
2. AnatomikModeling

Objective: Despite progress made in customizing airway stents, anatomically complex airway stenosis (ACAS) remains a challenging situation. Conventional devices usually result in a significant complication rate, including poor clinical tolerance, migration, or granulation tissue reaction due to lack of congruence. We hypothesized than patient-specific, fully customized 3D stents, using computer-assisted design is feasible and has potential for improving tolerance and decreasing the complication rate.

Methods: Patients with ACAS were included in this feasibility study (NCT02889029). After computer-assisted segmentation of the airways and virtual relief of the stenosis from a CT-scan (A), a virtual 3D stent and corresponding mold were designed (B). Numerical data were then entered in a 3D CNC machine to produce the Ertacetal mold, from which the silicon stent was made (C). Stents were placed under general anesthesia through rigid bronchoscopy (D). Complication rate, dyspnea (NYHA), quality of life (VQ11 questionnaire) and respiratory function were followed (before, at 7 days and 3 months). Congruence of the stent was controlled per-operatively (bronchoscopy) and at 1 week (CT-scan (E)).

Results: 10 patients have been included for post-transplant (n=4), post-tracheotomy (n=3) or post-surgery (n=2) ACAS, or for extensive tracheobronchomalacia (TBM, n=1). The stent could be implanted in all 10 patients. The 3-month complication rate was 40%, including 1 benign mucus plugging, 1 stent removal due to intense cough and 2 stent migrations. 9/10 stents showed great congruence within the airways, the only failure involving the TBM case. 8/10 induced significant improvement in dyspnea (>1 point NYHA class gain), quality of life (> 10% VQ11 score improvement) and respiratory function (>10% VEMS increase).

Conclusion: These preliminary data, in a selected subset of highly complex situations, suggest compelling outcomes using customized stents. The suboptimal congruence observed in a TBM case, probably due to higher respiratory variations, underlies the need to take into account the respiratory dynamic in tracheal cases using 4D CT-scan, and the migration events suggests the need to add reinforcements rings, studs or patient-specific structures in predefined areas in cases of less complex anatomy.

PO-001

Semi-rigid thoracoscopic biopsy for the diagnosis of benign and malignant pleural effusion with HybridKnife：a clinical study

Zhou,Hongmei
Affiliated Zhongshan Hospital of Guangdong Meidical Universty

Objective： To analyze the safety, efficacy and accessibility of flexible thoracoscopic biopsy for the diagnosis of unexplained pleural effusion combined with Hybrid Knife, and to explore its application value in diagnosis and treatment of pleural lesions.

Methods： Retrospectively analyzed 13 patients with pleural lesion who were difficult to obtain pathological specimens via the conventional thoracoscopic forceps, but operated again with Hybrid Knife via thoracoscopic under the condition of common anesthesia. All the biopsy tissues obtained were received the routine pathological examination and immunohistochemical analysis.

Results： The biopsy tissues acquired by the Hybrid Knife were large enough also with high positive rate, whose biopsy success ratio, qualitative diagnosis ratio ,coincidence ratio and complication ratio were 100%、99.1%、98.9% and 9.8% relatively. The main complications were pain that 3 cases ached during operation, 2 cases after operation, 1 case with hemorrhage, 1 case with pleural reaction. All the symptoms were relieved after relative disposes. The lager solitary lesions were removed during the biopsy procedure which released the tumor impact effectively.

Conclusion： Biopsy for unexplained pleural effusion operated by flexible thoracoscopic with Hybrid Knife is a diagnosis method with safety, effect and convenience, which can promote the diagnosis accuracy ratio in these patients and provide valid treatment.

PO-002

Use of noninvasive ventilation through a muti-function mask in the management of respiratory failure during the transbronchial lung biopsy process

Yang,Lianyue
The First Affiliated Hospital of Guangzhou Medical University

Objective： To explore the feasibility of transbronchial lung biopsy (TBLB) through assisted by noninvasive ventilation through muti-function mask in patients with respiratory failure.

Methods： A 76-year-old patient man with a history ofcough and sputum for 8 years, shortness of breath for 3 yearswas admitted to the hospital due to hemoptysis for more than one month. Chest CT showed consolidation of the right lower lobewhich was Suspectedof tumor. Patient’s condition is getting worse after active anti-infection treatment.Hence biopsy was needed to confirm the diagnosis. However, patientpresentwithrespiratorythattheblood oxygen saturation fluctuates between 78-85% under the state of resting. The blood gas analysis results show that the partial pressure of carbon dioxide is 27.5mmHg, and the partial pressure of oxygen is 48.4mmHg. With the consent of the patient and family members, TBLB was performed through bronchoscopy to confirm the diagnosis. During the operation, a noninvasive ventilator was used to support assisted ventilation, and a multifunctional tracheal intubation mask was connected. Under conscious sedation, a bronchoscope was inserted into the tracheal intubation hole of the mask and TBLBwasperformedin the right lower lobe. During the operation, the patient's vital signs were stable,

no dyspnea occurred and the blood oxygen saturation was maintained above 90%. the patient was well tolerated, the operation process was successful.No bleeding, pneumothorax and other biopsy-related complications occurred. Postoperative pathology was diagnosed as lung adenocarcinoma.

Results: Postoperative pathology was diagnosed as lung adenocarcinoma.

Conclusion: It is suggested that with the aid of noninvasive ventilation through a multifunctional tracheal intubation mask, TBLB can be performed safely in patients with respiratory failure.

PO-003

Application of Transbronchoscope Cryotherapy in the Rescue of Massive Hemoptysis :2 Cases

Wen,mei、Man,Ning、文梅
Wuhan Asia General Hospital

Objective: To investigate the efficacy and safety of transbronchoscope cryotherapy in the treatment of massive hemoptysis.

Methods: Two cases of massive hemoptysis in Wuhan Asia General Hospital were reported. After emergency endotracheal intubation, bronchoscopy found a large number of blood clots blocked in the airway. To evaluate the value of transbronchoscope cryotherapy in the rescue of asphyxia caused by massive hemoptysis by comparing the improvement of symptoms, vital signs and blood gas analysis before and after treatment.

Results: The blood clots in the airways were cleared rapidly, the symptoms of asphyxia and hypoxia were obviously improved in 2 patients. After treatment, the partial pressure of oxygen, oxygen index , symptoms and vital signs were obviously improved, and the time of symptom relief was obviously lower than that of routine suction and clamp treatment. The patients recovered well, no complications and recurrent hemoptysis.

Conclusion: Transbronchoscope cryotherapy method is effective and rapid in the rescue of blood clots blocked airway caused by massive hemoptysis.

PO-004

Value of bronchoscopy interventional therapy in benign and malignant airway stenosis

Fu,Weiping、Feng,Jia Gang、Shu,Jing Kui、Wang,Xu Ming
Department of Respiratory Critical Care Medicine， The First Affiliated Hospital of Kunming Medical University

Objective: To explore the value of bronchoscopic interventional therapy in the benign and malignant airway stenosis.

Methods: 114 patients of airway atenosis were retrospectively analyzed after bronchoscopic inerventional therapy in our hospital from April 2015 to November 2018,. The causes include benign and malignant tumors in the airway, tuberculosis, granulomatous lesions, foreign bodies, etc., Carrying out treatments such as freezing, electric knife, argon knife, balloon expansion, etc.To evaluate the effectiveness and safety of the treatment.

Results: Seventy-four patients with benign airway stenosis were compared with airway stenosis before and after treatment, t=26.433, P=0.000, the difference was statistically significant,mMRC (2.51±0.99) before treatment and mMRC(1.70±1.05) after treatment. The difference was statistically significant (P<0.05). Forty patients with malignant airway stenosis were compared with airway stenosis before and after treatment, t=8.062, p=0.000, the difference was statistically significant; mMRC was (2.75±0.55), and after treatment mMRC(2.50±0.61), the difference was statistically significant (P<0.05).The two groups were effective, and the benign group was better than the malignant group.and no serious complications occurred during the operation.

Conclusion: The use of bronchoscopic intervention in airway stenosis can significantly lighten the symptoms of patients, improve the quality of life, and the effectiveness of benign airway stenosis is significantly greater than malignant. In addition, it has the advantages of less trauma, less complications, and wide indications. It provides a new safe and effective choice for patients who cannot be treated surgically or who are unwilling to undergo surgical treatment.

PO-005

Diagnostic value of bronchoscopy biopsy guided by small ultrasound probe in peripheral lung nodules

Fu,Weiping、Feng,Jia Gang、Shu ,Jing Kui、Wan,Zhu
Department of Respiratory Critical Care Medicine， The First Affiliated Hospital of Kunming Medical University

Objective: To evaluate the diagnostic value of endobronchial ultrasound-guided transbronchial lungbiopsy (EBUS-TBLB) guided by a small ultrasound probe for peripheral lung nodules..

Methods: Sixty-one patients with peripheral pulmonary nodules detected by chest CT examination in the Second Department of Respiratory and Critical Medicine of the First Affiliated Hospital of Kunming Medical University from January 2019 to December 2019 were selected to perform peripheral lung lesions under the guidance of a small ultrasound probe Biopsy to obtain specimens, observe the benign and malignant nature of lung nodules, the diagnosis rate of the location of the lung lobe, the relative position of the ultrasound probe and the lesion, the relationship between the lesion diameter and the positive rate, and the incidence of complications. Use spss25.00 statistical software to analyze the data.

Results: Of the 61 patients, 47 were confirmed by EBUS-TBLB, with a total positive diagnosis rate of 77.05%, a malignant lesion diagnosis rate of 85.2% (23/27), and a benign lesion diagnosis rate of 70.59% (24/34). Average operation time (28.23 ± 3.91) min, lesion diameter (2.71 ± 0.75) cm, number of specimens (5.25 ± 0.97).2. The distribution of the lesions in the location of the lung lobes and the diagnosis rate:4 cases of left upper lobe (accounting

for 6.6%), diagnosis rate 50% (2/4); 19 cases of left lower lobe (accounting for 31.1%), diagnosis rate 78.9% (15/19); right upper lobe 15 cases (accounting for 24.6%), the diagnosis rate was 73.3% (11/15); 8 cases of the right middle lobe (accounting for 13.1%), the diagnosis rate was 75% (6/8); 15 cases of the right lower lobe (24.6%)), The diagnosis rate was 86.7% (13/15). Among them, the diagnosis rate of the left upper lobe was the lowest, and the diagnosis rate of the right lower lobe was the highest. The results showed that there was no statistical difference in the diagnosis rate between different lung lobes (X2 = 2.614, p> 0.05).3.Related factors affecting the diagnosis rate of EBUS-TBLB:The diagnosis rate of lesion diameter>20mm and ≦ 20mm was 86.36% (38/44) and 52.94% (9/17) respectively, and there was a statistical difference between the two groups (P <0.05). The diagnostic rates of the lesions located at the center and one side of the probe under ultrasound were 92.11% (35/38) and 50.00% (11/22), respectively, with statistical differences (P <0.05).4.complications: Most patients had no obvious serious complications during the operation. Among them, 4 patients had a small amount of bleeding of about 10-20ml, 1 patient had postoperative fever, and 1 patient had a small amount of pneumothorax. After proper treatment, there was no special discomfort.

Conclusion: EBUS-TBLB has a high positive diagnosis rate for peripulmonary nodular lesions. The diameter of the lesion and the position of the probe and the lesion affect the positive diagnosis rate. It is less invasive and has no serious complications. It is a safe and effective method for peripheral lung biopsy , Worthy of widespread clinical application.

PO-006

Bronchoscopic Retrograde Recanalization of Complete Trachea Obliteration after Tracheostomy: a 5-Case Report

Sun,Kunyan、Zhang,Hong、Zhang,Wei、Cheng,Yuan、Wang,Guangfa
Peking University First Hospital

Objective: Complete obliteration of trachea after tracheostomy is a great challenge to clinicians. We report for the first time a novel method of retrograde interventional bronchoscopy to successfully recanalize complete trachea obliteration, by retrogradely piercing through the obliterans segament with an aspiration needle and leaving its stylet as a guide wire for dilation.

Methods: Five patients with suprastomal trachea obliterationand tracheostomy dependency were enrolled in this study. After general anesthesia，rigid bronchoscope was inserted to the subglottic area of the trachea. Under the guidance of bronchoscopy at tracheostoma, a 21 G aspiration needle for transbronchial needle aspiration(TBNA) was carefully inserted retrogradely towards the vocal cords from the distal blind sac. Once the needle tip was visible in subglottic trachea obliteration site, and rigid forceps were introduced to grasp the tip and draw it up. When the length of the needle could guarantee its safe stay in the proximal sac, the knob of the stylet was cut off from the root. The stylet was inserted slightly until its tip got out of the needle. Afterwards, the rigid forceps grasped the tip of the stylet and the needle was extracted backwards gradually. The stylet was left in the tracheal as a guide wire. Ureteral dilator set with different diameters (maximum diameter 18Fr) were introduced sequentially through the stylet to dilate the stenosis. If it was too hard to get through, a harder dilator (external diameter2.7mm) from a central venous catheterset would be considered. After serial dilation, an appropriate-size CRE balloon would be used according to the diameter of the normal trachea based on previous CT scan. Once the trachea lumen was restored, further treatment would be determined according to patient’s need and condition.

Results: All cases achieved successful recanalization with effortless breathing after the treatment. 4 of them received T-tube insertion and restored phonation, and the other patient gave up further interventions after recanalization.

Conclusion: Interventional bronchoscopy combined with retrograde puncture is a safe and promising treatment method for complete tracheal obliteration. It is less invasive and more beneficial for patients compared to open surgery and conventional interventions. Simultaneously, this approach is capable of preserving vocal cords’ function and improving quality of life.

PO-007

The Effect of Bronchofibroscope Lavage Combined with Acetylcysteine Effervescent Tablets on Pulmonary Ventilation Function of Patients with COPD

Zhao,Tong
feixian pepole hospital

Objective: To investigate effect of bronchofibroscope alveolar lavage combined with Acetylcysteine Effervescent Tablets on pulmonary ventilation function of patients with COPD.

Methods : A total of 72 patients with COPD were divided into control group (n=36) and observation group (n=36) according to the hospitalization time. Observation group was treated with bronchofibroscope alveolar lavage combined with Acetylcysteine Effervescent Tablets on the basis of conventional therapy, while control group was treated with Acetylcysteine Effervescent Tablets on the basis of conven-tional therapy. Blood gas analysis and pulmonary ventilation function indexes were observed and compared before and after treatment for 30 d between the two groups.

Results: There were no significant differences in blood gas analysis and pulmonary ventilation function indexes between two groups (P > 0. 05). After treatment for 30 d, levels of partial pressure of carbondioxide (PaCO2) and total lung capacity (TLC) were significantly lower, while levels of partial pressure of oxygen (PaO2),forced expiratory volume in 1 second (FEV1) and vital capacity (VC) were significantly higher than those before treatment in observation group (P < 0. 05); in control group, PaCO2 and TLC levels were significantly lower than those before treatment(P < 0. 05). After treatment for 30 d, in observation group, PaCO2 and TLC levels were significantly lower, while PaO2 ,FEV1 and VC levels were higher than those in control group (P < 0. 05).

Conclusion: Bronchofibroscope alveolar lavagecombined with Acetylcysteine Effervescent Tablets can effectively improve pulmonary ventilation function and quality of life of patients with COPD.

PO-008

Combined small-cell lung carcinoma with squamous cell carcinoma in a unilateral lung mass: A case report

D'Souza,Jason Martin、Chuah,Khoon Leong 、Arputhan,Abisheganaden John、Lee,Chuen Peng
Tan Tock Seng Hospital

Objective: Background:Combined small-cell lung carcinoma (C-SCLC) is defined as small-cell lung carcinoma (SCLC) with additional components that consist of any of the histological types of non-small-cell lung carcinoma (NSCLC)1. This rare combination comprises of about 5%–10% of all SCLC2. We describe a rare case of combined small-cell lung carcinoma in a localised unilateral lung tumour that was diagnosed bronchoscopically.

Methods: Case Report: Mr T is a 75-year-old Chinese male with 50 pack-years of smoking and history of breast cancer in his sister. His past medical history also includes type 2 diabetes mellitus, hyperlipidaemia and shingles affecting the right facial nerve. He presented to our centre with complaints of non-productive cough for 7 months with occasional shortness of breath. Clinical examination revealed decreased intensity of breath sounds in the right infraclavicular and right suprascapular regions. A chest radiograph showed a mass-like consolidation in the right perihilar region. Computed tomography (CT) of thorax confirmed a right upper lobe mass causing obstruction to the right upper lobe bronchus and encasing the right upper lobe pulmonary artery (Fig-1 A, B). He underwent bronchoscopy with endobronchial ultrasound (EBUS) which revealed small station 4R, 4L and 7 lymph nodes. Transbronchial needle aspiration (TBNA) of the right upper lobe mass with rapid on-site evaluation confirmed atypical cells and moderate cell yield. Flexible bronchoscopy revealed a fleshy tumour completely occluding the right upper lobe bronchus.

This was subjected to endobronchial biopsy and a bronchioalveolar lavage to increase tissue yield (Fig-1 C, D). The histological evaluation revealed confirmatory evidence of small cell carcinoma from the right upper lobe mass and in the bronchioalveolar lavage sample. Squamous cell carcinoma was found in the endobronchial biopsy specimen. The lung tumour board concurred with the diagnosis of combined small-cell and squamous cell lung cancer. Chemotherapy with cisplatin and etoposide was initiated along with concurrent intensity-modulated radiotherapy and he has been stable on close follow up.

Results：

Conclusion： This case illustrates the rare presence of C-SCLC that was diagnosed with bronchoscopic techniques. Literature evidence suggests that in most cases, the histopathological diagnosis of C-SCLC was obtained from the post-surgical resected tumour. Meticulous tissue sampling with a combination of specimens from tumour core as well as endobronchial lesion gave the pathologist an opportunity to characterise the histology more effectively in this case. Comprehensive tissue sampling at bronchoscopy is vital in establishing the diagnosis of C-SCLC, and this has a significant impact on cancer treatment and prognosis.

PO-009

The Role of High in the Treatment of Tracheal Tumor

AN,XIAOQING
SHANDONG PROVINCIAL CHEST HOSPITAL

Objective： High frequency electrical snare can remove most tumors.

Methods： High frequency electrical trap combined with cryosurgery was used to remobve the airway tumor and observe the relief of postoperative symptoms and complications. As a conservative treatment,trcheoscopy can improve the symptoms of lung cancer patients, prolong the survival time and improve the quality of patients with lung cancer.Patients withs lung cancer can not be trested by surgery, the disease into the late stage,chest tightness,dysptoms,can be conservative treatment under the bronchoscope to improve the symptoms.The patient with lung cancer was trested with chest tightness and dyspner. Cough,expectoration with chest tightness 20till days. The patient had cough and expectoration more than 20 days before the cold,accompanied by chest tightness, the patient had no fever, no chest pain, and the patient had white expectoration Phlegm, patient with no abdominal pain, diarrhea, no headache, dizziness, diet, normal urine,patients do not care, oral head Spore, the patient effect is not good, sees a doctor the local hospital, the line chest CTprompt lung occupied ,then comes to my hospital to see a doctor,after the admission ward.Since the onset, appetite is normal, normal sleep, ruine and feces, patients with no significant changes in body weight. Normal health condition:Good;10 years history of left knee arthritis,hypertension history of 5 years,did not control blood pressure,denied liver inflammation, tuberculosis, malaria history; Deny the history of hesrt disease, diabetes, cerebrovascular disease, kidney disease ,lung disease history; Vaccination history is unknown. Denial of food and drug allergy;History of surgery, trauma,and transfusion were denied. Ater successful general anesthesia, the laryngeal mask was placed smoothly through the mouth, the glottis was closed, the tracheal ring was present,and the carina was sharp. The lumen of each segment of the right lung was clear and the mucosa was smooth.No obvious abnormalities were observed. A new oval organism is visible at the distal end of the left main branch,which is soft and causes almost complete left main branch blockage. High frequency electric snate was used to cut local new organisms, and carbon dioxide was used to freeze local new biological residues. Left upper lobe lumen unobstructed, left lower lobe mucous hupertrophy, lumen can be seen sticky a lot of mucus, give physiological lavage, suction, see lumen is unobstructed. Duing the operation, ice normal saline and APCwere given to stop bleeding .

Results： After operarion,the clinical symptoms,shortness of breath ,dyspnea index score and the dgree of airway stenosis were improved significantly.No serious complications such as massive hemoptysis and stent implantation occurred in this patient.

Conclusion： High-frequency electric snare in an effective and safe approach for the treatment of main airway neoplasm.

PO-010

A noval method for treating the refractory and severe benign central airway stenosis with oscillating positive expiratory pressure——two cases report

Huang,Haidong1、Zhu,Weihua1,2、Qin,Hao1、Bai,Chong1
1. Changhai Hospital，the Second Military Medical University-Shanghai (China)
2. Zhengzhou Yihe Hospital Affiliated to Henan University-Zhengzhou(China)

Objective: To appraise the safety and effectiveness of one novel method with oscillating positive expiratory pressure（OPEP） for treating the refractory and severe central airway stenosis.

Methods: Two cases were collected. One 84-year-old lady diagnosed as intrathoracic goiter suppressing the tracheal with aggregated dyspnea (MRC score 4). One 22-year-old lady with complex left main bronchus (LMB) stenosis due to historic tuberculosis (MRC score 3). Obstructive ventilatory dysfunction were observed. Due to the high risk for an invasive treatment, a complex conservative method was adopted including anti-infection, bronchial hygiene and OPEP. They were followed up more than 10 months.

Results: For the 84-year lady, dyspnea was improved (MRC score 1), lumens of tracheal enlarged (Fig. 1), pulmonary function didn't changed(Tab.1). For the 22-year-old lady patient, dyspnea relieved (MRC score 0), the LMB, left upper/lower lobe bronchus were enlarged (Fig. 2), pulmonary function also improved(Tab.2).

Conclusion: OPEP treatment may be a novel and non-invasive method for refractory benign central airway stenosis.

PO-011

An extremely Distal Bronchiole Foreign Body Removed with Virtual Navigation Bronchoscopy in Trendelenburg and Lateral Patient Position

Li,You、Li,Yishi、Guo,Shuliang
The First Affiliated Hospital of Chongqing Medical University

Objective: A foreign body aspirated into the extremely distal bronchus cannot be visible even using a flexible bronchoscope with the smallest diameter working channel. Thoracotomy is necessary on such situation generally. This retrospective report analyzes and summarizes a case concerning a dental drill aspiration. Combined utilization of virtual navigation bronchoscopy, intraoperative patient posture changes, and physical methods like thoracic flap and gravity, it was successfully and safely removed by a flexible bronchoscope. A literature review is conducted to provide reference value and discussion significance for clinical similar cases meantime.

Methods: The case was reviewed for risk factors of foreign body inhalation, such as Parkinson's disease, symptom distributions, radiographic features, bronchoscopic findings, precise localization through virtual navigation bronchoscopy, and convenient operations using patient position changes. We further identified these unique innovative methods and compare to other literatures on clinical experiences.

Results: HRCT was performed, as well as its three-dimensional reconstruction. Associated with LungCare virtual navigation bronchoscopy, we precisely localized the foreign body in the periphery bronchia of the anterior basal segment of the right lower lobe (RB8a, greater than grade 9 bronchus) nearly abutting the pleura and adjacent to the chest wall and diaphragm. Then we changed the patient to the Trendelenburg position and left lateral decubitus position.

Sustaining tapping thoracic cage and utilizing oscillatory expectoration eliminator, the dental drill slide back into right middle bronchial and was extracted successfully and integrally by using snare under visible circumstances.

Conclusion: This case proved innovatively combined utilization of virtual navigation bronchoscopy, intraoperative patient posture changes, and physical methods like thoracic flap and gravity to remove such foreign body aspirated into the extremely distal bronchiole by a flexible bronchoscope successfully and safely. And the present report provided a reference value and discussion significance.

PO-012

A case of electronic bronchoscope ablation combined with photodynamic therapy for large cell lung cancer

Hao,Xingliang、Wang,Yingying、Ji,Yanrong、ZhangJian、郝兴亮
Shengli Oilfield Central Hospital of Dongying, Shandong , China

Objective: To explore the long-term effect of bronchoscope electric snare, APC, carbon dioxide cryotherapy and other airway tumor removal combined with photodynamic therapy for large cell lung cancer at the carina.

Methods: A 82-year-old male patient was admitted to the hospital on March 24, 2020 due to cough, sputum, chest tightness and suffocation for 11 months. Chest CT with contrast showed in June 2019: Tumors near the opening of the right main bronchus; Multiple nodules in the lungs and interlobular pleural area, and can't exclude tumor metastasis (Figure 1). The patient who is barrel chest has a PS score of 3,and reduced right lung breath sounds, which are dry and wet rales. He had a history of hypertension for 10 years, and had surgery for esophageal cancer 22 years ago. The smoking index was 50 packs/year. Pulmonary function test: FEV1 1.29L, accounting for 50% of the expected value, FEV1/FVC 65%. The blood gas analysis: PH value 7.42, oxygen partial pressure 67mmHg, carbon dioxide partial pressure 42mmHg. Tumor markers: CEA 7.48ng/ml, cytokeratin 19 fragment 4.20ng/ml, CA199 63.59 U/ml. Diagnosis: 1. Lung space-occupying lesions and lung metastases are not excluded；2. Chronic obstructive pulmonary disease. Under general anesthesia, bronchoscopy and interventional therapy were performed. During the operation, it was found that the lesion involved the carina, and the right main bronchus was completely blocked by the new organism, so treatments such as electric snare, carbon dioxide freezing, and APC ablation hemostasis were given. (Figure 2). Postoperative pathological diagnosis: poorly differentiated large cell neuroendocrine carcinoma. Because chemotherapy was refused by patient, he was given radiotherapy for the carina lesions. In February 2020, the patient experienced aggravation of cough and chest tightness again. CT examination showed that there was a mass at the opening of the main bronchus on the right, multiple nodules in both lungs, considering metastasis, and atelectasis in the upper lobe of the right lung (Figure 3). On March 25, the right main bronchus mass was excised under bronchoscopy. During the operation, the lesion showed infiltrating changes, involving the carina, and the right main bronchus was completely blocked (Figure4).PDT630 semiconductor photodynamic therapy was given on April 1 2020, with an irradiation power of 300mW, 300 seconds × 5 times. Irradiate again for 300 seconds × 4 times on April 2. Bronchoscopy was performed on April 5 and the necrosis was cleaned up. At present, the patient's chest tightness and suffocation symptoms have improved significantly. Figure 1 CT:Lesions in the right main bronchus Figure 2 Comparison before and after endoscopy Figure 3 CT: Lesions in the right main bronchus Figure 4 Comparison before and after endoscopy

Results: The patient was given electric snare, APC, carbon dioxide refrigeration and other technologies to cut the tumor in the airway, which can eliminated the tumor burden quickly. After the ablation treatment, combined with photodynamic therapy, the patient's lung function was improved significantly.

Conclusion: Central malignant airway stenosis involving the carina, combined treatment with cryotherapy, electric snare, argon plasma coagulation, photodynamic therapy, etc. can improve the patient’s quality of life.

PO-013

Foreign body removal using bronchoscopy：a case report

Jin,Xingxing、Ding,Min
The First Affiliated Hospital of Chongqing Medical University

Objective： Introduce a case to investigate the methods of Foreign body removal using bronchoscopy.The patient was a middle-aged woman who was admitted to hospital for "cough and sputum with blood in sputum for 1 month". The white purulent sputum waswith blood and pharyngal itching.Without fear of cold, fever, night sweats, and other discomfort.The chest CT was improved in the local hospital to indicate pulmonary infection. After symptomatic treatment, such as anti-infection, the above symptoms were slightly relieved, but still repeated.After admission, the vital signs were stable, the breath sounds of both lungs were coarse, and there was a little moist rales in the left upper lung. CT and related examinations were completed, and small patchy high-density shadows were found in the left upper lobe bronchus (FIG. 1).Under bronchoscopy, there was a black substance blocking the lumen in the bronchial opening in the anterior segment of the upper lobe (Figure 2), and a large amount of purulent secretions were leaking out. A small amount of local granulation tissue hyperplasia was considered as a possible bronchial foreign body. However, the patient complained that there was no history of foreign body inhalation.

Methods： at firse,Both of the mucosal biopsy forceps and the freezing probe were failed to be taken successively. During the operation, the patient had a significant cough. Continuous sedation and analgesia were performed with propofol and Remifentanil, and the operation was performed under non-invasive ventilator assisted ventilation. After granulation tissue was cleaned with biopsy forceps, a small amount of suspected wood residue was taken out with forceps, and laser ablation was used to remove foreign bodies, with poor results.After the foreign body is cut with an electric trap, the foreign body is removed with a forceps. The material is suspected to be wood (FIG. 3).The remaining foreign body was located in the anterior segment a of the left upper lobe. Due to small operating space and local mucosal congestion and edema, it was difficult to remove the foreign body, so the operation was completed.The patient was instructed to adhere to atomization inhalation of budesonide fluid, and the foreign body was removed again three days after the anti-inflammatory treatment.After preoperative discussion, the foreign body was first crossed by the scraper and the stone balloon and moved from the distal bronchial to the proximal bronchial, and then the foreign body was successfully removed with the selection of a trap and the distal lumen was narrowed.

Results： three days after the anti-inflammatory treatment. the foreign body was successfully removed.

Conclusion： Tracheobronchial foreign body is a common respiratory disease, common in the right bronchus, distributed in the left upper lobe bronchus in rare cases.Preoperative CT was fully evaluated to pay attention to the blood vessels beside the foreign body, so as to achieve a clear understanding.Perfect intraoperative medical cooperation, according to the shape of the foreign body, size, edge smoothness, hardness and softness, water content and five characteristics and the location of the foreign body to choose the appropriate tools;Appropriate anesthesia and endoscopic approach were adopted to enhance the patient's comfort.The emergency plan should be improved, and the operation should follow the four principles of avoiding massive hemorrhage in the airway, preventing foreign body from falling off, preventing foreign body volume from blocking the airway, and ensuring the smooth passage of foreign body through the glottis. Various measures should be taken to ensure the successful removal of foreign body under the premise of safety.

PO-014

Observation and study of the effectiveness and safety of tracheobronchial stent loaded with 125I seeds in the treatment of central airway stenosis caused by lung cancer

Lin,Long、Guan,Li、Zhang ,Cail Yun、Gao,Bao-an
Institue of Respiratory Disease, China Three Gorges University-Yichang Central People's Hospital

Objective: To investigate the effectiveness and safety of tracheobronchial stent loaded with 125I seeds in the treatment of central airway stenosis caused by lung cancer.

Methods: Methods (1) To select standard malignant central airway stenosis patients who were treated in the department of respiratory and critical medicine of Yichang Central People's Hospital from January 2015 to January 2018, and accept tracheobronchial stent loaded with 125I seeds or common tracheobronchial stent for treatment. (2) Collect basic medical history data of all subjects, and complete the evaluation of American Thoracic Association shortness of breath score, KPS score and TNM stage. Finish related examinations before the operation. According to the results of chest spiral computer tomography and bronchoscopy, choose the stent of appropriate material and specification after in judgement of the features of airway lesions. (3) All patients were divided into observation group and comparison group according to the readiness to accept the treatment of 125I seeds brachytherapy. The tracheobronchial stent loaded with 125I seeds implantation was employed for the patients of the observation group, while the common tracheobronchial stent was adopted for the patients of the comparison group. (4) Main observation indicators: 1) Comparison of baseline data between the observation group and the comparison group; 2) Comparison of the symptom relief, the degree of airway stenosis and the quality of life between the observation group and the comparison group; 3) Comparison of intraoperative and postoperative complications between the observation group and the comparison group; 4) Comparison of the tracheobronchial restenosis rate and the first tracheobronchial restenosis time after operation between the observation group and the comparison group; 5) Comparison of the survival time between the observation group and the comparison group.

Results: Results (1) There was no statistical difference between the two groups in preoperative baseline characteristics($P>0.05$). (2) Two groups of patients were successfully implanted with tracheobronchial stent in one time. (3) 24 hours after operation in the observation group, the shortness of breath index decreased from 3.44±0.71 to 1.41±0.74($P<0.01$), SaO2 increased from (85.09±3.42)% before operation to (94.40±3.23)% after operation($P<0.01$). 24 hours after operation in the comparison group, the shortness of breath index decreased from 3.55±0.51 to 1.40±0.75($P<0.01$), SaO2 increased from (84.05±3.41)% before operation to (95.10±3.48)% after operation($P<0.01$). But there was no statistical difference in the shortness of breath index and SaO2 between the two groups before and 24 hours after operation($P>0.05$). (4) One month after operation in the observation group, the mean airway stenosis decreased from (78.82±13.65)% to (27.06±6.29)%($P<0.01$). In the comparison group, the mean airway stenosis decreased from (77.00±14.55)% before operation to (46.00±13.92)% after operation ($P<0.01$). The mean airway stenosis of the observation group was significantly lower than the comparison group one month after operation($P<0.01$). One month after operation in the observation group, KPS score increased from 49.70±10.59 before operation to 62.94±9.06 after operation ($P<0.01$). In the comparison group, KPS score increased from 50.50±13.17 before operation to 55.00±12.35 after operation($P<0.01$). KPS score of the observation group was higher than the comparison group one month after operation($P<0.05$). (5) There was no statistical difference in intraoperative hemorrhage, postoperative chest pain, irritable cough, retension of secretions, stent displacement and death due to operation between the observation group and the comparison group($P>0.05$). In the observation group, the postoperative bleeding rate is 6%(2/34). In the comparison group, the postoperative bleeding rate is 25%(5/20). There was statistical difference in the postoperative bleeding rate between the two groups($P>0.05$). There were no complications such as the displacement or drop of seeds, myelosuppression and radiation pneumonitis in the observation group. There were no complications such as pneumothorax, mediastinal emphysema, pneumoderma and damage of stent in two groups. (6) 1, 3 and 6

months after operation, the tracheobronchial restenosis rate was 0%、29% and 79% in the observation group. The tracheobronchial restenosis rate of the observation group was lower than that of the comparison group, the difference being significantly remarkably(P<0.05). Restenosis was detected at (121.10±53.60)days after implantation of stent in the observation group, which was significantly longer than (43.00±40.31)days in the comparison group(P<0.01). (7) The 3-month, 6-month survival rates after operation were respectively 88% and 76% in the observation group. The 3-month, 6-month survival rates after operation were respectively 72% and 56% in the comparison group. There was no statistical difference between the two groups(P>0.05). The one-year survival rate of the observation group was 44%, and the comparison group was 6%, the difference being significantly remarkably(P<0.01).

Conclusion: (1) Tracheobronchial stent loaded with 125I seeds is convenient, safe, affordable in the treatment of central airway stenosis caused by lung cancer, which is easy to be popularized and applied in clinic. (2) The effectiveness of tracheobronchial stent loaded with 125I seeds in the treatment of central airway stenosis caused by lung cancer has been confirmed in clinical practice, which can inhibit tumor and granulation tissue growth significantly. Dyspnea can be remarkably alleviated, lower tracheobronchial restenosis rate, better quality of life and a longer survival span can be expected by this technique. (3) Tracheobronchial stent loaded with 125I seeds in the treatment of central airway stenosis caused by lung cancer is fewer complication, safe and feasible.

PO-015

Efficacy and Safety of Interventional Bronchoscopy for Non-central Airway Stenosis Combined with Atelectasis

Ma,Yun
Henan Provincial People's Hospital, People's Hospital of Zhengzhou University

Objective: To investigate the efficacy and safety of interventional bronchoscopy for non-central airway stenosis combined with atelectasis.

Methods: Retrospectively analyzed the nine patients with segmental or sub-segmental airway stenosis underwent interventional bronchoscopy during March 2016 to December 2019. Dyspnea index and atelectasis recruitment were evaluated before and after the treatment. Complication related to the procedures was recorded.

Results: The clinical symptoms of all patients were relieved after the after segment and subsegmental stenosis being dilated by interventional bronchoscopy. Complete or partial recruitment was shown on chest computed tomography images. No bleeding or pneumothorax was observed. None of the patients developed hyperglycemia, adrenocortical insufficiency or other complications.

Conclusion: Role of interventional bronchoscopy in segment and subsegmental stenosis should not be ignored. It is a safe treatment and could avoid unnecessary surgical treatment.

PO-016

Comparative observation of the clinical effect of bronchial thermoplasty in the treatment of bronchial asthma and asthma-chronic obstructive pulmonary disease overlap

Hu,Siyu、Long,Fa、Long,Liang、Huang,Wenting、Fu,Peng、Dong,Hongbo、Gan,Jingfan、Huang,Zhihui、胡斯育
University of Chinese Academy of Sciences Shenzhen Hospital

Objective: To compare and observe the clinical efficacy of bronchial thermoplasty (BT) in the treatment of bronchial asthma ,asthma and chronic obstructive pulmonary disease overlap.

Methods: A retrospective analysis of the clinical data of 49 patients with ACO who underwent BT treatment and 50 patients with bronchial asthma who underwent BT during the same period at the University of Chinese Academy of Sciences Shenzhen Hospital from January 2016 to December 2018，which were divided into overlapping group and Asthma group, Comparative analysis of the two groups of patients, age, course of disease, and general characteristics of smoking history, lung function before and 1 year after BT treatment [including forced vital capacity (FVC), forced expiratory volume in the first second (FEV1), forced expiration in the first second Volume as a percentage of predicted value (FEV1% pred)], Asthma Control Test ACT score, Asthma Quality of Life Questionnaire (AQLQ) score, Asthma Control Questionnaire (ACQ) score, and overlap group pre- and post-treatment chronic obstructive pulmonary disease assessment test (CAT) Changes in scores and Modified British Medical Research Council (mMRC) scores.

Results: The general base characteristics of the two groups are compared. The patients in the overlapping group are older than those in the asthma group, and the course of disease and smoking history are longer than those in the asthma group (all $P < 0.05$)[64.29±10.50years vs 47.94±10.99 years; 10.00（10.00,25.00）years vs 9.00（1.75,20.00）years；20.00（2.00,40.00）years vs 0.00（0.00，10.00）years]. The predicted values of FVC, FEV1 and FEV1% of lung function in the overlap group before treatment were lower than those in the asthma group (all $P < 0.05$)[1.98（1.43,2.43）L vs2.54（2.02,3.15）L；0.92（0.61,1.26）L vs1.75±0.78L； 50.31±15.53L vs65.00±14.23L]. There was no significant difference in ACT, ACQ, and AQLQ scores between the two groups before treatment (all $P > 0.05$); after treatment 1 All indicators in the two groups were significantly better than before treatment, and all indicators in the asthma group were better than those in the overlap group (all $P < 0.05$).

Conclusion: BT treatment can not only improve the lung function and quality of life of asthma patients, but also improve the lung function and quality of life of asthma patients with COPD, but BT treatment is more effective for asthma patients.

PO-017

Analysis on the expression profile of circular RNAs in lung adenocarcinoma with pleural metastasis and tuberculous pleurisy

Xiao,Qiang、Liang,Luoqi、Liu,Bin、Tan,Shukun、Rong,Fu、Li,Xi、肖强
Department of Respiratory， Shunde Hospital， Southern Medical University (The First People’s Hospital of Shunde Foshan)

Objective: Lung adenocarcinoma pleural metastatic pleurisy (LAP) and tuberculous pleurisy (TBP) are two common causes of pleural effusion, but their pathogenesis is not completely clear, and it is difficult to distinguish them clinically[1]. Circular RNAs (circRNAs) are stable and conserved non-coding RNAs. Dysregulated expression of circRNAs was considered to be implicated in many diseases[2]. Here, we aimed to compare the differential expression of circRNAs between LAP and TBP.

Methods: RNA sequencing was applied to detect circRNA expression and the results were validated by reverse transcription - quantitative polymerase chain reaction. Meanwhile, receiver operating characteristic (ROC) curve was calculated to evaluate the predictive power of the selected circRNAs for identifying LAP and TBP. In addition, biological function of differentially expressed RNAs was predicted by genetic ontology and the Kyoto Encyclopedia of Genes and Genomics approach analysis.

Results: Compared with TBP, a total of 85 differentially expressed circRNAs were detected in LAP. Specifically, hsa_circ_0002688 was confirmed to be increased, while hsa_circ_0001240 was decreased in LAP samples (Figure). ROC analysis suggested that hsa_circ_0001240 had potential value for distinguishing LAP from TBP, followed by hsa_circ_0002688. Bioinformatics analysis indicated that Endocrine resistance, Axon guidance, Focal adhesion, ErbB signaling pathway, NF-kappa B signaling pathway and Toll-like receptor signaling pathway were potentially regulated by these aberrantly expressed circRNAs.

Conclusion: This work illustrates that some aberrantly expressed circRNAs were potential biomarkers for identifying LAP and TBP in pleural effusion disease.

PO-018

Continuous non-invasive PCO2 monitoring to detect apnea episodes and hypoventilation during flexible bronchoscopy under sedation

Liu,Yanan
Peking university first hospital

Objective: Background: Apnea and hypoventilation developing as results of over sedation is a potential clinical problem in patients undergoing flexible bronchoscopy (FB) under sedation. However, the incidence of hypoventilation and apnea during induction of bronchoscopic sedation is unknown. The aim of this study was to investigate the frequency of hypoventilation and apnea episodes during FB under sedation in the clinical setting by end-tidal capnography.

Methods: Methods: This study was a prospective study maintained database and medical records, including capnographic data, from June 2017 to June 2019. We enrolled patients who were sedated with midazolam and underwent diagnostic FB under transcutaneous PCO2 (PtcCO2) measurements monitoring. Apnea was defined as

cessation of airflow for more than 6s.

Results: Results: Data from a total of 153 eligible patients were analyzed. 76 patients had apnea during the FB under sedation. 117 patients occurred hypoxemia with hypercapnia. After the inspection, CO2 level return to baseline. Furthermore, 35 apnea episodes (22.9%) were followed by a rise of the CO2 by ≥4% from the baseline with out COPD or asthma. Operating time was associated with hypercapnia.

Conclusion: Conclusions: In this study, transcutaneous PCO2 revealed the occurrence of apnea episodes and hypercapnia at a high frequency in patients undergoing FB under sedation in the clinical setting.

PO-019

Developments in Interventional Pulmonology

Meng,Wenyan、孟文彦
Beijing Tongren Hospital, Capital Medical University

Objective: With the development of new materials and technology, bronchology and interventional pulmonology has grown rapidly and we use interventional pulmonology widely from minimally invasive diagnostic to some therapeutic procedures including airways, lungs, and pleura.In this paper, the progress of interventional pulmonary and the latest research results were summarized in the following aspects.

Methods: We describe the developments and changes in the field, new tools including virtual bronchoscopic navigation,bronchoscopic transparenchymal nodule access,solitary pulmonary nodules,peripheral pulmonary lesions,one-way endobronchial valves and so on for the diagnosis and potential treatment.

Results: Interventional pulmonology is an invasive and considerably safe and efficient procedure.The increasing number of pulmonary diseases has intensified the requirements for innovation in the field of interventional pulmonology.

Conclusion: Interventional pulmonology is a relatively new field in pulmonary medicine,which needs physicians and teams joint effort to progress and invent more relevant developments.

PO-020

Long-Term Efficacy and Safety of the Dumon Stent for Benign Tracheal Stenosis: A Meta-Analysis

Chen,Difei、Li,ShiYue
The First Affiliated Hospital of Guangzhou Medical University

Objective: Objective: We conducted the first meta-analysis to evaluate the long-term efficacy and safety of the Dumon stent for benign tracheal stenosis.

Methods: Methods: A literature search was conducted using electronic databases such as PubMed, the Web of Science and the Cochrane Library for related trials. Statistical analyses were conducted to calculate the effective rate and incidence of complication by using either random-effect or fixed-effect models depending on data heterogeneity.

Results: A total of 395 patients from 8 studies were included. Analysis of efficacy revealed that stablity rate was 41.12% (95% CI, 34.85%-48.52%), and the removal rate is 40.74%(95% CI, 34.92%-47.53%) and 75.49%(95% CI, 70.89%-80.39%). With respect to the incidence of complications, the migration rate was 25.04% (95% CI, 17.52%-35.79%), granulation rate 15.66% (95% CI, 9.39%-26.11%) and incidence of mucus retention 23.82% (95% CI, 13.77%-41.20%).

Conclusion: The efficacy and safety of the Dumon stent for benign tracheal stenosis appears unsatisfactory.

Multicenter and prospective studies are needed to fully evaluate its effect. The Dumon stent is recommended as a remedy for surgery or for alleviatinge dyspnea before surgery.

PO-021

Retrospective analyse of patients submitted to bronchoscopy for the removal of a foreign body. Experience of a teaching hospital in Brazil - SP.

DE ARAUJO VEGA,NELSON1,2、Alejandro Vega Ortega,Hugo 2、Cesar Domingues Favara,Fabio 2、D'Almeida e Silva de Toledo Ramos,Rafaela Maria1、Sebba de Souza Vega,Elisa1
1. Centro Universit á rio Barão de Mau á
2. Hospital Santa Casa de Ribeirão Preto

Objective: To demonstrate the experience of a teaching hospital in the removal of foreign bodies via airway endoscopy.

Methods: We performed a retrospective study with descriptive analyses of data. This study was carried in the Santa Casa de Ribeirão Preto. Medical charts from June 2017 to June 2020, of patients submitted to bronchoscopy when suspected FB aspiration, were reviewed. The procedures were performed under general anesthesia or sedation, by the same surgical team. Rigid and flexible bronchoscopes were used. For rigid bronchoscopy, removal of the FB was performed with the aid of a foreign body forceps. When the flexible version was employed, a "basket" forceps was utilized. All patients submitted to airway endoscopy with a positive FB aspiration were included. Diagnostic endoscopies and those that did not have FB were excluded. Variables included for analyses were gender, age, origin, location of FB, type of FB, nature of FB, type of forceps, type of bronchoscope, removal at first or second endoscopy, and complications.

Results: From the 587 bronchoscopies performed during the studied period, 19 were included due to suspected FB aspiration. Four were excluded for not identifying a FB or because it was a diagnostic procedure. A total of 15 bronchoscopies, from 13 patients, were analyzed. Ten children and 3 adults were observed. Three patients were female and 10 were male. The most frequent location was the left lung. One FB was removed with a rigid endoscope and 12 with a flexible instrument. Two patients needed a second bronchoscopy for removal of the FB. Type and nature of the removed FB's were: 7 cases of organic material (peanuts and popcorn) and 6 cases of inorganic (rock, digital prosthetic key, tooth, metal chain, dental crown and birefringent material). None of the patients was from Ribeirão Preto. No patient needed a bronchotomy. There were no deaths or postoperative complications.

Conclusion: The removal of a FB through endoscopy requires specific training, a prepared anesthesia team, and appropriate endoscopic equipment. The association of rigid and flexible bronchoscopy improves the chances of a safe and accurate FB removal. In our study, using the combinations of both methods, the success rate was 100%.

PO-022

The predictive value of optical coherence tomography, computed tomography and tumor markers in identification malignant lung nodules and masses

Ma,Xiaoyu、Zhang,Wei、Zhang,Hong、Cheng,Yuan、Gong,Yuhong、Wang,Guangfa
Peking University First Hospital

Objective: To compare the value of optical coherence tomography(OCT), computed tomography(CT) and tumor markers in identification malignant lung nodules and masses.

Methods: Patients with peripheral lung nodules and masses in the Department of Respiratory and Critical Care of Peking University First Hospital from July 2019 to February 2020 were screened.Then patients included would underwent OCT, CT and tumor marker examinations.The value of identification malignant lung nodules and masses of these three methods were assessed.

Results: 45 patients with peripheral lung nodules and masses were screened and 31 patients were finally included. OCT accurately diagnosed the lesions in 26 cases. The total diagnosis rate was 83.9% (26/31), the sensitivity was 92.3% (11/13), and the specificity was 77.8% (14/18). CT accurately diagnosed the lesions in 22 cases. The total diagnosis rate was 73.3% (22/30), the sensitivity was 84.6% (11/13), and the specificity was 64.7% (11/17). Tumor markers accurately diagnosed the lesions in 19 cases. The total diagnosis rate was 73.1% (19/26), the sensitivity was 83.3% (10/12), and the specificity was 64.3% (9/14).

Conclusion: OCT is feasible to differentiate malignant lung nodules and masses from benign ones.AS a new diagnostic method,its sensitivity and specificity are higher than CT and tumor markers.

PO-023

Progress and review of clinical application of endobronchial cryosurgery

Lu,Ye、Chen,XuJun、卢晔
The Second Department of Respiratory Medicine, the Third Hospital of Xiamen affiliated to Fujian University of Traditional Chinese Medicine

Objective: Cryopreservation is a series of techniques implemented in the bronchial lumen through a flexible freezing probe under bronchoscope, including freezing and thawing and cryosurgery. It has the advantages of definite effect, safe and simple operation, less complications and low cost, and can be used in benign and malignant lesions of the airway. And thermal ablation and other methods play an irreplaceable role in the diagnosis and treatment of intracavitary rare diseases.

Methods: Cryopreservation including freezing and thawing and cryosurgery.

Results: It has the advantages of definite effect, safe and simple operation, less complications and low cost, and can be used in benign and malignant lesions of the airway.

Conclusion: thermal ablation and other methods play an irreplaceable role in the diagnosis and treatment of intracavitary rare diseases.

PO-024

A preliminary study on the value of intratracheal

temperature measurement in the diagnosis of lung cancer in 44 cases

Lu,Ye、Chen,XuJun、卢晔
The Second Department of Respiratory Medicine， the Third Hospital of Xiamen affiliated to Fujian University of Traditional Chinese Medicine

Objective： To explore the clinical value of intratracheal temperature measurement in screening and early diagnosis of lung cancer.

Methods： The clinical data of 44 patients who underwent bronchoscopic intratracheal temperature measurement in our hospital from October 2016 to September 2019 were collected, including 21 patients with lung cancer diagnosed by pathology as the experimental group and 23 patients without lung cancer as the control group. The temperature in the trachea was measured directly through the working channel of the tracheoscope, and the temperature difference between the main branch trachea, lobar bronchus, diseased bronchus and Carina was calculated by using a soft thermometer. The difference of temperature difference between the control group and the control group was compared.

Results： In the control group, the difference between the endotracheal temperature and the Carina temperature in the left lower lobe was the largest, while in the lung cancer group, the difference between the bronchial temperature and the Carina temperature in the lung cancer group was significantly higher than that between the left lower lobe and the Carina ($P < 0.05$).

Conclusion： The measurement of intratracheal temperature is expected to be a new method for low invasive screening and differential diagnosis of lung cancer.

PO-025

Correlation analysis of lower respiratory tract infection in

Cui,Jinghua
Guangdong General Hospital

Objective： Tracheal esophageal fistula (TEF) is an abnormal fistula formation between trachea and esophagus caused by various reasons.TEF has a very high mortality rate, most of which are caused by repeated aspiration and severe lower respiratory tract infection. To further understand the epidemiology of lower respiratory tract infection in patients with tracheal esophageal fistula.

Methods： The incidence of lower respiratory tract infection, high risk factors and common pathogens of tracheal esophageal fistula cases in our hospital were analyzed by searching relevant literature and analyzing the incidence of tracheal esophageal fistula cases.

Results： 1. Lower respiratory tract infection is common in patients with tracheal esophageal fistula, and the incidence is 83-100%.2. Risk factors of lower respiratory tract infection found in patients with tracheal esophageal fistula include: damage of normal airway structure, repeated aspiration;Long hospital stay, easy to find nosocomial infection;Repeated use of broad-spectrum antibiotics resulted in the emergence of drug-resistant bacteria;Poor nutritional status, reduced resistance;3. Bacteria and fungi are common pathogens of lower respiratory tract infection in patients with tracheal esophageal fistula; pseudomonas aeruginosa and Acinetobacter baumannii are common gram-negative bacteria; Staphylococcus aureus is common gram-positive bacteria; candida albicans is common fungi. Moreover, the incidence of multi-drug resistant bacteria increased with the length of hospital stay and the number of hospital stays.

Conclusion：The incidence of lower respiratory tract infection in patients with tracheal esophageal fistula is high and the interfering factors are complex.If present, broad-spectrum antibiotics should be used as soon as possible.

PO-026

The diagnosis value of rapid on-site evaluation during medical thoracoscopy

Xiao,kui
The Second Xiangya Hospital of Central South University

Objective: To investigate the diagnosis value of rapid on-site evaluation(ROSE) during medical thoracoscopy (MT) by studying the sensitivity, the specficity, diagnostic accuracy, positive predictive value ,negative predictive value and area under the ROC curve of ROSE and assessing intermodality agreement between ROSE and histopathologic diagnosis.

Methods: 154 patients who underwent medical thoracoscopy (MT) , thoracoscopic biopsy procedures and ROSE from July 2018 to July 2019 in The Second Xiangya Hospital of Central South University were retrospectively analyzed. The demographic characteristics, clinical manifestations, pleural fluid analysis, the manifestations of medical thoracoscopy, thoracoscopist' s preliminary diagnosis of macroscopic appearance at thoracoscopy, ROSE, histopathological diagnosis, and final clinical diagnosis of the patients were summarized. According to the final clinical diagnosis, patients were divided into two groups, group A consisted of patients with benign disorders and group B with malignancy. Statistical analysis was performed on different indicators of the two groups and draw the area under the ROC curve of ROSE.

Results: Among the 154 patients, 90 patients were malignant pleural effusion and 64 patients were benign pleural effusion. Malignant pleural effusion included malignant mesothelioma(3 patients), metastatic lung cancer(73 patients), metastatic extrathoracic cancer(9 patients), and lymphoma(5 patients). 84 patients with the final diagnosis of malignant pleural effusion were diagnosed by thoracoscopic biopsy procedures, 6 patients with the final diagnosis of malignant pleural effusion were diagnosed by repeat thoracoscopic biopsy procedures or other biopsy procedures. Compared with the pathological diagnosis,area under the ROC curve of ROSE was 0.938 ($P < 0.001$) , with a sensitivity of 90.48%, a specificity of 97.14%, positive predictive value of 97.44% and negative predictive value of 89.47%. The intermodality agreement between ROSE and histopathology was good (kappa = 0.870, $P < 0.001$).

Conclusion: ROSE during medical thoracoscopy has a high diagnostic efficiency for distinguishing benign from malignant pleural lesions. ROSE has a good consistency with histopathological diagnosis. It can provide effective guidance for the operation of medical thoracoscopy.

PO-027

Left main bronchus endovascular tortuosity caused by embolization of thoracic aortic pseudoaneurysm: case report and literature review

Xiao,kui
The Second Xiangya Hospital of Central South University

Objective: The left main bronchus endovascular tortuosity caused by the embolization of thoracic aortic pseudoaneurysm is very rare. In order to improve the clinician's understanding and treatment of the disease, we did this case report and literature review.

Methods: We analyzed the diagnosis and treatment of a patient with left main endobronchial varicose caused by embolization of thoracic aortic pseudoaneurysm, and reviewed the literature.

Results: This 78-year-old male was hospitalized for repeated cough and dysphagia for more than 4 months. On April 19th 2018, he came to our hospital for emergency treatment because of chest pain accompanied by ecchymosis in the anterior cervical region for two days, and the neck swelling was found through physical examination. The size of ecchymosis in the anterior cervical region was about 10cm × 10cm. He received a CTA examination and found the formation of distal malformation of the bronchial artery and huge pseudoaneurysm. On that day, the emergency interventional embolization was performed. After the operation, the patient's vital signs were stable and the symptoms were significantly improved. CTA reexamination on April 23rd showed high possibility of small branches of left lower pulmonary artery embolism. After MDT discussion, the panel suggested that he should not be given anticoagulation temporarily and the patient was discharged on April 29th. After discharge, the patient's cough and dysphagia gradually aggravated. On August 28th, the CTA reexamined in the outpatient department showed that the pseudoaneurysm of the bronchus artery in the original thoracic aorta (upper level of the trachea bifurcation) was narrower than before, and the present range was about 5.5cm × 3.5cm, with high-density metal shadow, sectional esophageal compression and stenosis was improved. In mediastinum, tortuous and thickened bronchial arteries still can be seen, and branch blood supply was seen in left internal mammary artery. On September 6th, bronchoscopy showed that the mucosa of lower part of the trachea, carina and right main bronchus were congested and swollen; the left main bronchus was obviously congested and swollen in the whole process, with rough surface; the middle part of left main bronchus was narrow, with two soft texture, smooth surface and no obvious pulsation lesions in it, which could be reduced when compressed by the bronchoscope. In order to clarify their nature, we punctured them with Olympus puncture needle, and a small amount of local bleeding occurred after puncture. This proved that the lesions in the left main bronchus were vascular disease, and more likely to be varicose veins. Because of the high risk of surgery, the family members of the patient gave up further treatment.

Conclusion: The left main bronchus varicose caused by embolization of thoracic aortic pseudoaneurysm has not been reported before. Other causes of endobronchial varicosis include single ventricular disease with liver congestion, pulmonary vein stenosis, pulmonary vein atresia, extrahepatic portal vein stenosis, cirrhosis, and portal vein thrombosis.

PO-028

The spring coil in the sheath fell off during endobronchial ultrasound-guided transbronchial needle aspiration(EBUS-TBNA): case report and literature review

Xiao,kui
The Second Xiangya Hospital of Central South University

Objective: The spring coil in the sheath fell off during endobronchial ultrasound-guided transbronchial needle aspiration(EBUS-TBNA) is very rare. This was the case when our department used EBUS-TBNA to diagnose a patient with moderately differentiated squamous cell carcinoma in 2014. In order to improve clinicians' understanding and treatment of this kind of patients, we did this case report and literature review.

Methods: The diagnosis of a patient with moderately differentiated squamous cell carcinoma during EBUS-TBNA were analyzed with literature review of the spring coil in the sheath fell off .

Results: The patient was a 69-year-old male, he went to our hospital in April 2014 for progressive dysphagia for more than 2 months. The nature of posterior mediastinal space occupying shown by lung CT in other hospital remains to be determined: Lung cancer? Esophageal cancer? The patient underwent an electronic bronchoscopy, which showed stenosis of the left main bronchus and the left lower bronchus. EBUS-TBNA was taken on the same day to confirm the diagnosis. The size of lymph nodes in group 7 was measured under EBUS, about 44.7mm×32.5mm. 3 nodes of group 7 were punctured under ultrasound guidance after fixing the puncture site. After the examination, the patient had no special discomfort and was diagnosed as moderately differentiated squamous cell carcinoma by postoperative pathology. The patient gave up further examination and treatment and went home. In July 2014, the patient underwent esophageal barium swallow and lung enhanced CT because of aggravating dysphagia. The examination showed that the posterior mediastinal space occupying was more progressive than that of the previous one. A week later, the patient came to our hospital for a reexamination of the electronic bronchoscope. The examination showed that there seemed to be foreign bodies incarcerated in the posterior inner wall of the left main bronchus, and yellow-white necrotic objects and other attachments could be seen on the surface. The posterior internal wall of the lower part of the left main bronchus showed changes of external pressure, and the mucosal hyperemia, swelling and hypertrophy of the opening of the left lower lobe showed changes of infiltration, easy to bleed by touch, and obvious stenosis of the lumen. The foreign body was removed with biopsy forceps under the electronic bronchoscope. After comparison, the foreign body was a spring coil shed from the EBUS-TBNA puncture needle sheath. Subsequently, reexamination of pulmonary enhanced CT showed no abnormal high density shadow in the posterior mediastinum.

Conclusion: According to the review of the literature, In recent years, there have been 3 cases of puncture needle rupture reported during EBUS-TBNA surgery, but it is the first case that the spring coil in the sheath falls off, andIt is suggested that we should be vigilant in carrying out EBUS-TBNA and timely check and verify it to avoid serious complications.

PO-029

Hematogenous disseminated tuberculosis was misdiagnosed as nephrotic syndrome with c ellulitis：case report and literature review

Xiao,kui
The Second Xiangya Hospital of Central South University

Objective： This paper reports a case of hematogenous disseminated tuberculosis misdiagnosed as nephrotic syndrome with cellulitis and treated with Linezolid. In order to improve clinicians' understanding and treatment of the disease, we summarized the clinical characteristics of the disease and reviewed the literature.

Methods： a case report and literature review

Results： The patient was a 54-year-old female, she went to our hospital on May 2, 2015 for repeated fever for more than 5 months and another week.Six months ago, the patient began to have red swelling and heat pain in the right lower extremity. And five months ago, the patient developed fever with chills, body temperature up to 41.5 ℃ , and occasionally coughed and expectorated sputum. The patient was diagnosed as "cellulitis of the right lower extremity, nephrotic syndrome" in the local hospital. The anti-infection treatment of piperacillin tazobactam sodium, levofloxacin and cefepime was not effective.The patient was hospitalized in the nephrology department of the local hospital for three times before visiting our hospital.On January 5, 2012, the patient was given meropenem in the department of Nephrology for the first time for 6 days, but it failed. After 10 days of intravenous injection of Linezolid 0.6 Q12h, the pain in the right lower extremity improved and the temperature dropped to normal. Subsequently, the patient was discontinued after taking linezolid 0.6q12h orally for 2 weeks.After 10 days of drug withdrawal, the above symptoms recurred, and the patient was re-admitted to hospital and given Linezolid 0.6 Q12h intravenous drip for 7 days, followed by the oral administration of Linezolid 0.6 Q12h for 2 weeks. The symptoms recurred one week after withdrawal of the drug.When the patient was admitted to the department for the third time, it was considered that "fever causes: high possibility of connective tissue disease". "methylprednisolone 40mg Qd" was administered for half a month, and the patient's body temperature returned to normal. After discharge, the patient continued to receive meprednisolone tablets orally and was given linazolamide 0.6q12h orally for 5 days.During the course of hormone reduction, the patient developed fever again, presenting the same symptoms, so he went to the respiratory department of our hospital.Previous history: The patient was diagnosed as nephrotic syndrome (mild lesions) by renal biopsy 2 years ago, and had been taking hormone therapy and gradually reducing the dose to 5mg Qd. During the treatment, the patient's blood glucose increased and was given oral medication to control the blood glucose.Admission physical examination: T 38.8 ℃ . The skin on the radial side of the left forearm and the outer side of the right thigh was red, with palpable mass and tenderness. The respiration of both lungs is coarse, without rhonchus or crackles. Diagnosis on admission: 1. Fever: high possibility of infection, connective tissue disease to be deleted; 2. Nephrotic syndrome.After admission, blood routine examination: white blood cell 5.5×109/L, neutrophil 0.80, hemoglobin and platelet were normal. Routine stool and urine tests were normal.Liver and kidney function were normal. Blood sedimentation 34 mm/h. PPD skin test negative, tuberculosis antibody negative, tuberculosis spot test negative.Rheumatism complete set, lupus complete set no abnormality. CRP 106.0 mg/L. PCT 0.14ng/ml. Tumor markers: ferritin 536.57ng/L, the rest were normal. Blood culture was negative for many times. Sputum culture on May 8 showed haemophilus influenzae (sensitive to Meropenem and resistant to most cephalosporin drugs), blood fungus was negative for many times, and bronchial lavage solution GM test was negative. Repeated sputum acid-fast staining was negative. Body surface mass B ultrasound: the right thigh subcutaneous fat layer patchy low echo area, considering the possibility of inflammation; Acoustic image of subcutaneous tissue edema in the dorsal left forearm. B - scan of abdomen showed no abnormality. Echocardiography shows a small amount of pericardial effusion. Lung CT: diffuse distribution of a large number of patchy shadows in both lungs, a small amount of bilateral pleural effusion, high possibility of connective tissue lesions. Bronchoscopy showed slight changes in bronchial mucosa inflammation in the left upper lobe. During the operation, the secretion was

cultured and susceptibility test in the left tongue lobe, and 3 brush slices were sent for gram staining, acid-fast bacilli and fungi, respectively. Irrigation was conducted at the lateral branch of the right middle lobe, and the lavage fluid was sent for GM test and pathological cytology respectively. No abnormalities were found in the above examinations.Biopsy of the subbasement of the posterior left lower lobe shows inflammatory changes, alveolar wall thickening, fibrosis, no necrosis, and acid-fast staining (+). The patient was transferred to a tuberculosis specialist hospital for further treatment on 18 May. After the patient was transferred to the hospital, the sputum smear showed acid-fast staining (+), and the skin biopsy on the right thigh showed chronic inflammatory changes and acid-fast staining (+). Intracranial magnetic resonance imaging (MRI) showed multiple lesions scattered in the brain, which suggested the possibility of tuberculous encephalitis. Cerebrospinal fluid examination revealed tuberculous meningitis. Final diagnosis: 1. Hematogenous disseminated tuberculosis (lung, brain, meninges, skin), smear positive, initial treatment; 2.Nephrotic syndrome. After 16 days of "HREZ" combined with "isoniazid" intrathecal injection of antituberculous treatment, the patient's body temperature decreased to normal.

Conclusion: Linezolid is mainly used to control the infection caused by vancomycin-resistant gram-positive cocci. Recent studies have shown that linezolid has good anti-mycobacterium tuberculosis effect and strong antibacterial activity against drug-resistant strains. In clinical practice, if the cause of fever in the immunosuppressed host is unknown, gram-positive bacterial infection should be considered. If linazolamide is effective at the initial stage of treatment and has completed the treatment course but has repeated recurrence after drug withdrawal, the possibility of tuberculosis infection should be highly vigilant, and invasive examination should be conducted timely to further clarify the diagnosis so as to avoid misdiagnosis.

PO-030

Primary neuroblastoma of lung: case report and literature review

Xiao,kui
The Second Xiangya Hospital of Central South University

Objective: Primary neuroblastoma of lung is very rare. This was the case when our department diagnosed a patient with Primary neuroblastoma of lung in 2014. In order to improve clinicians' understanding and treatment of the disease, we did this case report and literature review.

Methods: We analyzed the diagnosis and treatment of a patient with Primary neuroblastoma of lung, and reviewed the literature.

Results: The patient was a 15-year-old female, she went to our hospital on April 26, 2014 for cough, hemoptysis, shortness of breath for 20 days and chest pain for more than 10 days. In early April 2014, the patient presented paroxysmal pharyngeal itching, cough and hemoptysis with dark red blood clots and occasional white necrotic tissue. The patient also felt dyspnea after climbing 4 floors and running, no fever, headache and other discomfort, and no obvious relief after taking cold tablets, amoxicillin and other drugs. More than 10 days ago, the patient presented left underarm pain, which was persistent swelling pain, aggravated after deep inspiration, and alleviated when supine and left lateral decubitus. There was no improvement after infusion of anti-infection treatment in the local hospital, so he came to our hospital for further treatment. Admission physical examination: T 36.5℃ , P 98 times/min, R 20 times/min, BP 116/52mmHg. Normal growth and good nutrition. There was no palpable enlargement of superficial lymph nodes throughout the body, left respiratory movement was weakened, verbal chatter was weakened, percussion dullness, left middle and lower lung respiratory tone was low, and a small amount of moist rales could be heard. The remainder is normal. After admission, lung enhanced CT scan showed a large soft-tissue density mass shadow in the left lung near the hilum, with a maximum cross-section of about 75mm×77mm, irregular shape, uneven density, unclear boundary and unclear boundary with mediastinal enlarged lymph nodes. Patchy, high-density shadows with blurred edges are seen around the mass. The left main bronchus, left upper lobe bronchus and left lower dorsal segment bronchus were

narrowed. The left pulmonary artery is circumferential, and the right lung is not significantly abnormal. Enlarged lymph nodes are seen in the mediastinum. Curved fluid density shadows were seen in the left thoracic cavity. Elevation of the left diaphragm. The spleen is large, up to 9 costal units. Diagnostic considerations: 1. Left central lung cancer with mediastinal lymph node metastasis, obstructive atelectasis and obstructive pneumonia, possible left pulmonary artery invasion, a small amount of left pleural effusion. 2. splenomegaly. After admission, relevant examinations were improved: Blood routine examination: WBC 10.25×109/L, N% 75.9%. Routine defecation and urination were normal. Liver and kidney function, electrolyte and PPD skin test were normal, CRP was 9.24mg/L, and tumor marker AFP was 125.63ng/ml. B-ultrasound-guided lung puncture biopsy was performed. The postoperative pathology showed :(left lung) broken, with a total rice grain size and a few cells as small round cells, showing atypia. Immunohistochemical: CD45R0（±），CD79a（+），CD20（-），CD1a（-），MPO（+），CK（-），TdT（-），Ki-67（++），CD3（+），Inhibin α（-），TTF-1（+），CD117（-），AFP（-），PLAP（-），Syn（-），S100（-），CD56（-）. It is consistent with small round cell malignancy and is considered in combination with clinical neuroblastoma.

Conclusion： According to the review of the literature, neuroblastoma usually occurs in the retroperitoneum, abdomen and posterior mediastinum. Primary neuroblastoma of lung is very rare. Clinicians should be vigilant in clinical work and timely improve pathological examination to avoid misdiagnosis and missed diagnosis.

PO-031

Failure and recurrence of primary airway sarcoma treated with PDT: a case report

Zhang,Qun、Li,Fengjuan、Xu,Wei、Xu,Yanling、张群
The Second Affiliated Hospital of Jilin University

Objective：Clinically, for some patients who are contraindicated or unable to operate,

photodynamic therapy or combined with APC can quickly and effectively solve the airway obstruction and relieve dyspnea;

Methods： A 76 years old female was admitted to emergency department for 2 months due to cough, expectoration and dyspnea. Blood gas analysis showed type 2 respiratory failure. Lung CT showed the main airway tumor (Fig. A). Fiberoptic bronchoscopy showed that the main airway tumor (about 1.0 cm from glottis) was about 2 cm in length (Fig. B1-2). Because of the obvious obstruction of the main airway, the tumor was removed by APC to relieve the symptoms of dyspnea and PDT was performed(Fig 3-6). One month later, Fiberoptic bronchoscopy showed that the tumor blocked the main airway again. tumor recurrence was considered (Fig.B7-8).

Results： the pathological results of the patient are mainly airway sarcoma, and PDT treatment shows failure and recurrence. The specific reasons are considered as well as the distribution of photosensitizer in the tumor, the microenvironment of the tumor, the location and staging of the tumor itself [11]

Conclusion： It is controversial whether PDT should be performed again after the first treatment failure, but local radiotherapy should be considered.

PO-032

Experience of first aid in hospital about a case of asphyxia caused by massive hemoptysis of tuberculosis

Lu,Jin1、Huang,Han ping1,2、鲁进
1. Third Hospital of Ezhou City in HUBEI province
2. Wuhan Jinyintan hospital

Objective: Through the description of the hospital emergency treatment of massive hemoptysis of tuberculosis,to accumulate the first aid experience of massive hemoptysis in hospital.

Methods: Though a case of pulmonary tuberculosis was treated in hospital. The severe hemoptysis caused asphyxia. The treatment of trachea catheterization under fiberbronchoscope and ventilator mechanical ventilation was reviewed in detail.

Results: The asphyxia symptoms of the patients improved obviously, the blood oxygen saturation increased, the vital signs recovered and the rescue was successful.

Conclusion: Through the retrospective analysis of massive hemoptysis cases of pulmonary tuberculosis, under the guidance of fiberbronchoscope, trachea catheterization combined with ventilator mechanical ventilation can timely and effectively unblock the blocked trachea, quickly relieve the symptoms of asphyxia, and win time for the follow-up intervention of bronchial artery embolization, which is worth learning and promoting. At the same time, through summarizing the relevant experience, improve the emergency response ability and reduce the risk The risk of complications and death caused by blood is conducive to the emergency treatment of patients.

PO-033

The Efficacy of Balloon Dilatation in Clinical Improving Period for Patients Who Suffered from Actively Caseating Endobronchial Tuberculosis and Central Airway Stenosis

Luo,Linzi、Xiao,Yangbao、罗林紫
Hunan Chest Hospital

Objective: To investigate the efficacy of balloon dilatation performed for patients who suffered from actively caseating endobronchial tuberculosis (EBTB) and central airway stenosis in clinical improving period who’s bronchus has not formed mature scar tissue.

Methods: A total of 152 tuberculous unilateral main bronchus stenosis patients who received treatment in Hunan Chest Hospital from January 1st 2014 to December 31st 2018 were included in this study. All patients received routine anti-tuberculosis chemotherapy. Sixty-four of them who suffered from actively caseating EBTB and unilateral main bronchus stenosis received cryotherapy and endobronchial isoniazid (INH) administration till the caseating necrosis in stenotic bronchus was disappeared and ulcers were recovered, and then received balloon dilatation combined with cryotherapy, were test group. Eighty-eight of them who suffered from fibrostenotic EBTB received balloon dilatation combined with cryotherapy were control group. We analyzed the efficacy and complications after treatments.

Results: The lung re-expansion rate after treatment in test group (74.0%) was higher than the control group(37.%), and the differences were statistically significant (c2=14.094, $P < 0.001$). The 6-month re-stenosis rate in test group (10.9%) was lower than control group (30.7%), and the differences were statistically significant (c2=8.318, P=0.004). The differences of diameter and diameter variation after balloon dilatation, immediate effective rates, average times of balloon dilatation and procedure-related bleeding ($<$ 10 ml) rates, chest pain rates had no statistical

signification in two groups. Severe complications including fatal bleeding (>100 ml) and mediastinal emphysema did not occur during our procedures.

Conclusion: Performing balloon dilatation for patients who suffered from actively caseating EBTB and central airway stenosis in the clinical improvement period, when caseous necrosis tissue disappeared and ulcers were recovered, not only helps to perform interventional procedures on distal bronchus in time, increase the rate of lung re-expansion, can also reduce the rate of re-stenosis after 6 months, so it is effective and safe.

PO-034

Value of fiberoptic bronchoscopy in diagnosis and treatment of plastic bronchitis in children

Cheng,Xing、Wang,Qi、Chen,Min、Sun,Yongfeng、Xu,Hui、Jin,Rong、程星
Guiyang Children's Hospital

Objective: To explore the value of fiberoptic bronchoscopy in clinical diagnosis and treatment of plastic bronchitis.

Methods: retrospective analysis of the data of 58 children with confirmed plastic bronchitis admitted in our pediatric ward from march 2018 to march 2020. all the children were treated with fiberoptic bronchoscopy, including under-mirror lavage, brushing, clamp and so on. There were 35 males and 23 females, aged 14 on February ~, with an average age of 2 years and 4 months. There was no statistical difference in the general data of all children (P>0.05). by summarizing the data of clinical manifestation, imaging examination, laboratory examination index, bronchoscopy examination, etiology results, number of treatment under microscope and prognosis before and after treatment.

Results: Among the 58 children with plastic bronchitis, the symptoms of cough, some with fever, wheezing and dyspnea, a few severe children need ventilator-assisted ventilation, after bronchoscopy treatment, most of the children symptoms relief, signs disappeared, only a few critically ill children still retain airway sequelae and withdrawal difficulties. All the pulmonary CT in 58 cases were characterized by single or multiple lobe consolidation or atelectasis with pleural effusion, mediastinal and subcutaneous emphysema. pulmonary imaging abnormalities can be rapidly improved after bronchoscopy treatment. Laboratory examination showed that :58 cases of children with inflammatory indicators have increased in varying degrees, after treatment most patients The index of infantile inflammation decreased. Bronchoscopy showed hyperemia and swelling of trachea mucosa, mucus suppository partially or completely blocked the bronchial lumen in the diseased airway, resulting in poor ventilation, repeated lavage and aspiration, can suck out a large number of sputum suppository, partial lavage difficult, foreign body forceps clamp plastic shape, clamp out of the shape of the "tree branch" shape, up to 6 cm, can be seen multi-level branches, a large number of sputum suppository and plastic objects were sucked out, distal ventilation can be significantly improved. Mycoplasma pneumoniae, influenza A virus, adenovirus, Streptococcus pneumoniae, Klebsiella pneumoniae, Haemophilus influenzae, Pseudomonas aeruginosa, and white Candida albicans. After 58 cases of bronchoscopy ,2 cases died ,4 cases were discharged from hospital after giving up treatment, and the remaining 52 cases were all improved.

Conclusion: Plastic bronchitis is a critical respiratory disease, the etiology is unknown, more because of inflammatory factors stimulate the airway to form endogenous foreign bodies, blocking the lumen, resulting in ventilation dysfunction. The clinical manifestations were cough, fever and dyspnea. Imaging detection of the corresponding lung tissue without inflatable area, if the disease is not treated in time, will quickly lead to respiratory failure or even death. Children's fiberoptic bronchoscopy can accurately diagnose the disease by visual judgment of the lesion site, and remove foreign body in the airway by means of bronchoscopy clamp, lavage and so on, remove inflammatory stimulation, relieve airway obstruction and improve ventilation, the effect is remarkable The diagnosis is clear and the risk of poor health is low. Therefore, in addition to routine anti-infection, bronchiectasis and hormone therapy, fiberoptic bronchoscopy in children has gradually become a more scientific, safe and effective way to treat plastic bronchitis.

PO-035

Three Gastrointestinal System Examination-Induced Cases of Tracheal Foreign Body and Lung Injury (Case report)

Chang,Ligong、Fang,Surong、Tan,Yan、Gu,Wei、常立功
Department of Respiratory Medicine， Nanjing First Hospital

Objective: The popularization rate of barium meal (BE) examination and gastrointestinal endoscopy is considerably high at present, but the introduction of tracheal foreign bodies and lung injury triggered by these examinations have been scarcely reported.

Methods: Three typical cases—BE examination-induced aspiration (1 case), the flow of capsule endoscope into the trachea (1 case), and gastric acid aspiration pneumonia (1 case)—are summarised in this paper, and the pathogenesis and diagnosis and treatment process are analysed, aiming to attract high attention from colleagues in the related departments and reduce the occurrence of incidents similar to the introduction of iatrogenic foreign bodies in the lung and lung injury.

Results: Clinical information Case 1:The patient was an elderly man who had anastomotic stenosis after surgery for oesophageal cancer and then underwent oesophageal obstruction due to eating chicken. He found it difficult to even swallow water with mild bucking. Therefore, a gastroscopy was planned, and he experienced bucking again during the BE examination before the surgery. Barium exuded from the nostril, but his condition has improved after some rest. Next, foreign body dissection under gastroscopy was performed smoothly, and the patient developed a fever 2 h after the surgery. His body temperature dropped and then rose again after treatment with an anti-inflammatory drug. Then, a routine blood examination was carried out: WBC 6.41 × 109/L. The chest film indicated dispersive flocculent shades in two lungs, where compact spotted flocculent shades could be seen in the right lower lung; they were considered to be ‘inhaled barium’. Further, chest computed tomography (CT) was performed when the patient was admitted to the hospital: spotted high-density shades (more evident in the right lung) scattered in both the lungs. After admission to the hospital, the patient underwent tracheoscopy: many light yellow secretions could be seen in the right main bronchus and the basal segment and the dorsal segment in the right lower lobe; these secretions were cleared away through negative pressure drainage and lavage of the right lung. Thereafter, the body temperature of the patient went back to normal. The discharge diagnosis was barium aspiration pneumonia. Case 2:The patient was a young man who, after painless gastrointestinal endoscopy (right lateral position), coughed and developed a fever, accompanied with blood-stained sputum. The routine blood examination showed a WBC count of 17.93 × 109/L. After anti-infection treatment with moxifloxacin, the patient’s body temperature fluctuated at 38.2 ° C. In order to receive further diagnosis and treatment, the patient was admitted to our hospital and underwent a chest CT examination, showing a lesion in the left lung, considered to be an infection (either aspiration pneumonia or alveolar haemorrhage). Oral administration of the hormone was implemented, and bronchoscopy was completed after he was hospitalized. Bronchial mucosa hyperaemia and oedema could be seen in the right upper lobe and the left lower lobe, and haemorrhage and foreign bodies were not observed. A chest CT examination was performed again after hormonotherapy, and the focus was absorbed in comparison with before. The discharge diagnosis was gastric acid aspiration pneumonia. Case 3:The patient was an elderly man admitted to a local hospital because of his complaint of stomach ache. According to the evaluation by the local hospital, the patient might not tolerate enteroscopy; therefore, capsule endoscopy was performed, during which the patient underwent bucking; later, he complained of asthma and chest discomfort. A chest CT examination was immediately completed, indicating foreign bodies in the left principal bronchus. He was transferred to our hospital right away. After being admitted to our hospital, the patient accepted bronchoscopy in the emergency department. The capsule endoscope could be seen in the left principal bronchus and was taken out using a foreign body basket. Then, his coughing and chest distress symptoms have remitted. The discharge diagnosis was the presence of foreign bodies in the left principal bronchus.

Conclusion: Discussion Cases of the introduction of tracheal foreign bodies and aspiration lung injury are considered as emergency and severe cases. Most patients need immediate diagnosis and treatment, and some may have latent pathogenesis [1]. Therefore, the diagnosis and treatment process can be difficult. The introduction of tracheal foreign bodies or inhalation lung injury is common in children [2-3]. The attack of this illness does not vary with age among adults. These foreign bodies are mainly food and industrial products and are mostly observed in the right lung [4]. They can be diagnosed by combining the related medical history and imaging characteristics. Bronchoscopy is the most common method used to diagnose and treat the presence of tracheal foreign bodies or inhalation lung injury. Furthermore, an iatrogenic tracheal foreign body or inhalation lung injury is commonly seen in tracheotomy patients, patients undergoing surgery of any of the five sense organs, and some patients accepting interventional respiration treatment. However, few reports have involved the introduction of BE and gastrointestinal endoscopy-induced iatrogenic tracheal foreign bodies or inhalation lung injury [5-6]. As a physician practicing respiratory intervention, the author made a retrospective analysis of three typical BE and gastrointestinal endoscopy-induced cases of the introduction of iatrogenic tracheal foreign bodies or inhalation lung injury, expecting to attract high attention from the related departments. These cases suggest that it is particularly important to complete a comprehensive preoperative evaluation, to strengthen technical and vocational training and education for different positions, to consolidate the consciousness of occupational risks, to reduce the introduction of iatrogenic tracheal foreign bodies or inhalation lung injury, and to raise vigilance. The emphasis should be laid on prevention, and in addition, once any foreign body or injury is found, it should be immediately treated to avoid the patient’s condition from worsening.

PO-036

Analysis of curative effect of APC combined with cryotherapy on 42 patients with airway tumor under bronchoscope

Sun,Simin、Jin,Yifeng
Yijishan Hospital of Wannan Medical College

Objective: To explore the value and safety of bronchoscopy argon plasma coagulation (APC) combined with cryotherapy for airway tumors.

Methods: A retrospective analysis of 42 patients with airway tumors who underwent bronchoscopy APC combined with cryotherapy in the Department of Respiratory Medicine of Yijishan Hospital from October 2018 to June 2020, all patients were treated by bronchoscopy based on medical treatment. Coagulation (APC) combined with cryotherapy, analysis of clinical symptoms before and after treatment, pulmonary CT manifestations, bronchoscopy findings, lung function results and breathlessness classification, reference to the literature to determine the effect of airway recanalization: ① fully effective: bronchial The endoluminal lesion was completely cleared and the function returned to normal; ② Partially effective: more than 50% of the narrowed lumen was reopened, the functional examination was generally normal, and the patient's subjective symptoms improved; ③ Mildly effective: the stenosis was less than 50% improved, but after drainage, the stenosis Dissipation of inflammation in the distal lung; ④ Invalid: There is no evidence of subjective and objective improvement clinically; treatment efficiency = (completely effective + partially effective) / total number of cases × 100%, to evaluate clinical efficacy and safety.

Results: 1.Of the 42 patients with airway tumors, 17 had lung squamous cell carcinoma, 3 had lung adenocarcinoma, 4 had small cell lung cancer, 4 had bronchial endometrial tuberculosis, 2 had lung sarcomatoid carcinoma, and 2 had esophageal cancer with airway metastasis. , 1 case of bronchial serous adenoma, 1 case of pulmonary adenoid cystic carcinoma, 1 case of pulmonary soft synovial sarcoma, 1 case of pulmonary neuroendocrine carcinoma, 1 case of bronchial amyloidosis, high-grade intraepithelial neoplasia of lung squamous epithelium 1 One case, one case of non-small cell carcinoma, one case of pulmonary hamartoma, and two cases of airway granulation tissue formation. 2.Forty-two of the 42 patients successfully completed bronchoscopy argon plasma coagulation (APC)

combined with cryotherapy. The number of treatments ranged from 1 to 9 times. Only 2 patients finally stopped the operation due to intolerance. Efficacy analysis: 6 cases were completely effective, 24 cases were partially effective, 7 cases were mildly effective, 3 cases were ineffective, and the total effective rate was 71.43%. Chest tightness, cough, hemoptysis and other symptoms of patients with effective treatment were significantly relieved. Bronchoscopy and CT of the lung showed that the airway cavity diameter was enlarged, and lung function related indicators and shortness of breath scores were improved. 3.The intraoperative adverse reactions of patients who tolerated interventional therapy were mainly irritable cough, a small amount of bleeding, and transient oxygen saturation. The postoperative adverse reactions were mainly cough, blood in the sputum, hoarse voice, and no pneumothorax or infection spread. , Severe bleeding and other serious complications.

Conclusion: Bronchoscopy APC combined with cryotherapy has a good short-term effect on benign and malignant tumors growing in the airway. Multiple treatments can achieve a good long-term effect. It is safe, repeatable, and operable. Effective relief of symptoms, can improve patients' life and treatment, it is worth further clinical promotion.

PO-037

Comparison of safety and efficacy between ultrasound-guided and CT-guided transthoracic needle biopsy: a meta-analysis

li,fei、Kong,Jinliang、Wang,Ke、Bao,Chongxi、Su,Yan、Liu,Si
Department of Respiratory Medicine, the First Affiliated Hospital of Guangxi Medical University, Nanning, Guangxi, China

Objective: Objective: Transthoracic needle biopsy (TTNB) is an important method to diagnose chest diseases. Image-guided transthoracic needle biopsy plays an important role in diagnostic performance, but few works of literature report the safety and effectiveness of transthoracic lung biopsy guided by ultrasound (US) and computed tomography (CT) currently. The purpose of this article is to use meta-analysis to evaluate the difference between image-guided methods（ultrasound and CT）on transthoracic needle biopsy, explore the safety and effectiveness of transthoracic needle biopsy, provide a reference for the selection of clinical diagnosis strategies.

Methods: Methods: Eligible studies were retrieved from the PubMed, EMBASE, Cochrane Library, Web of Science, and CNKI databases. The retrieval time is from database establishment to April 31, 2020. The data of diagnosis rate and complication rate of the ultrasound group and CT group were independently extracted by two people. After a cross-review of the literature and quality evaluation, RevMan5.3 software was used for statistical analysis.

Results: Results: This meta-analysis includes 10 studies,and includes 1905 results information about transthoracic needle biopsy.In this analysis results: the overall diagnostic rate of transthoracic needle biopsy , ultrasound group is higher than CT group (OR = 2.24, 95% CI: 1.52 ~ 3.30, p <0.0001).the adherent lesions diagnostic rate of transthoracic needle biopsy,ultrasound group is higher than CT group (OR=1.63, 95%CI: 1.04~2.57, p=0.03). postoperative pneumothorax complication rate of CT group higher than that ultrasound group (OR = 0.24, 95% CI: 0.15 ~ 0.36, p <0.00001). postoperative bleeding of CT group higher than ultrasound group (OR = 0.29, 95% CI: 0.12 ~ 0.70, p = 0.006).

Conclusion: Conclusion: Ultrasound group has a higher overall diagnosis rate in transthoracic needle biopsy than CT group.ultrasound group has a higher diagnostic rate in adherent lesions transthoracic needle biopsy than CT group. ultrasound group can reduce the incidence of postoperative pneumothorax and bleeding complication.

PO-038

The Guiding Function and Questionnaire Survey of the Manual Mapping Method in EBUS-GS for peripheral pulmonary lesions

Tong,Run1、He,Shun2、Wang,Guiqi2、Zhang,Lei2
1. Center of Respiratory Medicine， China-Japan Friendship Hospital; National Clinical Research Center for Respiratory Diseases
2. National Cancer Center/National Clinical Research Center for Cancer/Cancer Hospital， Chinese Academy of Medical Sciences and Peking Union Medical College

Objective: EBUS-GS guided biopsy or brushing plays an important role in the clinical diagnosis of peripheral pulmonary lesions (PPLs) [1-2]. Different guiding technologies combined with EBUS-GS can lead the bronchoscope and improve the diagnostic efficiency [3-4]. The manual mapping method is one of the simple and low-cost guiding methods.

Methods: This manual mapping method mainly includes the bronchoscope physician drawing the route with a series of bronchial opening sketches and marking the leading bronchus at every bifurcation point based on thin-section computed tomography, to guide bronchoscope insertion and sampling (Figure 1). We performed a retrospective analysis of 157 PPLs who received the manual mapping method or virtual bronchoscope navigation (VBN) assisted EBUS-GS in the department of Endoscopy, National Cancer Center/ Cancer Hospital from November 2011 to March 2018. Their clinical data were carefully studied. Questionnaires were also conducted among bronchoscope physicians through WeChat in December 2019 to initially explore the clinical application value of the manual mapping method.

Results: 123 cases of the 157 PPLs were finally diagnosed with malignant diseases (including 96 cases of lung adenocarcinoma, 10 cases of squamous cell lung cancer, 11 cases of non-small cell lung cancer that could not be classified, 3 cases of small cell lung cancer and 3 cases of metastatic cancer). For malignant diseases, the diagnosis rate of EBUS-GS was 88.6% (109/123 cases), and the diagnostic rate was not significantly different from the guidance of the mapping method, comparing that to the VBN method (P=0.221). Then 70 of them with the information of time to find the lesion were further analyzed, and there was no significant difference in the time to find the lesions by manual mapping method and VBN method (P=0.076). The speed of finding the lesion was related to the size of the lesion (P=0.035), while there were no significant differences with clinical symptoms, the lesion character, the distribution of lung lobes, the use of fluoroscopy or not, the visibility of the lesion under fluoroscopy, the bronchial generations where the lesion is located, and whether adjacent to the pleura (P values are 0.878, 0.957, 0.689, 0.397, 0.820, 0.959, 0.892). 68 questionnaires were distributed with a recovery rate and effective rate of 100%. 94.12% of those questioned were attending doctors or above, and 58 of them were from tertiary hospitals. 91.18% of the respondents' hospitals have thin-layer CT examinations, 55.88% of the departments have more than 50 cases of bronchoscopy each month, while 86.76% of the hospitals do not have any endoscopic navigation system. 98.53% of the respondents are interested in this manual mapping method, 91.18% of the respondents think that this mapping method is convenient, and 75% of the respondents think that this mapping method could be mastered by 2 months training.

Conclusion: The mapping method can guide bronchoscopy, and the diagnosis rate of malignant diseases is comparative with VBN guidance. Moreover, this method is simple, low cost, and does not require special equipment. While improving the endoscopic diagnosis rate, it can also enhance the doctor's CT reading ability and is suitable for hospitals of all levels.

PO-039

B-lymphocyte deficiency and recurrent respiratory infections in a 6-month-old female infant with mosaic monosomy 7

Mai,Kailin、Chen,Xiaowen、Chen,Dehui
The First Affiliated Hospital of Guangzhou Medical University

Objective: Monosomy 7 is generally considered as an acquired cytogenetic abnormality within hematopoietic cells, and indicates an especially high risk of progression to bone marrow failure, myelodysplastic syndrome (MDS) or juvenile myelomonocytic leukemia (JMML). However, clinical outcomes of monosomy 7 vary from spontaneous remission, to relapse after hematopoietic stem cell transplantation.

Methods: We report a case of a 6-month-old female infant with mosaic monosomy 7 who presented with clinical and laboratory evidences of immunodeficiency.

Results: The patient had suffered from recurrent respiratory infections since she was born. Peripheral blood lymphocyte subsets revealed an extremely low level of CD19+ B lymphocytes (0.3~0.8%, normal range: 6.4~22.6%) and a decreased CD4/CD8 ratio (0.67~1.12, normal range: 1.4~2.0). Decreased serum levels of IgG (1.53g/L, normal range: 4.09~7.03g/L), IgA (0.10g/L, normal range: 0.21~0.47g/L) and IgM (0.26g/L, normal range: 0.33~0.73g/L) were detected, while complements were normal. Excepting transient neutropenia, routine blood tests were within normal limits. Clinical exome sequencing identified a de novo mosaic monosomy 7, while no pathogenic mutation associated with immunodeficiency was detected. However, peripheral blood cytogenetic analysis was failure to detect monosomy 7 due to the very few cell mitosis. Subsequent fluorescence in situ hybridization (FISH) identified a mosaic monosomy 7 in 58 cells within a total number of 100 cells, which was consistent with clinical exome sequencing. The patient was diagnosed with primary immunodeficiency disease (PID) due to mosaic monosomy 7. Intravenous treatment with multiple antibiotic agents and infusion of gamma globulin could control the patient’s respiratory infections effectively. A better understanding of PIDs will enable effective treatments and prevention of infections in these patients. The IKZF1 gene is located within chromosome band 7p12, and encodes a hematopoietic zinc finger transcription factor named IKAROS, which is expressed restricted to hematopoietic cells and the pituitary gland. IKAROS plays a critical role in controlling hematopoiesis, particularly the differentiation and proliferation of lymphoid cells. IKZF1 whole gene deletions can be the results of monosomy 7 or del (7p), and intragenic deletions (e.g. Δ2-8, Δ4-7). IKZF1 deletions lead to the gene haploinsufficiency, and would result in an autosomal dominant (AD) monogenic disorder of common variable immunodeficiency (CVID) (MIM#616873). The phenotypes of CVID were characterized by recurrent bacterial infections, mainly affecting the respiratory tract, decreased numbers of B cells and hypogammaglobulinemia, increased CD8+ T cells, and so on. In this report, the patient’s clinical manifestations and laboratory tests are highly coincident with CVID. Considerating of B-lymphocytes deficiency and mosaic chromosome 7 (1.6x), the mosaic rate of monosomy 7 or IKZF1 deletions was 40%, and resulted in clinical features highly consistant with CVID in a dominant-negative effect. Monosomy 7 is one of the most frequent chromosome abnormalities observed in childhood MDS, AML and B-ALL, in which it is associated with a relatively poor prognosis. IKZF1 expression is halved in MDS or leukemias with monosomy 7. Deletion of the IKZF1 gene is an oncogenic lesion exclusively in patients with BCR-ABL1-positive ALL with B+My phenotype. Besides loss of function of the IKZF1 gene caused by the whole or intragenic deletions, missense or nonsense mutations occurring in a position critical for DNA binding were observed (eg, N159S, R213X). Aa a result, IKZF1 gene variants were strongly linked to pediatric MDS and acute leukemias (AL). In this report, the patient with mosaic monosomy 7 (1.6x) represented the clinical phenotypes of IKZF1-associated monogenic disorder, whether she would develop to MDS or AL in the future should be followed up.

Conclusion : Except for variant types of single nucleotide variants (SNVs), small insertions and deletions (indels), CNVs could be analyzed by clinical exome sequencing with depth of coverage (DOC) methods. The CNV analysis for interrogating exonic deletions and duplications was based on published algorithms by comparing the normalized exonic

coverage depth of test samples versus that of controls. Several studies have reported that CNVs covering adequate exons on autosomes can be accurately detected using targeted panel sequencing data as using chromosomal microarray analysis (CMA). As a result, CNVs on autosomes evaluated by targeted panel sequencing or CMA was considered as reasonable. As for the mosaic chromosomes, karyotype analysis or FISH should be applied to verify the chromosome abnormality. In the present report, the mosaic monosomy 7 was verified by FISH, while karyotype analysis did not identify the mosaic variant due to a failure of cell culture. However, it is noticed that the clinical features of mosaic monosomy 7 are heterogeneous for the reason of different mosaic proportions.

PO-040

Value of fiberoptic bronchoscopic lavage in early stage of severe pneumonia

Cheng,Xing、Wang,Qi、Chen,Min、Sun,Yongfeng、Xu,Hui、Jin,Rong、程星
Guiyang Children's Hospital

Objective: To investigate the effect of bronchoscopic alveolar lavage on sputum bacterial clearance and disease progression in children with severe pneumonia.

Methods: retrospective analysis of 138 cases of severe pneumonia admitted in pediatric ward of our hospital from december 2018 to february 2020. according to whether or not the treatment was treated alveolar lavage treatment was divided into treatment group 70 cases and control group 68 cases. The control group was treated with routine anti-infective therapy, and the treatment group was treated with bronchoscopic alveolar lavage on the basis of routine anti-infective therapy. Data are analysed and measured in SPSS22.0 statistical software the material comparison was t and expressed as (x±s). if (0.05), the difference was significant and statistically significant.

Results: After treatment, the positive rate of sputum bacteria culture in the treatment group was higher than that in the control group, and the data between the two groups were significantly different (P<0.05); the removal rate of sputum bacteria in the treatment group was 83.4%, which was significantly higher than that in the control group (58.7.%)(0.05). Compared with the control group, the remission rate of fever, cough, shortness of breath, wheezing and other clinical symptoms in the treatment group was higher, the duration was shortened, the lung rale and atelectasis were obviously improved, the serum infection index white blood cell count, neutrophil percentage, C reactive protein, calcitonin level and so on decreased obviously, the blood gas analysis results showed blood oxygen saturation, arterial partial pressure of oxygen and oxygenation index improved significantly (P<0.05).

Conclusion: Fibrobronchial alveolar lavage can be safely used in children with severe pneumonia, which can help to improve the positive rate of sputum bacteria culture, guide early accurate treatment, improve the clearance rate of sputum bacteria, improve the clinical symptoms of children, shorten the course of disease and hospital stay. Severe pneumonia often occurs circulatory system involvement, manifested as weak pulse, heart rate accelerated, heart tone low blunt show running rhythm, cyanosis aggravated, lung rale increased. Severe may have hepatosplenomegaly, vein filling, limb edema and other manifestations of heart failure. The appearance of shock and peripheral circulation failure can be seen pale, dark and cold skin spots, capillary filling time extended, blood pressure drop, urine A reduction in volume may even result in DIC mergers. Mental depression, lethargy or irritability, serious disturbance of consciousness, papillary edema of optic nerve, coma, convulsion, and then can appear brain hernia, the child died of central respiratory failure. High fever headache, vomiting, irritability or lethargy, convulsion and coma can be seen when complicated with toxic encephalopathy. Children with severe pneumonia due to low immunity, it is easy to cause bacteria into the blood, and then produce multiple organ failure. On the one hand, ventilator assisted breathing is required. Children with significant hypoxemia and carbon dioxide retention can be assisted breathing ventilator to ensure the body's oxygen supply. On the other hand, children will compare Severe infection, should be given strong broad-spectrum anti-infection treatment, while paying attention to strengthen the protection of multiple organs.

PO-041

The Application of Bronchoscopic Cryotherapy in the Diagnosis and Treatment of Tracheobronchial Tuberculosis in Children

Zhang,Huishan1,2、Chen,Xipo1,2、Ye,Leping1
1. Peking University First Hospital
2. The Second Affiliated Hospital and Yuying Children's Hospital of Wenzhou Medical University

Objective: A retrospective analysis was made to the clinical data of 10 children diagnosed with Tracheobronchial tuberculosis (TBTB) by bronchoscopic cryotherapy. The clinical characteristics of patients and the efficacy and safety of therapy were analysed to explore the application value of bronchoscopic cryotherapy in children with TBTB.

Methods: The clinical data of 10 hospitalized children (6 males and 4 females, aged 1-3 years), diagnosed with TBTB and performed bronchoscopy, were collected and analysed, including endoscopic findings (type and lesion site), pathological biopsy results, and the methods, times, complications and efficacy of bronchoscopic cryotherapy.

Results: 1. Clinical characteristics: 3 cases had only fever (3/10); 4 cases of fever with cough (4/10); 2 cases of hemoptysis (2/10); 2 case of wheezing (2/10); 5 cases of tuberculosis symptoms of poisoning (such as night sweats or weight loss) (5/10), and fever patients had moderate to high fever at the beginning of the disease; no vaccinated scar for 4 cases (4/10). 2. Laboratory tests: 10 patients underwent PPD and the positive rate was 100%; Interferon-γ release assays all showed positive (10/10). 3. Performance under bronchoscopy: 4 cases were granuloproliferative type, 3 cases were ulcer necrosis type, 2 cases were lymph node fistula type and 1 case was inflammatory infiltration type. 9 cases had bronchial obstruction at different levels (9/10); 1 case had obvious congestion and edema of bronchial mucosa, but no obvious obstruction (1/10); 5 cases had caseous necrosis with granulomatous lesion (5/10); 3 cases had caseous necrosis (3/10); 1 case had granulomatous lesions (1/10). 4. Safety and efficacy: After 1-2 times bronchoscopic cryotherapy based on the systematic standard antituberculosis treatment, the completely blocked bronchial lumina in children with TBTB (3 cases of granuloproliferative type and 2 cases of lymph fistula type) were all recanalized with 100% effective rate, without any complications.

Conclusion: 1. The histopathological diagnoses of the biopsy with the bronchoscopy were all positive, suggesting that the bronchoscopy has an important diagnostic value for TBTB in children. 2. The most common types of TBTB in children were granuloproliferative and ulcer necrosis, followed by lymph node fistula type. 3. It had better efficacy and safety for children suffered from granuloproliferative or lymph node fistula TBTB, with bronchoscopic cryotherapy based on systemic standard antituberculosis treatment.

PO-042

Application of lidocaine aerosol in rigid bronchoscopy

Su,Yingxiao
JIANGXI CHEST (THIRD PEOPLE) HOSPITAL

Objective: To investigate the efficacy of lidocaine aerosol in rigid bronchoscopy

Methods: Sixty ASA 2-3 patients who were scheduled to receive rigid bronchoscopy combined with soft endoscopy were selected and divided into group A and group B with 30 cases in each group. Group A only used total intravenous anesthesia when hard mirror was inserted, and group B was given lidocaine aerosol at throat before induction. The hemodynamic levels of two groups before and after implantation were compared.

Results: There was no significant difference in blood pressure and heart rate between the two groups before implantation. The blood pressure of group A was higher than that of group B, and the heart rate was faster than that of group B ($P < 0.05$).

Conclusion: Oral spraying lidocaine aerosol before induction of general anesthesia can effectively reduce the stimulation during hard mirror implantation and maintain the stability of hemodynamics.

PO-043

Photodynamic therapy for metastatic malignant pleural effusion by VATS: A case report

shi,tiansheng、Chen,Zhongshu、Lin,Dongjin、Feng,Jianxiong、Xu,Zhihong、施天生
Jiangxi provincial chest hospital

Objective: MT is insufficient to treat metastatic MPE by PDT due to plerual adhesion. VATS can break the adhesion and get sufficient pleural space for PDT.

Methods: CASE PRESENTATION: A 77-year-old man was referred on September 17, 2019 with complaints of chest distress and dyspnea for 3 months and deteriorating for 10 days" . He got chest distress and shortness of breath 3 months ago without cough、sputum、 chills、 fever. Chest CT in local hospital revealed right massive pleural effusion and pulmonary infection. Close chest drainage was performed immediately and the symptoms were relieved. The symptoms exacerbated 10 days ago and referred to our hospital. After admission the pleural effusion (about 500 ml) was removed by thoracentesis, and a few atypical denocarcinoma cells were detected. The diagnosis of "right lung cancer with MPE" was considered. After his consent for treatment, VATS were performed for pleural biopsy and PDT. METHOD: The patient was given 2.5 mg / kg of hematoporphyrin injection intravenously after negative skin test on September 21, 2020 keeping out of the light. After 48 hours, VTAS was performed, the patient was positioned in a left decubitus position, a 1.0 cm trocar was inserted into in the 8th midaxillary intercostal for observation and 4 cm long incision in the 4th anterior axillary intercostal for operating. Operation revealed encapsulated serous pleural effusion, many pleural nodules in posterior chest cavity and supradiaphragm , and strong adhesion in the anterior mediastinum. During the operation, 100ml fluid was excavated, the adhesions were broken, the fibrin attached to the pleura was removed . The right chest cavity was totally exposed and PDT was performed with a total energy of 2400J followed by the biopsies of the parietal pleura. Finally A 32F chest tube was inserted in the observation position, Patients were instructed to avoid direct sunlight for 30 days.

Results: White necrosis was seen daily after the operation, and the Chest tube was removed on Day 10. Postoperative pathological: Metastatic pleural adenocarcinoma from pulmonary. Genetic testing finding no mutations. The patient declined followed radiotherapy and chemotherapy , he taken Chinese traditional medicine after discharged from the hospital. No recurrence of pleural effusion was observed so far by Ultrasound and Chest X-ray every 2

months.

Conclusion: Photodynamic therapy for malignant tumor factors include: photosensitizer, oxygen and light. Light is the key to its treatment. , MPE always have adhisions and necrosis in chest cavity which impeded PDT by MT. VATS can broken the troublesome adhisions, obliterate the necrosis, so the chest cavity can be fully exposed and PDT implemented succesfully. The illumination scope were covered all regions of the pleural cavity: apex, anterior chest wall, posterior chest wall, posterior mediastinum, posterior costophrenic sulcus, anterior costophrenic sulcus, and pericardium. It guarantees the treatment effect.

PO-044

An example effect analysis and literature review on the effect of argon knife under the hard mirror of lung malignancies, post-line stent implant ationand implant of cryotherapy and in situ opening of the radon laser burning stent

Gao,Yang1、Wang,Guang fa2、Ma,Xian jun1、Su,Ri na1、Li,Sui xia1、Li,Xue qin1
1. Baotou Medical College Second Affiliated Hospital
2. Peking University First Hospital

Objective: Many patients with advanced malignancies often experience severe breathing difficulties when admitted to hospital, the principle is smooth airways, improve ventilation, interventional therapy as a transition, to alleviate narrowness, for further treatment to provide opportunities. Baotou Medical College Second Affiliated Hospital in August 2018 admitted a case of malignant central airway narrow patients, after a hard mirror argon knife, cryotherapy post-stent implantation and radon laser burning stent in situ annotated patient ventilation improvement, pathological cues for small cell lung cancer, followed by standardized chemotherapy treatment.

Methods: Patients with airway obstruction and severe breathing difficulties, in situ openings through a hard-mirror argon knife, a post-line stent implant editing for cryotherapy and a laser burning stent

Results: Applying a laser to produce a point-like high temperature burn cover bracket, so that it produces a point-like burning hole, the laser burning bracket opening can ensure the airway-owned bronchial tract smooth, prevent complications

Conclusion: Surgical stent placement after breathing airway laser treatment and stent on-site reprocessing, membrane stent can support the airway, but due to the tumor position relationship, will block the airway belongs to the important bronchial branch, resulting in poor sputum drainage, serious lung failure, the application of the laser to produce a point-like high temperature burning caps, so that it produces a point-like burning hole, laser burning bracket can ensure that the airway bronchial venture saves smooth, prevent complications

PO-045

Negative pressure pulmonary edema with airway foreign body：clinical analysis of 7 children

Li,Qin、An,Shu-Hua
河北省儿童医院

Objective： To explore the clinical characteristics of negative pressure pulmonary edema (NPPE) in children with airway foreign body.

Methods： The clinical data of 7 children with airway foreign body complicated with NPPE in Department of Respiration, Hebei Children，s Hospital from 2018.01 to 2020.03 were analyzed retrospectively.

Results： Five boys and two girls in the 7 cases；the range of age was 1 to 3 years. There were 5 cases of NPPE types I and 2 cases of types II. Type I showed respiratory symptoms before removing foreign body, type II appeared several minutes after removing foreign body.All of the 7 cases had patchy exudates in lung CT. Most of the pulmonary edema sites in children with type I were contralateral or other segments in the ipsilateral， but the type II was significantly located in the same side of obstruction . The children with type I NPPE were given nasal catheter oxygen inhalation, and the type II were given CPAP ventilation, one of which was given diuretic. The respiratory symptoms disappeared within 24 hours and discharged followed recovery within 48 hours in all of the children.

Conclusion： The potential risk of NPPE in children who with airway foreign body can be diagnosed according to the history of foreign body obstruction, respiratory system symptoms, pulmonary vesicular sound, typical imaging characteristics of pulmonary edema . The pathogenesis, location and timing of type I and type II were different.. Giving the CPAP auxiliary ventilation and diuretic can achieve good therapeutic effect.

PO-046

Post Intubation Stenosis and Interventional Pulmonology Management – A Single Centres 2 Years' Experience

Alaga,Arvindran、Selvaraj,Navindran 、Ismail,Rosmadi、Nasaruddin,Mona Zaria 、Abdul Rahman,Jamalul Azizi
Hospital Serdang

Objective： Tracheal stenosis is an uncommon but serious complication in prolonged intubated and tracheostomy patients. As symptoms may not appear for weeks or months after extubation, it may be mistaken for asthma with dyspnoea and stridor. Treatment provided by interventional pulmonologists is gaining momentum in recent years. Aim of this study is : Evaluvate abd describe incidence of Post intubation Stenosis in our center. Evaluvate outcome of Interventional Pulmonology management in Post intubation Stenosis.

Methods： Retrospective analysis of cases of Post Intubation/Tracheostomy Tracheal Stenosis (PITS) referred to us in 2018 and 2019. Patients records were retrieved via electronic medical record and analysed via Microsoft Excel 2013

Results： All patients referred to us were females with mean age of 48 years. Presenting signs and symptoms were dyspnoea, rhonchi and failed extubation, The mean duration of intubation/ tracheostomy is 16 days (with range of 3 to 40 days). The lesions mean length is 2.1 cm and they are within the range of Cotton-Meyer Grade II -III. All of them underwent rigid bronchoscopy, mechanical dilatation and Mitomycin C application. One of them underwent the procedures thrice to be relieved from the symptoms, another 1 case were referred for surgical management while other 4 patients were asymptomatic after undergoing the procedure only once. No complications like pneumothorax or bleeding post procedure occurred. We noticed middle age female, with underlying diabetes mellitus who were intubated 7 days

or more highly susceptible to develop PITS

Conclusion: Patients with history of prolonged intubation or tracheostomy who presented with dyspnoea, rhonchi and failed extubation should be evaluated for postintubation tracheal stenosis. Interventional pulmonology techniques can be valuable first line treatment with better outcome in experienced centres.

PO-047

Analysis of 12 Cases of Benign Stenosis in Central Airway Cavity and Tracheal Endoscopic Interventional Therapy

Ma,Lanhong
People's Hospital of Xinjiang Uygur Autonomous Region

Objective: To analyze the causes of 12 cases of benign stenosis in central airway cavity, and discuss the risk factors and treatment of tracheal stenosis after intubation.

Methods: The clinical data of children with benign central airway stenosis in pediatric respiratory group of Xinjiang Uygur Autonomous Region People's Hospital from January 2018 to December 2019 were collected retrospectively, and their general clinical data, CT three-dimensional airway reconstruction image data and bronchoscope airway stenosis characteristics were analyzed. Various and combined interventional treatment methods are adopted for treatment.

Results: Results: Clinical data of 12 children with benign central airway stenosis were collected, including 7 males and 5 females, including 1 tracheoesophageal fistula, 1 webbed stenosis after tracheotomy, 1 right main and right upper stenosis after foreign body, and 9 tracheal stenosis after intubation. The main etiological components were tracheal stenosis after intubation (75%, 9/12), tracheoesophageal fistula (8.33%, 1/12), webbed stenosis after tracheotomy (8.33%, 1/12) and right main and right upper stenosis after foreign body (8.33%, 1/12). Compared with surgical resection of stenotic segment and end-to-end suture, it is a classic method for the treatment of tracheal stenosis. Various and combined interventional treatment methods are adopted for treatment, with remarkable curative effect.

Conclusion: The most common cause of benign central airway stenosis in children is airway stenosis caused by tracheal intubation or tracheotomy. Compared with surgical resection of stenosis and end-to-end suture, it is a classic method for the treatment of tracheal stenosis. Multiple and combined interventional therapies are adopted for treatment, with significant curative effect.

PO-048

7 cases of benign bronchostenosis were treated by rigid bronchoscopy

Lin,Chunlong、SONG,LIXIA 、ZHAO,XIXI
Department of respiratory and critical care medicine， Yueyang Second People's Hospital， Hunan Province 414000

Objective: To compare the advantages and disadvantages of rigid bronchoscopy in the treatment of bronchial stenosis with flexible bronchoscopy

Methods: There were 3 males and 4 females patients.which suffered from bronchostenosis. The average age was 37 ± 13 years. The oldest was 78 years and the youngest was 24 years from May 2016 ,12 to 2017. Among them 2 patients were with tracheal stenosis after tracheal intubation, 3 with pulmonary tuberculosis and 2 with fibroma of main trachea. The seven patients with bronchostenosis were treated by Rigid bronchoscope (Storz 22220055-3) with Invasive ventilator, in general anesthesia and muscle relaxant .In addition, 12 patients with benign airway stenosis were analyzed retrospectively. As were treated with by soft Bronchoscope ,there were 4 males and 8 females, aged 72 years and 21 years, T he average age was 32 ± 12years. The therapeutic effect of methods between rigid bronchoscope with soft Bronchoscope was compared .

Results: Comparing to soft bronchoscope, rigid bronchoscope can make course of the disease shorter significantly ($P < 0.05$), the patient feel comfortable, operate be easy accompanying with the increase of cost, the incidence of arrhythmia and laryngeal edema increased

Conclusion: rigid bronchoscope can maintain a certain gas channel, provide a larger visual field for the operator, and facilitate the operation in the airway.

PO-049

Treatment of 13 cases of central lung cancer with xigeima stent suspended iodine 125 radioactive particles

Lin,Chunlong、SONG,LIXIA、林春龙
Department of respiratory and critical care medicine， Yueyang Second People's Hospital， Hunan Province 414000

Objective: To observe the effect of xigeima stent suspended radioactive particles125 implanted into carinma trachea.

Methods: 13 cases of central lung cancer were diagnosed by pathology, 9 males and 4 females, with an average age of 66 ± 6.2 years. Among them there were 2 tumors of the main trachea, 3 tumors of the right trachea, 4 cases of primary left tracheal tumor, 4 cases carina with left and right airway . Under general anesthesia, muscle relaxants and invasive respiration, the patients were inserted into the trachea with Storz bronchoscope, and the Y-shaped or straight tube stent with radioactive iodine 125 particles was implanted with xigeima stent pusher.

Results: three months later, the lung function was improved and the tumor shrank or disappeared.

Conclusion: Xigeima Stent implantation can effectively solve the ventilation function, alleviate the disease and improve the quality of life; The implantation of iodine-125 radioactive particles has an obvious killing effect on lung cancer cells.

PO-050

Clinical report of 1 case of giant tracheoesophageal fistula treated by silicone stent implantation under rigid bronchoscope.

Lin,Chunlong、HUANG,HESONG、林春龙
Department of respiratory and critical care medicine， Yueyang Second People's Hospital， Hunan Province 414000

Objective: To understand the effect of implanting silicone stent under rigid bronchoscope in the treatment of giant tracheoesophageal fistula.

Methods: Aged male of 71 years with 4 months course of disease suffered from giant tracheoesophageal fistula. His trachea had a deformation and stenosis of 7.5cm long along with uneven and pipe diameter, and tissue defect about 6cm posterolateral , cartilage exposure. Under general anesthesia, controlled respiration, muscle relaxant and rigid bronchoscope, Y-type silicone stent (Y-type silicone stent, length: 9.5mm, diameter of main trachea: 18mm, left trachea: 2.5mm, right trachea: 1.5mm) was implanted for esophageal cancer tracheoesophageal fistulain by Using silicone stent pusher, following adjust stent, repeat balloon expansion in September 26, 2019.

Results: After stent implantation under rigid bronchoscope , the stent and airway have good adhesion, stability and no leakage. The patient's respiratory function is improved and can get out of bed.

Conclusion: Silicone stent can replace tracheal function for a short time, which is a good palliative treatment.

PO-051

Evaluation of the changes in alveoli elastic fibres with ageing using Confocal Laser Endomicroscopy

Feng,Jiaxin、Li,Shiyue、Zhou,Ziqing、Chen,Yu、Zhong,Shanghai、Chen,Xiaobo、Tang,Chungli、Feng,Jiaxin、Li,Shiyue、Zhou,Ziqing、Chen,Yu、Zhong,Changhao、Chen,Xiaobo、Tang,Chungli
广州医科大学附属第一医院

Objective: To explore the morphologic characteristics of alveolar elastic fibre in vivo，and how elastic fibre morphologic changes correlate with age using pCLE.

Methods: 503 bronchopulminary segments were examined in 82 non-smoker subjects with peripheral pulmonary nodules. All subjects underwent CT sacn，spirometry，and pCLE. We measured the alveolar opening elastic fibre fluorescence intensity and thickness、the alveolar distal elastic fibre fluorescence intensity and thickness 、alveolar elastic fibre extension length increase percentage（AL%） and analyze alveolar elastic fibre pattern. The association between elastic fibre morphologic characteristic at different area and age was evaluated.

Results: Both elastic fibre autofluorescence intensity and thickness of alveolar opening were significantly larger than alveolar distal（$p<0.05$）. Alveolar opening elastic fibre autoflurescence intensity correlated positively with age （$r=0.642$，$P<0.01$）; AL% correlated negatively with age and elastic fibre autoflurescence intensity（$r=-0.4581$，$p<0.01$ and $r=-0.3002$，$p<0.01$）. In the aged 18-39 group、40-54 group、55-79 group ，the mean ±SD autoflurescence intensity of the alveolar opening elastic fibre were 11.48±4.19、19.23±4.84、26.10±11.08 ,respectively（all $p<0.05$）; AL% were 81.85±51.31、44.54±31.79、35.96±23.88;the proportion of alveolar elastic fibre appear ruptured were 6.94%（10/144）、13.44%（25/186）、20.81%（36/173）, respectively（all $p<0.05$）. The proportion of alveolar elastic fibre appear ruptured in the autoflurescence intensity of elastic fibre 5-14group、15-21group、22-75 group were 7.32%（12/164）、13.81%（25/181）、21.52%（34/158）, respectively（all $p<0.05$）.

Conclusion: Both the proportion of alveolar elastic fibre appear ruptured and AL% were significantly correlated with ageing and alveolar elastic fibre autoflurescence intensity. We can analyzed the changes of alveolar elastic fibre with aging in vivo including morophologic changes、functional changes using pCLE，which helped us know the nonpathologic ageing process in the lung.

PO-052

Rigid bronchoscopic interventional therapy in two pregnant women with massive hemoptysis

Jin,Zhe、Zhang,Hong、Wang,Guangfa
Peking University first hospital

Objective: To evaluate the application of rigid bronchoscopic interventional therapy in the treatment of massive hemoptysis and to assess the security of cesarean delivery under ventilation ensured by rigid bronchoscopy.

Methods: We present two cases of pregnancy women who presented with an episode of massive hemoptysis and respiratory failure. Emergency rigid bronchoscopy and interventional treatment were performed in both patients. One case was endobronchial irrigated with cold saline and sprayed thrombin at the local lesion. And another was filled with gelatin sponge at the bleeding site. Both patients successfully completed cesarean delivery under rigid bronchoscopy to ensure ventilation. Angiography and bronchial artery embolization were performed in both patients then, and there was no hemoptysis after operation.

Results: Rigid tracheoscopy is safety and effective in the treatment of massive hemoptysis

Conclusion: Massive hemoptysis requires a systematic yet flexible multidisciplinary approach. Initial treatment consists of stabilization, securing the airway, and nonsurgical temporization of the bleeding source. Rigid bronchoscopy is the best way to secure an airway in patients with massive hemoptysis. Rigid bronchoscopy clearly has merits with regard to airway assessment and management in patients with massive life-threatening hemoptysis. It is very efficient at securing airway patency and safe guarding ventilation, thereby preventing asphyxia. It allows better suction of blood clots and secretions through its large working channel, and improved visualization of the airways. It also provides effective tamponade of accessible bleeding sites, and allows isolation of the nonaffected lung.

PO-053

Placement of silicone Montgomery T tube throug h trachea incision under rigid tracheoscope

Yan,Hongxia
The First Affiliated Hospital of Nanchang University

Objective: Subglottic tracheal benign stenosis(STBS) is a very difficult clinical problem， this kind of clinical problem lies in the interdisciplinary field of laryngeal surgery, respiratory medicine and thoracic surgery.Tracheal intubation or tracheotomy is the most common cause of benign tracheal stenosis，we usually use balloon dilatation and cryosurgery to solve these problems，The effect of ablation with laser, high frequency electrotome and argon knife is not good，because the patient has scar constitution,In the case of poor efficacy of other interventional methods, bronchial collapse and softening, it is suggested to put in tracheal silicone stent and silicone Montgomery T tube.

Methods: After repeated analysis and discussion,we think this case of benign airway scar stenosis is seriously ill.This patient has a short and thick neck,and the operation is very risky and difficult,so we carefully formulate the detailed technical route and operation plan,and deciding to place silicone Montgomery T -tube for this patient.Under the supervision of anesthesiologist,we made rigid bronchoscopy for patient under general anesthesia,The distance between T- tube and glottis, carina , incision were measured accurately.We have made the specification of T- tube,then the T-tube was trimmed and polished for covering the narrow area completely and coinciding with airway.The patient's dyspnea was significantly improved after we put T-tube into his airway.The operation was successful and lasted for three hours,the placement of T tube was ideal and the airway was unobstructed.Through the operation, we quickly relieved the patient's dyspnea.Now the patient can breathe normally through T tube.

Results: Through the operation, we quickly relieved the patient's dyspnea.Now the patient can breathe normally through T tube.

Conclusion: Subglottic tracheal benign stenosis(STBS) is a very difficult clinical problem， this kind of clinical problem lies in the interdisciplinary field of laryngeal surgery, respiratory medicine and thoracic surgery.Tracheal intubation or tracheotomy is the most common cause of benign tracheal stenosis，we usually use balloon dilatation and cryosurgery to solve these problems，The effect of ablation with laser, high frequency electrotome and argon knife is not good，because the patient has scar constitution,In the case of poor efficacy of other interventional methods, bronchial collapse and softening, it is suggested to put in tracheal silicone stent and silicone Montgomery T tube.

PO-054

Probe-based confocal laser endomicroscopy for real-time diagnosing lung cancer

Feng,Jiaxin、Li,Shiyue、Zhou,Ziqing、Chen,Yu、Zhong,Changhao、Chen,Xiaobo、Tang,Chunli
广州医科大学附属第一医院

Objective: Fluorescein-Aided probe-based confocal laser endomicroscopy enables real-time imaging of cells. We described specific images of using pCLE for real time identification of lung cancer.

Methods: Fluorescein-Aided pCLE was performed in 17 patients with proven bronchus malign tumor or peripheral lung malignant tumor. Before and after intravenous administration of fluorescein，suspected malign tumor lesion were evaluated using pCLE.

Results: Fluorescein-Aided pCLE wad performed in 17lesions (9 bronchus malign tumor， 8 peripheral lung malignant tumor)。Three fluorescein-Aided pCLE-lung cancer specific image feature included caring sizes and irregular shapes black cells、motionless dark clumps、high fluorescence filling and leaking around the lesion , and the proportion of them appeared were 100%、100% and 64.71%.

Conclusion: Fluorescein-Aided pCLE might be useful to rapidly and accurately recognized lung cancer.

PO-055

Brief Description of the lumen instrument examination of Electronic Bronchoscope

Guo,Mingxue、Yang,Zhen、Jia,Yanhong、Li,Lina、Zhu,Qiang、Zou,Chenxi、Xu,Yi
Chinese PLA General Hospital

Objective: To preliminary assess the abrasion and cleanliness of the lumen of electronic bronchoscope.

Methods: An lumen instrument examination workstation (Healthmark, FIS-005SK) was used to assess the abrasion and cleanliness of the lumen of bronchoscopes that frequently used in the Interventional Clinic for Lung Cancer and Respiratory Diseases of the Chinese People’s Liberation Army General Hospital, after routine leak detection, disinfection and cleaning. The lumen instrument examination workstation includes a high-precision ultra-fine flexible inspection scope and a mobile computer equipment. high-precision ultra-fine flexible inspection scope insertion length: 110cm, diameter: 1.9mm; image resolution 160,000 pixels; image magnification rates: 50 times; A LED light was located surrounding the front of the whole digital camera, ensuring that the area around the camera can be illuminated completely. During inspection, the head of the scope inserts from the end of the bronchoscope, retrogrades to the two openings (suction and biopsy channels openings) to record the abrasion and cleanliness of bronchoscope during the entire process.

Results: 9 bronchoscopes (models: five bf260, one bf-et260, one bf-q290, one uc-fw260, one bf-uc260f, one bf-uc260f-ol8) were assessed successfully.

The service life of these electronic bronchoscopes is 2-13 years (average 8 years), 3 of which have been repaired due to internal leaks. After the inspection, 2 bronchoscopes (two bf260) were found scratch and slight deformation at curved ends, 5 bronchoscopes (three bf260, one bf-et260, one bf-uc260f-ol8) were found abrasion at the junction of the biopsy channel and the suction channel, 2 bronchoscopes (two bf260) lumen appeared scattered scratches and the epidermis tilted, 3 bronchoscopes (two bf260, one bf-q290) appeared with a filamentous warp in the middle of the lumen; dirt and rust-like flakes were found in biopsy channels of all 9 bronchoscopy near the entrance of the handle end, and on the surface of the front end of the lumen; 2 bronchoscopes (two bf260) were found dirt on the inner folds of the

lumen. We reviewed the routine sensory monitoring data of of all bronchoscopes (1 time/3 months) in the past year and the random sampling data of sensory control were qualified.

Conclusion: Various degrees of damages and dirt attachment were found in the lumen of the bronchoscopes, while no abnormal data was found in the detection of possible infection inside the bronchoscopes, indicating that further steps should be considered to keep the lumen of the bronchoscopes integrated and clean.

PO-056

In vivo use of Probe-based confocal laser endomicroscopy for diagnosing lung cancer.

Xu,Yi、Zhu,Qiang、Li,Lina、Guo,Mingxue、Zou,Chenxi、Yang,Zhen
The General Hospital of the Peoples Liberation Army

Objective: Probe-based confocal laser endomicroscopy (pCLE) is a innovative, non-invasive technique that provides real-time micro-imaging of the epithelium during bronchoscopy, whether central or distal airway. Although considered as "optical biopsy", the pCLE are far from being used in clinical routine, because the image features of lung cancer are not well established. The purpose of this study was to investigate the imaging features and safety of pCLE in lung cancer at different sites.

Methods: From November, 2019 to April, 2020, patients who were clinically suspected lung cancer and needed to be further confirmed by bronchoscopy in PLA general hospital were recruited in this research. Histopathological images from malignant lesions were analyzed by two independent physicians.

Results: 43 image sequences from 11 patients who were diagnosed lung cancer by biopsy were analyzed. The most common pCLE features of lung cancer are the Irregular arrangement of fibers, which presents in all the patients. Other features include absence of fibers, alveoli septal thickening and fiber fragmentation. All 9 patient did not present major adverse event.

Conclusion: In our preliminary work, pCLE are efficient and safe for diagnosing lung caner. More cases should be recruited and analyzed to further confirmation.

PO-057

The retrospective analysis of safety and feasibility of electromagnetic navigation bronchoscopy under local anesthesia for patients with pulmonary peripheral lesions

Yang,Zhen、Zhu,Qiang、Liang,Zhixin、Wang,Juan、Jia,Yanhong、Zou,Chenxi、Li,Lina、Guo,Mingxue、Wang,Huishuang、Chen,Liangan
Chinese PLA General Hospital

Objective： To explore the safety and feasibility of application of electromagnetic navigation bronchoscopy（EBV）for pulmonary peripheral lesions（PPLs）under local anesthesia.

Methods： Patients with PPLs who have received bronchoscopy under local anesthesia in the center of Interventional Pulmonology of PLA general Hospital from May 2017 to December 2019 were included retrospectively, the safety and feasibility of ENB under local anesthesia was evaluated.

Results： A total of 22 patients were collected, including 13 males and 9 females. The median age was 57 years (21-79 years). There were 22 target lesions, including 12 in the right upper lobe, 3 in the right middle lobe, 2 in the right lower lobe, 3 in the left upper lobe and 2 in the left lower lobe. The average lesion size was 23.8mm (12-43mm). Of the 22 patients, 21 (95.5%) were successfully navigated. The average navigation time was 11 min (2-25 min) and the average operation time was 47 min (21-68 min). 19 patients (86.4%)were confirmed by pathology after ENB (15 adenocarcinoma, 1 organic pneumonia, 1 eosinophilic pneumonia, 2 non-specific benign lesions), 2 patients were confirmed adenocarcinoma by the following percutaneous transthoracic needle biopsy, and 1 cases could not be confirmed. The common complications were mild cough and bleeding after biopsy. Only one patient developed mild pneumothorax after operation, which was absorbed spontaneously.

Conclusion： EBV under local anesthesia for patients with PPLs was safe and feasible.

PO-058

Preoperative Electromagnetic Navigation Bronchoscopy guided Multiple dye localization for Resection of subsolid nodules

Park,Hyeongbin、Ji,Wonjun、Lee,Geun Dong、Kim,Dong Kwan、Hwang,Hee Sang、Jang,Se Jin、Oh,Sang Young、Kim,Mi Young、Lee,Jae Cheol、Choi,Chang-Min
Asan Medical Center

Objective： Although video-assisted thoracoscopic surgery (VTAS) of multiple small, subsolid pulmonary nodules is challenging, electromagnetic navigation bronchoscopy (ENB) guided transbronchial dye marking is a useful emerging technique that enables successful resection. We aimed to evaluate the accuracy and safety of preoperative ENB guided transbronchial multiple dye localization for VATS resection of subsolid pulmonary nodules.

Methods： As a single center pilot study, we recruited patients who had more than two small or subsolid pulmonary nodules. Multiple localization was performed by intraoperative ENB guided transbronchial injection of an indigo carmine dye. The patients underwent VATS for sublobar resection immediately after localization. The accuracy of ENB guided dye marking was checked in intraoperative fields ,

Results： ENB guided one-stage multiple dye localization was conducted for 18 pulmonary nodules in 7 patients between September 2018 and December 2019. The mean diameter of the pulmonary nodules was 9.3 mm (range, 4-18) and the mean distance from the pleura to pulmonary nodule was 6 mm (range, 1-17 mm). More than half of the

nodules (61.1%) were located in lower lobe and 15 of 18 nodules were subsolid (83.3%). ENB guided transbronchial multiple dye localization was successfully performed in 94.4% (17/18) having only one failed case which happened when approaching the target lesion located in superior segment of left lower lobe. The accuracy of ENB guided dye marking was 88.2% (15/17). The two unidentified nodules in intraoperative fields, anatomical sublobar resection was performed. VATS was performed successfully in all patients (100%). There was no conversion to thoracotomy and operative mortalities. Among the 7 patients, there was no major complication including moderate to severe bleeding or pneumothorax during ENB guided dye localization, and just one patient showed mild intrabronchial bleeding, but stopped spontaneously. Of the 18 nodules, final diagnosis was adenocarcinoma in 13 (72.2%), ameloblastoma in 3 (16.7%), and benign in 2 (11.1%).

Conclusion: In this study, ENB guided one-stage transbronchial dye localization showed accurate and safe intraoperative identification of multiple subsolid pulmonary nodules. A large scale prospective clinical study using ENB guided one-stage multiple transbronchial dye localization is warranted.

PO-059

Eosinophilic Granulomatosis with Polyangiitis Initially Diagnosed as Suspicious COVID-19

Yu,Haiqiong、Chen,Xiaoke

The eighth Affiliated Hospital of Zhongshan University

Objective: A 38-year-old woman was admitted to our hospital for violent cough, fever.

Methods: She was initially diagnosed as suspicious COVID-19. One year ago, she was diagnosed as paranasal sinusitis. Blood examination showed decreased WBC at 3740 cells/μL, increased eosinophils at 1670 cells/μL, elevated levels of immunoglobulin (Ig) G at 20.82 g/L, IgE>200IU/ml and C-reactive protein at 39.6 mg/L. Perinuclear ANCA (p-ANCA) was positive. Nucleic acid tests (Sputum, BALF, anal swab, nasopharynx swab) for SARS-CoV-2 virus were negative. IgM antibody of 9 respiratory tract infection pathogens was negative. Chest computed tomography (CT) showed multiple ground glass shadows in the bilateral lobes. Bronchoscopy, bronchoalveolar lavage and mucosal biopsy were performed under bedside sedation and analgesia. Tracheobronchial bronchitis, multiple nodules necrosis of the trachea was found under bronchoscope. No fungi or acid-fast staining positive bacilli were found in BALF. Pathological examinations of the trachea showed eosinophilic infiltration under the epithelium, no granulomatous nodules and caseous dead bodies were found.

Results: She was diagnosed with eosinophilic granulomatous polyangiitis (EGPA) and treated with corticosteroids, which resolved the eosinophilia, fever, cough and lung infiltration.

Conclusion: She was diagnosed with eosinophilic granulomatous polyangiitis (EGPA)

PO-060

A long-term clinical study on the bronchoscopic lung volume reduction of the patients with severe emphysema.

Liu,Yang、Song,Xiaolian、Wang,Changhui
Department of Respiratory Medicine， Shanghai Tenth People's Hospital， Tongji University

Objective: To evaluate the long-term efficacy and safety of bronchoscopic lung volume reduction in patients with severe emphysema, prognosis and relevant influencing factors.

Methods: A retrospective analysis was performed on patients diagnosed with COPD from 2015 to 2018 in Shanghai 10th peoples hospital.All patients should meet the eligibility requirements.The patients were divided into 2 groups,the underwent endobronchial valve group and the control group (with standard medical treatment). FEVl, FEV1% pred, RV% pred, TLC% pred, 6MWT， mMRC and CAT were examined in 1, 2， 6 and 12 months in two groups. Both efficiency and complications were evaluated and recorded .All data was analyzed to find the affecting factors.

Results: (1)In the group underwent endobronchial valve, significant changes were observed in FEV1, FEV1%, RV%, TLC%, 6MWT, mMRC and CAT scores than control group ($P < 0.05$). (2) There was no significant change in the efficacy indicators of patients in the control group during the follow-up ($P < 0.05$). (3) There were significant differences between the valve group and the control group in FEV1, FEV1% pred, RV% pred, TLC% pred, 6MWT, mMRC and CAT scores ($P < 0.05$). (4)No serious complications occurred in the valve group, and there was no significant difference compared with the control group ($P < 0.05$). (5)The location of the target lobe or the type of valve has no significant effect on efficacy ($P < 0.05$). (6)The improvement of pulmonary function in the treatment group did not increase gradually with time, but had its own pattern.This may be related to the natural course of emphysema.

Conclusion: (1) BLVR is more effective than traditional medical treatment to patients with severe emphysema. (2) Lung function, clinical symptoms, and the ability of exercise all improved significantly after BLVR, but decreased with the time extension. (3) BLVR does not increase the risk of death or serious complications. (4) The location of the target lobe or the type of valve did not affect the efficacy of BLVR.

PO-061

Tracheal capillary hemangioma in one child and literature review

Yu,Gang、Zheng,Yangming、Hu,Xiaoguang、Zhang,Hailin
the second Affiliated Hospital and Yuying Children’s Hospital of Wenzhou Medical University

Objective: To explore the clinical feature and therapeutic process of tracheal capillary hemangioma in child.

Methods: Clinical data and treatment in one case of tracheal capillary hemangioma in child were retrospectively analyzed, and literatures were reviewed.

Results: A 12-year-old boy was admitted to the hospital due to "several times of hemoptysis within half a day". After coughing, there was sudden massive hemoptysis with a total amount of about 100ml within half a day. There was no fever, no chest tightness, no shortness of breath, no cyanosis and other symptoms. Past medical history and family history were normal. Physical examination: the complexion was short ruddy, the right lung breath sound was lower, and been heard a few wet fine rales. The remained physical signs were negative.Auxiliary examination: blood routine, coagulation function is normal. Chest computed tomography showed scattering patchy shadows and ground glass appearance.Admission diagnosis was hemoptysis: pneumonia, pulmonary arteriovenous fistula? After

admission, pulmonary artery CTA suggested infection of the right lower lung and no obvious vascular malformation. Bronchoscopy indicated right lower lung active hemorrhage, clot blockage in the right lower basal segment, and 4 ℃ NS and 1:10 000 epinephrine were given for hemostasis. DSA suggested bronchial artery pulmonary fistula, and at the same time was given spring coil and embolized microsphere embolization.No hemoptysis was found after the operation. After discharge, there was no hemoptysis and no cough. 3 weeks later, the children were admitted to the hospital under general anesthesia, and the tumor was removed by freezing under rigid bronchoscopy. No obvious bleeding was observed during the operation. The excised tissue was submitted for pathological, and the results were reported as angiogenic tumors, tending to capillary tumors. Follow-up with telephone so far, no hemoptysis occured. The retrieval of "tracheal or endobronchial capillary hemangioma AND child" was made in PubMed, web of science, Chinese CNKI, VIP daeabase and wanfang database. From the establishments of these databases to April 1st, 2020，a total of 1 chinese article and 3 english articals were retrieved. Including 1 case of this article, a total of 5 children with tracheal capillary hemangioma were analyzed.The clinical manifestations were hemoptysis and cough, the longest hemoptysis time was 2 years, the shortest was half a day, 3 cases of large hemoptysis, 2 cases of small hemoptysis. Dyspnea after exercise in 2 cases and intermittent wheeze in 1 case. There were 3 cases in trachea, 1 case in right main bronchus and 1 case in right basal segment. One case was resected by flexible bronchoscopy, one case was resected by rigid bronchoscopy, two cases were resected by rigid bronchoscopy combined with flexible bronchoscopy.4 cases of hemoptysis and other symptoms disappeared in postoperative follow-up, 1 case did not show follow-up.

Conclusion: The main symptoms of tracheal capillary hemangioma in child are hemoptysis and cough, which can be massive or small hemoptysis. It can wheeze or dyspnea after exercise. Its course is different. Bronchoscopic interventional resection of endotracheal capillary tumors in children is a safe, minimally invasive and effective treatment strategy.

PO-062

Comparison of four anesthesia methods in painless fiberoptic bronchoscopy in children

Ning,Junjie、Chen,Huayou、Li,Xuemei
First People's Hospital of Zigong City， Sichuan Province

Objective: To compare the clinical effects of painless fiberoptic bronchoscopy in different groups of children with different anesthesia methods.

Methods: A total of 120 children who underwent bronchoscopy from November 20, 2019 to October 2019 in the Department of Pediatrics, First People's Hospital of Zigong City, Sichuan Province were assigned to group A (lidocaine topical anesthesia + midazolam)30 cases, group B (lidocaine topical anesthesia + midazolam + sufentanil) 30 cases, group C (lidocaine topical anesthesia + midazolam + sufentanil + propofol medium/long-chain fat emulsion injection) 30 cases and group D(lidocaine topical anesthesia + sufentanil + propofol medium / long-chain fat emulsion) 30 cases according to the random number table. The feasibility and safety of different anesthesia methods were compared by recording the breathing, heart rate, oxygen saturation, adverse reactions, FLACC score, wake-up time and drug dosage of each group of children.

Results: In group A, group B and group D, intraoperative respiratory and heart rate increased and oxygen saturation decreased significantly compared with group C, the difference was statistically significant ($P<0.05$); group A had the most adverse reactions compared with group B, C, D and there was significant difference($P<0.05$). There was no significant difference in adverse reactions among group B, C and D ($P>0.05$). The FLACC scores in group B, C and D were significantly lower than those in group A, of which group C had the lowest scores, showed that the analgesic effect was the best ($P < 0.05$); the recovery time of group C and D was longer than that of the other two groups, and the recovery time of group C was the longest, but the final data were not statistically significant ($P >0.05$); The doses of three intravenous anesthetics in group C were significantly lower than those in the other three groups, and the difference

was statistically significant (P < 0.05).

Conclusion: All four anesthesia programs can be used for pediatric fiberoptic bronchoscopy, but group C has fewer adverse reactions, the best sedative and analgesic effect, and the least amount of anesthetic drugs. It may be the most suitable anesthesia for pediatric fiberoptic bronchoscopy.

PO-063

Clinical study of different dose lidocaine via spray-As-You-GO technique through epidural catheter in topical anesthesia of bronchoscopy examination

Jin,Xiuling、Chen,Limei
The First Affiliated Hospital of Wenzhou Medical University

Objective: To investigate the clinical efficacy of different dose lidocaine via spray-as-you-go technique through epidural catheter in tipical anesthesia of bronchoscopy examination.

Methods: 110 patients underwentpainless bronchoscopy from June 2018 to June 2019 were selected.They were randoomly divided into group A and group B according to random number table.Patients in group in group underwent topical anesthesia with 2% lidocaine via spray-as-you-go technique through epidural catheter;patients in group B underwent topical anesthesia with 1% lidocaine via spray-As-You-GO technique through epidural catheter. Coughing, satisfaction, time to reach effective anesthesia, average medication dose, hemodynamic changes at different times, and adverse reactions during examination between two groups were compared.

Results: The incidence of cough was lower in group B than in group A (22.00%), and the difference was statistically significant (P < 0.05). There was no significant difference in visual analogue scale (VAS) scores between the two groups (P > 0.05). The time to reach effective anesthesia in group B was faster than that in group A, and the average medication dose was less than group A. The difference was statistically significant (P < 0.05). The heart rate (HR) and mean arterial pressure (MAP) of group A were higher at T1 than T0, and the difference was statistically significant (P < 0.05). There was no significant difference in HR, MAP and SpO2 between T0 and T1 in group B (P > 0.05). HR and MAP at T1 were lower in group B than group A, and the difference was statistically significant (P < 0.05). The adverse reactions in group B were less than those in group A, and the difference was statistically significant (P < 0.05).

Conclusion: The effects of 1% lidocaine via spray-As-You-GO technique through epidural catheter in topical anesthesia of bronchoscopy examination are better than 2% lidocaine. The incidence of cough is less, and the adverse reactions are less.

PO-064

Medical thoracoscopic photodynamic therapy for metastatic pleural tumor: A prospective single arm study

mai,zhonglun、Feng,Qixiao
Southern Medical University Hospital of Integrated Traditional Chinese and Western Medicine

Objective: To explore the value of low-dose photosensitizer, selection of irradiation dosage, operation method of optical fiber, and the effect and safety of thoracoscopic photodynamic therapy of metastatic pleural tumor.

Methods: We conducted a prospective single arm study. From March 2019 to November 2019, the clinical data of 23 metastatic pleural tumor patients who underwent thoracoscopic photodynamic (or combined with argon gas knife) therapy at the Respiratory Department/Thoracic Oncology Department of TCM-Integrated Hospital of Southern Medical University were collected. We observed the efficacy and complications of 2mg/kg, 2.5mg/kg and 3mg/kg HiPorfin under 90J/cm2-150J/cm2 irradiation energy, respectively. We also summarized the experience of perioperative management of photodynamic therapy.

Results: All operations were completed successfully, and the total effective rate was 87%.There was no significant difference in effective rate among the three groups of patients injected with different dose of photosensitizer. The arterial P02 increased significantly in patients with routine use of high frequency jet non-invasive assisted ventilator. Three patients had recurrent fever, one patient had extensive pleural adhesion due to delayed injection of urokinase into the pleural cavity, and another one patient developed systemic capillary leak syndrome 30 hours after receiving extensive pleural irradiation. No other complications were observed.

Conclusion: The effective and safe dose of photodynamic therapy of metastatic pleural tumor was 2-2.5mg/kg HiPorfin under 90J/cm2-150J/cm2 irradiation energy, which can also greatly reduced the medical cost. There are several recommendations based on our clinical experiences: preoperative and intraoperative routine use of high frequency jet non-invasive assisted ventilator to increase the tissue oxygen content, simultaneously performing thoracoscopic thermal ablation and photodynamic therapy, administrating antibiotics during perioperative period to prevent infection, use glucocorticoids to prevent systemic capillary leak syndrome during extensive intraoperative irradiation, and injecting urokinase through the 36-40 Fr thoracic tube 24 hours after surgery to fully drain necrotic material. At present, the photodynamic therapy of pleural tumors is still in its exploration stage, further studies of its practice are needed to better evaluate this method.

PO-065

Epstein-Barr virus-associated endotracheal leiomyosarcoma after kidney transplantation treated with argon plasma coagulation: a case report and literature review

Yang,Jiasheng、Lin,Guohui、Gong,Jinru、Wang,Yan、Chang,Yongmei、Yan,Wensen、Wang,Aiwu、Sun,Ruilin
Guangdong Second Provincial General Hospital

Objective: Patients with EBV-associated leiomyosarcoma are rare.We hope to improve our knowledge and guide the treatment through the clinical manifestations, histological diagnosis and management of a case.

Methods: A case report of EBV-associated endotracheal leiomyosarcoma after kidney transplantation in a 25-year-old male patient of Guangdong Second Provincial General Hospital was presented.

Results: Chest CT showed soft tissue nodules attached to the trachea and right main bronchus, and bronchoscopy found neoplasm in the trachea and right main bronchus. More importantly, pathological examination indicated positive Smooth muscle actin, Vimentin, Caldesmon and EBER, which helped establish the final diagnosis. After the patient underwent argon plasma coagulation (APC) and sleeve cutting of the neoplasm, no chest tightness, shortness of breath or hemoptysis has been observed during postoperative follow-up.

Conclusion: EBV-associated endotracheal leiomyosarcoma is a rare tumor, and APC ablation is an effective treatment method.

PO-066

Tracheobronchopathic osteochondroplastica:one case report

Su,Huanzhang、Zhang,Huaping、Zeng,Yiming
Department of Respiratory and Critical Care Medicine， the Second Affiliated Hospital of Fujian Medical University，
Quanzhou， China.

Objective: Tracheobronchopathic osteochondroplastica（TO） are rare, easy to misdiagnosis and missed diagnosis, and there is no specific therapy, this article report to in 1 case, combined with the literature TO discuss the clinical manifestation, treatment and prognosis of the disease.

Methods: The patient, a 62-year-old male, was admitted to hospital because of tracheal lesions found by physical examination for 5 days. There were multiple tiny nodules in the chest CT: trachea in the other hospital. In the past, "hypertension, hyperlipidemia" for 20 years, blood pressure up to 160/70mmHg long-term use of "losartan 50mg, Lipitor 10mg" treatment. Deny the history of dust exposure and related occupational history. Admission examination chest CT hint: 1. The trachea wall thickens irregularly and the density increases. The density of both lower lungs increased unevenly with mosaic perfusion (figure 1). Bronchoscopy showed that multiple nodules of different sizes protruding to the lumen could be seen on the trachea wall, and there was no stenosis of the lumen (figure 2).When bronchoscopy was performed, the tissue on the Carina was taken at 9 o'clock and 12:00 for pathological examination. Histopathology showed chronic inflammation of bronchial mucosa, ossification of submucosa and lamina propria (lamellar bone, adipose tissue in medullary cavity) (figure 3). It was diagnosed as "TO disease". Symptomatic treatment such as bronchodilation was given, and the symptoms improved and discharged from the hospital. After being discharged from the hospital.

Results: TO disease is a benign disease with multiple nodular hyperplasia of bone or cartilage tissue protruding

to the lumen under the tracheobronchial mucosa. Rokitarisky was first discovered in autopsy in 1855. Wilks first described the histological features of the disease in 1857[1]. The disease is relatively rare, only more than 30 cases have been reported at home, and more than 380 cases have been reported abroad. The predilection age of TO disease is generally about 50 years old, there is no significant difference in the proportion of male and female, and its symptoms are generally atypical. Domestic patients are generally characterized by cough, expectoration, blood in sputum, shortness of breath, repeated infection and hoarseness. the incidence rates were 85%, 52%, 48%, 33%, 26% and 7%, respectively[2]. When the lesion involves the distal bronchus, it will cause airway obstruction, poor drainage, atelectasis and obstructive pneumonia. At present, the pathogenesis of the disease is not clear. Considering that TO is the late stage of bronchopulmonary amyloidosis, it is mainly based on the finding that ossification centers can sometimes be observed in localized amyloidosis [3、4].At present, it has been confirmed that bone morphogenetic protein-2 (BMP-2)and transforming growth factor- β 1 (TGF- β 1)are related to the formation of TO disease [5].In addition, it has been reported that the endocrine cells in the body secrete disorders of hormones or calcium and phosphorus.The abnormality of regulation and metabolism in vivo is related to the disease [6]. Jepsen [7] believes that chronic irritation such as long-term exposure to oil fumes and / or chemicals may be an important factor leading to the disease.In a word, the possible factors of disease are related to long-term persistent infection, airway mucosal metaplasia, chemical or physical (radiation, etc.) stimulation, congenital factors, abnormal hormone regulation and so on. The diagnosis of ossifying tracheobronchoscopy mainly depends on fiberoptic bronchoscopy and pathological biopsy, but chest CT can assist in the diagnosis. Chest CT screening showed multiple calcification of small submucosal nodules in the anterior and lateral walls of the trachea and bronchi, and characteristic changes protruding to the lumen, and the trachea membrane was rarely involved. For example, in the early stage, it is only manifested as thickening and irregular changes of trachea and bronchial mucosa, which is often easy to be missed and misdiagnosed. The characteristics of fiberoptic bronchoscopy are of great significance for the diagnosis of TO disease. they often show small gray-yellow nodules of different size and uneven distribution and protruding to the lumen, the texture is hard, and it is not easy to clamp during biopsy. pathological results suggest the formation of submucosal bone or cartilage nodules in the trachea and bronchus, and occasionally bone marrow and calcium salt deposits can be seen in the nodules. At present, the treatment of TO disease is mainly symptomatic support treatment, including drug antitussive, antibiotic anti-infection and so on. At the same time, for symptomatic TO disease, bronchoscopic intervention techniques, including laser resection, rigid bronchial nodule extraction and stent implantation, can alleviate the symptoms and improve the quality of life [1].

Conclusion: TO disease is a non-progressive benign disease. When many patients are diagnosed, the symptoms are often atypical or asymptomatic. As the disease is relatively rare, clinicians do not know enough about it, and it is often easy to misdiagnose and miss diagnosis. Therefore, when chest CT indicates that ossification-like nodules protruding to the lumen appear in the anterior wall or lateral wall of trachea or bronchus, clinicians should consider TO disease and conduct fiberoptic bronchoscopy and pathological examination to make a clear diagnosis.

PO-067

A prospective study on the effectiveness and safety of transbronchial lung cryobiopsy in the diagnosis of interstitial pulmonary disease

WU,YUTING1、HUANG,WENQI1,2
1. southern hospital of southern medical university
2. Southern medical university

Objective: To evaluate the effectiveness and safety of transbronchial lung cryobiopsy in the diagnosis of interstitial pulmonary disease

Methods: A total of 29 patients with suspected ILD who were admitted to the southern hospital of southern medical university from January 2018 to August 2019 were enrolled.Inclusion criteria: Age greater than 15 and less than 85; Arterial oxygen partial pressures with low flow oxygen >60 mmHg(1 mmHg = 0.133 kPa);High resolution CT(HRCT) of the chest indicated diffuse lesions of both lungs with unknown causes, and the main lesions were located in the distal bronchus below the bronchus of both lung segments or peripheral pulmonary lesions.The patients cardiopulmonary function can withstand general anesthesia and coagulation function is normal.Exclusion criteria: Abnormal coagulation function;Platelet <100×109/L; Chest enhanced CT indicated significant thickening of pulmonary vessels, pulmonary vascular malformation, hemangioma and pulmonary vasculitis in the biopsy site; Severe cardiopulmonary insufficiency and general anesthesia could not be tolerated.

Results: Pathological reports showed that 5 patients were diagnosed with non-specific interstitial pneumonia (NSIP), 5 with autoimmune interstitial pneumonia, 2 with organic pneumonia, 1 with lymphangiomyomatosis, 4 with lung adenocarcinoma, including 1 with drug-related interstitial pneumonia and 1 with lung squamous cell carcinoma.the diagnostic coincidence rate was 62.1% (18/29).

Conclusion: The application of transbronchial lung cryobiopsy can accurately diagnose interstitial pulmonary disease. It is a safe and effective biopsy method.

PO-068

A case of left main bronchus atresia caused by occult trachea rupture after trauma

Ye,Liqun1、Guo,XinZhi2

1. The First Affiliated Hospital of Zhengzhou University
2. The Sixth Peoples Hospital of Zhengzhou City

Objective: To explore the application of tracheoscopy in the treatment of tracheal atresia

Methods: a patient with multiple injuries recently admitted to the First Affiliated Hospital of Zhengzhou University, Deng XX, was injured in a car accident one month ago, which resulted in right clavicle fracture, left rib multiple fracture, large area subcutaneous emphysema and mediastinal emphysema. After subcutaneous incision and drainage, subcutaneous emphysema and mediastinal emphysema improved. Half a month later, chest CT showed that the left side of the lung was atelectasis. Bronchoscopy was performed in the local hospital It was found that the left main bronchus was completely occluded according to the 2cm of protrusion, and could not be opened by cryotherapy. Therefore, it is proposed to carry out left pneumonectomy and transfer to thoracic surgery in our hospital. After multi-disciplinary consultation and discussion, it is suggested to try the interventional treatment under the bronchoscopy first, and then transfer to our department through the bronchoscopy laser cutting, probe guidance, balloon expansion, so that

the atretic left main bronchus can be reopened, and later put in the silicone stent, and the left pulmonary atelectasis can resume ventilation.

Results: the left main bronchus was recanalized and the left lung was atelectasis.

Conclusion: the incidence of tracheal rupture is low, misdiagnosis and missed diagnosis are easy. Early bronchoscopy is helpful to clear diagnosis, and it can deal with severe complications such as tracheal atresia through endotracheal endoscopic intervention, so as to avoid surgical resection.

PO-069

Anesthesia in difficult replacement airway stents—Case Report

Chen,Limei
The First Affiliat Hospital of Wenzhou Medical University

Objective: Esophagotracheal fistula often occurs in patients with advanced esophageal cancer, and airway stents are often required. The patients always develop dyscrasia.

Methods: A 79-years-old male patient who had esophageal tumor underwent esophagectomy and postoperative chemoradiotherapy 5 years ago. He developed dyspnea and came to our hospital for trachea and left mainstream bronchi stent implantation one year ago. Recently he developed dyspnea again. Bronchoscopy found that there was stenosis at both ends of the tracheal stent due to tumor recurrence. He was scheduled for "trachea and left mainstream bronchi stent removal and metal Y-coated stent implantation". He has hypertension and diabetes for more than 10 years. He got cancer cachexia (Height 155 cm, Weight 40kg, he lost weight 20kg in one year. Albumin 31.4g/L, Hemoglobin 73g/L). Monitoring according to national standards was established. With venturi mask on oxygen, his SpO2 was 95%, and his noninvasive blood pressure was 90/50mmHg, the electrocardiogram showed a sinus rhythm of 120 bpm. Anesthesia was slowly induced by intravenous injection of midazolam 1mg, sufentanil 10ug, propofol and remifentanil iv-vp. The nasopharyngeal airway was inserted and connected to the anaesthesia machine for oxygen, but spontaneous breathing was retained. The operation underwent three steps: airway clearance by bronchoscope, stent removal by rigid bronchoscope and new stent placement. After bronchoscopy, a lot of sputum bolt was found. Given the airway cleaning would be long, the anesthesia was deepened. The nasopharyngeal airway was exchanged to an endotracheal tube. Ventilation mode was exchanged to SIMV. During this period, blood pressure dropped several times and was maintained by noradrenaline. The blood pressure was maintained at 110/60mmHg. After airway cleaning, the silicone trachea stent and the left bronchus metal stent were prepared to remove by rigid bronchoscope. In consideration of the patient's already dyscrasia, unstable hemodynamics, the anesthesia was not deepened, only rocuronium 10mg was administrated. When the endotracheal tube was removed, the patient's larynx was still active. 20mg rocuronium was added. The blood pressure dropped to 80/50mmHg. Given the stimulation of the insertion of rigid bronchoscope, the blood pressure was not raised. The glottis was exposed difficultly because of radiotherapy. At the same time, both of the blood pressure and SpO2 dropped. In 3minutes, SpO2 continues to drop till zero, blood pressure drops to unmeasurable, and heart rate drops to 10bpm. The rigid bronchoscope was removed immediately and the endotracheal tube was reinserted for manual ventilation. Epinephrine 250ug was administrated immediately. Propofol and remifentanil were discontinued. SpO2 slowly rose to 90% and blood pressure rose to 210/120mmhg. Propofol 10ml/h micro pump was continued and vital signs became stable. 20min later, full preparation with deep anesthesia, norepinephrine to raise blood pressure, sputum aspiration and tracheal catheter removal, removing the stents was tried again. Two stents were removed successfully. At this time, SpO2 had been gradually reduced to 80%, and the 6.0# tracheal tube was inserted into the rigid bronchoscope and connected to the anesthesia machine for manual ventilation, but SpO2 still could not be raised. Considering that the patient had no stent support in the airway, ventilation could not be maintained when the rigid bronchoscope was removed. The endotracheal intubation could not maintain the ventilation too. It was difficult to place the "Y" type stent under the fiber bronchoscope. So we decided to place the stent under the rigid bronchoscope at risk. Immediately

removed the endotracheal tube in the rigid bronchoscope, quickly placed the "Y" type metal coated stent, suction the sputum and removed the rigid bronchoscope, insert the 8.0# endotracheal tube, and manually control ventilation. It only took 10 minutes to finish these actions. At the same time, SpO2 had been gradually reduced to 20%. After manual ventilation by endotracheal tube, SpO2 rose rapidly to 100%.

Results: After the surgery, the drug was stopped, and the patient woke up 10min later. But the spontaneous breathing was still weak, and SpO2 could be maintained above 95% under SIMV ventilation. He was transfered to RICU, and was removed the endotracheal tube the day following. He was discharged from hospital 12 days later.

Conclusion: The lesson to be learned from the present case is that the depth of anesthesia and clinical decision are very important.

PO-070

Holmium laser in the treatment of benign tracheal stenosis

Sun,Danxiong、杨振 ,Yang Zhen 、张云辉 ,Zhang Yun Hui、孙丹雄
First People's Hospital of Yunnan

Objective: With the development of critical medicine, the number of patients with benign tracheal stenosis caused by tracheal intubation and tracheotomy is increasing. The purpose of this study was to observe the effect of Ho: YAG laser on tracheal stenosis caused by tracheal intubation and tracheotomy.

Methods: The clinical data of patients with tracheal stenosis treated by holmium laser in the first people's Hospital of Yunnan Province from February 2017 to may 2019 were analyzed retrospectively. The causes of these patients' tracheal stenosis were endotracheal intubation or tracheotomy. Evaluation criteria of clinical effect: (1) continuous remission: the duration of airway patency is more than 6 months without further treatment; (2) remission: the duration of airway patency is 3-6 months, which may require additional treatment; (3) no remission: the duration of airway patency is less than 3 months, which requires additional treatment; (4) failure: airway patency cannot be maintained, accompanied by airway softening or collapse. Degree of tracheal stenosis = stenosis diameter / normal diameter × 100%. The degree of tracheal stenosis was classified as grade 1 ≤ 25%; grade 2 26% ~ 50%; grade 3 51% ~ 75%; grade 4 76% ~ 90%; grade 5 > 90%, but the lumen was not completely occluded; grade 6: the lumen was completely occluded.

Results: 28 patients were included in the study, including 16 males and 12 females, aged from 18 to 62 years, with an average age of 34 ± 16.2 years. All patients had symptoms of acute respiratory distress. Causes of tracheal stenosis: tracheal intubation (23 cases), tracheotomy (5 cases). There were 8 cases of grade 3 stenosis and 20 cases of grade 4 stenosis. Twenty eight patients were treated with holmium laser for a total of 35 times. All patients had significant improvement in dyspnea on the postoperative day. Among them, 13 patients (46.4%) were continuous remission, 8 patients (28.5%) were remission, and 4 patients (14.3%) did not respond, 3 failures (10.7%).Two of the three patients who failed in the treatment were patients with tracheotomy. A total of 21 cases of tracheal stenosis continued to be relieved and relieved, of which 20 cases had a stenosis length of less than 2 cm; 7 cases had no remission and failed patients, of which 6 cases had a tracheal stenosis length of 2 to 3 cm. No serious complications such as pneumothorax, mediastinal emphysema, hemorrhage, tracheal wall perforation, and airway fire occurred during and after the operation.

Conclusion: Holmium laser is a relatively safe and effective method in the treatment of benign tracheal stenosis, which is worth further development in the airway interventional surgery, but the long-term effect needs further study.

PO-071

IgG-4 related lung disease diagnosed by transbronchial cryobiopsy

Sun,Kunyan、Hu,Yan、Yu,Qing、Zhang,Hong
Peking University First Hospital

Objective: IgG-4 related disease(IgG4-RD) is characterized by IgG4-positive plasmacyte infiltration in various organs, in which histology plays an important role for the diagnosis. The aim of the present study was to report how useful transbronchial cryobiopsy (TBCB) is for this diagnostic purpose.

Methods: one patient complained fever with ground glass opacities and consolidation in the upper lung lobeon chest computed tomography(CT), and underwent a transbronchial cryobiopsy.

Results: A 62-year-old male visited our hospital due to prolonged fever failuring in empirically antibiotics treatment. Chest CT showed ground glass opacities and consolidation subpleural in the upper lung lobe. PFT testing showed restricted pulmonary ventilation disorder as well as diffusive dysfunction. The etiological examination and tumor screening were all negative. Serum ANA was positive at the titter of 1:1000, and RF was 341IU/ml. Serum IgG-4 was 3.47g/l. Other immunological screening tests were negative. Under transbronchial lung cryobiopsy, a diagnosis of IgG-4 related lung disease was made, and he was prescribed to prednisone at a dose of 55 mg per day.

Conclusion: TBCB provided histological findings that were supportive for the diagnosis of IgG4-RD, which is a promising strategy and may become an alternative to surgical lung biopsy.

PO-072

Contrast-induced encephalopathy by bronchial arteriography and embolization: A case report and Literature Review

Zhan,Xiaohui
the second affiliated hospital of fujian medical university

Objective: to improve the understanding of contrast-induced encephalopathy caused by bronchial arteriography and embolization

Methods : The clinical data of contrast-induced encephalopathy in a patient who underwent bronchial arteriography and embolization were analyzed, the Etiology, risk factors, clinical manifestations, diagnosis and differential diagnosis, treatment, prognosis and prevention of contrast encephalopathy were analyzed retrospectively.

Results: The patient, a 75-year-old male, was admitted to Ricu because of "repeated hemoptysis for more than 2 years, with recurrence and aggravation for 10 hours" . After admission, massive hemoptysis was considered, and a bronchial arteriography was performed. The arteriography showed that the branches of the left and right bronchial arteries and the subclavian artery branch arteries were increased, disordered, and some of them were slightly distorted and dilated, the left and right bronchial arteries were superselected and the branches of the Subclavian artery artery were embolized. During the operation, the patient presented with Dysphoria, accompanied by limb twitching, right limb weakness, nausea, vomiting, difficulty in hearing and understanding, inability to speak, urinary incontinence, etc. , after CT scan, the left brain tissue was swollen and the density was increased, and the patients were treated with intubation and aspiration, sedation, decreasing intracranial pressure, dehydration, improving cerebral circulation, improving vasospasm, etc. . There was no high density image in the left Sulcus CISTERNA on the CT scan.

Conclusion: Contrast encephalopathy is a rare neurological complication after contrast iodine. At present, the

possible reason is related to the chemical toxicity and direct neurotoxicity of the contrast agent itself. To find a drug that can antagonize the toxicity of contrast medium and accelerate the excretion of contrast medium is an important measure to improve the safety of bronchial arteriography + embolization.

PO-073

Diagnostic value of pleural effusion tumour markers CEA, CA19-9, CA125, NSE and SCC in malignant pleural effusion

Yu,Yanxia、Tong,Zhaohui、Liang,Lirong、Zhou,Xiaoxia、Wang,Zhen、Xu,Lili
Beijing Chaoyang Hospital

Objective: To evaluate the diagnostic value of pleural effusion tumour markers carcinoembryonic antigen（CEA）, carbohydrate antigens 19-9 (CA19-9), carbohydrate antigens 125 (CA125), neuron-specific enolase（NSE）and squamous cell carcinoma antigen（SCC）in malignant pleural effusion（MPE）.

Methods: Pleural fluid tumor markers CEA, CA19-9, CA125, NSE and SCC of 114 cases confirmed by pleural biopsy through medical thoracoscopy were retrospectively analyzed. MPE was confirmed in 65 cases and tuberculous pleural effusion（benign pleural effusion, BPE） in 49 cases. The optimal cutoff of tumour markers with statistically significant difference for MPE were determined by using the ROC curve.

Results: The concentration of pleural fluid CEA（42.50 (2.14-500) ng/ml）and CA19-9 (13.06 (3.33，206.50) U/ml) were significantly higher in MPE than that of BPE (1.12 (0.61，1.77) ng/ml, $P < 0.001$), (2.94 (1.88，5.33) U/ml, $P < 0.001$), but there were no statistically significant difference in pleural fluid CA125、NSE、SCC. The cutoff value of pleural fluid CEA and CA19-9 for MPE were 5.80ng/ml and 12.52U/ml, the sensitivity respectively was 67.7% and 50.8%, the specificity respectively was 100% and 93.9%. When pleural fluid CEA and CA19-9 combined, the sensitivity was increased(70.8%), and the specificity was 98.0%, which was superior to pleural fluid CA19-9（z=2.089, P=0.0367）, but no difference with pleural fluid CEA（z=0.902, P=0.367）.

Conclusion: The concentration of pleural fluid CEA and CA19-9 have diagnositic significance to MPE, the sensitivity and specificity of pleural fluid CEA are higher than pleural fluid CA19-9, The combined determination of pleural fluid CEA and CA19-9 is not superior to the determination of pleural fluid CEA alone. Pleural fluid CA125, NSE and SCC have no diagnositic significance to MPE.

PO-074

Literature review on bronchoscopic used as the approach of choice to diagnose lung nodules

Guo,Zhifeng、Zeng,Yiming
福建医科大学附属第二医院

Objective: By reviewing the literature about bronchoscopic used to diagnose lung nodules, the advantages and disadvantages of different bronchoscopic approaches in the diagnosis to lung nodules were analyzed, and the selection of different approach to lung nodules diagnosis were summarized and recommended.

Methods: PubMed database was used to search the literatures about bronchoscopic used to diagnose lung nodules at home and abroad in the past 10 years, and the literatures were analyzed, summarized.

Results: Lung cancer is currently the leading cause of malignancy related mortality. This fact is due in large part to the advanced stage at which lung cancer is often diagnosed. Detection of stage I disease followed by timely surgical resection provides a significant increase in 5-year survival compared to those diagnosed at later stages.Minimally invasive diagnostic and therapeutic modalities have supplanted more traditional surgical approaches as the standard of care. Diagnosis and staging of lung cancer are now often completed using flexible bronchoscopy and endobronchial ultrasound (EBUS).Transbronchial needle aspiration of the mediastinal and hilar lymph nodes frequently provides sufficient information and material, obviating the need for biopsy of the primary site.If mediastinal staging is negative for malignancy, a biopsy of the primary site should be performed. Bronchoscopic approaches, even for nodules in the periphery, have become the standard of care when the proper equipment and experience are available.

Conclusion: With their ever-increasing safety and accuracy, bronchoscopic modalities are being increasingly used as the approach of choice to diagnose most lung nodules. With the continued development and finessing of these techniques and their combined use，we must find a most suitable approach to diagnose nodules for particular individual.

PO-075

Treatment of primary endotracheal schwannoma by bronchoscopy: a case report and literature review

Xu,Yingxuan、Zhang,Huaping、Zeng,Yiming、Lin,Huihuang
Second Affiliated Hospital of Fujian Medical University

Objective: Primary tracheal tumors refer to tracheal tumors originating from cricoid cartilage to carina plane, which are quite rare clinically[1] , far less than bronchial tumors, and most of them are malignancy.Benign tumors are quite rare, and the primary tracheobronchial schwannoma is even rarer[2].Schwannoma is a type of tumor originating from Schwann cells, with a low incidence, and can occur in various parts of the body, commonly in the flexion side of head, neck and limbs[3]. Primary tracheal schwannoma is an extremely rare tumor, and most of the relevant literatures are case reports and single-center case reviews.The purpose of this paper is to explore the clinical characteristics, early diagnosis and treatment of primary tracheosynoma, especially the application of respiratory interventional therapy in this area, and to improve the understanding of the disease.

Methods: case report and literature review

Results: A 14-year-old female was admitted to hospital with the chief complaint of "cough, sputum and asthma for 3 weeks". On admission, she was found to be slightly short of breath, and the sound of breathing in the upper lungs was thick, and wheezes could be heard. CT scanning of the lungs showed abnormal soft tissue shadow in the trachea

at the level of sternum stalk, with a size of about 1.2×1.1cm and a wide base attached to the wall of the air tube.After injection of contrast medium,there was slight enhancement.After completing the preoperative examination without contraindications, the electronic bronchoscopy was performed.Cauliflower-like new organisms were found in the middle part of the trachea. The base was located on the left anterior wall, with a length of about 15mm.As the breath moves, about 90 percent of the lumen was blocked during exhalation,high frequency electrical trap combined with argon knife was used to treat trachea neoplasm.Asthma was significantly improved after the procedure,and benign schwannoma was confirmed by postoperative pathology. No abnormal findings were found in 1 year of follow-up after discharge.During the literature review, it was found that the diagnosis and treatment of patients with endotracheal schwannoma was delayed due to the lack of specific symptoms and low incidence of the disease.Airway obstruction is the most common clinical manifestation.Patients with dyspnea who use a variety of bronchodilators, anti-infection and other treatments with poor or progressive aggravation of dyspnea should be vigilant against the existence of the disease.Early diagnosis can be made by neck-chest CT and bronchoscopy.

Conclusion: intratracheal schwannoma is an extremely rare tumor. Most of the patients present with irritant dry cough and uncontrollable dyspnea with recurrent attacks [4]. Chest CT examination has a high clinical value in the screening of this disease .With the development of fiberoptic bronchoscopy and bronchoscopic interventional therapy in recent years,there have been literature reports on the combined application of high-frequency electrocoagulation, argon knife and cryotherapy for comprehensive interventional therapy of tracheobronchial schwannoma[5].Compared with surgery, interventional therapy under fiberoptic bronchoscopy has the characteristics of minimally invasive, safe, economical and less complications.It can achieve radical cure in the therapy of benign tracheal tumors and plays an important role in long-term follow-up after simple resection of benign tracheal tumors,also in the evaluation of tumors before surgery and the auxiliary treatment of malignant tumors.

PO-076

Arterial embolization combined with bronchoscopic interventional technique in the treatment of elderly patients with laryngeal carcinoma complicated with severe tracheal stenosis: a case report

Lu,Xiaoling、Zhang,Huaping、Zeng,Yiming
The Second Affiliated Hospital of Fujian Medical University

Objective: To investigate the clinical efficacy and safety of bronchoscopic interventional technique in the treatment of elderly patients with laryngeal carcinoma complicated with severe tracheal stenosis.

Methods: Male patient, 94 years old, was admitted to the hospital on July 24, 2019 for "cough, sputum and asthma." Cough, sputum, asthma appeared 3 weeks before admission, sputum was white and viscous, low volume, asthma after activity, gradually relieved after rest, with paroxysmal wheezing, no chest tightness, chest pain, no cough pink foamy sputum and other discomfort. After taking “amoxicillin clavulanate potassium, doxofylline” and other treatments, the symptoms did not improve significantly. External hospital examination: CT of the chest showed that chronic bronchitis with little fibrotic lesions in the lungs, emphysema, bilateral pleural thickening, and electronic nasopharyngoscope showed that new biological properties under the glottis was to be investigated. Considering that the patient was laryngeal cancer, surgical treatment or tracheotomy was recommended, but the patient firmly refused and referred to our hospital for bronchoscopic interventional treatment to solve the problem of airway obstruction. Suffering from chronic obstructive pulmonary disease for 10 years, he usually coughs, expectorates, and wheezes repeatedly. He visited other hospitals several times. After anti-inflammatory, antiasthmatic, expectorant treatment and other symptoms could be improved, and usually irregular medication. he can take care of himself during the remission

period. Found hypertension for 2 weeks and have a history of smoking. Admission examination: body temperature: 36.4 ℃ , respiration: 28 times / min, pulse rate: 102 times / min, blood pressure: 136 / 82mmHg, consciousness, breathing is stable, breathing rate is significantly accelerated when moving on the bed, under nasal duct (2 liters / minute) no cyanosis on lips, no tri-concavity sign, middle trachea, thick breathing sounds in both lungs, audible small blisters and inspiratory gas wheeze in both lungs, no pleural friction sound The heart rhythm is normal and no heart murmur is heard. No contraindications of bronchoscopy were found in blood routine examination, blood coagulation screening, electrocardiogram and blood gas analysis. CT and enhanced CT scans of the chest and neck indicate that the level of aryepiglottic fold to the posterior wall of the cervical trachea was located, length of about 3cm. The CT value of the enhanced scan increases by 80Hu, and the tracheal stenosis is about 90%, considering malignant lesions. Taking into account that the tumor blood supply is very rich, and a large nutrient vessel can be seen in the trachea membrane to enter the tumor, if the bronchoscopic interventional treatment is performed directly, the risk of major bleeding is great. Therefore, arterial embolization was first performed. During the operation, the superior thyroid artery branch of the right external carotid artery and the inferior thyroid artery branch of the right clavicle were directly entered into the tumor. Embolization was performed, and the following day was treated with electronic bronchoscopy laser treatment and high frequency electricity knife.

Results: Airway stenosis was significantly improved after surgery. The tracheal stenosis at the lesion was about 40%, and the patient's dyspnea was significantly relieved. Pathological findings suggest squamous cell carcinoma.

Conclusion: 1. For airway tumors with abundant blood supply, arterial embolization combined with bronchoscopic interventional therapy can effectively improve airway obstruction and reduce the risk of major bleeding. [1][2] 2. Elderly patients are not contraindications for bronchoscopic interventional treatment, but they need to undergo detailed evaluation and adequate preparation before surgery. [3][4] 3. Some patients with laryngeal cancer are suitable for bronchoscopic interventional therapy.

PO-077

The feasibility and therapeutic value of positive pressure ventilationand sputum aspiration under bronchoscope in patients with atelectasis after lung cancer operation

Zhang,Chenghua
Department of Endoscopy Jilin Cancer Hospitle

Objective: To investigate the feasibility and therapeutic value of positive pressure ventilation under bronchoscope in patients with atelectasis after lung cancer operation.

Methods: 98 patients with atelectasis after lung cancer surgery in our hospital from January 2018 to July 2019 were treated with sputum aspiration and alveolar lavage under fiberoptic bronchoscope until the airway was cleaned, and then treated with positive pressure ventilation at the opening of atelectasis through fiberoptic bronchoscope, with air pressure of 15-20cmH2O and ventilation time of 1-3 minutes. After treatment, the X-ray imaging examination at the bedside was reexamined.

Results: During the treatment, the heart rate increased, the venous oxygen saturation decreased slightly, and all patients successfully completed the treatment. The operation time was 11-30 minutes. After 15 minutes of treatment, 91 cases of atelectasis were reexamined with chest radiographs and showed good dilatation. 7 cases of atelectasis were re-tensed. After 30 minutes of treatment, all vital signs of the patients were basically stable, clinical symptoms such as chest tightness and dyspnea were improved, blood oxygen saturation was significantly improved, and there were no serious complications such as respiratory failure, hemoptysis, severe arrhythmia, laryngeal bronchospasm.

Conclusion: Bronchofiberscope sputum suction combined with positive pressure ventilation can significantly

improve the incidence of atelectasis after the first treatment, significantly shorten the time of atelectasis, and rapidly improve the clinical symptoms of chest tightness and dyspnea. It is a safe and effective method for treating atelectasis after surgery.

PO-078

Interleukin17 levels of bronchoalveolar lavage fluid in children with bronchiolitis obliterans

Wu,Linlin
zhengzhou children's hospital

Objective: To explore interleukin 17 levels of bronchoalveolar lavage fluid in children with bronchiolitis obliterans

Methods: A total of 35 children with bronchiolitis obliterans hospitalized from Jan. 2017 to Jan. 2019 were enrolled as observation group, at the same time 35 healthy children as controls,Using enzyme-linked immunoassay (ELISA), to determine interleukin17 levels of bronchoalveolar lavage fluid between two groups.

Results: the interleukin 17 levels in observation group group were（27.79±7.22）ng/l, whereas（12.89±5.16）ng/l in control group,with statistically significant differernces($p<0.05$)

Conclusion: Determination interleukin 17 levels of bronchoalveolar lavage fluid in children with bronchiolitis obliterans has great clinical significance, which can provide the basis for treatment of the disease, worthy of clinical application.

PO-079

Efficacy of intralesional triamcinolone acetonide injection combined with radial incision for recalcitrant benign central airway stenosis

Wang,Zheng、Yun,Ma、Huizhen,Yang、Quncheng,Zhang、Taibo,Huang、Xiaoju,Zhang
Henan Provincial People's Hospital

Objective: To evaluate the efficacy and safety of local injection of triamcinolone acetonide (TA) combined with radial incision for benign central airway cicatricial stenosis.

Methods: Non randomized trial of conventional interventional treatment or TA injection plus radial incision in benign central airway stenosis. TA was locally injected into the circumference of incised of stenosis lesions. Patients were followed by 6-12 months. The efficacy and safety of these two methods were evaluated by the airway diameter, dyspnea score, interphase of interventional treatment and clinical stabilization, fasting blood glucose, plasma cortisol, injection local mucosal and clinical symptoms before and after treatment.

Results: Thirty-six and 56 patients were enrolled in the control group and in the TA group, respectively. After 6 to 12 months follow-up, both groups showed similar efficacy, but the total expenses and times of interventional therapy were significantly lower in the treatment group than in the control group. Complications included rash (n=1) and hyperglycemia (n=1, leading to discontinuation of TA treatment), but no adrenocortical insufficiency or other complications. The duration of bronchoscopic interventional operation in the two groups was (35.6 ±18.4) minutes and (27.1±8.7) minutes, respectively (P=0.022). The average times of treatment in the TA group and the control group was 1.7±1.1 times and 4.7±3.3 times in 6 months. The total times of interventional bronchoscopy, as well as the total times of balloon dilatation, heating ablation, cryotherapy and stent implantation per each patient during 6 months were significantly lower than those of the control group.

Conclusion: Local injections of TA therapy combined with radial incision is equally efficient for refractory benign central airway cicatricial stenosis, but may yield better cost-effectiveness.

PO-080

Photodynamic therapy (PDT) for adenoid cystic carcinoma of the tracheo-bronchial tree: A case report

Yu, 勍、Wang,Guangfa、Zhang,Wei、Zhang,Hong、Cheng,Yuan
Peking University First Hospital

Objective: Photodynamics therapy (PDT) is a safe and effective technology, and can be used to treat inoperable tracheal adenoid cystic carcinoma.

Methods: Our patient was a 48-year-old female who developed dyspnea, cough, and sputum for 4 years ago. A bronchoscope at the local hospital showed neoplasm in lower trachea and right main bronchus. Then in local hospital metal stents were placed in each of the left and right main bronchus. Postoperative pathology showed "adenoid cystic carcinoma", and received radiotherapy and particle implantation therapy. One years ago, the symptoms of dyspnea gradually worsened. Bronchoscopy in our hospital showed granulosis at the distal end of the left and right main bronchial stent. Freeze and cryotherapy the granulation and remove the left and right bronchial stent. After the stent is removed, the left main bronchus does not collapse, and distal stenosis of right main bronchus, we used balloon dilation. The patient subsequently developed dyspnea symptoms within 1 year, and bronchoscopy revealed granulation and neoplasm in the right main bronchus. Pathology confirmed adenoid cystic carcinoma.Therefore, we choosed PTD for treating tracheal adenoid cystic carcinoma. Pre PDT examination, we did bronchoscopy for mapping of topography

and extent of lesion. Then intravenous administration of the photosensitizer: Hematoporphyrin, 3mg/Kg. After 40–48h, bronchoscopic illumination either interstitial for bulky tumours using a cylindrical diffuser or surface application for flat lesions in lower trachea and right main bronchial opening. Light dose was 200 J/cm(400mw × 500 s).

Results: The patient was symptomatic on admission. There was no pro-cedure related mortality and no record of post PDT complicationsor photosensitivity skin reaction. The symptoms was improvement by PDT. Regular follow-up for 8 months, no obvious airway stenosis was found on re-examination of bronchoscopy, and tracheal mucosal pathology does not suggest neoplastic lesions.

Conclusion: We concerned PDT is a safe and effective treatment modality for adenoid cystic carcinoma particularly in patients unsuitable for surgery and possibly adjunct to surgery. It affords symptoms relief with survival benefit, even in those with previously failed radiotherapy.

PO-081

The changes of the anxiety level of mothers before the operation of tracheoscopy by the way of health education

Hu,Shidong
The second affiliated hospital of wenzhou medical university, YuYing children's hospital

Objective: To discuss the effect of health education on relieving the anxiety of infant mothers before tracheoscopy, and find out the best way of health education.

Methods: 150 mothers of children undergoing tracheoscopy in our department from October to November 2019 were randomly divided into group AB. Mothers of children in group A were given oral education by doctors and nurses and then given paper materials for health education. Mothers in group B, The nurse showed the content of the mission and explained to the PPT. The two groups were given the self-rating Anxiety Scale (SAS) test the day before and after the mission, and the difference between the two groups before and after the mission was statistically significant.

Results: The paired T test before and after health education showed that: Group A had no statistically significant effect on the change of anxiety of mothers (p>, 0.05), while group B had A statistically significant effect on the change of anxiety. The anxiety level of the two groups after education was compared by group T test, and the results were statistically significant ($p<0.05$).

Conclusion: Oral and paper-based education given to the mothers of the children before the operation of tracheoscopy could not effectively reduce their anxiety level. PPT explanation could help the mothers of the children to better understand the role and precautions of tracheoscopy, deepen their impression and reduce their anxiety level.

PO-082

Rosai-Dorfman disease of the trachea: an unusual life-threatening benign tumor

Zhang,Dongmei、Diao,Xiaoli、Xu,Lili、Wang,Zhen、Huang,Kewu、Dongmei Zhang
首都医科大学附属北京朝阳医院

Objective: Rosai-Dorfman disease (RDD), also called sinus histiocytosis with massive lymphadenopathy, is a rare disorder with a prevalence of 1:200 000[1]. About 80% of RDD cases present with painless cervical lymphadenopathy, whereas 43% of RDD cases have the extranodal organs involvement including skin, bone, central nervous system, ear-nose-throat, digestive system, genitourinary tract and respiratory tract [2]. Intrathoracic RDD manifested as interstitial lung disease, pulmonary nodules and tracheobronchial disease is described in 2% of patients [3]. Trachea involvement is rare with less than 20 cases of tracheobronchial RDD being reported. Here we report a case with an unusual life-threatening RDD of the trachea.

Methods: case report

Results: A 34-year-old man presented with seven months of unproductive cough and four months of progressing dyspnea. He denied fever, chest pain, night sweat or emaciation. On physical examination, he showed mild three depression sign and sonorous rhonchi during inspiratory phase, without lymphadenopathy. Chest computed tomography showed an endotracheal mass and irregular thicken of local tracheal wall (Figure 1). The patient underwent flexible bronchoscopy in the other hospital, during which a smooth-surfaced, circumscribed mass was seen encompassing about 90% of his trachea in 4cm under glottis. Pathological analysis of the biopsy was too small to make the diagnosis, and only showed chronic inflammation with lymphocytes and neutrophils infiltration and scattered multinucleated giant cells.

Rigid bronchoscopy combined with flexible bronchoscopy under general anesthesia was performed to completely remove the endotracheal mass using argon laser (Figure 2). The hematoxylin and eosin stain of the mass shows submucosal infiltration of histocytes, neutrophils, lymphocytes, and eosinophils, numerous foamy macrophages and phagocytes with hemosiderin inside. Immunohistochemical stain demonstrate S100+, CD68+, and CD1α-. The biopsy was consistent with RDD. The patient recovered well without shortness of breath after exertion. He is still on regular follow-up, and without any sign of relapse.

Conclusion: Tracheobronchial involvement of RDD is an unusual manifestation of the rare and heterogeneous disorder. It can mimic other tracheal tumors and require careful pathological test. Local therapy to relieve obstruction by rigid bronchoscopy, laser, or surgery is crucial for the management of tracheobronchial RDD. Considering the recurrence in some cases, long-term follow-up is required.

PO-083

Role of Apolipoprotein A-I in inhibiting the progression of granulation tissue hyperplasia to scarring in benign tracheal stenosis patients

Shi,Hui、Ning,Yunye、Bai,Chong
Changhai Hospital

Objective: Repeated interventional treatments can cause damage and stimulation to the mucosa of patients with benign airway stenosis, leading to fibrosis of the granulation tissue and scar formation, resulting in airway restenosis or permanent atresia. Tracheal stenosis, which is dominated by scar tissue replacement, is ineffective in treating distal lesions after intervention. In patients with benign airway stenosis, there are abnormal fibroblasts around the mucosa at the injury site, which promotes tracheal scarring and fibrosis. Apolipoprotein A-I (ApoA-I) is widely recognized as the main anti-atherosclerotic component in high-density lipoprotein (HDL). No research on apolipoprotein and benign airway stenosis has been reported before. The aim of this study was to explore the role and mechanism of a potential new therapeutic agent of ApoA-I mimetic peptide for inhibiting the progression of granulation tissue to scar formation in patients with benign tracheal stenosis.

Methods: Patients with benign airway stenosis (granulation hyperplasia after tracheal intubation, tracheotomy and airway foreign body, etc.) treated by endoscopic operation in our respiratory endoscopy center were collected. Each fifteen benign airway stenosis patients with trachea granulation tissue of fresh hyperplasia and trachea scarring were sampled to detect ApoA-1 level . In addition, patients with benign airway stenosis were collected with bronchoscopy aseptic biopsy forceps to clamp the granulation tissue (avoided using electrocoagulation, laser, cryoablation and other operations before specimens). Subcultured, isolated and identified fibroblasts from the granulation tissue. The cells were treated with the ApoA-1 mimetic peptide D-4F at different concentrations (0, 20, 40, 80 μg/ml) or incubated with D-4F (40 μg/ml) for different times (0, 6, 12, 24 h), CCK-8 method was used to detect the effect of ApoA-1 mimetic peptide D-4F on cell proliferation and viability of fibroblasts, scratch test was used to determine fibroblast migration capacity.

Results: It was found that ApoA1 levels in patients with airway scarring were significantly reduced than those with granulation tissue of fresh hyperplasia ($P=0.037$). We successfully cultured primary fibroblasts from granulation tissue of patients with benign airway stenosis. We first discovered that fibroblasts highly expressing ATP-binding cassette transporter A1 (ABCA1), the transporter of ApoA-1 ($P<0.05$) . ApoA-1 mimetic peptide D-4F could inhibit the proliferation and migration of fibroblasts in vitro. After treated with the ApoA-1 mimetic peptide D-4F, our results showed that the levels of the cytokines, such as tumor necrosis factor-α (TNF-α) 、Interleukin-6(IL-6) and monocyte chemoattractant protein-1(MCP-1), were decreased at both concentration- and time-dependent manners.

Conclusion: ApoA-1 mimetic peptide D-4F could be used as a potential candidate therapeutic agent to inhibit the progression of granulation tissue hyperplasia to scarring in patients with benign tracheal stenosis.

PO-084

A comparative study between electromagnetic navigational bronchoscopy cryobiopsy and transbronchial cryobiopsy in patients with diffuse interstitial lung disease

Luo,Shaohua1,2、Li,Jing1,2、Wang,Longlong1,2、Gao,Xinglin1,2
1. Guangdong Provincial People's Hospital
2. Guangdong Academy of Medical Sciences

Objective: To prospectively evaluate the diagnostic yield and safety of electromagnetic navigational bronchoscopy cryobiopsy(ENBCB) compared with transbronchial cryobiopsy (TBCB) in patients with diffuse interstitial lung disease.

Methods: Thirty-four cases with diffuse interstitial lung disease (DILD) on CT scan, from January to December in 2019, were randomly divided into two groups(16 cases in ENBCB group and 18 cases in TBCB group). The sample size, diagnostic accuracy, pneumothorax and hemorrhage were compared between the two groups.

Results: No significance was observed in sample size(12.15±3.9mm2 vs 11.96±3.6mm2) and diagnostic accuracy(75.0%, 12/16 vs 72.2%, 13/18, P>0.05) between the two groups. There was also no significance in pneumothorax occurrence(18.8%, 3/16 in ENBCB group vs 16.7%, 4/18 in TBCB group). 18.8%（3/16）of ENBCB cases had no hemorrhage, which was similar in TBCB group(22.2%, 4/18). Mild hemorrhage occurred in 43.8%（7/16）of ENBCB cases and 44.4%（8/18）of TBCB cases respectively. Moderate hemorrhage rate in ENBCB group was higher than in TBCB group(37.5%, 6/16 vs 27.8%, 5/18, P<0.05) . However, severe hemorrhage occurred in one of ENBCB cases , who was shock and recovered after balloon blockade and blood volume expansion with vasopressin intravenous infusion.

Conclusion: ENBCB may not increase the diagnostic yield compared with TBCB only in DILD patients. Similar safety was shown in the two sampling methods.

PO-085

Airway remodeling and bronchodilator responses in asthma accessed by endobronchial optical coherence tomography

Su,Zhuquan
广州医科大学附属第一医院

Objective: To evaluate the airway remodeling characteristics and the bronchodilator responses in asthma.

Methods: We recruited 104 asthmatic patients and 31 non-smoking control subjects to compare the airway inner area (Ai) and airway wall area percentage (Aw%) with endobronchial optical coherence tomography. We also enrolled 32 patients with moderate-to-severe asthma to dynamically access the airway morphological changes after salbutamol inhalation.

Results: More prominent airway structural abnormalities correlated with greater asthma severity, evidenced by the decreased Ai and greater Aw% in medium-sized and small airways. Patients with mild asthma yielded comparable Ai but greater Aw% than control subjects. A longer disease duration correlated with lower Ai and greater Aw% from the 3rd to 6th generation of bronchi. Salbutamol inhalation led to a rapid dilatation of both medium-sized and small airways, the lung function improvement correlated significantly with the increase in Ai of the medium-sized, but not small, airways at 15 min.

Conclusion: Luminal narrowing and airway wall thickening of the medium-sized and small airways are present in mild asthma and reflect asthma severity, lending support to the use of anti-imflammatory intervention in mild asthma. The medium-sized airways are the crucial site of the bronchodilator responses, providing the scientific rationale for future development of more effective delivery of inhaled medications for asthma.

PO-086

The effect of low temperature plasma therapy under tracheoscope on the symptoms and pulmonary function of patients with tracheal stenosis

Lliu,jinhua、liujinhua
the Third Hospital of Changsha Liu Jinhua Postal code: 410015

Objective: To study the effect of low temperature plasma therapy under tracheoscope on the symptoms and pulmonary function of patients with tracheal stenosis.

Methods: 52 patients were divided into two groups according to different treatment methods, each group has 26 patients. The control group was treated with cryotherapy combined with balloon dilatation and APC, and the treatment group was treated with low temperature plasma therapy. The curative effect, complication rate and inner diameter of airway after treatment were compared between the two groups.

Results: the total effective rate of the treatment group was higher than that of the control group ($P < 0.05$), the incidence of complications was lower than that of the control group ($P < 0.05$), and the improvement rate of airway diameter, FEV1% and FEV1/FVC were higher than that of the control group ($P < 0.05$).

Conclusion: low temperature plasma can improve the symptoms of shortness of breath and pulmonary function, reduce the incidence of complications in patients with tracheal stenosis, which is better than cryotherapy combined with balloon dilatation and APC

PO-087

Endoscopic treatment of tracheo-oesophageal fistulae: an innovative procedure

Galluccio,Giovanni、Lucantoni,Gabriele、Romani,Sofia、Dello Iacono,Raffaele、Batzella,Sandro
Center of Thoracic Endoscopy, San Camillo – Forlanini Hospital

Objective: Tracheo-esophageal fistulas represent a major complication of prolonged intubation and may cause death. Surgical repair is a complex procedure that can be challenging in compromised patients. In this study, we describe a simple endoscopic technique that resulted in the effective palliation of symptoms. A palliative endoscopic approach, based mainly on the use of a stent,occlusion with fibrin glue or cyanoacrylate has been described although long-term results are not available. Therefore, surgical repair remains the gold standard. However, in compromised patients, surgical repair may be difficult or dangerous, with a recurrence rate of 10–22%. In our institution in recent years, three patients with tracheo-esophageal fistula were treated by endoscopic suturing of the fistula through the tracheotomy. This preliminary experience led to the development of a new technique, even less invasive.

Methods: We present our experience with a totally endoscopic approach based on the suture of a fistula with resorbable stitches. The procedure was performed in a young patient (20 years old) with a congenital tracheo-esophageal fistula , located in the middle third of the trachea 2cm long, and recurrent inhalation pneumonia who refused a surgical approach. He was treated by suturing the tear without external access to the trachea. The patient had rigid bronchoscopy

under intravenous sedation. A rigid telescope (Storz) connected to a camera and a rigid aspirator were inserted through the tube. The fistula was exposed and sutured by means of resorbable stitches (Vycryl© 3.0), using a long needle holder. The knots were tied outside of the tracheoscope and were pushed down with a knot pusher. The surgical thread was cut with a contact Yag laser fiber (Figure 1).

Results: The procedure lasted 40 min, and the patient was discharged after 24 h. He was able to eat normally the same day. After 3 months, the patient was in excellent condition, free of cough and of pulmonary symptoms. A monthly endoscopic examination and CT scan confirmed the stability of the suture, and no recurrence of the fistula was observed.

Conclusion: Our experience demonstrates that an endoscopic suture of the fistula is feasible and may be effective for palliation. Long-term follow-up will indicate whether this procedure may also be considered a definitive intervention.

PO-088

Ultrathin bronchoscopy combined with virtual bronchoscopy and radial-probe endobronchial ultrasound to diagnose small pulmonary peripheral lesions: a retrospective study

Mizumori,Yasuyuki、Takenouchi,Masaki、Hirata,Nobuya、Hiraoka,Ryota、Hirano,Katsuya、Kominami,Ryota、Higashino,Sachiko、Tsukamoto,Hiroaki、Sasaki,Shin、Kawamura,Tetsuji、Nakahara,Yasuharu、Yasuyuki Mizumori
Himeji Medical Center

Objective: To study the effectiveness of transbronchial biopsy (TBB) using ultrathin bronchoscopy with virtual bronchoscopy (VB) and radial-probe endobronchial ultrasound (R-EBUS) in order to diagnose small pulmonary peripheral lesions.

Methods: We retrospectively evaluated a total of 20 patients who underwent TBB using ultrathin bronchoscopy (BF-MP290, Olympus) with VB and R-EBUS (UM-S20-17S, Olympus) at our hospital from April 2019 to January 2020. Bronchoscopy procedures were selected based on the patients' pulmonary lesions at a conference the day before. VB images were created from multidetector computed tomography data (slice width: 1.0 mm) on a three-dimensional workstation (Ziostation2, Ziosoft).

Results: Patients included five women and fifteen men, with a median age of 66 (range: 44–79) years. The lesion sites were the right upper, right lower, left upper, and left lower lung lobes in six, nine, four, and one patient, respectively. The lesion size was 18.0 ± 9.2 mm, and its distance from the pleura was 13.0 ± 11.7 mm (mean ± standard deviation). CT demonstrated pure ground-glass, part-solid, and solid nodules in one, five, and fourteen patients, respectively. The bronchus sign on CT was positive in thirteen patients and negative in seven. The median number of biopsies was nine (range: two to twelve). R-EBUS findings were within, adjacent to, and the blizzard sign in eleven, seven, and two patients, respectively. The median procedure time was 37 (range: 16–77) min. Histological samples were obtained from eighteen patients, and cytological samples were obtained from the remaining two patients. Bronchoscopy confirmed the diagnosis for 19 of the 20 patients (95%). The diagnoses were primary lung cancer, lung metastasis of renal cancer, cryptococcus, and Mycobacterium avium complex infection in sixteen, one, one, and one patient, respectively. The remaining patient was diagnosed with tissue necrosis after surgical resection. No complications were observed.

Conclusion: Although the diagnosis of small pulmonary peripheral lesions using TBB may be challenging, ultrathin bronchoscopy combined with VB and R-EBUS may prove effective.

PO-089

MANAGEMENT OF POST-INTUBATION TRACHEAL LACERATIONS: CONSERVATIVE TREATMENT VERSUS SURGICAL APPROACH

Galluccio,Giovanni1、Cardillo,Giuseppe2、Lucantoni,Gabriele1、Carleo,Francesco2、Carbone,Luigi2、Romani,Sofia1、Di Martino,Marco2、Dello Iacono,Raffaele1、Jaus,Massimo2、Batzella,Sandro1
1. Center of Thoracic Endoscopy， San Camillo – Forlanini Hospital
2. Center of Thoracic Surgery， San Camillo – Forlanini Hospital

Objective： Post-intubation tracheal laceration (PITL) is a rare condition (0.005% of intubations).The treatment of choice has traditionally been surgical repair, although now the literature and clinicians tend to support conservative treatment. Moreover, the group of patients that would benefit from surgical treatment has never been fully defined. Based upon our previously published morphological classification-guided treatment protocol for PITL, we present and validate the rationale for treatment of PITL through the largest ever reported series of patients.

Methods： This retrospective analysis is based on a prospectively collected series of 57patients(2003-2019) with PITL, endoscopically staged and treated according to our revised morphological classification (8 Level I, 35 Level II, 9 Level IIIA, 4 Level IIIB, and 1 Level IV) (Table 1).

Results： Using the morphological classification treatment protocol, all 52 patient-cases with Level I, II and IIIA post-intubation tracheal lacerations were successfully treated conservatively by bronchoscopic application of 1 to 2 ml of fibrin sealant (Tisseel®, Baxter, Deerfield, MA, USA) onto the lesion, covering it with a complete layer (Figure 1) . The 4 patient-cases with a Level IIIB injury and the patient with Level IV underwent a surgical repair of the trachea. No mortality was reported. Flexible bronchoscopy at 7, 28, 90, 180, and 270 days showed no abnormalities. Complete healing was attained in all patient-cases by day 30.

Conclusion： In PITL, our previously proposed morphological classification based upon the depth instead of the length of the injury,has been validated as the major tool for defining the type of treatment, specifically surgical versus conservative management.

PO-090

Application of Personalized airway Y type coated metal stent in right middle bronchial chest gastric fistula

Cai,Saifen、Zhang,Huaping、Zeng,Yiming、Wu,Weijing
The Second Affiliated Hospital of Fujian Medical University

Objective: Purpose: Secondary tracheal-gastrointestinal fistula refers to the damage to the integrity of the airway and gastrointestinal tract caused by various reasons. There are abnormal channels between the airway and the digestive tract, and it is difficult to control lung infection The prognosis is extremely poor. The most common cause is advanced esophageal cancer, especially after surgery, radiotherapy and chemotherapy. Most patients are not suitable for surgery, and the placement of airway stent and / or esophageal stent is currently the most important treatment method. This article aims to explore the treatment of secondary airway-residual gastric fistula in special parts.

Methods: Report the diagnosis and treatment of a patient with secondary right middle bronchial of thoracogastric fistula our hospital.

Results: Female patient, 53 years old. Main Complaint: repeated cough and sputum for more than 1 month. She was admitted to the hospital on December 14, 2018.Two years ago, for "esophageal squamous cell carcinoma", "radical esophageal cancer + left neck anastomosis of gastric esophagus" was performed. Radiation therapy was reissued for esophageal cancer 7 months ago. Physical examination: Body temperature: 36.6℃ , breathing 18 times / min, pulse 65 times / min, blood pressure 123 / 76mmHg. Conscious ,slightly poor nutrition. There was no malformation of the thorax, smooth bilateral breathing, no abnormal tactile tremor, and no pleural friction. On both lungs, there was a voiceless sound on both lungs, thick breathing sounds on both lungs, and small scattered blisters on both lower lungs, with no dry rales or pleural friction. The heart rate is uniform, but no noise. Abdominal examination was normal, liver and spleen were not touched under the ribs, and no edema in both lower limbs. Auxiliary examination: blood routine showed hemoglobin 93g / L, no abnormality; biochemical complete set, blood coagulation complete set, blood gas analysis, electrocardiogram examination showed no obvious abnormalities; chest CT plain scan + enhancement: 1.postoperative changes of esophageal cancer, tracheal bifurcation level The following low-density increased shadows of the thorax and stomach, and enlarged lymph nodes under the trachea; 2. Increased low-density shadows of the lower lungs of the two lungs, considering the possibility of inflammation changes; electronic gastroscopy: narrowing of the anastomosis after esophageal cancer; Pathology (gastric body): acute and chronic mucosal inflammation with erosion and necrosis. Esophageal lipiodol angiography: After CA of esophagus, the anastomosis is narrowed and the esophageal trachea is fistula. Bronchoscopy: a fistula with a diameter of about 7mm is seen at the posterior wall of the right middle bronchus opening, with a small amount of necrosis around. A colorless liquid flows out of the fistula when coughing, and the surrounding mucosa is slightly swollen. A metal staple is visible in the fistula and visible at the distal end. Mucosa of the digestive tract. This patient belongs to the airway-thoracic gastrostoma, and because it has undergone esophageal cancer surgery and radiotherapy, it is an advanced cancer patient and is not suitable for surgery. Interventional treatment is the most reasonable choice. Because the end of the gastrointestinal tract of the fistula is located in the thoracic cavity and stomach, it is not suitable for esophageal stent occlusion, and only airway stent occlusion can be used. However, since the airway end of the fistula is located in the right middle bronchus, the airway stent often requires an individual design. Commonly used airway obstruction fistula stents include silicone stents and covered metal stents. The position of the fistula in this case is quite special, and currently there is no silicone stent of suitable shape. After admission, anti-infection, phlegm reduction, oxygen therapy, duodenal tube-nasal feeding diet, nutritional support and other symptomatic treatments, we combined the characteristics of the disease and measurement results to tailor a Y-coated airway nickel-titanium memory for this patient. Alloy stent. The stent completely covered the fistula after operation. The lumen of the right upper branch and right middle bronchus was unobstructed. No gastric fluid flowed into the airway when coughing. Pulmonary infections were controlled, and symptoms relieved and discharged.

Conclusion: Conclusions: (1) Airway-thoracic gastrostoma is usually treated by placing an airway stent because

of its pathological anatomy. (2) Covered airway nickel-titanium memory alloy stent, due to its good conformability, can be customized at any time according to the needs of different specifications of the shape of the stent, stent endocrine retention rate is low, and other advantages, especially suitable for complex pathological anatomical airway Thoracic gastric fistula.

PO-091

One case of chest castleman disease treated by radiofrequency ablation and literature review

Xu,Feng
Cangzhou city people's hospital

Objective: Castleman's disease (CD) is a chronic lymphoproliferative disease of unknown etiology and is a rare disease. Also known as "giant cell lymph node hyperplasia, vascular follicular lymphoid hyperplasia, lymphoblastoma", etc., which was first reported by Castleman in 1954 , the etiology and pathogenesis of this disease have not yet been clarified.A case of Castleman's chest disease admitted to our hospital is now discussed in combination with symptoms and signs, clinical examination, corresponding treatment, prognosis and literature review to enhance the familiarity with this disease.

Methods: Radiofrequency ablation

Results: The patients were followed up after discharge with good quality of daily life

Conclusion: A case of Castleman in the chest was treated with minimally invasive local radiofrequency ablation, and a good result was obtained, in order to provide a reference for similar situations in the future, and further study was suggested.

PO-092

Therapeutic Flexible Bronchoscopy in Infant Aspiration Pneumonia: A Case Report

Aldiani,Airin1、Alatas,M. Fahmi1、Sagoro,Tjatur Kuat2、Soehardiman,Dicky1
1. Department of Pulmonology and Respiratory Medicine， Faculty of Medicine University of Indonesia – Persahabatan Hospital Jakarta， Indonesia
2. Departement of Pediatric Persahabatan General Hospital， Jakarta – Indonesia

Objective: Aspiration pneumonia known as a result from the oropharyngeal, esophageal, or stomach contents passage into the lower respiratory tract. Milk aspiration could lead to central apnea and asphyxia due to laryngospasm, or airway obstruction. Early diagnosis and management of aspiration will help contribute to the best possible outcome in infants.

Methods: In this, study we present a case of infant aspiration pneumonia treated with flexible fiberoptic bronchoscopy (FFB).

Results: Flexible fiberoptic bronchoscopy showed milk aspiration in the intermediate branch and the upper lobe of the left lung, and BAL was performed to relieve the symptoms. The patient showed clinical and radiological improvement following the procedure.

Conclusion: Flexible fiberoptic bronchoscopy in infants, particularly of less than 2 years old, is a relatively safe procedure with a very low incidence of significant complications. No need to delay the procedure when indicated.

PO-093

IMPACT OF SEDATION TYPE ON THE DIGNOSTIC YIELD OF EBUS-TBNA: A META-ANALYSIS

Bao,Chongxi、Kong,Jinliang、Wang,Ke、Cai,Shuangqi、Lu,Huasong
广西医科大学第一附属医院

Objective: To investigate the difference of EBUS-TBNA diagnostic yields between deep sedation (DS) and moderate sedation (DS).

Methods: We searched the databases of PubMed, Embase, Cochrane library, CNKI, and VIP until May 2019. Studies reporting the comparison of deep sedation and moderate sedation for EBUS-TBNA diagnostic yields were identified. The overall diagnostic yields, lymph node size, procedure time, and the complication rates were evaluated in the Meta analysis.

Results: Seven studies involving 2408 patients were finally included in our analysis. The pooled OR (95% CI) for the overall diagnostic yield of EBUS-TBNA was 1.20 (0.98-1.46), respectively, suggesting no statically significant difference between DS and MS groups. For the procedure time, the pooled SMD (95%CI) was 0.49 (0.21-0.76，p=0.0005), indicating that the longer procedure duration of DS group than the MS group. Besides, no difference was observed for the lymph node size, the number of lymph node sampling, and the complication rates between the comparable groups. SMD (95%CI): -0.28（-0.70-0.14，p=0.19）； 0.20（-0.77-1.16，p=0.69），OR (95%CI): 0.62 (0.20-1.91，p=0.40). The Funnel plot, the Eggers test, and the Begg test suggested no publication bias.

Conclusion: The diagnostic yields of EBUS-TBNA operated in deep sedation or moderate sedation had no statically significant difference. The procedure time in the deep sedation group was longer than the moderate sedation group. However, for the lymph node size, lymph node samples per patient, and the complication rates, no statically significance was observed in our analysis.

PO-094

Bronchoscopic Instillation Of Recombinant Factor VIIa In an Elderly COPD Mechanically Ventilated Patient with DAH – An Interesting Case Report

CHACHRA,VAIBHAV1、UNIYAL,BHUPESH1,2、SINHA,ANUMITA1,3
1. Max Super Speciality Hospital Dehradun
2. Max Super Speciality Hospital Dehradun
3. Max Super Speciality Hospital Dehradun

Objective: Diffuse alveolar hemorrhage (DAH) is a serious pulmonary complication usually seen either secondary to autoimmune diseases or a patient on ongoing chemotherapy/ post chemotherapy or stem cell transplantation.It has been seen DAH linked to the release of inflammatory cytokines, which are involved in alveolar capillary endothelial injury and inflammation which causing the expression of the intraalveolar tissue factor (TF),causing an increase in the markers of thrombin generation as seen in bronchoalveolar lavage (BAL) fluid[1-3] . There are 3 different patterns described histopathologically:subclinical hemorrhage,capillaritis and diffuse alveolar damage[4].Here we had a 85 Gentleman known case of COPD with PTB sequlae with LLZ fibrosis on domicillary BiPaP and oxygen support came to the ER with increase in oxygen requirement with difficulty in breathing progressed since 2 days.Patient had raised procalcitonin levels and worsening of respiratory distress he further was intubated and went in septic shock for which ionotropic support was required.On day 2 of ventilation patient had frank bleed and ventilation became difficult.

Methods: An urgent bronchoscopy done revealed fresh ooze from Rt upper lobe anterior segment,Lower lobe superior and left lingula.Multiple aliquots of xylocaine+adrenalin/cold saline flushes,intrabronchial instillation of tranexamic acid/hemocoagulase were tried but of no use.

Results: As hemostasis could not be achieved rFactor VII was used by diluting in 19ml Normal saline and 7ml(700mcg) was instilled in each segment followed by inflating the fogarty cather inflation for 40seconds in each sub-segment to prevent spillage of the same along with positioning of the patient.Bleeding rapidly ceased within 45minutes post procedure,with improvement in oxygenation and hemodynamics.Also leading to improvement in ventilation of the patient.

Conclusion: Intravenous recombinant activated Factor VIIa (rFVIIa) produced by the transfection of the human factor VII gene into clustered hamster cells is approved as a hemostatic agent for only a few bleeding disorders. The off-label use far exceeds the use for approved conditions.As tissue factor is expressed in the lung alveoli during inflammation and therefore pulmonary administration of human recombinant activated factor VIIa(rFVIIa) seems to be a rational treatment option for the same.It has been observed that endobronchial instillation of rFVIIa to control alveolar hemorrhage has been published in only a few case reports across the globe.However here we report the first successful case in the state and the country wherein 2 segments of the same Lung and a single segment of another was instilled with endobronchial rFVIIa for life-threatening pulmonary hemorrhage in a patient Of COPD with septic shock with DAH,followed by fogarty cather inflation thereby minimizing the spillage,lesser dosage required and a successful procedure.

PO-095

Initial experience with EBUS TBNA for the management of lung cancer in an Andean Latin American country: Peru

Garcia-Mantilla,Pedro Francisco、Castro-Bernardini,Socorro
SANNA San Borja Private Medical Center

Objective: Since its introduction in clinical practice in 2004, EBUS-TBNA has become the standard of care in the management of lung cancer in developed countries. However, a significant number of tertiary health facilities in Latin America still do not have access to this technology, and continue to make the diagnosis and staging of lung cancer with invasive thoracic surgeries and imaging techniques (contrast CT, PET scan). In Peru, a middle-income country with high prevalence of tuberculosis and high levels of pollution in its main cities, mediastinoscopy is not performed regularly and mediastinal staging is mostly non-invasive. We herein describe the initial experience over one year on the utility of EBUS-TBNA from a tertiary healthcare private center in Lima, Peru.

Methods: EBUS-TBNA was performed in 12 patients. Selection of the patients for EBUS -FNA was based on contrast computed tomographic (CT) scanning in 07 patients and on positron emission tomography in five. The video ultrasound bronchoscope for guided TBNA used was a PENTAX EBUS EB-1970UK with an outer diameter of 6.3 mm and a working channel of 2.0 mm. The instrument has a small curved array transducer in the distal end and a 75-degree ultrasound scanning angle with real-time visualization of the needle tip, increasing aspiration efficiency and detection. The procedures were performed under general anaesthesia in the operating room at SANNA San Borja Private Clinic in Lima, Perú. EBUS -FNA was performed by direct transducer contact with the trachea or central airway bronchi with a EchoTip® Ultra Endobronchial HD Ultrasound 22 Gauge Needle. Rapid on-site evaluation was not available and the samples (cell-blocks, cytology slides and needle wash) were sent directly to the pathology laboratory. We recorded location of the lesion in the mediastinum as per the International Association for the Study of Lung Cancer classification, and definitive diagnostic result (EBUS with a diagnostic biopsy).

Results: A total of 22 lesions were punctured, 19 were adenopathies and 03 were lung nodule. No complications were experienced. Ten lesions were targeted in region 7, four in region 4L, four in region 4R, and one in region 11Rs.

The size of the lesions ranged from 7 mm to 20 mm. A definitive diagnosis was established by EBUS-TBNA in all cases identifying malignant cells in 15 lesions and benign cells in seven. In one of our lung cancer staging cases the EBUS-TBNA negative samples (regions 4L, 7, 4R) were true negatives, confirmed on surgical resection specimens. All of our EBUS-TBNA negative node samples contained significant amount of lymphoid tissue, with or without benign appearing respiratory epithelial cells and epithelioid histiocytes. One of these cases was unique in our setting, because it was a positive PET adenopathy 4R with a final diagnosis of anthracosis.

Conclusion: Endobronchial Ultrasound guided Transbronchial Needle Aspiration (EBUS-TBNA) is the standard approach for the diagnosis and mediastinal staging of lung cancer in the developed world and in most middle-income Latin American countries. It is also a valuable and practical tool for re-staging and recurrence evaluation of Non-Small Cell Lung Cancer. In this era of oncology precision medicine, there is a need to ensure timely and equitable access to EBUS for lung cancer patients in Latin America and avoid invasive surgeries and inaccurate diagnosis and staging. EBUS-TBNA has recently been introduced in Peru in the private healthcare setting. Our EBUS service is currently the only one in Lima, the largest city in Peru, and the country’s capital. Lima´s population is almost 10 million people. However, clinical pulmonologists, oncologists and thoracic surgeons still refer us few cases. It is well known that in some settings clinicians are so poor at adhering to Clinical Practice Guidelines. Maybe they also need to be able to overcome the inertia of “normal practice” and understand the need for change. The initial experience with this technique for the management of lung cancer is very promising with a very high diagnostic yield and effectivity. Our results support us to continue with our EBUS services and provision them in a Lung Cancer Network. It will raise the standards of care in the thoracic oncology of Peru and Latin America.

PO-096

One case of lung cancer misdiagnosed as pneumonia

Wang,Shuang、Shi,Haotian、Li,Caihong、Wang,Chunxiu、Xu,Lixin、Jin,Jingjing、Xu,Tiantian、王爽
Affiliated hospital of north China university of science and technology， tangshan city， Hebei province

Objective: Objective: The diagnosis of pneumonic lung cancer is difficult, the clinical manifestations are non-specific, and the imaging manifestations are similar to pneumonia, so early diagnosis is difficult.

Methods: This report reports a 70-year- old man with recurrent pneumonia, who improved after treatment but developed new pulmonary infection and was finally diagnosed with lung cancer. Physical examination revealed redness and swelling of the pharynx, shallow and rapid breathing, and thick breath sounds in both lungs . It could be asked that no lymph node enlargement was detected and no significant weight reduction was observed. Laboratory evaluation showed leukocytosis, positive antibody to respiratory syncytial virus IgM, elevated procalcitonin and erythrocyte sedimentation rate, and no abnormality in the male tumor series. Chest CT showed inflammatory lesions in the left lung and the lower lobe of the right lung, and multiple nodules in the middle and lower lobe of the right lung.

Results: Results: Bronchoscopy indicated that the opening of the upper lobe of the right lung was a neoplasm. Brush examination: abnormal cells were found and non-small cell lung cancer cells were considered. Pathology: squamous cell carcinoma in situ with necrosis.

Conclusion: Conclusion:Further bronchoscopy should be performed for recurrent infection in one site or new infection in another site after active anti-infection treatment. This is highly specific for patients with pulmonary lung cancer, which can be diagnosed early and avoid the delay of the disease.

PO-097

Endobronchial ultrasound-guided transbronchial biopsy for ground glass opacity：a case report

Sun,Danxiong、孙丹雄
First People's Hospital of Yunnan

Objective： Computed tomography-guided percutaneous transthoracic needle biopsy（CT-PTNB） was reported as effective in giving value to the nature of ground glass opacity（GGO）. However, the complication rates observed with endobronchial ultrasound-guided transbronchial lung biopsy （EBUS-TBLB）were lower than those reported for computed tomography-guided percutaneous transthoracic needle biopsy. Here we report a case presenting with pulmonary mixed ground glass opacity, who was successfully diagnosed by endobronchial ultrasound-guided transbronchial lung biopsy, and discuss the value of endobronchial ultrasound-guided transbronchial lung biopsy in evaluation of ground glass opacity.

Methods： A 52-year-old woman presented to our department with abnormal pulmonary shadow found in annual health check-up. She had no respiratory symptoms. She was a non-smoker, and normally well. Chest computed tomography revealed a mixed ground glass opacity measuring 1.9 cm by 1.4 cm in the apical and posterior segments of the superior lobe of the left lung.Her blood tests were all normal (full blood count, blood coagulation function, liver function, renal function, blood electrolytes, fasting blood glucose, alpha-fetoprotein, carcinoembryonic antigen, cancer antigen 199, cancer antigen 125, cancer antigen 153, cancer antigen 724, neuron-specific enolase, cells Keratin fragment-19).12-lead ECG was normal.

Results： Bronchoscopy was performed under local anesthesia. The endobronchial ultrasound image through left B1+2b revealed low-echoic lesion located adjacent to. endobronchial ultrasound-guided transbronchial lung biopsy was performed and the cytological examination showed pulmonary adenocarcinoma.

Conclusion： Endobronchial ultrasound-guided transbronchial lung biopsy is feasible. It is effective in giving value to the nature of ground glass opacity. Although the yield remains lower than that of computed tomography-guided percutaneous transthoracic needle biopsy, the procedural risks are lower. We recommend that endobronchial ultrasound-guided transbronchial lung biopsy be given as a choice for the evaluation of ground glass opacity, especially for a relatively large diameter mixed ground glass opacity.Further studies are indicated to assess the possible role of endobronchial ultrasound as a potential imaging method of choice for the biopsy of peripheral pulmonary ground glass opacity.

PO-098

Discussion of the clinical value of electronic bronchoscope brush inspection in the treatment of children with refractory Mycoplasma pneumoniae pneumonia

He,Xin、Wu,Yanjun、Wang,Wei、Xu,Bo、Jia,Nan、Yao,Zhigang
Beijing Friendship Hospital, Capital Medical University

Objective: Refractory Mycoplasma pneumoniae pneumonia increased year by year, resulting in prolonged course of disease and a series of complications that affected the quality of life of the children. However, in pediatric electronic bronchoscopy, Bronchoalveolar lavage is often used in clinical treatment, while electronic bronchoscopy brush is rarely used in clinical treatment. To discuss the clinical implications of protected specimen brush inspection with electronic bronchoscope in the treatment of children with refractory Mycoplasma pneumoniae pneumonia.The purpose of this study was to investigate the clinical value of bronchoscopy for refractory Mycoplasma pneumoniae pneumonia.

Methods: A retrospective analysis was performed on hospitalized 71 patients with refractory Mycoplasma pneumoniae pneumonia under the electronic bronchoscopy in Beijing Friendship Hospital from May 1, 2009 to May 31, 2019. The patients were divided into two groups: the atelectasis group(n=27) and the pulmonary consolidation group(n=44). Then according to the different operations performed under the electronic bronchoscopy, the patients were further divided into the bronchoalveolar lavage group and the bronchoalveolar lavage combined bush inspection group. In the atelectasis group, 11 patients only examined bronchoalveolar lavage, and 16 patients examined both bronchoalveolar lavage and brush inspection. In the pulmonary consolidation group, 23 patients only examined bronchoalveolar lavage, and 21 patients examined both bronchoalveolar lavage and brush inspection. The clinical value of the different operations performed under the electronic bronchoscopy in the treatment of atelectasis and pulmonary consolidation patients was collected and compared.

Results: In the atelectasis group, compared with the patients who only examined bronchoalveolar lavage, the inflammatory absorption was more pronounced in those who examined bronchoalveolar lavage combined brush inspection one week after the treatment [43.8%(7/16) vs 9.1%(1/11), $\chi 2=6.619$, P=0.037]. In the pulmonary consolidation group, compared with the patients who only examined bronchoalveolar lavage, the inflammatory absorption was more pronounced in those who examined bronchoalveolar lavage combined brush inspection one week after the treatment [57.1%(12/21) vs 17.4%(4/23), $\chi 2=7.625$, P=0.022].

Conclusion: The patients with refractory Mycoplasma pneumoniae pneumonia, on the basis of drug therapy, brush inspection should be applied as soon as possible to promote lung lesions absorption, shorten course of disease, reduce the occurrence of sequelae and improve the prognosis. Electronic bronchoscope brush inspection has positive therapeutic significance.

PO-099

Application of Narrow-Band Imaging thoracoscopy in diagnosis of pleura lesions.

Zhang,Xinglu、Wang,Feng、Tong,Zhaohui
Department of Respiratory and Critical Care Medicine， Beijing Chaoyang Hospital

Objective: Patients with undiagnositic pleura effusions are routinely examined by conventional medical thoracoscopy under the white light (WLT). Because of the variety of appearance of pleura lesions, some of them are missed during the diagnostic process. Narrow-Band Imaging (NBI) has been applied as an effective diagnostic tool to endoscopy. However, there is also controversy about its value in the application of thoracoscopy. The objective of this study was to investigate the efficacy of NBI technology for the diagnostic reliability of thoracoscopy by the application of NBI in diagnosis of pleura lesions.

Methods: Patients with undiagnosed pleural effusion admitted to our clinical center between September 2017 and September 2019 were enrolled. During the thoracoscopy , we performed WLT mode first to get a macroscopic impression and then by NBI. Pictures of endoscopic real-time lesions were recorded under two modes, and at least 5 pieces of tissue were taken respectively on the lesions of pleura. Biopsy specimens obtained under this two modes were respectively taken for pathologic analysis. Diagnostic sensitivity, specificity were calculated to compare them with the gold-standard—pathologic diagnosis.

Results: Among 100 eligible patients enrolled into this study, 63 cases were diagnosed with malignancy, 23 with tuberculous pleurisy, 3 with systemic disease and 11 cases with negative condition. Compared with pathological results, the sensitivity of WLT and NBI was 91.01% and 84.27%, respectively. The specificity of WLT and NBI was 27.27% and 81.82%, respectively. Compared NBI with WLT, the former's specificity is superior to the latter, which is statistically significant ($P < 0.05$).

Conclusion: The advantage of NBI lies in its high specificity. We have concluded that it is useful to diagnose unknown pleural effusions in clinical practice. With better visualization of blood vessels via the application of NBI, we can enhance the accuracy of biopsy and reduce the risk of unexpected bleeding arose from biopsy.

PO-100

A novel drug-eluting tracheal stent can reduce the granulation tissue formation in a canie model with tracheal stenosis

Chen,Feng、Zhang,Jie
Beijing Tiantan Hospital affiliated to Capital Medical University

Objective: To evaluate the safety and effectiveness of a rapamycin drug-eluting stent compared with a bare metal stent in a canine model with tracheal stenosis.

Methods: Six beagle dogs with comparable tracheal stenosis were randomly divided into two groups:drug-eluting stent(DES) group and bare metal stent(BMS) group.Before stent insertion,all the tracheal stenosis were carefully evluated and were dilated with tracheal ballon,and then the rapamycin drug-eluting stents were placed in the stenosis of Beagle dogs in DES group ,while,the bare metal stents were inserted in the stenosis of BMS group.The endoscopic evaluation were carried out every two weeks after the operation,the symptoms of the dogs,the granulation tissue formation,scores of inflamation in the airway mucosa were recorded.After three months' observation,all the Beagle dogs were euthanized and the trachea were dissected, Samples from the trachea that around the stent were taken and made into pathologic slides to examined under the microscope. H&E staining of the samples were conducted and further evaluation of tracheal tissue was taken under the microscope.

Results: All the dogs in the both two groups presented slightly coughing after stenting,there was no other symptoms such as loss of appetite,fever or dyspnea in the first two months.The beagle dogs in BMS group presented exerted dyspnea two months after the stent insertion, of which,one dog was euthanized ten weeks after stenting because of sever dyspnea.Generally, in endoscopic evaluation, the granulation tissue proliferation occurred 2 weeks after the stenting in BMS group and gradually caused a tracheal stenosis from 35% to 95%. At the same time ,the scores of inflamation in the airway mucosa in BMS group were relatively higher than DES group(2.33 ± 0.82 vs 1.07 ± 0.26,$p < 0.05$).However,in DES group,the proliferation of granulation tissue was relatively slight than BMS group. Samples from the trachea that around the stent in DES group revealed an obvious decrease in granulation tissue formation than BMS group.

Conclusion: The rapamycin drug-eluting stent can reduce the granulation tissue formation of tracheal stenosis in a canine model,futher experiment should be carried out in humans in the future.

PO-101

Bronchoscopic Intratumoral Injections of Cisplatin and Endostar as Concomitants of Standard Chemotherapy to treat Malignant Central Airway Obstruction

Yin,Bin1、Yang, Xiaoping 1、Wang,Xuekun2、Li,Yue1、Yang, Xinai1、Wang, Na1、Jiang,Wenqing1
1. Department of Respiratory Diseases, Qingdao Haici Hospital, Qingdao, China
2. Qingdao Central Hospital, Department of Cardiovascular Medicine

Objective: In the present study, we summarized our recent experience in exploring the feasibility of endobronchial intratumoral injection of cisplatin and Endostar time-staggered concomitant with systemic chemotherapy as a treatment option for patients with inoperable advanced NSCLC and symptomatic central airway obstruction（CAO）. We assessed clinical parameters and performed imaging and histopathological analyses of 10 participants with different NSCLC subtypes up to three months after treatment.

Methods: Between December 2016 and March 2017, 10 patients (7 men and 3 women, mean age 70.3±4.4 years) with symptomatic malignant CAO were selected for intratumoral cisplatin and Endostar (Simcere Pharmaceutical Co., Ltd., Nanjing, China) combination treatment at the Department of Respiratory Diseases, Qingdao Haici Hospital. All treatments were carried out under local anesthesia via a flexible bronchoscope (OlympusBF-1T260). Before surgery, 2% lidocaine spray was used to numb the pharynx and larynx.Continuous intravenous infusion of propofol remifentanil was applied during the operation.Intratumoral injections were performed using a bronchoscope-specific injection needle (Shanghai Elton, Model: AF-D1810PN). Patients were treated initially by tracheal tumor debulking under flexible bronchoscopy and followed by direct drug injections into the residual tumor body. Injections were carried out in a fanning manner to disperse the drug throughout the tumor. 15 mg Endostar and 20 mg cisplatin were diluted into 4ml and for each time, a volume of 0.5 ml was injected into 4-6 sites. The piercing depth of each injection was about 3-4 mm. The first endobronchial intratumoral treatment was performed immediately following tumor debulking (one day before initiation of systemic cisplatin based chemotherapy) and three additional treatments were carried out on day 2, day 6 and day 10 (4treatment sessions in total) post systemic chemotherapy. One month past last injection,patients were checked for blood routine test, liver and kidney function, sputum culture, lung function, chest CT, KPS and shortness of breath score, and also received bronchoscopy to observe the changes of tumor size and morphology. In addition, tumor specimens were collected from several sites for pathological studies. The same examinations were carried out every month until tumor progression was observed (airway obstruction exceeding 50% of the lumen). At any time during the course of the study, if any objective evidence indicating tumor.

Results: All 10 patients completed the study including 4 intratumoral injections and 3 months follow-up. All patients responded to the intratumoral treatment of cisplatin and Endostar concomitant with systemic chemotherapy. 1 month post treatment, greater than 50% relative reduction in airway obstruction (CR+SR) was observed in 9 of 10 patients, and only one participant showed a moderate remission. Noteworthy, 3 months after the last injection, airway patency was still stably established. Only one participant with squamous cell carcinoma showed a reduction in airway diameter, but was still classified significant remission. The clinical remission rate achieved 90% (table 2) and lasted the entire 3 months follow-up, and all patients benefited from the treatment (100% beneficial rate).

Conclusion: This study demonstrates that intratumoral injection of cisplatin plus anti-angiogenic Endostar is a feasible adjuvant therapeutic option to treat malignant CAO in clinical practice. 10 NSCLC patients with symptomatic CAO underwent endobronchial cisplatin and Endostar co-injection next to systemic chemotherapy. Bronchoscopy and CT scanning detected a massive and stable airway widening after treatment. A substantial improvement of lung function was confirmed by increased FEV1/FVC ratio and KPS, as well as reduced shortness of breath score. Histopathological analyses identified various degrees of tumor necrosis accompanied by inflammation and fibrosis. No severe side effects were observed during the study.

PO-102

A case study of Papillary squamous cell carcinoma treatment using Endotracheal injection of Cisplatin and Endor combined with Microscopic tumor-reducing therapy

Jiang,Wenqing、Li,Yue、Yin,Bin、Yang,Xiaoping
Department of Respiratory Diseases, Qingdao Haici Hospital, Qingdao, China

Objective: Squamous cell carcinoma (SCC) is a kind of malignant epithelial tumors originating from bronchial epithelium, showing keratosis and/or intercellular bridges. Papillary squamous cell carcinoma (PSCC) is an extremely rare variant subtype of SCC, which manifests itself as a unique intrabronchial papillary growth pattern. Because of its malignant pathological classification, surgery and chemotherapy are commonly used in the treatment of SCC., the patient burden is heavy. Our goal is to strengthen the understanding of pathological typing of PSCC and to explore the clinical efficacy of electronic bronchoscopic interventional therapy for isolated papillary squamous cell carcinoma (SPSCC) in the airway.

Methods: A case of endotracheal and extratracheal papillary squamous cell carcinoma admitted to the Department of Pulmonary Disease of Qingdao Haici Medical Group in December 2016 was analyzed. The efficacy and complications of endotracheal interventional therapy were followed up.

Results: The patient completed the treatment and follow-up. After the operation, the original airway stenosis was significantly improved, the symptoms of cough and wheezing were alleviated, and the interventional therapy under the mirror achieved the desired effect. Postoperative shortness of breath score 1 point, KPS score 90 points, PS score 1 point. Improvement of dyspnea severity classification (mMRC) score: dyspnea score decreased from 3.0 before operation to 0 after operation. Chest CT was reviewed every three months. Up to now, no new lesion was found in the lesion site, and the mucosa of the primary lesion was smooth and no recurrence was found.

Conclusion: (1) Isolated papillary squamous cell carcinoma is rare and easy to be misdiagnosed, which can be diagnosed by electronic bronchoscopy and communication with pathology department; (2) Low-grade bronchial malignant tumors of exophytic papillary squamous cell carcinoma subtype, such as non-metastasis on pre-examination, especially in patients who can not tolerate systemic treatment, may be considered for electronic bronchoscopy. Endoscopic interventional therapy combined with submucosal injection can achieve better clinical efficacy.

PO-103

Bronchoscopy findings in laryngeal and tracheobronchial involvement in Wegener's granulomatosis

Peposhi,Ilir、Nuredini,Ornela 、Teferici,Alma 、Miha,Vasil
Albanian

Objective: To describe the endoscopic abnormalities found in the airway mucosa of a group of six patients with WG undergoing bronchoscopy in University Hospital Lung Diseases Tirana Albania from 2008 to 2019. Wegener granulomatosis (WG) is characterized by a necrotizing granulomatous vasculitis. The most frequent airway manifestations include subglottic stenosis and inflammation, tracheal and bronchial stenosis. The endoscopic visualization of the airways is the best tool for assessing, diagnosing and managing those changes. The diagnosis can be approached on the basis of pattern recognition. However, other diagnostic possibilities must be considered, such as infection, acute respiratory distress syndrome, and complications of medicines.

Methods: We report 6 cases with subglottic and endobronchial stenosis patients diagnosed with GW vasculitis referred for bronchoscopy from Service of Pulmonology. Bronchial stenosis is rare in the course of WG, and occurs

even more rarely than subglottic stenosis.

Results: Six patients were studied [2 females and 4males]; mean age, 29 ± 15.5 years. Airway changes were found in all of the patients, and the most frequent endoscopic finding was airway stenosis. Therapeutic bronchoscopy was performed in one patient with subglottic stenosis and in other three patients with bronchial stenosis, all showing good results. One patient female dead for 11 mounth after diagnosis from multilobar pneumonia

Conclusion: The pulmonary manifestations of small-vessel vasculitis are nonspecific and often overlap with other conditions. Consequently, the diagnosis and management of pulmonary vasculitis are complex and require special attention to detail. The hallmark manifestation of granulomatosis with polyangiitis (GPA [Wegener’s granulomatosis]) is necrotizing granulomatous inflammations, but the pulmonary manifestations can include nodules, cavitary masses, airway stenosis, and alveolar hemorrhage. Wegener's granulomatosis can cause alterations in any segment of the airways, including inflammation, ulceration, pseudomembranes, traqueobronchomalacia, destruction of cartilages, endobronchial masses, and laryngeal tracheobronchial stenoses. Respiratory endoscopy allows for the diagnosis and treatment of several manifestations in a minimally invasive way, avoiding surgical procedures. Bronchoscopy allows for diagnosing, monitoring, and treating the airway lesions in WG.

PO-104

The effect of chemotherapy combined with 125I seed implantation on advanced non-small cell lung cancer (NSCLC) and the changes of serum carcinoembryonic antigen (CEA) and cytokeratin 19 (CYFRA21-1) levels

Yang,Dongyong、Lin,Huihuang、Fan,Jimin、Lin,Zengwei、Wang,Yi、Shong,Duanhong
Second Affiliated Hospital of Fujian Medical University

Objective: To evaluate the efficacy of chemotherapy combined with 125I seed implantation in the treatment of advanced non-small cell lung cancer (NSCLC) and the changes of serum carcinoembryonic antigen (CEA) and cytokeratin 19 (CYFRA21-1).

Methods: 90 NSCLC patients were divided into two groups according to different treatment methods: combined group (46 cases) was treated with chemotherapy combined with 125I seed implantation; control group (44 cases) was treated with chemotherapy alone. The changes of serum carcinoembryonic antigen (CEA), cytokeratin 19 (CYFRA21-1), postoperative quality of life, complications, local effective rate and long-term survival rate were compared between the two groups.

Results: The total effective rate of the combined group was 70.4% in three months after operation, which was significantly higher than that of the control group (38.5%) ($P < 0.05$). The effective rate of the combined group was 74.7% in three months after operation, and 59.0% in adenocarcinoma; the effective rate of the control group was 40.2% in three months after intravenous chemotherapy, and 36.5% in adenocarcinoma. The median survival time was 16.7 months in the combined group and 10.6 months in the control group. The cumulative survival rates of the combined group in 1 and 2 years were 69.2% and 30.6% respectively, and 38.6% and 12.0% in the control group. The survival rate of the combined group was significantly better than that of the control group ($P = (P < 0.05)$). The decrease of CEA in the combined group was significantly higher than that in the control group ($P < 0.05$). The decrease of CYFRA21-1 level in one month after operation was significantly higher than that in the control group ($P < 0.05$).The decrease of CEA in the combined group was significantly higher than that in the control group ($P < 0.05$). The decrease of CYFRA21-1 level in one month after operation was significantly higher than that in the control group ($P < 0.05$).

Conclusion: chemotherapy combined with 125I radioactive particles is a safe and effective interventional therapy for advanced NSCLC

PO-105

Double Y-shaped stents for bronchial mediastinal fistula and bronchial stenosis: A case report

zhang,jinzhen、Zeng,Yiming、Zhang,Huaping
The Second Affiliated Hospital of Fujian Medical University

Objective: To share a case of bronchial mediastinal fistula and bronchostenosis treated with double Y-shaped stents under bronchoscope，and to provide more possibilities for the treatment of patients with bronchial mediastinal fistula and bronchostenosis.

Methods: The patient was a 59-year-old male, and was admitted to the hospital in 2019-10-09 mainly because of "repeated cough, sputum, and asthma for more than one month, aggravated by 10 days". Computer tomography showed:bilateral pneumonia, trachea and left main bronchus stenosiscervical and thoracic tracheal stenosis.This patient had previous history of radiotherapy and chemotherapy for esophageal cancer, so the narrowing of the trachea and left main bronchus may be due to esophageal cancer invasion.This patient received bronchoscope in 10-11. We can see it under the bronchoscope:We can see under bronchoscopy: a huge fissure-like ulcer is seen from the right wall of the lower part of the trachea to the opening of the right upper lobe, about 30mm long.The left main bronchial tube has external pressure stenosis at the opening, about 20 mm long. This patient received bronchial stent placement in 10-23，and The operation went smoothly. The position and expansion of the two Y-shaped stents in the airway were good, completely covering the left main bronchial stenosis, trachea and right main bronchial fistula. The diameter of the left main bronchus is about 8mm, and the lumen of each branch at the distal end is unobstructed. And The bronchial lumen of each lobe of the right lung was unobstructed. The position and expansion of the two Y-shaped stents in the airway were good, completely covering the left main bronchial stenosis, trachea and right main bronchial fistula. The diameter of the left main bronchus is about 8mm, and the lumen of each branch at the distal end is unobstructed.

Results: After the treatment of double Y-shaped stents placement, the patient's originally narrow left main bronchus became unobstructed, and the right lower tracheal fistula was completely covered. The patient's cough, sputum, and asthma were significantly better than before.

Conclusion: Airway stent is the main method for treating patients with tracheal mediastinal fistula and bronchoconstriction, and often requires personalized design.

PO-106

Photodynamic Therapy (PDT) for Tracheobronchial Carcinoma as an Effective and Palliative Treatment: A Small Case Series

Sun,Wen、Wang,Guang-Fa、孙雯
Peking University First Hospital

Objective: Backgroud: The purpose of the study was to evaluate the effectiveness of photodynamic therapy (PDT) for disease palliation in patients with inoperable tracheobronchial carcinoma, although surgical resection was the treatment of choice whenever possible.

Methods: Methods: Retrospective data were obtained from patients treated with PDT for tracheobronchial carcinoma at the Peking University First Hospital between March 2019 and November 2019. Demographic data as well as clinical data and response were collected. All patients were checked clinically, radiologically and bronchoscopically, and diagnosed by surgical or endoscopic biopsy. Patients receiving PDT were given 3 mg/kg hematoporphyrin® intravenously, followed illumination using diffusing fiber at wavelength of 630 nm generated by a diode laser 48h later.

The light dose of lesions was different between 114 to 400 J (200-450mW). Follow-up was at 1–5 months and repeat PDT if necessary.

Results: Results: Five patients, 3 male, 2 female, aged 49–73 years with unresectable tracheobronchial carcinoma were treated with PDT. Cough (100%), hemoptysis (60%) and dyspnea (40%) were the most frequent manifestations. Among all the cases, 4 patients had primary tracheobronchial carcinoma (three adenoid cystic, one squamous histology), 1 had secondary squamous cell carcinoma of the trachea and bronchus, and 1 had suspicious metastases. Malignant lesions were observed in the area of the maximum airway stenosis in all patients. The length of lesions for PDT ranged from 1.5-5cm. Treatment was well tolerated. One patient received subsequent PDT and developed a mild photosensitive reaction. All patients has been followed up. Until today, they all had symptomatic relief, 4 of which received partial response, and 1 had a complete response for 1 month.

Conclusion: Conclusions: Taking all these factors into consideration, PDT is safe, provided effective palliation generally, and plays an important role in the treatment of tracheobronchial carcinoma. However, a large multicenter prospective study is warranted for PDT to reach further exploration.

PO-107

Endotracheal endoscopic intervention for adenoid cystic carcinoma

Li,Tingtian、Chen,Jianyou、Huang,Shujuan、Tang,Huaping
Qingdao Municipal Hospital

Objective: Adenoid cystic carcinoma (ACC) is a rare low-grade malignant tumor. At present, surgical resection is the first choice.Adenoid cystic carcinoma is also sensitive to radiotherapy, but not to chemotherapy. At present, most of the patients who are unable to operate are treated by bronchoscopy

Methods: 1. Middle aged male. 2. Main complaint: cough, expectoration for more than half a year, blood in sputum for more than one month, aggravating 10 days, was admitted to hospital in August 2016. 3. Have been in good health and have no habit of smoking and drinking. 4. Physical examination: clear mind, low breath sound in the right lung, wheezing sound in the right lung, homogeneous rhythm, no noise in each valve auscultation area. 5. 4. Auxiliary examination: no abnormality was found in blood routine test, coagulation function, complete autoimmune test and procalcitonin. No obvious abnormality in the whole set of lung cancer and Ca series。No obvious abnormality was found in total abdominal CT + brain MR and bone scan Chest CT: nodular shadow in right main bronchus, partially blocked trachea 6. The tumor is located near the carina of the right main bronchus opening under the tracheoscope. Please consult with the surgery and suggest the right pneumonectomy The patient was young and refused surgical treatment。Endotracheal intubation, argon, cryotherapy and electrocoagulation

Results: The airway tumor was completely resection by interventional therapy with tracheoscope

Conclusion: For central airway adenoid cystici carcinomo patients with no surgical indications or sever dyspnea interventional bronchoscopy is an efficacious and rapid method for alleviating airway senosis .For locally recurrent patients after surgical or interventiontional therapy ,interventional therap euticbronchoscopy exerts a relatively high efficay.TACC is a low-grade malignant tumor, and its prognosis is relatively good in general Good. The 5-year survival rate is high. The traditional treatment is surgical treatment It is mainly assisted by radiotherapy, but severe tracheobronchial stenosis occurs in central TACC The risk of asphyxia could not be relieved quickly, and the postoperative complications were also higher。

PO-108

The Diagnostic Value of Transmission Electron Microscopy in Medical Thoracoscopic Biopsy Specimens

Huang,Junjun、Liao,Jiping、He,Pengkang、Wang,Xi、Yu,Qing、Zhang,Hong、Cheng,Yuan、Zhang,Wei、Wang,Guangfa、Junjun Huang
Peking University First Hospital

Objective: Medical thoracoscopy, which is defined as thoracoscopy with intravenous sedation combining local anesthesia, is now widely used in the differential diagnosis of pleural effusion [1]. However, the sizes of medical thoracoscopic biopsy specimens are usually smaller than that from the surgical operation. In some cases, the specimens are too small to identify the type of tumor or differentiate malignant from benign lesions with histology and immunohistochemistry (H/IHC) methods [2,3]. Transmission electron microscopy (TEM) can display ultrastructure changes, which make it a feasible, highly sensitive tool for the diagnosis of different pathology. The application of TEM for diagnostic and prognostic purposes include Alport’s syndrome, thin basement membrane disease, amyloidosis and so on [4]. A recent study has shown that TEM was helpful for the distinction of malignant pleural mesothelioma and lung adenocarcinoma in pleural effusion cytology [5]. To the best of our knowledge, there was a lack of data on the diagnostic value of TEM in medical thoracoscopic biopsy specimens. The aim of our study was to investigate the sensitivity and specificity of TEM compared with H/IHC. We tried to find out in which kind of conditions performing TEM can get more clinical benefits.

Methods: All patients who underwent medical thoracoscopy with diagnostic intent were retrospectively observed in Peking University First Hospital from April 1, 2009 to April 1, 2017. Both H/IHC and TEM were performed on each case to get diagnosis separately. We interviewed all patients by telephone during April 1, 2018 to May 1, 2018, and got the final diagnosis that was defined as the diagnosis one year after the medical thoracoscopy. The diagnostic value of H/IHC and TEM was compared.

Results: 105 patients were recruited. The TEM diagnosis of 88 cases was consistent with the H/IHC diagnosis for discriminating between benign and malignant lesions. The final diagnosis was used as the gold standard. The sensitivity of H/IHC in the diagnosis of malignancy was 90.2%, and that of TEM was 72.1%. While for H/IHC plus TEM, the sensitivity was up to 95.1%. The specificity for all three diagnostic methods was all 100%. The diagnostic rate of malignancy for H/IHC, as well as TEM, had significant difference with that of the gold standard (P-value=0.041, <0.001). However, that of H/IHC plus TEM had no significant difference (P-value=0.248), and the consistency was good (Kappa value = 94.2%).

Conclusion: Our study suggests that H/IHC plus TEM might improve sensitivity for diagnosing malignant pleural effusions, and this combined diagnostic method might be considered to be performed in thoracoscopic biopsy specimens to improve sensitivity.

PO-109

A case report: pulmonary hamartoma of left main bronchus

Liu,Chunhui、Ma,Tingting
The First Affiliated Hospital of Xinjiang Medical Univesity

Objective: To investigate the effectiveness of rigid bronchoscopy in the diagnosis and treatment of a rare case of main bronchus pulmonary hamartoma.

Methods: A detailed description of a case of pulmonary hamartoma completely occluding the left main bronchus confirmed by rigid bronchoscopy in our hospital.

Results: A 31-year-old male patient was admitted to our hospital for cough, sputum, fever and chest pain.The patient had undergone electronic bronchoscopy in the other hospital and showed a huge mass in the left main bronchus. The mass could not be removed after repeated attempts. CT in our hospital: left main bronchus obstructed distally, left atelectasis. Electronic bronchoscopy: the left main bronchus has a new round creature that completely blocks the lumen, the endoscope cannot pass, and the endoscope can enter the upper left lobe after electrocoagulation + cryotherapy. Pathology for examination: a total size of 0.6 * 0.4 * 0.3cm, degenerate and necrotic tissue, a little connective tissue and adipose tissue. Because the lesion is relatively smooth, the difficulty of operation under flexible bronchoscopy is high, and the diagnosis cannot be confirmed. Therefore, rigid bronchoscopy is performed for diagnosis and treatment. Partial tumor was removed by ligation of the electric snare through a rigid bronchoscope, and then part of the tumor was removed after freezing adhesion with carbon dioxide, and part of the tumor was removed with biopsy forceps. After repeated treatments, the left main bronchus has an unobstructed lumen and the endoscope can enter. Bronchial tumors are at least about 2 cm in length. Endoscopy can enter the upper left and lower left bronchi, a large amount of purulent secretions are aspirated, and the tissue removed for pathology is about 3*2*1cm. Reactive bone, fat, and fibrous connective tissue are seen on the microscope, which is consistent with hamartoma. Postoperative symptoms were significantly relieved and body temperature was gradually controlled. Reexamination of lung CT after 2 days: left atelectasis improved than before, and 3 days later electron bronchoscopy: moderate upper stenosis of left upper bronchi, moderate stenosis of left lower bronchus. Instruct patients to continue with local small lesion resection after 1 month.

Conclusion: Endobronchial hamartoma account for approximately 1.4% -10% of hamartomas, and pulmonary hamartomas that completely occlude the left main bronchus are extremely rare and have a high rate of misdiagnosis,difficult to distinguish from bronchial lung cancer and bronchial tuberculosis,Traditional surgery is traumatic and high risk.Through rigid bronchoscopy and snare, freezing and other treatments can not only effectively solve the obstruction, but also send a sufficient number of pathology to confirm the diagnosis, and also avoid unnecessary surgical treatment for some benign diseases, but still need follow-up electronic bronchus Microscopic treatment. In addition, due to the possibility of recurrence and malignant changes in lung hamartoma, regular follow-up is required.

PO-110

Preparation and application of sirolimus-coated tracheal stenosis

Wang,Shanzuan1、Chen,Zhengxiian2、王善钻
1. The Affiliated Hospital Of Putian Univevsity
2. The Sixth Affiliated Hospital Of Sun Yat-sen Univevsity

Objective: 1.To explore the preparation of sirolimus eluting stent. 2.To explore the pharmacokinetics of sirolimus eluting stent in vitro. 3. To explore the safety and efficacy of sirolimus eluting stent on the application of animal model by inserting drug eluting stents with tracheotomy.

Methods: 1.The preparation of sirolimus eluting stent: Bare Nitinol tracheal stents were carefully cleaned using an ultrasonic cleaning method with dichloromethane and distilled water in sequence. The cleaned stents were kept under a fume cupboard for 24 hours to evaporate the residual water.The stents were dipped vertically into a coating solution prepared by different concentration ratio of sirolimus in 20ml of dichloromethane. Samples were kept at 37ºC while being constantly for one day. Repeat the above steps. Finally, the DESs were placed in an oven overnight at 37ºC to remove any solvent. 2. The pharmacokinetics of sirolimus eluting stent in vitro: Coated stents were submersed in 10 ml of PBS at pH 7.4. PBS. The samples were kept at 37ºC while being constantly agitated at 75 revolution/min in an incubator shaker. Every two days, the incubation medium was removed for analysis, and completely replaced with fresh medium. These results were used to plot the cumulative release over time. 3. The study about safety and efficacy of sirolimus eluting stent on the application of animal model: Sixteen New Zealand white rabbits were randomly divided into the sirolimus eluting stent group(n=8) and the bare-metal stent group(n=8).The rabbit trachea was incised annularly and separately placed sirolimus eluting stent or bare-metal stent, and the tracheal was then closed.The granulation hyperplasia in trachea in-stent was observed by ultrathin bronchoscope at the 2nd and 4th week after operation. The severity of tracheal stenosis under endoscope was estimated by percentage stenosis of the cross-sectional area of the trachea.All animals were euthanized at the 4th week.The specimens of trachea were obtained and observed under light microscope after HE staining.

Results: 1.Ultrasonic cleaning method with dichloromethane can remove the impurity of stents. No damage was found on the stent under scanning electron microscopy. The scanning electron microscopy were used to observe stent morphology, It was indicated that not only the coating was very smooth and uniform, but also the coating had not any webbings between stents. We successfully prepared the sirolimus-eluting trachea stent with dipping method, and stent coating was obtained with the thickness of about 4~5um. 2.The Drug loading for different drug loading conditions are distinct. The proportion of sirolimus/PLGA stents of 1:10 loaded the most amount of drug, so the optimal proportion of sirolimus/PLGA is 1:10; We also attempted to increase drug loading by increasing the ratio of sirolimus in the coating solution. increasing the ratio of sirolimus/PLGA concentration (sirolimus/PLGA 1:5) cannot improve stent drug loadings, However, increasing the ratio did not improve drug loading. It suggest that the prompt stent drug-polymer interactions exist saturation effect.Concentration of sirolimus in PBS solution were detected by enzyme immunoassay amplification every two days, it continuous detection for 42 days. The amount of sirolimus released from a stent per day was about 80.07±2.26ug and exhibited a sustained, steady release. In vitro experiments showed that there was measurable drug release for more than 42 days, with about 50% of the loaded drug released during the first 2 weeks, about 70% during the first 28 days,80% during the first 42 days. We assumed that all of the loaded sirolimus would be released More than 6 weeks. Additionally, drug release in DES in vitro were mainly based on the drug diffusion and degradation of the polymer, there was a quick release in first 10days and subsequent a slow release period of drugs in DES in vitro. Thus, the results were satisfactory, and could meet the needs to inhibit granulation formation. 3.Each group had one animal death in experimental process,the other animals survived to the end and all appeared different degree of trachea stenosis.The ultrafine bronchoscope showed mild granulation hyperplasia of in-stent was observed at the 2nd week of postoperation in control group,and partial animals had heavily mucus retention,while in the sirolimus eluting stent group no visible granulation tissue formed and a small number of mucus retention could be seen.At the 4th

week after stent placement,mild-to-moderate granulation tissue formed in the control group,even completely obstructed in individual case,the top or lower edge of stent had visible granulation hyperplasia.Mild granulation tissue was seen in the DES group,in which the top edge of stent was the most common. Stent migration, fracture was not found. The data for statistical analysis showed that less thickness（mm）of in-stent granulation tissue in the experimental group（812.945+235.893）was detected compared to that in the control group(1577.529+507.971)（t=3.612,P=0.004）,and the inflammation response induced in experimental group （mean rank 4.93）was weaker than that in control group（mean rank 10.07）（Mann-Whitney U=6.500,P=0.014）,and the stronger the inflammation was,the more obvious granulation tissue hyperplasia becomed（the correlation coefficient r=0.809,P=0.000）,the difference was statistically significant.Our study determined that granulation hyperplasia didn’t exist in the sutured region,mild inflammation was found.

Conclusion: 1.The dip-coating method for making drug stent is simple which can make the drug uniform distribution in the surface of the stent. We successfully prepared the drug stents which meet the requirement of experiment by dip-coating method. 2.The best ratio of sirolimus/PLGA coating is 1:10, which enables the stent carry most drugs. The drug loading of stent did not increase when continue to increase the concentration of sirolimus in solution, suggesting a saturation effect of coating carrying drugs.Perform an initial evaluation of the sirolimus-coated stent pharmacokinetics in vitro. The amount of sirolimus released from a stent are safe in the administration scope ,no correlation of drug poisoning. 3. The thickness of in-stent granulation hyperplasia is highly related to the degree of inflammation. The homemade drug stents are proved to be safe and effective novel trachea drug-eluting stents on animal models,it highlights the potential value of clinical application,Sirolimus eluting stent can inhibit the granulation hyperplasia and reduce inflammation response after trachea stent implantation when compared to bare-metal stent.

PO-111

Features of Optical Coherence Tomography (OCT) for Endoscopic Typing of Patients with Bronchoplasty

Long,Fa、Huang,Zhihui、Long,Liang、Huang,Wenting、Hu,Fengbo、Fu,Peng、龙发
University of Chinese Academy of Sciences Shenzhen Hospital

Objective: To explore the OCT characteristics of 69 severe asthma patients with bronchial thermoplasty (BT).

Methods: 69 patients with severe asthma who underwent BT treatment in our hospital from October 2018 to November 2019 were included as study subjects. According to the endoscopic view of the airway mucosa at the left and right lower lobe bronchial openings, they were divided into the mucosal edema group (n = 8), the strong contraction group (n = 26), and the mucosal remodeling group (n = 15), the mucosal structure mixed group (n = 20). A total of four OCT images were taken from the B6 and B8 bronchi of each lower lobe of each patient, and the thickness of the epithelium, lamina propria, and submucosa was measured. The epithelium / lamina propria (epi-lamina ratio) was calculated. And count the proportion of cartilage and holes, measure the maximum diameter of the holes. Compare the parameters of the four types of optical coherence tomography (OCT).

Results: The four types of the OCT images of mucosal edema（ME）, strong contraction（SC）, mucosal remodeling（MR）, and mucosal structure mixed （MSM） showed epithelial thickness (um) were: 0.18 ± 0.06, 0.09 ± 0.02, 0.08 ± 0.02, 0.07 ± 0.03, using the Anova analysis showed that the mucosal edema epithelium was significantly thicker than those of the other three types (all p = 0.00); the lamina propria (um) were 0.1 ± 0.02, 0.12 ± 0.03, 0.11 ± 0.03, 0.09 ± 0.03, and the lamina propria of strong contraction type is thicker than mucosal edema type and mucosal structure mixed type (both p = 0.00); the epithelium / lamina propria were 1.68 ± 0.65, 0.77 ± 0.33, 0.78 ± 0.26, 0.82 ± 0.33, and the mucosal edema type has a significantly higher epi-lamina ratio than the other three types (All p = 0.00), the submucosa (um) were 0.66 ± 0.21, 0.59 ± 0.21, 0.61 ± 0.22, 0.53 ± 0.25, the mucosal edema type is significantly thicker than the mucosal structure mixed type (p = 0.009); the hole diameters (um) were 0.09 ± 0.19, 0.16 ± 0.37, 0.78 ± 0.56, 0.26 ± 0.45. Compared with the other three types, the cartilage and holes are more likely to

appear in mucosal remodeling type, and the hole diameter is also larger (both p = 0.00).

Conclusion: The OCT of the mucosal edema type shows a marked thickening of the epithelialium and a significant increase in the epithelium / lamina propria.The cartilage and holes are more likely to appear on OCT of mucosal remodeling type, and the holes are larger in diameter.

PO-112

Clinical Features of Transluminal Broncholiths and the Efficacy and Safety of Bronchoscopy for Treating Transluminal Broncholiths

Wang,Hong、王虹
Lanzhou University Second Hospital

Objective: Objective To reveal the clinical features of transluminal broncholiths and to evaluate the efficacy and safety of bronchoscopy for treating transluminal broncholiths.

Methods: The treatment methods for transluminal broncholiths included bronchoscopy and surgery. 2 patients were first assigned to receive surgical treatment: one was with massive hemoptysis and the other was judged the risk of massive hemorrhage in case of receiving bronchoscopy treatment, because the broncholiths were adjacent to peripheral blood vessels. 26 patients were treated with bronchoscopy: 6 patients with single stone were treated with bronchoscopic forceps and basket for one time. However, broncholiths were removed successfully only in 3 patients, the other 3 patients were shifted into surgery because of massive hemoptysis or bronchial fistula occurring during bronchoscopy. 20 out of the 26 patients were treated with repeated bronchoscopic lithotripsy: First, the intracavitary part of the broncholiths was fragmented and removed segmentally with foreign body forceps to relieve the obstructive symptoms. Then the remaining part of broncholiths within the bronchial lumen was removed eventually by repeated bronchoscopy during monthly follow-up period. The detailed results were shown in Table 3.

Results: 28 patients with 36 pieces of transluminal broncholiths were diagnosed using chest CT and bronchoscopy, of which 2 patients underwent broncholiths removal via an elective surgical procedure and 6 patients were treated with one-time removal of broncholiths by foreign body forceps and basket under bronchoscope. Among the 6 patients, 2 underwent massive hemorrhage in the process of one-time broncholiths removal and 1 suffered from bronchial fistula after the broncholiths removal, all of the 3 patients received surgical treatment eventually. No serious complications occurred in the other 20 patients who underwent broncholiths removal via repeated bronchoscopy. All the 28 patients were followed up for 5 months and found no any long-term complications.

Conclusion: Conclusion Removal of transluminal broncholiths by bronchoscopic forceps and basket are effective and safe with less complications. When it is difficult to remove the transluminal broncholith completely at one time, multiple times removal could be chosen: First, to remove the portion which causes airway obstruction; and then to remove the remaining part by repeated bronchoscopy during the follow-up period. In case that severe distal lung tissue injury, massive hemoptysis or bronchial fistula occurred due to broncholiths or the diagnosis of broncholiths is unclear, surgical treatment is required.

PO-113

Improved Lung function In Patients with severe refractory asthma After Bronchial Thermoplasty When FEV1 Is Less Than 60%

Long,Fa、Zhong,Ding、Huang,Wenting、Long,Liang、Fu,Peng、HU,Fengbo、龙发
University of Chinese Academy of Sciences Shenzhen Hospital

Objective: To explore the effectiveness of bronchial thermoplasty in the lung function of the refractory asthma patients with FEV1 less than 60% and FEV1 more than 60%.

Methods: Data were collected from 64 consecutive patients with severe refractory asthma according to the GINA 2016, who received BT treatment in our hospital from August 2016 to October 2017. According to the baseline prebronchodilator FEV1 % predicted, the patients were divided into two groups. Group A with their FEV 1 % predicted <60% (n= 31) and group B with an FEV 1≥60% (n= 33). Compare the improvement of lung function at 12 months after BT treatment in each group.

Results: Compared with before surgery, patients in group A showed significant improvement in lung function at 12 months after BT, which were FVC (2.34 ± 0.71 L vs 2.8 ± 0.89 L, t = 5.242, p <0.01) and FVC% (70.7 ± 12.9% vs 82.3 ± 14.1 % , t = 6.405 p <0.01); FEV1 (1.3 ± 0.42 L vs 1.96 ± 0.72 L t = 6.405, p <0.01) and FEV 1% (46.8 % ± 9.2% vs 64.1% ± 14.3% ,t = 6.620, p <0.01). While the patients in group B, there was no significant improvement in lung function at 12 months after BT,which were FVC(3.71 ± 2.87 L vs 3.29 ± 0.79 L , t = 0.868, p = 0.392) and FVC% (94.2 ± 12.5% vs 94.3 ± 10.4%, t = 0.085 , P = 0.933); FEV1 (2.35 ± 0.73 L vs 2.43 ± 0.71 L, t = 1.568 , p = 0.127) and FEV1% (82.3 ± 14.4% vs 84.8 ± 15.2% , t = 1.55, p = 0.131).

Conclusion: The results of this study demonstrated statistically significant improvements in FVC、FVC%、FEV1 and FEV1% from baseline to 12 months after the final BT treatment, these findings show that BT could provide an effective treatment option for severe refractory asthma patients with FEV1 <60%.

PO-114

Bronchoalveolar lavage and locally of amikacin in the treatment of bronchiectasis with chronic obstructive pulmonary disease clinical observation

Wang,Xiaojiang
Department of Respiratory Medicine， Wuhan No. 6 Hospital， Affiliated Hospital to Jianghan University

Objective: Severe COPD patients with bronchiectasis, both of which are chronic respiratory diseases, often interact with each other to form a vicious circle，To investigate bronchoalveolar lavage and locally amikacin in the treatment of bronchiectasis with the clinical curative effect of patients with chronic obstructive pulmonary disease.

Methods: 47 patients were randomly divided into control group of 23 patients with bronchiectasis, 24 cases of experimental group. Two groups were given intravenous anti-infection, anti-inflammatory and asthma, spasmolysis, phlegm, postural drainage, oxygen, noninvasive ventilator assisted ventilation and other routine therapy, the control group only with 0.9% sodium chloride injection line bronchoalveolar lavage, experimental group on the basis of local use amikacin therapy, comparing two groups after efficient treatment, laboratory examination indexes and the incidence of adverse reactions.

Results: The total effectiveness (95.83%) was significantly higher than the control group (69.56%), and the difference was statistically significant (P < 0.05). In the two groups after treatment with lung function, peripheral blood

leukocyte count (WBC), neutrophil ratio (N %), hypersensitive c-reactive protein (hs - CRP), calcitonin (PCT) level was obviously improved, the difference is statistically significant (P < 0.05). The improvement of pulmonary function (FEV1, FEV1 / FVC) was better than the control group, and the difference was statistically significant (P < 0.05). After treatment, the test group WBC, N %, hs-crp and PCT were significantly lower than the control group, and the difference was statistically significant (P < 0.05). The incidence of adverse reactions was not statistically significant (chi 2 = 0.0899, P = 0.956).

Conclusion: Bronchiectasis and COPD may overlap, which can be called bronchiectasis and COPD overlap syndrome. On the basis of routine treatment, combined with bronchoalveolar lavage and local use of amikacin in the treatment of bronchiectasis combined with COPD, can control infection more effectively, improve clinical symptoms, strong practicability, little damage to patients, rare serious complications, and good safety, which is worthy of wide clinical application.

PO-115

The diagnosis value of endobronchial ultrasound transbronchial lung biopsy combined with rapid on-site evaluation in peripheral lung cancer

xu,chunhua、徐春华
Nanjing Chest Hospital

Objective: Rapid on-site evaluation (ROSE) has the potential to increase endobronchial ultrasound transbronchial lung biopsy with guide sheath accuracy in the diagnosis of peripheral lung cancer. However, studies have reported controversial results. The aim of the study was to assess the diagnosis value of endobronchial ultrasound transbronchial lung biopsy with guide sheath combination with cytological rapid on-site evaluation (ROSE) in peripheral lung cancer.

Methods: A total of 138 patients undergoing EBUS-GS-TBLB and ultimately diagnosed with lung cancer were allocated into the ROSE group and non-ROSE group. The result of the diagnostic yields, number of biopsy sites, the complication, cytopathological diagnostic cost and procedure times of EBUS-GS-TBLB with ROSE and without ROSE were compared.

Results: Total 90 times of biopsy was performed in the 74 patients in ROSE group, and 128 times in the 64 patients in the non-ROSE group. Sixty-five cases in ROSE group were positive for malignancy. Of the 65 positive cases in ROSE group, the final procedural pathologic diagnosis was of malignancy in 65 lesions with no false positive result. Four cases of ROSE examination were negative, the final pathologic diagnosis of which was squamous carcinoma and adenocarcinoma respectively, and the consistency was 94.2%. The diagnosis yield of EBUS-GS-TBLB in ROSE group was 87.8%, while the diagnosis yield of EBUS-GS-TBLB in non-ROSE group was 78.1%, and the difference was statistically significant (P=0.012). For the peripheral lesion diameter≥3 cm, the diagnosis yields of ROSE group and non-ROSE group were 87.5% and 85.0% respectively, and there was no statistically significant difference between the two groups (P>0.05). Meanwhile, the diagnosis yields of ROSE group were higher than that of non-ROSE group in the lesion diameter <3 cm (P<0.05). In the non-ROSE group, the number of biopsy sites, the rate of hemorrhage, the cytopathological diagnostic cost, and procedure times were all higher than that of the ROSE group. Mild bleeding occurred in 8 cases of ROSE group and 18 cases of non-ROSE group. No moderate or severe bleeding or complications such as emphysema and mediastinal hematoma was observed in this study.

Conclusion: EBUS-GS-TBLB combined with ROSE could be helpful to diagnose peripheral lung cancer, and could reduce the number of biopsy, procedure times, cytopathological diagnostic cost and complication.

PO-116

The Influence of Electronic Health Assistant on the Completeness of Electronic Bronchoscopy under Local Anesthesia in Outpatients.

Li,Lina、Zhu,Minghui、Jia,Yanhong、Guo,Mingxue、Yang,Zhen
The General Hospital of the Peoples Liberation Army

Objective: This real-world study aimed to explore the influence of Electronic Health Assistant (EHA) on the completeness of electronic bronchoscopy under local anesthesia in outpatients. The EHA is an pile of electronic document for patients before bronchoscopy developed by the Center of Interventional Pulmonology of Chinese People's Liberation Army General Hospital. After the patient receives pre-operative guidance performed by a specialist nurse, the electronic version is pushed to the patient before the operation.

Methods: Electronic Health Assistant (EHA) is an electronic document developed by our department to instruct patients who are about to receive bronchoscopy examination in professional instructions. EHA could keep sending guidance to patients until the day they receive the bronchoscopy examination. In this study, clinical data and EHA records from 1126 patients who made appointments of electronic bronchoscopy in the Center of Interventional Pulmonology of Chinese People's Liberation Army General Hospital were collected retrospectively to evaluate the influence of EHA on the completeness of electronic bronchoscopy.

Results: Out of the 1126 patients, 706 received EHA instruction while 420 failed. In patients who received EHA instruction, only 5 patients failed to receive electronic bronchoscopy (5/706). 3 hypertensive patients were evaluated to have dangerous high blood pressure (≥160/100 mmHg) pre-operatively, while others had sinus tachycardia (≥120 / min) before the examination. However, in patients who did not receive EHA instruction, 15 patients failed to receive electronic bronchoscopy (15/420). The reasons were as follows: 6 patients did not take anti-hypertension drugs before the operation, 2 patients had new-onset hypertension (systolic pressure ≥150 mmHg), 5 patients had sinus tachycardia (≥120 /min) and the other 2 patients forgot to bring the results of examinations with them. Statistic significance was found between these two groups of patients ($P<0.05$).

Conclusion: EHA can assist outpatients who are receiving electronic bronchoscopy examination with professional pre-operative instructions, which can increase the completeness of electronic bronchoscopy.

PO-117

The effectiveness and safety of Bronchial Thermoplasty in the treatment of severe bronchial asthma during acute attacks: A preliminary clinical study

Long,Fa、Fu,Peng、Huang,Wenting 、Long,Liang、Dong,Hongbo、Jiang,Hui、Gan,Jingfan、龙发
University of Chinese Academy of Sciences Shenzhen Hospital

Objective: To eveluate the effectiveness and safety of bronchial thermoplasty(BT) in the treatment of severe bronchial asthma during acute attacks.

Methods: A retrospective analysis of 3 patients admitted to our hospital from March to November 2017 who underwent invasive ventilator-assisted ventilation for acute exacerbation of severe asthma was treated with BT and observed for complications within 3 weeks after surgery. The symptoms of asthma, acute attacks, hospitalizations due to acute attacks of asthma, pulmonary ventilation function and postoperative complications were recorded at 6 months, 1 year, and 2 years.

Results: The tracheal intubation was removed in 2 cases within 2 days after the first BT, 1 cases of tracheal intubation removed within 10 days,and the average was 4.7 days after surgery. The most common complications were cough(9 cases),sputum (6 cases), wheezing (3 cases) within 3 weeks and after each BT and Pulmonary infection with atelectasis occurred in 2 cases. The condition improved after sputum removed and anti-infection. The asthma symptoms of the three patients in all the observation nodes were significantly improved compared with the BT first treatment , the ACT score increased, the AQLQ score increased, and the ACQ score decreased. Among them, FEV1 increased by 68% in one patient, and FEV1 increased by an average of 8% in the other two patients. The average frequency of acute attacks was (2.3 ± 1.5) times / month, and no patient was hospitalized due to severe acute asthma attacks.No patient died.Computed tomographic scans from baseline to 2 year after the BT treatment showed no structural abnormalities related to BT.

Conclusion: The application of bronchial thermoplasty in the treatment of severe bronchial asthma during acute exacerbation has a good initial effect, and no serious adverse reactions have occurred. The sample size of this study is small, and it is worth further observation with a large sample size.

PO-118

A case of anaplastic large cell lymphoma involving bronchus

wen,si、Zhang,Hongyi、He,Yuanbing
the first affiliated of Xinjiang Medical University

Objective: described a case of ALCL involving main bronchus aiming to identify unspecific clinical manifestations in the early stage and hence be able to stay alert to the disease to avoid a delay in treatment.

Methods: performed a transbronchial ligation and excision biopsy of the right total bronchus with an electric snare under intravenous general anesthesia, together with a biopsy of in the left total bronchus on a 15-year-old girl presenting with a cough, yellow and white sputum, and dyspnea for about 45 days,but with fruitless effort.

Results: Pathological analysis of the right bronchus revealed almost effacement with diffuse infiltration of large anaplastic cells, which were positive for anaplastic lymphoma kinase (ALK). These findings are compatible with anaplastic large cell lymphoma (ALCL).CHOPE chemotherapy was immediately started. CT performed after one cycle of CHOPE chemotherapy revealed that the tumors in the bilateral bronchus were reduced and the reexamination of

bronchoscope also showed the shrinking tumors after four cycles on someday in 2018.

Conclusion: As a rare non-Hodgkin's lymphoma, ALCL accounts for only 10% to 15% of NHL in children and adolescents, and more than 90% of them are ALK-positive.ALCL often occurs in lymph nodes and rarely affects the tracheal bronchus，so it is more likely to be missed clinically because of the low incidence. Due to the lack of specific clinical manifestations of ALCL, it is particularly noteworthy that early diagnosis is difficult in many cases and the clinical diagnosis is mostly in the late stage of the disease (stage III-IV). When the next patient presents with a cough and sputum,but with fruitless effort,the lymphoma involving bronchus should be associated.ALCL is confirmed only by a biopsy and pathological analysis of the tumor when affecting the tracheal bronchus, though new obstructive neoplasm of the lumen can be seen and an initial judgment could be made under the bronchoscope. The combination of interventional bronchoscopy and CHOPE chemotherapy can improve the outcomes in young patients with ALCL involving main bronchus.

PO-119

Beware of new causes of chronic cough and stimulus of suture nails after pulmonary surgery

Mei,Zhoufang1、Sun,Jiayuan2、梅周芳
1. The fifth people's hospital of shanghai， Fudan University
2. Department of Pulmonary and Critical Care Medicine， Shanghai Chest Hospital， Shanghai Jiaotong University

Objective: To search for new causes of chronic cough and provide new ideas for clinical diagnosis and treatment.

Methods: A case of chronic cough in our department was retrospectively analyzed, and the related literature was reviewed.After the patient was admitted to the hospital, relevant examinations were improved. In order to clarify the nature of lung lesions, after informed consent of the patient's family members, on the morning of May 11, 2018, general anesthesia + 2% lidocaine local anesthesia, ECG monitoring, fiberoptic bronchoscopy under laryngeal mask + foreign body extraction + balloon dilatation + argon helium knife operation. Fiberoptic bronchoscopy: the general trachea: lumen unobstructed, mucosa smooth, protuberance sharp. Right bronchus: right common branch, right upper lobe, right middle lower lobe, all branches are unobstructed with smooth mucosa. Left bronchus: the mucosa at the end of the left common branch swelled and swelled, the lumen was obviously narrow, and the body could not enter the bronchus. After balloon dilatation (5atm / 11mm), there were 8 sutures in total

Results: Six years ago, a patient with chronic cough underwent VATS left lower lobe resection under general anesthesia in thoracic surgery in our hospital. The pathology was benign tumors, and the long-term cough after operation. The effect of various drugs was not obvious. The fiberoptic bronchoscopy showed that the pulmonary suture nail was exposed to the left lower lobe stump, accompanied by granulation hyperplasia, mucosal congestion and edema. The suture nail was pulled out under bronchoscope, and the patient's cough symptoms were alleviated.

Conclusion: With the widespread use of intrapulmonary suture nails in thoracic surgery, the displacement of suture nails increases. Therefore, patients with chronic cough after operation should be vigilant against stimulus of suture nails.At present, with the aggravation of aging and air pollution in our country, chronic cough has become an important disease source in respiratory clinic. For some chronic cough with unknown causes, chest CT should be performed in time. If necessary, invasive examination should be performed. Fiberoptic bronchoscopy is a direct and effective means to understand the situation in the airway. As a respiratory physician, it is reasonable and effective The development of fiberoptic bronchoscopy is a sharp sword to solve clinical problems. This sharp sword should be mastered and used by all respiratory doctors for the benefit of patients.

PO-120

Photodynamic Therapy for peripheral-type lung cancers

USUDA,JITSUO、Inoue,Tatsuya、Sonokawa,Takumi、Matsumoto,Mitsuo
Nippon Medical School

Objective: Photodynanic therapy (PDT), is a treatment modality for many cancers, and uses a tumor-specific photosensitizer and laser irradiation. PDT is recommended as a treatment option for centrally located early lung cancer. The detection of peripheral lung cancers is increasing, and stereotactic body radiotherapy (SBRT) and percutaneous thermal ablation are emerging as alternatives to surgical resection, but PDT has not been a modality.

Methods: Recently, we have developed a new laser probe, we aimed to develop a new endobronchial treatment for peripheral cancer using PDT, and we evaluated the feasibility of PDT for peripheral lung cancer.

Results: We performed PDT for peripheral-type lung cancer in a multi-center clinical trial. In this trial, we performed PDT for 3 patients with c-stage IA peripheral lung cancer, using a laser dose (120mW, 50J/cm2), and confirmed the feasibility of the dose. We escalated the laser dose and performed 4 patients using a laser dose (120mW, 100J/cm2). Seven patients met our criteria, and 5 cases were adenocarcinoma and 2 case squamous cell carcinoma. Two weeks and 3 months after NPe6-PDT, complications such as pneumonia and pneumothorax were not found, but one mildly found light skin-photosensitivity. Six months later, we found CR in 3 cases and SD in 4 cases.

Conclusion: PDT was a feasible and non-invasive treatment for a peripheral type early lung cancer. Now we will conduct an investigator-initiated clinical trial of PDT for peripheral lung cancer (c-IA, tumor size less than 25 mm) , in order to establish as a proper treatment. This study design is multi-center randomized controlled trial (PDT vs BSC), and primary endpoint is progression free survival (PFS). In this session, we will introduce this clinical trial.

PO-121

Treatment of malignant pleural effusion by thoracoscopy combined with intrapleural perfusion hyperthermia in 3 stage IV EGFR-positive lung adenocarcinoma cases

Yang,Shifang、Huang,Guohua、Gao,Xinglin
Department of Respiratory and Critical Care Medicine, Guangdong Provincial People's Hospital (Guangdong Academy of Medical Sciences), Guangdong Institute of Geriatrics

Objective: To expand the application of intrathoracic heat perfusion therapy in patients with malignant pleural effusion who can't tolerate surgery through the technique of placing tube under the medical thoracoscope.

Methods: Firstly, artificial pneumothorax was made according to the location of ultrasound or CT. And then the chest film was reexamined to evaluate whether there was adhesion and wrapping, and determine the best catheterization position of thoracoscopy. The patient took the healthy side lying position and used the seventh intercostal space of the axillary midline as the access channel of thoracoscopy. The suspicious lesions were biopsied for pathological examination. Secondly, a small incision of 1cm was made in the sixth intercostal space of the axillary front of the affected side. Thirdly, under the direct vision of thoracoscopy, the first drainage tube as the outlet pipe was sent to the posterior costophrenic angle through the biopsy forceps. And then,the second drainage tube as the inlet pipe was sent to the front and upper part of the chest on the affected side. After adjusting the position, the suture was fixed. After the operation, the position of the port could be further confirmed by he chest film. Lastly, before thermal perfusion treatment, the two drainage pipes and the body cavity thermal perfusion treatment system are accurately and closely connected with the body cavity thermal perfusion treatment pipe components. After the machine is preheated, water will enter. If the pipe is blocked, the pipe can be adjusted. After the pipe is unobstructed, the thermal perfusion treatment can

be carried out

Results: All the three patients successfully completed the catheterization under the direct vision of thoracoscopy, and successfully completed the intrathoracic heat perfusion treatment. They were followed up for half a year, reexamined chest CT. The pulmonary lesions were evaluated as SD, and the pleural effusion as CR.

Conclusion: Medical thoracoscopic catheterization technology can not only biopsy the focus pleura under direct vision, but also ensure the safety and accuracy of catheterization.The operation is simple and convenient, providing technical support for the promotion and application of intrathoracic heat perfusion therapy in non-surgical population.

PO-122

Safety and Feasibility of Radiofrequency Ablation guided by BTPNA in normal Canine lung tissue

Zhong,Changhao、Li,Shiyue、Xu,Hong
The First Affiliated Hospital of Guangzhou Medical University

Objective: To evaluate the safety and efficacy of Radiofrequency Ablation (Automatic saline micro perfusion) for normal lung parenchymaguided by BTPNA (Bronchoscopic TransParenchymal Nodule Access) technology in Labrador animals, and to provide experimental basis for future human trials

Methods: A total of 11 Labrador animals were randomly divided into three groups: 1 day group (n=3), 30 days group (n=4) and 90 days group (n=4). The lung model was reconstructed via LungPro Navigation Systemaccording to the CT before operation. Lesions without bronchus sign were simulated and identified (the diameter of each lesion was 1 cm, the distance from lesion to pleura was at least 1cm). Meanwhile, the POE (Point of Entry)and tunnel path were automatically planned to establish a direct tunnel leading to the simulated lesion.During the operation, the tunnel was established for each simulated lesion according to the planned path, and the ablation probe was placed into the lesion through the sheath. Once the target lesion was confirmed by the C-arm, the Radiofrequency Ablation System(Automatic saline micro perfusion) was activated and the simulated lesion was ablated according to preset parameters (15w, 3min). The feasibility of operation and safety were evaluated. The ablation parameters were recorded during operation. Chest CT for each animal was took before sampling. The changes of imaging morphology and size after ablation were observed. HE stainingof lung tissue containing the ablation area was carried out.

Results: A total of 14 ablation operations were performed in 11 animals. The ablation tunnels were all successfully established and the ablation procedures were all completed in 11 experimental animals. The immediate success rate of the operation was 100% (14/14). No pneumothorax, bleeding and other adverse events occurred during the operation. The average tunnel establishment time (total time from beginning of puncture to placement of sheath to the simulated lesion) was 7.79 ±3.29 min. The average tunnel length was 19.50 ±6.11 mm. All follow-up visits according to the protocol were completed for all animals. There was no accidental death during the study.Chest CT, anatomy and pathology results showed that coagulation necrosis of lung tissue, hyperemia, hemorrhage around the necrosis were caused by radiofrequency ablation, accompanied byinflammatory reaction. The Chest CT on 7thday after operation showed that inflammation induced by heat injury had been almost absorbed.

Conclusion: BTPNA-guided Radiofrequency Ablation technique was feasible, safe and effective.

PO-123

A case of malignant central airway stenosis with abundant blood supply

Weng,Meili1,2、Zhang ,Huaping1,2、Su,Xiaoshan1,2、Zeng, YiMing1,2
1. the Second Affiliated Hospital of Fujian Medical University
2. Respiratory Medicine Center of Fujian Province

Objective: Malignant central airway stenosis refers to airway stenosis caused by primary or metastatic malignant tumors of the trachea, carina, left and right main airway and middle bronchus, which can lead to different degrees of dyspnea or asphyxia death in clinical practice. Malignant tracheobronchial stenosis is a life-threatening disease. Hemoptysis occurs in approximately 10% to 30% of patients with primary lung cancer during the clinical course of the disease, and 3% of patients with lung cancer died of massive hemoptysis. With the development of treating interventional respiratory disease, endoscopic interventional therapy has become the main means of malignant central airway stenosis. Arterial embolization is another option to treat hemoptysis in patients with lung cancer. Here, we report a case of a patient with advanced lung cancer with malignant central airway stenosis with abundant blood supply. How to make a medical decision when hemoptysis and atelectasis occur caused by central airway obstruction is significant.

Methods: The clinical process of diagnosis and treatment of the patients with central airway stenosis were retrospectively analyzed.

Results: The patient was a 70 - year - old male who complained of the cough, shortness of breath for 15 days and hemoptysis for 0ne week. He has been a smoker for 40 years and suffers from the diseases of COPD and asthma. The chest radiograph showed obstructive atelectasis of the middle and lower lungs (figure 1), and chest CT enhancement scan indicated space-occupying lesions in the right porta pneumonia, which completely blocked the right middle bronchus, and the lesions were significantly intensified. The CT value was more then 200Hu, the vegetative vessels in the lesions were large and came from bronchial arteries (figure 2). the patient was diagnosed as right central lung cancer with invasion of the mediastinum and unknown distant metastasis, performance status sore(PS)=4. In this case, surgery、radiotherapy or chemotherapy all were contraindications, and the indications of targeted therapy and immunotherapy needed to be further evaluated by pathological and genetic tests. Then, we tried to relieve hemoptysis and atelectasis by central airway recanalization and bronchoscopy and to create conditions for further treatment. First, the central lesion assessment: the lesion was in the Ⅴ area + Ⅵ area, and the narrow type was mixed type. The degree of stenosis was 100% (level 5) and the narrow length > 2cm, bleeding risk analysis suggested lesions were rich in blood supply and were easy bleeding. It is recommended to use the combination of rigid bronchoscopy and electronic bronchoscopy according to the Chinese guidelines. Second, the patient tolerability assessment: although the patient had basic diseases of COPD and asthma disease with right lower atelectasis, his symptoms were controlled well because of taking drugs regularly, and the degree of difficulty in breathing is light, no wheezing in the lungs, no widespread pneumonia changes in CT, arterial blood oxygen partial pressure was up to 86mmHg under oxygen inhalation of the nasal catheter. This suggested that the compensatory and reserve status of lung function was acceptable, and it was estimated that prolonged bronchoscopy intervention could be tolerated. In order to prevent massive intraoperative hemorrhage, bronchial artery embolization was performed first, and then bronchoscopy was performed (figure 3). The procedure was performed under general anaesthesia, Under the bronchoscope, the tumor and blood clot in the right main bronchus were completely blocked, and the distal bronchus in the right upper lobe was still patency (figure 4). Frozen resection, balloon dilation and electrotomy were performed to remove the lesions (figure 5), and prepositioned balloons were placed intraoperatively to reduce the risk of airway hemorrhage. Postoperative pathology confirmed the diagnosis of lung squamous cell carcinoma, and the bedside chest X-ray showed a reexpansion of the right lung three days later (figure 6), postoperative enhanced CT showed small necrotic foci in the center of the mass and metastatic foci in the right lower lung. Postoperative bronchoscopy revealed ulcers at the opening of the right upper branch and the right lower branch. CT at three weeks after the operation showed that the stenosis of the distal end of right main bronchus was aggravated again, and the distal airway of the superior right ramus, middle right ramus and right basal

trunk were basically unobturated. (figure 7) Can we reconstruct the right main airway? In this case, it is necessary to design and insert a double Y-stent to reconstruct the right main airway (figure 8). The next step is feasible gene testing and immunotarget testing to further anti-tumor therapy.

Conclusion: In the face of malignant central airway stenosis with abundant blood supply, Comprehensive preoperative evaluation，bronchial artery embolization before interventional surgery and pre-positioned hemostatic balloon are good choices to prevent massive intraoperative hemorrhage. Although there are few fistula complications in bronchial artery embolization, it has become a thorny problem in treatment and led to poor prognosis. Therefore, we should pay attention to the rare "fistula" complications after bronchial artery embolization.

PO-124

Non-tuberculous mycobacteriosis with early central squamous cell lung carcinoma: a case of interventional therapy under bronchoscope and review of literature

Xiao,Kui1、Jiang,Jiehan2、Zhu,Zhiruo1、Wang,Yaohui1、Xia,Shulan1、Shi,Zhihui1、He,Wenlong1、Liu,Qingqing1、Qing,Qingwu1、Zhou,Rui1
1. The Second Xiangya Hospital， Central South University
2. Changsha Central Hospital

Objective: Non-tuberculous mycobacteriosis (NTM) with early central squamous cell carcinoma (SCC) is relatively rare. In order to improve clinicians' understanding and treatment of this kind of patients, we did this case report and literature review.

Methods: The diagnosis and treatment of a NTM with early central SCC were analyzed with literature review.

Results: The patient was a 68-year-old male, he went to our hospital for repeated coughing and expectoration for more than 20 years, found mucosa lesion of the left upper lobe (LLL) for 1 week. In the past, due to his repeated coughing and expectoration, multiple lung exudative lesions and bronchiectasis, sputum stain positive for acid fast antibacterial in other hospital, . he was treated with irregular anti tuberculosis treatment for more than 5 years without obvious improvement in symptoms. On May 10, 2018, bronchoscopy showed that the mucosa at the opening of the LLL was swollen and rough, and the opening of the left upper lobe was narrow. Mucosal biopsy showed chronic inflammation of the mucosa. In order to seek further diagnosis and treatment, bronchoscopy was performed in our outpatient department on May 20. Under the bronchoscope, the mucosa at the opening of the LLL was swollen and bulged, covered with necrotic substances. After aspiration and cleaning, mucosal biopsies were performed, and abnormal cells were found in rapid on site evaluation. The pathological report showed that there were small nests of cells in the stroma with infiltrative growth，immunohistochemistry confirmed poorly differentiated SCC. Tissue culture showed: mycobacterium avium complex (MAC). Whole body PET-CT showed: SUV value of LLL bronchus was 7.9, multiple patchy lesions in both lungs, SUV value was 1-2, considering infection. After MDT discussion, he was considered as early LLL lung squamous cell carcinoma (T1assN0M0, stage IA1). He was suggested to receive anti MAC treatment (azithromycin + rifampin + ethambutol + levofloxacin) for 3-6 months and reevaluate his surgical conditions. Before the surgical treatment, bronchoscopy intervention could be considered. Then he received bronchoscopic interventional therapy for many times, among which, on June 25, high-frequency electrocoagulation were performed at the mucosal lesions of the LLL. After treatment, eschar was seen, and no obvious mucosal lesions were found; on July 30, there were more necrosis in the inner wall of the LLL opening, and high-frequency electrocoagulation were performed after suction and cleaning. After treatment, no obvious mucosal diseases were found On September 12, a small amount of necrosis and scars were found in the opening of the LLL, and the mucosa was smooth after suction and cleaning, then he was treated with cryotherapy. From October 2018 to August 2019, multiple bronchoscope reexamination showed that the local mucosa was smooth, and no obvious abnormality was found. In October 2019, the mucosa of the anterior wall of the opening of the LLL was smooth, while the mucosa of the posterior wall was hypertrophic and prominent, which was

confirmed by biopsy as focal SCC. In November and December 2019, after local high-frequency electrocoagulation and APC treatment, there was eschar and no obvious mucosal lesions. The patients were asked to reexamine bronchoscopy every month and receive interventional therapy if necessary. At present, his spirit and appetite were improved, cough and expectoration were significantly reduced, and his lung CT showed that the exudative lesions are significantly reduced.

Conclusion: According to the review of the literature, there has not been reported that non tuberculous mycobacterial disease with early central squamous cell carcinoma received interventional therapy under bronchoscope. A small number of literatures have reported the retrospective analysis of NTM disease in patients with previously diagnosed lung cancer, and the case analysis of lung cancer found by CT in patients with tuberculosis and NTM disease.

PO-125

Clinical application of fast-track surgery with Chinese medicine treatment in painless bronchoscopy-a self-made "Resuscitation Pack"

Tan,Xinyuan、谈馨媛－重复数据
GuangDong Provincial Hospital of Chinese Medicine

Objective : To investigate the clinical effect of an early fast-track surgery method using a self-made "resuscitation pack" mainly consists of aromatic Chinese herbal medicine after painless bronchoscopy.

Methods: We performed a prospective observational study on 138 patients undergoing painless bronchoscopy in Guangdong Provincial Hospital of Chinese medicine from December 2018 to November 2019. Patients were randomly assigned with SAS 9.2 software into treatment group (using self-made "resuscitation pack" with formulated Chinese herbal medicine) and control group(using placebo pack) , 69 cases in each group. Both groups were given a pack upon acupoint Tiantu(CV22) immediately after operation of painless bronchoscopy for four hours. Operation (right after operation and 1 hour after operation) and anesthesia recovery time (right after operation、1 hour after operation、24hours after operation), incidence of symptoms like dizziness, headache, nausea and vomiting and quality were recorded and compared between groups during the perioperative period.

Results: Compared with the control group (n=69), the intensity of nausea and vomiting was decreased in the treatment group(n=69)at the first hour of recovery time (4 cases in treatment group vs 13 cases in control group, $p<0.05$,$p=0.023$). The data also indicated that the treatment group had shorter average anesthesia recovery time (2.03±3.73min in treatment group vs. 2.14±3.65min in control group) and faster recovery of dizziness, for less cases suffered for dizziness above Ⅳ grade intensity (9 cases in treatment group vs. 20 cases in control group). But there was no significant difference between two groups. There were no serious postoperative complications during the study.

Conclusion: It tends to be easy to suffer symptoms like dizziness and vomiting after operation for patients undergoing painless bronchoscopy. The self-made "Resuscitation Pack" are made by aromatic Chinses herbs and applied on acupoint, and it is believed that it can induce resuscitation, regulate the flow of qi and descend the adverse rise of qi based on Chinese Medicine theory. Our study finds that the self-made "Resuscitation Pack" can reduce the incidence the intensity of nausea and vomiting after one hour at recovery time, as well as improve the intensity of dizziness to some extent. And no severe adverse events were observed in the study. Therefore, we believed that the self-mad "Resuscitation Pack" is a safe and feasible fast-track surgery approach to accelerate the recovery of patients in perioperative period of painless bronchoscopy operation.

PO-126

Clinical observation of radioactive 125I particles implantation in the treatment of non-small cell lung cancer (NSCLC)

Liu,Zhanglin、Xu,Fei
the First Affiliated Hospital of Nanchang University

Objective: To observe the efficacy and side effects of radioactive 125I particles implantation in the treatment of NSCLC.

Methods: The clinical data of 278 patients with NSCLC who underwent radioactive 125I particles implantation in the First Affiliated Hospital of Nanchang University from May 2010 to August 2018 were collected.According to the treatment ways, the patients were divided into four groups: Particles implantation combined with chemotherapy group(group A),Simple particles implantation group(group B),Particles implantation after operation group(group C),Particles implantation combined with chemotherapy and tyrosine kinase inhibitor group(group D).To analyze the clinical effect and adverse reactions of each group after treatment.

Results: After completing treatment,the effective rates of the first, third and sixth month in each group were 83.5%/83.5%/76.4%（group A）,76.3%/76.3%/72.6%（group B）,78.4%/78.4%/76.8%（group C）,88.6%/87.9%/78.2%（group D）.The median progression free survival was 12 months (group A), 8 months (group B), 13 months (group C) and 15 months (group D), respectively,and the median survival time of each group was 16 months (group A), 13 months (group B), 24 months (Group C) and 21 months (Group D).The incidence of adverse reactions in group B was lower than that in group A,and the difference between the two groups was statistically significant($P<0.05$).And there was no statistically significant when comparing the difference between the group B and group C.

Conclusion: In the treatment of non-small cell lung cancer, the short-term effect of radioactive 125I particles implantation is significant, and the adverse reactions are mild.It can improve the clinical benefit rate when combined with chemotherapy and tyrosine kinase inhibitors.It is also effective in recurrent NSCLC patients after operation,we also found it can improve the quality of life of patients and is worthy of clinical promotion.

PO-127

Safety and utility of the endoscopic microwave ablation for malignant central airway obstruction, case series.

Senitko,Michal、Abraham,George
University of Mississippi Medical Center School of Medicine

Objective: Malignant central airway obstruction (CAO) is causing debilitating complications of primary lung cancer and other extrapulmonary malignancies. Approximately 30% of patients with primary lung cancer present with CAO as a late-stage or recurrent locoregional disease [1, 2]. The goal of therapeutic bronchoscopy is to recanalize an airway in order to provide palliation of symptoms, bridge to further cancer therapy and to improve survival [3]. Commonly used modalities to devitalize a tissue and achieve hemostasis during a tumor debridement utilize either high or low temperatures. Microwave ablation (MWA) is a field-based technology that heats tissue by creating an electromagnetic field in the patient around an ablation device [4]. We present case series utilizing MWA catheter via flexible bronchoscopy as a novel, not previously described modality for the management of malignant central airway obstruction.

Methods: We performed therapeutic bronchoscopy and used a flexible (MWA) catheter (MedWaves Inc., AveCure ®) in a total of five cases. We recorded radiographic and/or endoscopic measurements of tumors, a number

of microwave energy applications, time of each application, the total time of MWA, amount of energy delivered, the average temperature during ablation, rate of successful ablation, need for other ablative techniques, complications, and 30-day follow up.

Results: Out of five cases, successful airway recanalization was achieved in 100% of them. No immediate complications were noted, and all patients were alive at 30 days. The MWA was used to treat a tumor ingrowth within a silicone stent in one case. No damage to a stent was noted.

Conclusion: Microwave ablation of malignant central airway obstruction is a safe and effective heat method to achieve the devitalization of a tumor and hemostasis while maintaining a very good perception of an airway axis. This is the first case series describing the MWA method via flexible bronchoscopy and dosimetry of delivered energy. Authors suggest that microwave ablation should be considered as another effective endoscopic method of tumor destruction and airway recanalization, although more research is needed to compare its characteristics with other ablation techniques.

PO-128

Left main bronchus varicose caused by embolization of thoracic aortic pseudoaneurysm: case report and literature review

Xiao,Kui1、Jiang,Jiehan2、Zhu,Zhiruo1、Wang,Yaohui1、Xia,Shulan1、Shi,Zhihui1、Zheng,Dongyuan1、Zhou,Rui1
1. The Second Xiangya Hospital, Central South University
2. Changsha Central Hospital

Objective: The left main bronchus endovascular tortuosity caused by the embolization of thoracic aortic pseudoaneurysm is very rare. In order to improve the clinician's understanding and treatment of the disease, we did this case report and literature review.

Methods: We analyzed the diagnosis and treatment of a patient with left main endobronchial varicose caused by embolization of thoracic aortic pseudoaneurysm, and reviewed the literature.

Results: This 78-year-old male was hospitalized for repeated cough and dysphagia for more than 4 months. On April 19th 2018, he came to our hospital for emergency treatment because of chest pain accompanied by ecchymosis in the anterior cervical region for two days, and the neck swelling was found through physical examination. The size of ecchymosis in the anterior cervical region was about 10cm × 10cm. He received a CTA examination and found the formation of distal malformation of the bronchial artery and huge pseudoaneurysm. On that day, the emergency interventional embolization was performed. After the operation, the patient's vital signs were stable and the symptoms were significantly improved. CTA reexamination on April 23rd showed high possibility of small branches of left lower pulmonary artery embolism. After MDT discussion, the panel suggested that he should not be given anticoagulation temporarily and the patient was discharged on April 29th. After discharge, the patient's cough and dysphagia gradually aggravated. On August 28th, the CTA reexamined in the outpatient department showed that the pseudoaneurysm of the bronchus artery in the original thoracic aorta (upper level of the trachea bifurcation) was narrower than before, and the present range was about 5.5cm × 3.5cm, with high-density metal shadow, sectional esophageal compression and stenosis was improved. In mediastinum, tortuous and thickened bronchial arteries still can be seen, and branch blood supply was seen in left internal mammary artery. On September 6th, bronchoscopy showed that the mucosa of lower part of the trachea, carina and right main bronchus were congested and swollen; the left main bronchus was obviously congested and swollen in the whole process, with rough surface; the middle part of left main bronchus was narrow, with two soft texture, smooth surface and no obvious pulsation lesions in it, which could be reduced when compressed by the bronchoscope. In order to clarify their nature, we punctured them with Olympus puncture needle, and a small amount of local bleeding occurred after puncture. This proved that the lesions in the left main bronchus were vascular disease, and more likely to be varicose veins. Because of the high risk of surgery, the family members of the patient gave up further

treatment.

Conclusion: The left main bronchus varicose caused by embolization of thoracic aortic pseudoaneurysm has not been reported before. Other causes of endobronchial varicosis include single ventricular disease with liver congestion, pulmonary vein stenosis, pulmonary vein atresia, extrahepatic portal vein stenosis, cirrhosis, and portal vein thrombosis.

PO-129

A rare case of a secondary organizing pneumonia: The challenges of establishing a diagnosis between infectious vs inflammatory bowel disease (IBD)

Chacon Martinez,home、Rodriguez,Armando、Wellickoff,Adam
University of Miami

Objective: It is impossible to differentiate cryptogenic organizing pneumonia (COP) from secondary organizing pneumonia (SOP) based on radiologic or pathologic findings. Multiple conditions are associated with the histopathology of SOP. Thus, a careful review of the patient's history, physical examination, medication usage, potential exposures, and underlying diseases is needed to determine the etiology. The clinical classification based on etiology (COP vs SOP) is useful to predict clinical course and outcomes (10). Also, there are significant differences between the diagnostic procedures in terms of radiological patterns when diagnosing SOP (14). We present the case of a 49-year-old female with past medical history of inflammatory bowel disease (IBD) and subacute fluctuating cavitary lesions. With subsequent histopathology findings of SOP and severe necrotizing bronchopneumonia, an extensive workup (CT guided biopsy, Bronchoscopy, VATS) and the guided management resulted in marked clinical improvement.

Methods : A 49-year-old female with past medical history of partially treated community acquired pneumonia (CAP) three weeks prior-to presented to the ER with dry cough, nasal congestion, generalized weakness, fatigue, chills, and shortness of breath. Vital signs upon arrival were: 37.5 ° C, 114/74 mmHg, 114 bpm, 22 rpm, and 95% O2 saturation with laboratories demonstrating within normal limits metabolic panel, leukocytosis of 17.2 10^3/uL (ANC of 11), bands of 13%, thrombocytosis (885 K), RDW (16.5), hemoglobin (8.3 g/dL), D-dimer (1399 ng/mL), lactate (1.46), PT/INR (22.2 sec/2.0), leukocyturia (11-20 HPF), and Chest X-ray showing left lower lobe atelectasis versus pneumonia and mid-right basilar atelectasis. The patient underwent Computed Tomography (CT) angiography confirming multifocal pneumonia with a bilateral basilar predominance and airway opacities on right upper lobe. Patient was deemed immunocompetent. Antibiotic therapy was broadened (Vancomycin, Cefepime, Metronidazole and Doxycycline) since patient respiratory condition worsened with hemoptysis and thicker productive cough with evolving cavitary lesions on follow up chest CT scan. Differential diagnosis included infectious and autoimmune causes. Mycoplasma IgM was found positive. Sputum culture grew Achromabacter xylosoxidans and Mycobacterium fortuitum. Negative MTB PCR. Blood and urine culture remained negative. Bronchoalveolar lavage was positive for MRSA, Geotrichum candidum, eosinophilic secretion, inflammatory cell and negative for malignancy cells. CT guided left lower lobe core-needle biopsy revealed organizing pneumonia with fibrinoid material and acute inflammation. Subsequently, the patient improved after extensive supportive and antibiotic therapy (length of stay 17 days), leading to a safe discharge (with a 7-day home IV antibiotic therapy with Linezolid), but an inconclusive diagnosis. Sixty-five days after being discharged patient returned to the hospital due to abdominal pain and reported hematochezia with associated fatigue, night sweats, dry cough, and dyspnea on exertion. Low titer positive ANCA (PR3 and MPO) was suggestive of inflammatory bowel disease. Chest CT re-demonstrated prior cavitary lesions, now increased in size and number. Due to the nature of this subacute fluctuating cavitary lesions, she underwent right upper and lower lobe wedge biopsy of the lungs which initially suggested necrotizing granulomatous inflammation with associated vasculitis. However, final diagnosis was consistent with secondary organizing fibrinous pneumonia and severe necrotizing bronchopneumonia with abscess formation. Patient was started on steroid and mesalamine therapy which resulted in marked improvement on lung lesions.

Results: The clinical and radiographic findings in patients with COP and SOP are similar and nonspecific. Although certain laboratory abnormalities are more common in SOP and can be associated with worse prognosis, they are likely due to the underlying disease. COP and SOP have similar treatment response, prognosis, relapse rates, and mortality (8, 11). However, some other studies show that clinical classification of OP is useful to predict clinical course and outcome. COP most often presents with a symptomatic bilateral lung process that had an overall favorable prognosis with prolonged corticosteroid therapy. Patients with SOP have a high mortality rate when the disease is associated with predisposing conditions or drugs. Patients with asymptomatic focal OP have an excellent prognosis (10). Diagnostic value of bronchoscopy is significantly higher in COPs. Although diffuse radiological pattern is more common in "successful bronchoscopy" group, frequency of focal pattern is higher in "failed bronchoscopy" group. Ground glass opacity in successful bronchoscopy group and mass-like lesions in failed bronchoscopy group reach significant differences (14). Both COP and SOP are steroid-responsive. Delayed treatment may be associated with frequent relapses, and thus it is highly imperative to have a high degree of suspicion and to have pathological confirmation so that treatment can be instituted early. Factors associated with a relatively worse prognosis include the presence of diffuse interstitial infiltrates as the predominant radiographic abnormality, paucity of lymphocytes on bronchoalveolar lavage, presence of associated conditions, and a finding of scarring and remodeling of the lung parenchyma in addition to organizing pneumonia. Patients with IBD can develop varied inflammatory complications in the lung and a sizable fraction of these complications is steroid-sensitive (12).

Conclusion: Clinical classification by histopathology of OP is useful to predict clinical course and outcomes. COP which presents as a symptomatic bilateral lung process that have an overall favorable prognosis with prolonged corticosteroid therapy. However, patients with SOP had a high mortality rate when the disease was associated with predisposing conditions or drugs. Patients with IBD can develop varied inflammatory complications in the lung and a sizable fraction of these complications that are steroid-sensitive such as in this case in which the preliminary pathology suggestive of necrotizing granulomatous inflammation with associated vasculitis. This allows for early correct instauration of treatment (steroid treatment), with marked clinical improvement. Furthermore, VATS procedure might provide curative treatment in this case of severe necrotizing bronchopneumonia as there are no practice guidelines to direct the care of patients with necrotizing pneumonia and determining if and when surgical intervention is needed is challenging.

PO-130

Veno-venous extracorporeal membrane oxygenation rescue therapy without mechanical ventilation for acute lung injury following lung volume reduction surgery

Naselsky,Warren、Encarnacion,Carlos、Galvagno,Sam、Krause,Eric、Holden,Van、Pickering,Edward、Burrows,Whitney、Sachdeva,Ashutosh
University of Maryland School of Medicine

Objective: *Case Report* Patients with severe COPD/Emphysema who undergo either lung-volume reduction surgery (LVRS) or bronchoscopic LVR (bLVR) with endobronchial valves are at risk for significant pulmonary complications including pneumothorax, persistent air leak, pneumonia and respiratory failure. We report the use of veno-venous extracorporeal membrane oxygenation (V-V ECMO) to rescue a patient with delayed pneumothorax and severe respiratory failure after LVRS and avoid intubation and mechanical ventilation.

Methods: Not Applicable

Results: A 61-year-old gentleman with severe COPD, needing 2L/min nasal cannula oxygen with exertion, and significant dyspnea with exertion was referred to our center after a failed bLVR done at another institution two years prior. Although initially considered for repeat bLVR, he was found to have multiple incomplete fissures and was

offered bilateral LVRS. His postoperative clinical course was unremarkable other than possible pneumonia for which he received antibiotics and was discharged home on postoperative day (POD) 11. His chest tubes, right and left, were removed on POD 3 and 7 respectively after he no longer had any air leak. He returned to the hospital 3 days later with progressive shortness of breath and was found to have large right-sided pneumothorax, which was rapidly drained with a pigtail catheter (figure 1). Despite adequate pneumothorax evacuation his respiratory status continued to decline. He was in respiratory extremis within 24 hours. After much discussion, weighing in the risks and benefits of intubation and mechanical ventilation versus V-V ECMO, the patient was rapidly placed on V-V ECMO with percutaneous femoral-jugular cannulation strategy. This resulted in rapid improvement in his hypoxemia and respiratory acidosis. The patient remained on ECMO for a total of 14 days prior to decannulation. His only ECMO related complication was a lower extremity DVT for which he was treated with anticoagulation. He was eventually discharged to home on low oxygen supplementation on hospital re-admission day 28. The patient is now approximately 7 months from surgery and is doing well at home, using 2 L/min oxygen via nasal cannula with exertion but improved exertional dyspnea symptoms and FEV1.

Conclusion: We present the use of V-V ECMO for rescue therapy, instead of mechanical ventilation, in a patient with severe COPD/Emphysema who developed respiratory failure after LVRS. Especially in this patient population who are susceptible to ventilator-induced lung injury and ventilator dependency, it is important to consider ECMO as a potential alternative to mechanical ventilation. It is important to consider the availability of ECMO when planning bLVR/LVRS.

PO-131

Is there any correlation between CBC values, body measurements and OSAS and disease severity ?

Cilingir,Fatih Mehmet
Bafra State Hospital

Objective: Our study aimed to investigate the relationship between complete blood count (CBC) values like platelet count, mean platelet volume (mpv), neutrophil, lymphocyte, neutrophil to lymphocyte ratio (n/l), mean corpuscular volume (mcv), body weight, height and body mass index with obstructive sleep apnea syndrome (OSAS) and disease severity.

Methods: A total of 344 people were included in the study162 (47,1%) were female and 182 (52,9%) were male. The mean age of total group was 51,28; while the mean age of the women population was 53,16 years and the mean age of the men population was 49,60. People were divided into two groups according to apnea-hipopnea index (AHI) normal and OSAS group. Person apnea-hipopnea index <5 was assumed as normal, while AHI ≥5 was assumed as OSAS. Also patients with OSAS were divided into three groups according to disease severity from mild to severe. CBC values of group with normal total AHI and group with OSAS were statistically compared.Also body measurements were compared.

Results: There was no statistically significant difference between presence of OSAS and platelet count (p: 0.321), mcv (p: 0.342), neutrophil count (p: 0.559), lymphocyte count (p: 0.998), n/l ratio (p: 0.270), mpv (p: 0.871). There was no statistically significant difference between presence of OSAS and height (p: 0.996) but statistically significant difference with body weight (p: 0.000), body mass index (p: 0.000).There was no statistically significant difference between disease severity and mpv, neutrophil count, lymphocyte, n/l ratio, mcv, platelet count and height, respectively (p: 0.784, p: 0.515, p: 0.159, p: 0.367, p: 0.841, p: 0.402, p: 0.524). Disease severity was statistically significant between body weight and body mass index, respectively (p: 0.001, p: 0.001).

Conclusion: In other studies CBC values like mpv, n/l ratio were correlated with OSAS and disease severity but in our study there was no correlation.Therefore, further prospective data is needed.

PO-132

Radial probe endobronchial ultrasound guided transbronchial croybiopsy

Yang,Jinmi
INNER MONGOLIA PEOPLE'S HOSPITAL

Objective: To observe the clinical value of radial probe endobronchial ultrasound guided or combined with conical beam CT positioning guided transbronchial croybiopsy.Retrospctive summery about 20 cases in China-Japan firendship hospital during December 2018 to October 2019 used radial probe endobronchial ultrasound guided or combined with conical beam CT positioning guided transbronchial croybiopsy. Discasing and analying the value of radial probe endobronchial ultrasound guided transbronchial croybiopsy.The specimens of the 20 cases were all qualified and the operations did not lead to any seriously complications.The results of the pathology were significant to the discussion of multi-disciplinary team（MDT）or the final diagnosis.Radial probe endobronchial ultrasound guided transbronchial croybiopsy is a method of practicablity and non-radiation，with high positioning accuracy and high diagnostic positive rate and low incidence rate of seriously complications （such as massive bleeding）.If combined with conical beam CT positioning guided，the position of biopsy could be more accurate.And the risk of massive bleeding and pneumothorax also should be reduced.

Methods: Retrospctive summery about 20 cases in China-Japan firendship hospital during December 2018 to October 2019 used radial probe endobronchial ultrasound guided or combined with conical beam CT positioning guided transbronchial croybiopsy. Discasing and analying the value of radial probe endobronchial ultrasound guided transbronchial croybiopsy.

Results: Discasing and analying the value of radial probe endobronchial ultrasound guided transbronchial croybiopsy.The specimens of the 20 cases were all qualified and the operations did not lead to any seriously complications.The results of the pathology were significant to the discussion of multi-disciplinary team（MDT）or the final diagnosis.

Conclusion: Radial probe endobronchial ultrasound guided transbronchial croybiopsy is a method of practicablity and non-radiation，with high positioning accuracy and high diagnostic positive rate and low incidence rate of seriously complications （such as massive bleeding）.If combined with conical beam CT positioning guided，the position of biopsy could be more accurate.And the risk of massive bleeding and pneumothorax also should be reduced.

PO-133

The diagnosis of ARDS about 2 cases with ECMO by radial probe endobronchial ultrasound guided transbronchial croybiopsy

Yang,Jinmi
INNER MONGOLIA PEOPLE'S HOSPITAL

Objective: Because of the physiopathologic mechanism of ARDS ，which leads to the imaging findings are very similar to the interstitial lung disease，we always needs to make differential diagnosis.The transbronchial croybiopsy have fewer complications and damages than surgical lung biopsy and using of the radial probe endobronchial ultrasound guided ，made the transbronchial croybiopsy could be done beside the bed.We have completed 2 cases of transbronchial croybiopsy with ECMO-supporting to diagnosis ARDS，and the results of the pathology have made positive meanings to clinical diagnosis and treatment.The 2 cases dose not have seriously complications and adverse consequences.Now we share and discuss the security of the radial probe endobronchial ultrasound guided transbronchial

croybiopsying beside the bed，and how to control the timing of anticoagulation during the ECMO-working.

Methods： The transbronchial croybiopsy have fewer complications and damages than surgical lung biopsy and using of the radial probe endobronchial ultrasound guided ，made the transbronchial croybiopsy could be done beside the bed.We have completed 2 cases of transbronchial croybiopsy with ECMO-supporting to diagnosis ARDS，and the results of the pathology have made positive meanings to clinical diagnosis and treatment.The 2 cases dose not have seriously complications and adverse consequences.Now we share and discuss the security of the radial probe endobronchial ultrasound guided transbronchial croybiopsying beside the bed，and how to control the timing of anticoagulation during the ECMO-working.

Results： We have completed 2 cases of transbronchial croybiopsy with ECMO-supporting to diagnosis ARDS，and the results of the pathology have made positive meanings to clinical diagnosis and treatment.The 2 cases dose not have seriously complications and adverse consequences.

Conclusion： We have completed 2 cases of transbronchial croybiopsy with ECMO-supporting to diagnosis ARDS，and the results of the pathology have made positive meanings to clinical diagnosis and treatment.The 2 cases dose not have seriously complications and adverse consequences.Now we share and discuss the security of the radial probe endobronchial ultrasound guided transbronchial croybiopsying beside the bed，and how to control the timing of anticoagulation during the ECMO-working.

PO-134

Cytology Profile of Bronchoalveolar Lavage Fluid and Bronchial Brush using Flexible Bronchoscopy in Lung Cancer Patient at Zainoel Abidin Hospital Aceh

Efrina,Devi、Zulfikar,Teuku
Syiah Kuala University

Objective： Lung cancer occurred in approximately 1.8 million patients in 2012 and cause 1.6 million deaths. Approximately 95 percent of all lung cancers are classified as small cell lung cancer (SCLC) or non-small cell lung cancer (NSCLC). Flexible bronchoscopy is a reasonable approach for the evaluation of large centrally located parenchymal masses discovered with chest imaging. Diagnostic specimens can be collected for cytopathological analysis by washing, brushing, BAL, or biopsy. The extent of extrinsic compression of the airway from the mass if present can also be assessed as well as direct sampling of peribronchial masses with transbronchial needle aspiration (TBNA) can be performed. Flexible bronchoscopy alone is much less useful for smaller peripheral nodules. Cytological techniques such as bronchoalveolar lavage (BAL) and bronchial brushing (BB) can aid in the early diagnosis of lung malignancies.

Methods： Case investigated with possible lung malignancy by brushing and bronchoalveolar lavage the visualized lesions while doing flexible bronchoscopy after taking informed consent from the patients. Specimen ware taken during flexible bronchoscopy under general anesthesia. Study was performed period 1 year from june 2017 to mei 2018. The bronchial brushing smear were fixed with 95% alcohol and BAL samplewere received as 20 ml aliquouts of normal saline in sterile vials. Sample immediately sent to the cytologist for examination

Results： The study comprised of 266 sample who include 149 male dan 49 female of 198 patients suggest to malignancy. There were 149 male and 48 female that perform to Bronchoalveolar lavage fluid examination and 48 male patients and 21 female patients that perform to bronchial brush examination. Diagnoses made by brusing and bronchoalveolar lavage of the 198 patients, suggests that 86 sample (32.33%). A combination of two techniques yielded the highest percentage of positive diagnoses is represented by bronchial brushing examination (73,91%) dan bronchoalveolar lavage examination (17.77%).

Conclusion: Several studies have investigated the accuracy of brushing and bronchoalveolar lavege with flexible bronchoscopy. In this study in comparation to Bronchoalveolar lavage and bronchial brush gave higher number positive result malignancy cell using bronchial brushing methode (73.91%), compare to bronchoalveolar lavage examination method (17.77%).

PO-135

Bronchoscopic balloon dilatation in the treatment of Tuberculous bronchial stenosis:A case report

liu,chaofeng、Li,Jun
the first hospital of shanxi medical university

Objective: Bronchial tuberculosis is the most commom cause of benign airway stenosis in clinical, the patients can be characterized by these symptoms such as chest pains, chest suppress, dyspena, cough,and so on. These patients will easily progress to tracheal and bronchial stenosis, which will seriously impact on the patient's quality of life. Early detection of bronchial tuberculosis, according to the different pathological type of under the bronchoscope and give appropriate treatments to patients with bronchial tuberculosis is very significant.

Methods: A retrospective analysis:The clinical features, imaging characteristics, treatment and outcome of a patient who was diagnosed as bronchial tuberculosis.

Results: The patient was a famale, 28 years old, was admitted to the hospital on November 23, 2019 , due to "cough and sputum coughing for 1 week and chest pain for 3 days".The patients had symptoms of cough and expectoration, the phlegm was white, about 10 ml/day, oral "clear heat particles, amoxicillin" for 3 days by herself, the symptoms did not relieved,and had the left chest pain, obviously with chest suppress, chest pain and chest suppress symptoms were aggravating gradually, chest X-ray revealed a left pleural effusion, chest CT scan(figure 1) indcated that the left chest had a small amount of effusion, left pulmonary atelectasis. Previous history: tuberculous pleurisy was diagnosed 3 years ago, regular anti-tuberculous treatment for 2 years.Physical examination: T 36 ℃ , HR 77 times/min,RR 20 times/min, Bp111/80 mmHg, conscious, left thoracic collapse, left lung respiratory movement degree was reduced, left lung percussion dullness, no breath sounds.Laboratory examination: blood gas analysis、compete blood count、PCTwere normal, tuberculosis protein chips and tuberculosis antibody are negative. On November 26, 2019, bronchoscopy (figure 3) showed that the opening of the left main bronchus was narrow like a scar, the upper segment of the left main bronchus was distorted and the lumen was narrow like a scar, the tracheoscope could not enter the distal end.Chest enhanced CT and 3D reconstruction of tracheobronchial suggested that left pleural thickening, left pleural effusion, and stenosis of left main bronchus and its branches. The symptoms of cough, sputum and chest pain were alleviated after the treatment with levofloxacin. The first balloon dilatation under bronchoscope was performed on December 3, 2019 (figure 4). The opening of the left main bronchus was narrow like a scar, the tracheoscope could not be extended, and the lumen was significantly narrow. Balloon dilatation of 8×30mm was performed, but the balloon could not be fully penetrated. The bronchoscope balloon dilatation was performed again on December 11, 2019 (figure 5), obvious stenosis of the left main bronchus was observed, the lower segment of it could not be passed by 4.9mm bronchscope , and its distal end was completely blocked. After balloon dilatation (8, 9, 10×30mm) was given, the 5.9mm tracheoscope could be passed, and a pinpoint opening of the lower left lobe could be seen at the distal end.On December 18, 2019 ,the third balloon dilatation (figure 6), it was clearly visible the stenosis of left main bronchial, giving a balloon (8, 9, 10×30 mm) expansion, the bronchoscope can be passed by 5.9 mm tracheoscope, and the opening of upper and lower of left trachea was visible. The chest CT examination on December 23, 2019 (figure 2) showed left atelectasis was significantly improved compared with the previous chest CT .

Conclusion: The patient was a young woman, who has a history of tuberculous pleurisy, the main clinical symptoms are cough, chest pain, dyspena , chest CT and 3D Reconstruction of tracheobronchial both indicate that the left main bronchus and its branches are narrow with left atelectasis,the patient’s diagnosis was left main bronchial

tuberculosis with left atelectasis. After 3 times bronchoscope balloon dilatation,the patient' s clinical symptoms、the narrow left main bronchus and its branches and left atelectasis are obviously improved.Bronchoscopic balloon dilatationis is one of the main methods to treat benign airway stenosis[1]. Studies have shown that bronchial tuberculous stenosis is the primary cause of benign airway stenosis[2]. For patients with scar stenosis, electric knife and APC can be used to cut the stenosis ring first, so as to create conditions for subsequent balloon dilation and achieve better dilation effect. As a method of interventional therapy through bronchoscope, Bronchoscopic balloon dilatationis is effective and safe[3,4], it has great clinical application values[5]. It provides a new approach and method for resolving some patients with airway stenosis who have poor effect of internal medicine and cannot bear surgical treatment. It should be noted that a appropriate intervention method should be selected according to the different types of lesions under bronchoscopy, and multiple intervention methods should be combined to achieve the best therapeutic effect[6].

PO-136

Case report: A case of closure of refractory bronchopleural fistula via intracavity.

Hai,Wang
Shanghai Pulmonary Hospital, Tongji University school of medicine

Objective: Bronchopleuralfistula (BPF) is one of the serious complications after pneumonectomy,which has high difficulty and the mortality in treatment. Recently, with the increase of surgical operations, more attention has been paid to the treatment of BFP under bronchoscopy, and the therapeutic effect has been focused.

Methods: We firstly tried silicone plug,injection of lauromacrogol and argon knife treatment(pic.1), which was repeated three times.After two months, the fistulais enlarged, the effect is not obvious.Then endobronchialvalve (EBV)4.0mm were implanted (pic.1) firstly, but the valve was displaced to the thorax, then EBV was removed by medical thoracoscopy and changed to a big EBV with 5.5mm. After one month observation, the fistula was still presented, and a little bigger than before.Lastly, ventricular septum plug wasimplantedfor blocking the fistula (pic.1),one month after this treatment, individual symptoms, thoracic duct drainage and X-ray examinations indicated successful closure of fistula.

Results: This report introduces a case of bronchopleural fistula was blocked with some methods. A 42 male patient had a pneumonectomy for aspergillusinfection and damage in the right lung.Two months after surgery, fistula occurred in the right lower dorsal lobe of the patient (pic.1),the thoracic duct continuously drained blood-colored fluid, which lasted for more than 2 months. We firstly tried silicone plug,injection of lauromacrogol and argon knife treatment(pic.1), which was repeated three times.After two months, the fistulais enlarged, the effect is not obvious.Then endobronchialvalve (EBV)4.0mm were implanted (pic.1) firstly, but the valve was displaced to the thorax, then EBV was removed by medical thoracoscopy and changed to a big EBV with 5.5mm. After one month observation, the fistula was still presented, and a little bigger than before.Lastly, ventricular septum plug wasimplantedfor blocking the fistula (pic.1),one month after this treatment, individual symptoms, thoracic duct drainage and X-ray examinations indicated successful closure of fistula.Finally, the fistula was successfully blocked and the patient recovered gradually.

Conclusion: There are many different techniques for treating bronchial fistulas, and treatments vary with the size and depth of the fistula.As one of the internal medicine methods, the treatment of bronchial fistula through bronchoscope has shown great advantages, such as high efficiency, safety, less complications and so on, which will be widely applied in clinical practice in the future.

PO-137

Curative efficacy of Fiberoptic bronchoscopy assisted in treatment of Tuberculosis (TB) and its effectson respiratory function of patients

Kadiliya,abuduweili
PEOPLE'S HOSPITAL OF XINJIANG UYGUR AUTONOMOUS REGION

Objective: To study Curative efficacy of Fiberoptic bronchoscopy assisted in treatment of Tuberculosis (TB) and its effectson respiratory function of patients. Methods 100 tuberculosis patients admitted to our hospital from October 2015 to October 2018 were selected for the study, and were divided into the observation group (n=51) and the control group (n=49) by the random number table method. The control group was treated with conventional chemotherapy, while the observation group was treated with fiberoptic bronchoscopy. The clinical efficacy, forced vital capacity (FVC), forced expiratory volume in the first second (FEV1), FEV1/FVC, CD3+, CD4+, CD4+ /CD8+ levels and clinical symptom improvement time of the two groups were compared. Results After treatment, the total effective rate of the observation group was 82.35%, significantly higher than 63.27% of the control group (P < 0.05); Before the treatment, there was no significant difference in the level of respiratory function between the two groups; after the treatment, the level of respiratory function in the two groups was improved, and the levels of FVC, FEV1, FEV1 / FVC in the observation group were significantly higher than those in the control group (P < 0.05); Before treatment, there was no significant difference in the level of immune function between the two groups; after treatment, the level of immune function in the two groups was improved, and the levels of CD3 +, CD4 +, CD4 + / CD8 + in the observation group were significantly higher than those in the control group, and the level of CD8 + was significantly lower than that in the control group (P < 0.05); after treatment, the observation group had significantly lower cavity shrinkage, cavity closure, sputum smear turning negative and sputum culture turning negative time than that in the control group, with significant difference (P < 0.05). Conclusion: the effect of fiberoptic bronchoscopy in pulmonary tuberculosis patients is significant, and respiratory function can be effectively improved

Methods: 1.1 一般资料　选择 2015 年 10 月至 2018 年 10 月我院收治的肺结核患者 100 例进行研究。采用随机分组法分为 2 组，观察组 51 例，男 26 例，女 25 例，年龄 20-70 岁，平均（49.56±3.52）岁，病程 10~20 月，平均（15.56±2.25）月，空洞数目（2.54±0.32）个；结核类型：慢性纤维空洞型 35 例，浸润型 16 例；病变部位：双肺 24 例，左肺 15 例，右肺 12 例。对照组 49 例，男 26 例，女 23 例，年龄 20-68 岁，平均（49.51±3.48）岁，病程 9~19 月，平均（15.48±2.19）月，空洞数目（2.39±0.29）个，结核类型：慢性纤维空洞型 32 例，浸润型 17 例；病变部位：双肺 22 例，左肺 16 例，右肺 11 例。两组基线资料无明显差异，具有可比性。 纳入标准：（1）符合《肺结核门诊诊疗规范》[7] 中的诊断标准；（2）X 线检查证实肺内伴有病灶、空洞；（3）正规治疗 12 个月以上，复查痰菌阳性；（4）满足手术指征。排除标准：（1）重药物过敏者；（2）有心、肝、肾等功能异常者；（3）妊娠期和哺乳期妇女。1.2 方法 对照组给予常规化疗方案 (2HRZES /6H R E)：采用异烟肼（规格：100mg，生产厂家：上海信谊黄河制药有限公司，国药准字：H31020495）0.3g 口服，1d1 次、乙胺丁醇（规格：0.25g，生产厂家：北京曙光药业有限责任公司，国药准字：H11021034）0.75g 口服，1d1 次。吡嗪酰胺（规格：0.25g，生产厂家：上海信谊药厂有限公司，国药准字：H31020800）1.5g 口服，1d1 次。利福平胶囊（规格：0.15g/ 粒，生产厂家：沈阳红旗制药有限公司，国药准字：H21021905）450mg，口服，1d1 次联合链霉素（规格：0.75g，生产厂家：华北制药股份有限公司，国药准字：H13020651）0.75g 加入 250mL 的 5% 葡萄糖注射液或者 0.9% 氯化钠注射液中静脉滴注，1d1 次治疗方案，巩固期 6 个月采用异烟肼、利福平联合乙胺丁醇治疗方案。观察组在对照组的基础上经纤维支气管镜局部药物注射，支气管镜置入后，将脱落、坏死组织吸除，局部注射左氧氟沙星（规格：0.1g，生产厂家：上海普康药业有限公司，国药准字：H10980067）0.2g，丁胺卡那（规格：10ml：25mg，生产厂家：四川方向药业有限责任公司，国药准字：H51023304）0.2g，每周治疗 1 次。 1.3 观察指标 FEV1、FVC、FEV1/FVC 水平采用 HI-101 肺功能检测仪测定；使用 Beckman Coulter FC500 全自动流式细胞仪对各个时间段 T 细胞亚群（CD3+、CD4+、CD8+）进行检测；观察记录临床症状改善时间。 疗效评定标准：　显效：临床症状基本消失，痰液转阴；有效：临床症状有所改善，痰液转阴；无效：临床症状无改善或加重。 1.4 统计学分析　以 spss18.0 软件包处理，符合正态分布计量资料用均数 ± 标准差（±s）表示，

组间比较使用独立样本 t 检验，计数资料以率表示， x 2 检验， P ＜ 0.05 表示差异具有统计学意义。

Results：2.1 两组疗效比较 治疗后，观察组总有效率为 82.35% 显著高于对照组的 63.27%，差异显著（P ＜ 0.05），见表 1。 表 1 两组疗效比较 [n（%）] 组别例数显效有效无效总有效率 观察组 5128(54.90)14(27.45)9(17.65)42(82.35) 对照组 4916(32.65)15(30.61)18(36.73)31(63.27) x 2 值 4.619 P 值 0.032 2.2 两组呼吸功能比较 治疗前，两组呼吸功能水平无显著差异；治疗后，两组呼吸功能水平均有所改善，且观察组 FVC、FEV1、FEV1/ FVC 水平均显高于对照组，（P<0.05），见表 2。 表 2 两组呼吸功能比较（±s） 组别例数 FVC（%）FEV1（%）FEV1/ FVC 治疗前治疗后治疗前治疗后治疗前治疗后 观察组 5174.45±6.5486.20±11.4165.01±5.4282.84±8.6464.21±7.1275.69±11.32 对 照 组 4975.02±6.7580.12±9.1463.34±6.4776.45±7.3364.27±7.1571.01±9.21 t 值 0.4292.9341.4013.9800.0422.263 P 值 0.6690.0040.1640.0000.9670.026 2.3 两组免疫功能比较 治疗前，两组免疫功能水平无显著差异；治疗后，两组免疫功能水平均有所改善，且观察组 CD3+、CD4+、CD4+ / CD8+ 水平均显高于对照组，CD8+ 水平显著低于对照组，（P<0.05），见表 3。 表 3 两组免疫功能比较（±s） 组别例数 CD3+（%）CD4+（%）CD8+（%）CD4+ /CD8+ 治疗前治疗后治疗前治疗后治疗前治疗后治疗前治疗后 观察组 5158.18±2.2669.49±2.1523.71±1.4938.19±1.4134.19±2.3224.14±1.210.71±0.141.58±0.21 对照组 4958.21±2.2963.45±2.0123.68±1.5334.15±1.3234.25±2.3828.16±1.450.73±0.151.27±0.21 t 值 0.06614.4980.09914.7780.12815.0760.6897.379 P 值 0.9480.0000.9210.0000.8990.0000.4920.000 2.4 两组症状改善时间比较 治疗后，观察组空洞缩小、空洞闭合、痰涂片转阴、痰培养转阴时间均显著低于对照组，差异显著（P<0.05），见表 4。 表 4 两组症状改善时间比较（±s） 组别例数空洞缩小（d）空洞闭合（月）痰涂片转阴（d）痰培养转阴（d） 观察组 5139.78±6.413.58±1.1373.56±14.2551.23±11.58 对照组 4958.63±5.497.15±2.4397.67±16.9386.41±11.63 t 值 15.7659.4807.71615.155 P 值 0.0000.0000.0000.000

Conclusion：3 讨论 肺结核是由结核分枝杆菌感染后侵袭人体肺部组织引起的一种严重传染性疾病，临床表现为咳嗽、低热、乏力等症状，人体感染肺结核后不一定发病，当抵抗力降低时才可能引起临床发病，若能给予及时有效的治疗大多数患者则可痊愈 [8~9]。近年来，随着病情的不断蔓延，国内结核病的发病率呈逐年增长趋势，严重威胁人类健康 [10]。 临床通常使用药物治疗该病，但目前，肺结核患者总耐药率高达 30%，经多种抗核药物治疗后仍有更多患者呈阳性 [11]。耐药性肺结核患者具有病程长、肺内纤维组织增生广泛等特性，机体组织长时间的缺氧，药物不能很好的渗透，从而使药物有效率降低，故有学者提出将纤维支气管局部治疗应用于此病中 [12]。纤维支气管镜可以清除肉芽组织和坏死物，促进药物发挥作用，提升治疗效果。本研究结果显示，纤维支气管镜辅助治疗的患者总有效率为 82.35%，明显高于单独使用药物治疗的患者，且空洞缩小、空洞闭合、痰涂片转阴、痰培养转阴时间均显著低于对照组，结果提示，纤维支气管镜辅助可缩短症状改善时间，提高治疗效果。分析其原因是因为纤维支气管镜可选择性提高局部药物浓度，增加药物与结核菌的接触结合，控制了结核菌的生长，从而提高患者的治疗效果。肺结核患者周围肺组织遭严重破坏，纤维组织增生，局部血液循环差，可严重影响患者肺功能，导致患者肺功能指标下降，促进肺组织缺氧，不利于空洞的愈合，严重影响患者康复进程 [13]。有研究显示，肺功能在复治菌阳肺结核中降低，且经治疗后有明显提高，可作为预测疾病的标志物 [14]。本研究结果显示，纤维支气管镜辅助治疗的患者 FVC、FEV1、FEV1/ FVC 水平均显高于单独使用药物治疗的患者，提示，纤维支气管镜辅助治疗肺结核可明显提高患者肺功能指标。李文博 [15] 等研究也显示，在支气管镜下注射能够直视下进入患者病灶部位，有效清除病灶区域的分泌物，引流出洞壁中的干酪样坏死组织，清除细菌，有利于周围新生肉芽组织生长修复。分析其原因是因为纤维支气管镜下注射药物可直达病症被肺泡血管膜等部位吸收，增加药物浓度，增强患者的抗菌能力，同时能局部吸出机体不能自然排除的病症分泌物，清除肺部局部梗阻，改善引流，从而提高肺功能的改善情况。此外，研究结果还显示，纤维支气管镜辅助治疗的患者 CD3+、CD4+、CD4+ /CD8+ 水平均显高于单独使用药物治疗的患者，CD8+ 水平显著低于单独使用药物的患者，结果提示，在纤维支气管镜辅助下治疗肺结核是有效的，可增强机体的保护免疫应答，降低免疫抑制效果，发挥结核杆菌的最大致死性。 综上所述，在肺结核患者中应用纤维支气管镜辅助治疗效果显著，可有效改善患者呼吸功能，值得推广应用。

PO-138

Comparisons of the biopsy efficiency of different tracheoscopy personnel

Mao,Jingyu、Qian,Jiale
The first affiliated hospital

Objective: the biopsy assisting method of tracheoscopy personnel with training experience less than 6 months (Personnel A) andtracheoscopy personnel with over 3 years of training experience (Personnel B) in tracheoscopy, compare the differences of their methods and the satisfaction of the specimens, looking for ways to improve the positive rate intracheal biopsy in real practice of the procedure。

Methods: The collection of biopsy specimens from all patients included in the study was divided into two phases. In the observation stage, biopsy specimen collection on same patient was divided into two phases. In the first phase 5 biopsies were performed by Personnel A, and in the second phase 5 biopsies were performed by Personnel B. Specimens were then measured using biopsy forceps and all biopsy forceps used were Miro-Tech™ MTN-BF-18/12. Measuring criteria were full cup, 1/2 cup, <1/2 cup and empty cup. Full cup and 1/2 were classified as satisfactory, while the rest were not.

Results: A total of 279 cases of tracheal endoscopic biopsy were collected in this study. The satisfaction of specimens collected by Personnel B reached 71.4% and it was much higher than that of the Personnel A, with a satisfactory rate of only 25.1%. Full cup rate by Personnel B was 26.7%, as opposed to 5.8% by Personnel A. Meanwhile, the one-time success rate of biopsy on difficult tissues by Personnel Bwas distinctly greater thanPersonnel A.

Conclusion: The size of specimen is big enough, positive rate for diagnosis is markedly increased and this can provide groundings for succeeding diagnosis and treatment.Through this study, we find it is very necessary to carry out specialized tracheoscopy training. For tracheoscopy personnel currently performing or about to perform tracheoscopy biopsy, systematic training (≥6 months) should be carried out to raise the positive rate of biopsy specimens and provide more precise examination results for clinical treatment.

PO-139

Efficacy of radial probe endobronchial ultrasound as a diagnostic tool for benign/malignant peripheral pulmonary lesions without guide sheath/fluoroscopy

Guliani,Abhinav、Basu,Arup、Dhamija,Amit
Sir Ganga Ram Hospital, New Delhi, India

Objective: Peripheral pulmonary lesions are commonly encountered by a pulmonologist. Now with the inclusion of CT screening for early detection of lung cancer by ACCP in their latest guidelines, the number of peripheral pulmonary lesions requiring evaluation is bound to increase. Modalities widely used to evaluate such a lesion are CT guided biopsy/FNAC, blind or fluoroscopy guided transbronchial lung biopsy, radial pobe EBUS with guide sheath, latest navigational techniques. With the advent of radial probe endobronchial ultrasound and navigation techniques, the yield of a transbronchial biopsy can be increased and thus VATS biopsy can be avoided. There is ample literature on the efficacy of radial probe EBUS with guide sheath with a diagnostic yield of nearly 75%. We analysed retrospective data on radial EBUS at our hospital to ascertain the diagnostic yield without help of guide sheath or fluoroscopy.

Methods: We analysed 258 cases of peripheral pulmonary nodules and small consolidations who presented as outpatients or inpatients to Sir Ganga Ram Hospital in whom radial probe EBUS was used to establish a diagnosis. All patients underwent flexible bronchoscopy under conscious sedation or general anaesthesia. Radial probe EBUS without

guide sheath was used to localize the lesion seen on CT, followed by transbronchial biopsy and/or bronchoalveolar lavage to establish a diagnosis. Cryoprobe was also used in some cases to take biopsy.

After: localization of the lesion, site was confirmed by reinserting probe. Distance from the opening of bronchus was noted by withdrawing probe. This was followed by withdrawal of probe from the working channel and biopsy forceps/cryoprobe was passed to the opening of the identified bronchus. Forceps/probe were advanced the measured length to take multiple biopsies. The technique will also be presented as a video. We evaluated the lesions in terms of size, distance from hilum, distance from the pleura and whether the biopsy was taken from within the lesion or with the bronchus abutting the lesion.

Results: The results included both malignant and infective pathologies with malignancy being more than infective. The diagnostic yield obtained using radial probe EBUS was considerably higher than a blind TBLB for such lesions. It was also comparable with biopsies with guide sheath/fluoroscopic guidance. Other results and review of literature will be presented.

Conclusion: Radial EBUS is an excellent tool to visualize and sample peripheral pulmonary lesions. It is a safe and effective modality even when performed without guide sheath/fluoroscopy guidance. It can also be combined with cryoprobe transbronchial biopsy for better results.

PO-140

Retrospective clinical study of 20 cases of fistula closure by EBV.

Hai,Wang
Shanghai Pulmonary Hospital, Tongji University school of medicine

Objective: Endobronchial valve (EBV) is a new endoscopic treatment for bronchial fistula.This study reviewed and analyzed the follow-up results of 20 patients with bronchial fistula who underwent bronchoscope implantation of endobronchial valves (EBV) in our hospital, and discussed the clinical application value of EBV technology in the closure of bronchial fistula.

Methods: From August 2016 to December 2019, 20 cases of bronchial fistula were treated with endobronchial valve implantation under bronchoscope.After anesthesia, the patient was first checked the location of fistula by Chartis system to determine the side of the fistula and whether there was lateral branch ventilation. Then, the size of the EBV was measured. Finally, the one-way valve was placed into the collateral of the fistula (Pic.1).A systematic review was conducted on the disease types,mean intubation time, postoperative treatment effect and postoperative complications.

Results: There were totally 20 patientsunderwent EBV implantation under bronchoscope, male 15, female 5, average age 56 years old.Among the etiology of 20 patients, 17 had bronchopleural fistula and3had bronchial esophageal fistula. There were 5 patients with pneumothorax, 6patients with tuberculosis, and 9 postoperative patients. A total of 32EBVs were implanted,the average is 1.6 per person. Among the 20patients, 14 (70%) showed significant improvement in clinical symptoms (cough, sputum, chest tightness, etc.), imaging results (X-ray and CT indicated pneumothorax or liquid pneumothorax) and manifestations under bronchoscopy after treatment. The average time of thoracic duct removal was31.9 days after treatment. After EBV surgery, white sticky sputum around the flap was observed in all 20patients (90.63%); after implantation of 25one-way valves, granulation in the flap formed or blocked the flap orifice (78.13%); and in3patients, EBV displacement or shedding occurred (9.38%), without death, massive hemorrhage, pneumothorax and other serious complications.

Conclusion: The success rate of EBV in the closure of bronchial fistula was70%, this is an effective endoscopic treatment for bronchial fistula, with high efficiency, safety, less complications and so on.

PO-141

Questionnaire results of the 2019 survey of Hunan provincial interventional bronchoscopy league

Xiao,Kui1、Shi,Zhihui1、Xia,Shulan1、Liu,Heping2、Hong,Kefu3、Xie,Lihua4、Liu,Wenguang5、Xiao,Yangbao6、Tan,Xiaowu7、Tang,Binsong8、Huang,Changyi9、Xiang,Zhi10、Lin,Chunlong11、Li,Zhe12、Liu,Yi13、Liu,Zhiguang14、Jiang,Mingyan15、Wang,Xianyong16、Liu,Guoping17、Yu,Dinghong18、Li,Keyu19、Huang,Hua20、Lan,Lan21、Yang,Huaping22、Zhou,Yong23、Zhou,Rui1

1. The Second Xiangya Hospital, Central South University
2. The Second Hospital of Zhuzhou
3. Kangya Hospital of Yiyang City
4. The Third Xiangya Hospital, Central South University
5. Yiyang Central Hospital
6. Hunan Chest Hospital
7. The Second Hospital, South China University
8. Yongzhou Central Hospital
9. The Fourth Hospital of Chenzhou
10. The First Hospital of Huaihua
11. The Second Hospital of Yueyang
12. The Third Hospital of Changsha
13. Zhuzhou Central Hospital
14. Hunan Provincial Hospital
15. Xiangtan Central Hospital
16. Hospital of Xiangxi Tujia and Miao Autonomous Prefecture
17. The Third Hospital of Xiangtan
18. The First Hospital of Yueyang
19. The First Hospital of Changsha
20. The Second Hospital of Chenzhou
21. Hospital of Zhangjiajie City
22. Xiangya Hospital, Central South University
23. Hospital of Qiyang County

Objective: To investigate the current status of interventional bronchoscopy (IP) in the Pulmonary and Critical Care Medicine Departments (PCCMD) of major hospitals of the Hunan province in year 2019.

Methods: We designed a on-line questionnaire via www.wjx.cn and delivered it to the members of Hunan Provincial Interventional Bronchoscopy League (HPIBL), and all the members of HPIBL filled the questionnaire and send back as we required. All data start from Jan 1st, 2019 to Dec 15th, 2019.

Results: A total 23 hospitals joined in this yearly survey, including 21 tertiary hospital and 2 secondary hospital, located in 11 cities in Hunan province. 21 hospitals have independent PCCMD while 2 were not. 20 IP centers belongs to the PCCMD while 3 belongs to the Endoscopy Center. The number of beds ranges from 6 to 158, with a mean number 94. The area of IP center ranges from 60 to 1000 m2, with a mean number 207. The number of IP doctors in each center ranges from 2 to 12, with a mean number 4.8. The number of IP nurses in each center ranges from 1 to 38, with a mean number 4.5. The number of IP technician in each center ranges from 1 to 15, with a mean number 3.5. Among all these IP centers, 20 have Olympus endoscopy, 7 have Fuji endoscopy, 3 have Pentax endoscopy. Totally, there are 43 fiberoptic bronchoscopes, 127 electronic bronchoscopes, 16 ultrasound bronchoscopes, 31 rigid bronchoscopes, 18 semi-rigid medical thoracoscopes, 5 rigid medical thoracoscopes, 71 multi-channel monitors, 19 defibrillators, 18 high frequency ventilators, 16 anesthesia machines, 3 C-arm fluoroscopies, 33 endoscope cleaning stations and 10 automatic endoscope washing machines in these centers. The total bronchoscopy examination number is 4,6446 and ranges from 143 to 10,000, with the top ten techniques are tumor biopsy, TBB, cryobiopsy, brushing, BAL, C-TBNA, EBUS-GS-TBLB, EBUS-TBNA, ROSE and virtual navigation. The total bronchoscopy treatment number is 1,1415 and ranges from 33 to 3,000, with the top ten techniques are cryotherapy, balloon dilation, metallic stents, electrocoagulation/

electrotomy, APC, whole lung lavage, block off airway fistula, microwave, laser, transbrochial radioactive particles implantation. The total number of rigid bronchoscopy treatment is 197 and ranges from 0 to 87. The total number of medical thoracoscopes is 1500 and ranges from 4 to 311.

Conclusion: The current status of IP in major hospitals of the Hunan province have solid base, while there are still many aspects need to be improved in the future.

PO-142

Diagnostic yield and complications of Linear EBUS-TBNA- A tertiary care centre experience

Nair,Sreeraj Rajendran、Joseph,Tinku
Dr.

Objective: Among the new diagnostic modalities available to chest physicians, endobronchial ultrasound (EBUS) has unquestionably had the most profound impact. The combined use of Endobronchial ultrasound-guided transbronchial needle aspiration (EBUS-TBNA) with endoscopic ultrasoundguided fine-needle aspiration has been shown to reduce the need for surgical sampling and, by accurately staging unresectable patients, to avoid unnecessary thoracotomies.The aim of our study was to assess technical aspects, diagnostic yield and complications of patients undergoing EBUS-TBNA under conscious sedation.

Methods: This is a prospective observational study data of 618 patients, who underwent EBUS-TBNA under conscious sedation in Interventional Pulmonology unit at Amrita institute of medical sciences, Kochi, were included in our study population. Relevant clinical findings, lab parameters, Chest xray/ CT chest/PET CT findings were noted. Patients with known history of coagulopathy, severe hypoxemia and raised intracranial pressure were excluded from our study population. Equal numbers of punctures were performed at the target lymph node stations using conventional TBNA techniques followed by EBUS-TBNA at the same sites. Indication for EBUS-TBNA, lymph node station accessed, complications and final diagnosis made was noted.

Results: Out of 618 patients, a diagnosis was obtained in 548 patients (Yield: 88.6%). Among these 548 patients, there were 303 cases of malignancy, 245 cases of granulomatous lymphadenitis- Sarcoidosis picture was noted in 67 cases, 86 cases of tuberculosis and 92 cases with reactive lymphadenitis. Out of the 303 malignant cases, 158 cases were adenocarcinoma, 92 squamous cell carcinoma, 53 small cell carcinoma, , Among complications during EBUS-TBNA intra-procedural hypoxemia was noted in 25 patients, minor bleeding in 14 patients and respiratory depression in 3 cases.

Conclusion: EBUS-TBNA is a highly accurate (diagnostic yield 88.6 %) and relatively safe procedure for diagnosing mediastinal and hilar lesions. In our experience, malignancy was the most common etiology for mediastinal lymphadenopathy, out of which, adenocarcinoma was the most common.

PO-143

Endobronchial Ultrasonography Pro-core vs. 19 g needle

šest á kov á ,zuzana1、Votruba,Jir í 1、Duškov á ,Jaroslava2
1. 1 st Chest clinic
2. Pathology clinic of 1 st medical faculty

Objective: The sensitivity of the CT scan to determine correctly the bronchial infiltration and the involvement of the hilar and mediastinal nodes in lung cancer is very unsatisfactory. Due to the increasing emphasis on correct nodal diagnosis of lung cancer, we currently use a linear endosonography (EBUS) for N staging of lung cancer, whose greatest advantage is the ability to perform transbronchial needle aspiration in real time under direct ultrasound control through the bronchoscope working channel. The number of performed punctures at each nodal locus has the greatest influence on the yield of linear ultrasonography. The additive benefits of pro-core needles, which may be very flexible and thin, are not entirely clear - and yet may be capable of taking a high-quality tissue sample due to a different biopsy pattern. Given that the accessibility of some mediastinal and hilar sites of a histological needle is very limited due to its limited flexibility (eg 4L location), it would be very beneficial for clinicians to find that pro-core needle recovery for diagnostic purposes is comparable to histological needle recovery . The aim of our work was to prospectively compare the biopsy efficiency.

Method : Prospective evaluation of two needle systems used for EBUS guided nodal diagnostics in order to prove non-inferiority of the pro-core G22 puncture system compared to a 19G histological needle.

Results: Combined sensitivity of both biopsy systems was 94,5%, histology 19G needle showed 84% diagnostic yield, surprisingly procore 22 G needle brought diagnostic material in only 64% of patients . Morphometry showed total average area of he sample taken by 19 G needle to be 0,924-1,816 mm² and 0,33-1,192 mm² with the use od 22 G procore needle.

Conclusion: Three samples from one lymph node may not be sufficient for quality diagnostics - combined sensitivity was 94.5%, while with 19G (3 TBPs) 84% and with 22G procore 64%(another 3 TBPs). Pro-core needle did not have a significantly better (non-bloodied) morphology for the pathologist, morphometry came out significantly in favor of the 19G needle.

PO-144

Micro laryngeal Tube (MLT/MLS) guided debulking of Tracheo-Bronchial Rhinosporidiosis lesions - An alternative option to Rigid Bronchoscopy

Kavanakudiyil,Tinku Joseph
Amrita Institute of Medical Sciences &Research center, Kochi, Kerala, India

Objective: Rhinosporidiosis is an infection of mucocutaneous tissue caused by Rhinosporidiumseeberi. It is a chronic granulomatous disease characterized by the production of large polypoidal hyperplastic, highly friable and sessile or pedunculated lesions. As the name suggests, nose is most common site. Lesions in the tracheobronchial tree are rarely reported. In our case Rhinosporidiosis lesions was involving predominantly Trachea-bronchial lumen. The main objective of our study was to assess the utility and safety of microlaryngeal tracheal tube (MLT/MLS tube) as an alternative to rigid bronchoscopy in debulking of multiple central airway lesions

Methods: Case report: A 62 year old gentleman, known case of COPD, complaining of cough, progressive dyspnea, orthopnoea and haemoptysis. Bronchoscopy showed multiple broad based lesions involving mid trachea, carina and near total occlusion of left main bronchus. Bronchoscopic biopsy of the lesions confirmed etiology as

Rhinosporidiosis. The patient was scheduled initially to undergo rigid bronchoscopy guided resection of tracheo-bronchial lesions. However in view of inadequate ventilation and high risk of aspiration of blood during debulking, procedure was done with the assistance of an extra long, soft small sized microlaryngeal tracheal tube (MLS/MLT tube). Multiple lesions involving trachea and left main bronchus was initially freezed with the help of 2.4mm cryo-probe and later once the vascularity of lesions reduced it was debulked using snare electrocautery. Through out the procedure a micro laryngeal tube (MLS) was used to ventilate the patient and prevent aspiration of the blood.

Results: MLS/MLT tube provided adequate ventilation for the patient and once the distal cuff of MLT tube was inflated it prevented aspiration of blood associated with debulking. Also since the tube size was small (5mm internal diameter) in size it provided adequate working space inside the tracheal lumen to pass a standard adult flexible bronchoscope and various flexible electro-surgical equipments when we performed this procedure. Entire tracheobronchial rhinosporidiosis lesions were debulked and patient was extubated on table and was discharged the next day.

Conclusion: We recommend the use of extra long, soft, small sized microlaryngeal tracheal tube(MLT/MLS) as a possible alternative to rigid bronchoscope guided debulking of vascular lesions/tumours. It helps to provide bronchoscopist a safer airway

PO-145

Profile of Non-Small Cell Lung Cancer (NSCLC) EGFR Mutation at Zainoel Abidin Hospital Banda Aceh

Bahry,Stanley
indonesian respiratory society

Objective: Mutations of epidermal growth factor receptor (EGFR) have been used widely as for non-small-cell-lung- cancer (NSCLC). The EGFR mutation profile showed significant geographical differences (about 35% in East-Asia and 10% in Caucasian population), but very limit data have been reported from Aceh, Indonesia. We hereby reported the mutation profile of EGFR in Aceh NSCLC patients. To investigate the distribution of epidermal growth factor receptor (EGFR) mutations, and explore any relationships with clinical characteristics in non-small-cell lung carcinoma (NSCLC) patients.

Methods: From January 2012 to June 2019, primary EGFR mutations were assayed in tumor tissue of 86 Aceh patients with NSCLC by a Taq DNA PCR kit Qiagen from Zainoel Abidin Hospital Aceh. Relationships between EGFR mutation and clinical characteristics were analyzed by SPSS 21.0 and chi square.

Results: Among the 86 patients, 57 (66.3%) were male and 29 (33.7%) were female, 39 (45.3%) had adenocarcinoma (ADC) and 47 (54.7%) had squamous carcinoma (SCC). The median age of patients was 56 yr. ADC is more common in women (48,3%), whereas in men it is more SCC (56,1%) (p= 0,873). The EGFR mutation rate was 25.5% (22/86). EGFR mutations occurred more frequently in age >60 yr (25,7 vs 25,5, p= 1,00). The positive EGFR is more common in female than in male (31% vs 22.8%, p= 0.572). The positive EGFR tended to be more founded in ADC compared to SCC (28.2% vs 23.4%, p= 0.795). Ratio EGFR mutation profile was shown more positive 1.2 in ADC than SCC, more positive 1.36 in female than male, and more positive 1.009 in >60 yr (risk estimate).

Conclusion: There was no significant association between age, sex, and NSCLC cell type (ADC and SCC) with the positivity of EGFR. The EGFR mutation rate was low at Zainoel Abidin Banda ACEH and SCC is more common than ADC. Ratio EGFR mutation profile was shown more positive 1.2 in ADC than SCC, more positive 1.36 in female than male, and more positive 1.009 in >60 yr (risk estimate).

PO-146

Two cases with Pancreaticopleural Fistula-induced Empyema Thoracis

Guo,Wenjia、Mu,Xiangdong、Wenjia Guo
Beijing Tsinghua Changgung hospital

Objective: Pancreaticopleural fistula (PPF) is a very uncommon complication of pancreatic diseases. Although progressive infection secondary to PPF can lead to significant morbidity and mortality, the initial symptom of always cough or breath shortness may divert clinicians toward the cardiopulmonary diseases with overlook of abdomen. We attempt to describe the clinical characteristics of pyothorax induced by pancreaticopleural fistula and further investigate the diagnosis and treatment of pancreatic empyema.

Methods: Two cases were presented.

Results: In case 1, a 65-year-old male complained of recurrent fever and expectoration over 3 months. The contrast-enhanced chest CT revealed lung abscess in the lower lobe of left lung and besides, left diaphragmatic fistula. Case 2 was about a 50-year-old male who had cough and dyspea for 8 months, of whom chest CT indicated right pneumothorax. The significantly elevated amylase was found with pleural effusion in both patients. Eventually, the contrast-enhanced abdomen CT in case 1 showed possibly mucinous papillary carcinoma in the duct of the pancreas, abdominal abscess around the perforation of posterior gastric wall, and ruptured left diaphragm, while in case 2, a magnetic resonance cholangiopancreatography (MRCP) revealed multiple abnormal signals in the abdominal cavity with discontinuity and distal irregular dilation of pancreatic duct. The diagnosis of pancreaticopleural fistula was made. However, in consideration of the high risk, the patient in case 1 rejected and discharged eventually because of multiple organs involved and severe adhesion due to previous surgery history. Only the patient in case 2 agreed with surgery. Followed by the resection of pancreatic body and tail with cyst drainage and splenectomy, his amylase level within pleural effusion was decreased remarkably. Inflamatory cells were infiltrated without malignancy from the biopsy. On the basis, chronic pancreatitics was considered as the underlying cause.

Conclusion: PPF is a rare complication of pancreatic diseases and most ofter presents itself as unilateral pyothorax. Thoracocentesis and imaging are recommended for the diagnosis. Elevated amylase within pleural effusion makes sense. Surgical intervention should be considered for the treatment.

PO-147

Diagnostic value of Aspergillus galactomannan antigen assay from endobronchial ultrasonography guided bronchial washing fluid for diagnosis of invasive pulmonary aspergillosis

Lin,Ya-Hui、Chen,Chia-Hung、Tu,Chih-Yen、Liao,Wei-Chih、Wu,Biing-Ru、Cheng,Wen-Chien、Hsu,Wu-Huei
China medical university hospital, Taichung, Taiwan

Objective: Invasive Pulmonary Aspergillosis (IPA) is a frequent and increasing cause of morbidity and mortality in immunocompromised patients. To improve the outcome of these often fatal infections, early diagnosis of IPA is of utmost importance. In every entity of pulmonary aspergillosis, the detection of Aspergillus from respiratory tract samples is very important for reaching a precise diagnosis. However, the roles of conventional diagnostic tools, such as cultures obtained from respiratory tract samples, are limited by their low sensitivity. The detection of galactomannan antigen has been investigated. The serum galactomannan (GM) antigen has been recognized to be a useful tool for the diagnosis

of invasive pulmonary aspergillosis. Several studies have evaluated the Platelia assay in detecting bronchealveolar larvage (BAL) GM in adult patient populations and reported sensitivities ranging from 60% to 100% and specificities from 87.8% to 100% using a cut-off index of >1.0. Bergeron et al. reported a sensitivity and a specificity of 57.6% and 95.6% respectively when using a cut-off index of BALF GM > 0.5. Endobronchial ultrasonography (EBUS), a newly introduced technique, has been applied to the assessment of peripheral lung lesions. Compared with conventional bronchoscopy, EBUS offers the benefits of visualizing the parabronchial structure, confirming the precise location of peripheral lung lesions and therefore improving the diagnostic yield. BAL GM obtained in the above studies is usually from conventional bronchoscopy and the role of bronchoscopy with the aid of EBUS in the diagnosis of invasive pulmonary aspergillosis is still no reported. The primary aim of this study was to establish the diagnostic value of Aspergillus galactomannan antigen assay from endobronchial ultrasonography (EBUS) guided bronchial wash fluid for diagnosis of IPA.

Methods: The diagnostic yields of EBUS for patients with suspicion of IPA between December 2012 and December 2017 were retrospectively analyzed.

Results: A total of 106 patients with suspicion of IPA were enrolled in the study. The mean age was 52.9±17.1 years old and the most underlying disease was hematological malignancy (n=36, 34%). Among these patients, 29 patients were diagnosed as proven aspergillosis and 6 patients as probable of IPA infection. At a cut-off index value of 0.5, GM detection in BW fluid had a sensitivity of 97.14% and specificity of 78.57%. PPV and NPV were 69.39% and 98.21%. Applying a cut-off index of 1.0 as is proposed in adults resulted in sensitivity, specificity, PPV and NPV of respectively 96.97%, 95.89%, 91.43% and 98.59%.

Conclusion: Aspergillus GM antigen assay from EBUS guided BW fluid is a useful diagnostic tool for pulmonary aspergillosis. It offered a high sensitivity, specificity, positive predictive value and negative predictive value at a cut-off index value of 1.0. This technique can be particular helpful in immunocompromised patients who suspicion of pulmonary aspergillosis to avoid delay treatment.

PO-148

Using endobronchial ultrasonography with a guide sheath under bronchoscope for diagnosis of peripheral lung lesions

Zou,Chenxi、Yang,Zhen、Chen,Liangan、Zhu,Qiang、Xu,Yi

Chinese PLA General Hospital

Objective: To retrospectively analyze the clinical value of endobronchial ultrasonography with a guide sheath under bronchoscope for diagnosis of peripheral lung lesions using.

Methods: Clinical data of the patients with peripheral lung lesions who underwent endobronchial ultrasonography with a guide sheath examination in the Center of Interventional Pulmonology of Chinese PLA General Hospital was collected from March 2016 to September 2019. Clinical feasibility and safety were evaluated using both electronic bronchoscope and small ultrasound probe were used to locate the lesion for biopsy.

Results: A total of 46 patients (46 lesions) were included,there were 26 males and 20 females, with an average age of 54.3 years (range 28-81 years). The mean size of the biopsy lesion was 35.2 ± 15.6mm. 11 lesions located in left upper，8 lesions in right upper，6 lesions in middle bronchus and 22 lesions in other. 42 patients received virtual navigation combined with EBUS-GS. These lesions between grade 5 and grade 9 and EBUS-GS can reach or discover. 32 lesions were reached successfully by small ultrasound probe and 21 cases get definite diagnosis by pathologic examination of tissue biopsied by. The factors associated with successful biopsy were the relationship between bronchus and lesions ($p < 0.05$), the bronchial grade ($p<0.05$), and the size of lesions ($p<0.05$); the lesion size ($p<0.05$) and the

relationship between bronchus and the lesions ($p<0.05$), are the factors associated with diagnosis rate significantly. Furthermore, no severe complications such as hemoptysis, pneumothorax and severe occurred during and 3 days after procedure.

Conclusion: EBUS-GS is a can locate as far as grade 9 bronchus with few complications and high safety, which is of great clinical value for the biopsy of peripheral lung lesions.

PO-149

Case presentation and literature view: The pleuroscopic finding in a patient with Meigs' syndrome

Kuo,Tzu-Yu1、Tsai,Ying-Ming2、Cheng,Chih-Hung2
1. Kaohsiung municipal Siaogang hospital
2. Kaohsiung Medical University Hospital

Objective: The pleuroscopy is the method of choice to investigate undiagnosed exudative pleural effusions. Flexi-rigid pleuroscopy is performed on patient with local anesthesia under the aid of conscious sedation with estimated complication rate around 1-5%. Meigs' syndrome is known as a triad of an ovarian fibroma, pleural effusion and ascites; it attracted widespread attention in 1937 due to the report of Joe Vincent Meigs . It has been few reports about the pleural finding in Meigs' syndrome. Here, we presented a 29-year-old woman with progressive dry cough and dyspnea on exertion due to massive pleural effusion. The patient was eventually diagnosed as Meigs' syndrome. Through pleuroscopy, we disclosure the finding in pleura.

Methods: A 29-year-old woman presented to our clinic for her right-side recurrent effusion. She was diagnosed as pulmonary tuberculosis (TB) 2 years ago with a complete course of treatment. For fear of TB recurrence, she was advised to have pleural biopsy for tissue TB culture. Chest computed tomography (CT) only showed right-side pleural effusion and ascites. Neither fibrinous adhesion nor organized fibrin was identified during pleuroscopy. Patient then received a series of study including CA125 and gynecological sonography; the sonography disclosed right-adnexa mass(Figure 1), and lab data showed high CA-125. Right ovarian tumor was noted during exploratory laparotomy, and the frozen section showed benign fibroma.

Results: The surface of pleura was relative smooth except some equivocal polyp, and the biopsy did not suggest TB infection. The pleural effusion showed exudative in character. Either the pleural effusion and ascites resolved after oophorectomy. She then was diagnosed as Meigs' syndrome.

Conclusion: Meigs' syndrome is not common at all, but the tumor is usually benign. Meigs' syndrome accounts for about 1% of ovarian tumors, and ovarian fibroma are found in 2–5% of surgically removed ovarian tumors. Ten to fifteen percent of women with ovarian fibroma have ascites, and 1% has hydrothorax. The predilection of pleural effusion in ovary fibroma are right sided (more than 70%), with 15% in left side and 15% in both sides . The treatment of choice for patients with Meigs' syndrome is tumor removal. The result of surgical removal of oophorectomy leads to resolution of either pleural effusion or/and ascites.

PO-150

Radial probe endobronchial ultrasound (EBUS) in diagnosing atypical pulmonary infection

Tseng,Ying-Ying、Chen,Chia-Hung、Tu,Chih-Yen、Liao,Wei-Chih、Wu,Biing-Ru、Cheng,Wen-Chien、Hsu,Wu-Huei
China medical university hospital, Taichung, Taiwan

Objective: Background: The development of a pulmonary infiltrate and/or nodule may represent a particularly ominous sign and remain a diagnostic challenge even immunocompromised or immunocompetent patients. Although diagnostic techniques continue to improve, accurate diagnosis of unknown radiologic pulmonary infiltration is still difficult. Several diseases may present with a pulmonary infiltrate and mimic bacterial pneumonia. A delay in resolution of the pulmonary infiltrate or a lack of response to initial antibiotic treatment should trigger consideration of an atypical pathogen infection, such as Mycobacterium tuberculosis, fungus, or virus. The use of empiric antibiotic therapy can lead to increased mortality and cost. Bronchoscopy examination with a smear and culture of the bronchoalveolar lavage fluid (BALF) has been successful in establishing the diagnosis of pulmonary infection. Unfortunately, most invasive pulmonary infections, such as fungal infections, must rely on histology for diagnosis. Radial probe endobronchial ultrasonography (EBUS), a newly-introduced technique, has been utilized to assess peripheral pulmonary lesions and to identify parenchymal lung lesions for biopsy. EBUS offers the benefits of visualizing the parabronchial structure, confirming the precise location of peripheral lung lesions, and improving the diagnostic yield of lung cancer. Currently, no studies focus on the role of EBUS as a diagnostic tool in the diagnosis of non-bacterial pneumonia. Therefore, a retrospective study was performed to ascertain the value of EBUS in assisting the diagnosis and management of patients with atypical pneumonia.

Methods: A retrospective collection and review of data from patients who underwent bronchoscopy with EBUS at the China Medical University Hospital (a 2100-bed tertiary care, university-affiliated hospital) in Taiwan between December 2014 and December 2017 was performed.

Results: During the study period, 78 patients (54 males and 24 females) with a mean age of 60.2 years ± 17.5 years (range, 24-87 years) developed non-bacterial pneumonia. Most patients (n=57, 72.8%) had chronic underlying diseases or associated medical conditions; the most common concomitant conditions were diabetes mellitus (33.8%) and malignancy (15.6%). A total of 78 organisms were isolated or identified by histopathology, including M. tuberculosis (n=59), Aspergillus (n=8), Cryptococcus (n=6), Pneumocystis jiroveci (n=3), and mucormycosis (n=2) Of the 59 patients eventually proven to be infected with M. tuberculosis, EBUS-guided smears were positive in 11 patients; cultures were positive in 46 patients; and tissue specimens were positively identified in 29 patients. Moreover, for the 13 patients eventually diagnosed with fungal infections, none of the EBUS-guided smears or cultures were positive. All 13 of these patients with fungal pneumonia were diagnosed based on EBUS-guided TBB. EBUS was considered helpful in making the diagnosis in 64 (82.1%) of 78 patients. The diagnostic rates of EBUS for the various pathogens responsible for atypical pneumonia were 86.4% for M. tuberculosis, 87.5% for Aspergillus, 100% for mucormycosis, 100% for Pneumocystis jiroveci, and 16.7% for Cryptococcal disease. As shown in Table 3, EBUS was considered helpful in assisting the diagnosis in 63 (80.8%) of 78 patients. EBUS examinations provided a definitive diagnosis in 49 patients (62.9%) and changed the diagnosis in 14 patients (17.9%). However, 15 patients received no diagnostic benefit from EBUS examinations, including 9 patients with M. tuberculosis, 1 patient with Aspergillosis, and 5 patients with Cryptococcal disease. The most common diagnostic methods used to confirm the diagnosis in these 15 patients were surgical intervention (n=7) and CT-guided biopsy (n=4). The EBUS examinations helped manage 61 (78.2%) of 78 patients, including making new decisions for 14 patients and confirming current management in 47 patients. EBUS examinations were not beneficial for 17 patients, including 9 patients with M. tuberculosis, 5 patients with Cryptococcal disease, 2 patients with Aspergillosis, and one patient with Pneumocystis jiroveci (n=1). Patients with Pneumocystis jiroveci received the most benefit from EBUS-guided examinations, while patients with M. tuberculosis received the least benefit from the examinations.

Conclusion: Bronchoscopy with EBUS is a useful diagnostic tool for atypical pneumonia. This technique can be particular helpful in critically ill patients who cannot tolerate surgical intervention.

PO-151

Novel technique of performing Transbronchial lung Cryobiopsy (TBLC) for diagnosing DPLD in infant - First case reported in the world

Kavanakudiyil,Tinku Joseph、Kochucheruroor,Sreeraj Nair、Nambiar,Ajit
Amrita Institute of Medical Sciences & Research center, Kochi, Kerala, India

Objective: Transbronchial lung cryobiopsy (TBLC) was introduced into clinical practice has recently been recognized as a safe and effective tool to diagnose diffuse parenchymal lung diseases. However its role in diagnosing pediatric ILDs is not explained much in literatures. The objective of our study was to perform TBLC in an infant using a novel technique inorder to obtain the cause of DPLD.

Methods: 11 month old male infant with past history of multiple hospitalizations for pneumonia, presented with cough and breathlessness. Lab investigations showed neutrophilic leukocytosis. CT chest revealed bilateral diffuse ground glass opacities with consolidatory patches. Sweat chloride test was negative for cystic fibrosis. He was subjected for bronchoscopy and BAL. BAL cytology showed lymphocytic inflammation, with negative cultures and PAS stain. In view of inconclusive diagnosis under fluoroscopic guidance, transbronchial lung cryobiopsy was performed using a novel technique in which 1.9mm flexible cryoprobe was passed through the working channel of rigid bronchoscope (5.5mm) under fluoroscopic guidance into left lower lobe segments. To obtain post procedural haemostasis 2F fogarty balloon was kept in the adjacent segment with the help of ultrathin neonatal flexible bronchoscope. Multiple cryobiopsies (3 bits) were taken from left basal segments.

Results: There was no immediate post procedure complications and the child was safely extubated post procedure. Histopathological examination of TBLC tissues showed lamellated concretions in alveolar lumina suggestive of alveolar microlithiasis. Later on the histopathology results were supported with the evidence of submutation of the SLC34A2 gene in child blood sample. The novel technique used by us helped to perform Transbronchial lung Cryobiopsy for diagnosing etiology of DPLD in an infant for the first time in the world. The main limitation of TBLC in children is difficulty in application.

Conclusion: Transbronchial lung cryobiopsy is a valuable and safe technique and holds promise to become the preferred, first line approach to lung biopsy in the diagnostic approach to the children suffering from DPLD. The novel technique which we employed to perform Cryobiopsy is safe method which can be used to obtain tissue diagnosis in both infant/ pediatric DPLD patients.

PO-152

The application of TBLB combined with brush biopsy and ROSE in the diagnosis of peripheral lung lesions

Xie,Lihua、Dai ,Yingbin、Zhang,Li、Liu,Caihong、Liu,Jianming、Sun,Shenghua、谢丽华
Lihua Xie

Objective: In the undeveloped regions and countries，it is difficult to dignose the peripheral pulmonary nodules without endobronchial ultrasound.We aimed to find a simple and feasiber way to sovle this issue.To evaluate the diagnostic value of transbronchial lung biopsy (TBLB) combined with brush biopsy and rapid on-site evaluation (ROSE) in peripheral pulmonary nodules or mass.

Methods: The clinical data of patients who was found Lung nodules or masses on chest and underwent TBLB combined with brush or ROSE in the Third Xiangya Hospital of Central South University from April 20, 2018 to August 21, 2019 were retrospectively reviewed.The clinical data included gender,CT,lung function and pathology results etc. The patients were divided into two groups： Bush biopsy +TBLB group,which under bush biopsy combined with blind TBLB； Bush biopsy+ROSE+TBLB group,who under TBLB after brush biopsy + ROSE showed positive pathological cells. The diagnostic positive rate of two groups were analyzed and compared.

Results: A total of 85 patients were collected.There were no significant differences in gender, size of peripheral pulmonary nodules or mass, and pathological type composition ratio between the two groups of patients. The overall diagnostic positive rate of TBLB was 63.53%(54/85). The diagnostic positive rate of the TBLB + brush biopsy, the TBLB combined brush biopsy and ROSE group was 51.28% (20/39) ,73.91% (34/46), respectively. The diagnostic positive rate of the bush biopsy +ROSE+TBLB group was significantly higher than bush biopsy +TBLB group ($\chi 2$=4.665, P=0.031). All patients were well tolerated without severe complications such as active bleeding and pneumothorax after biopsy. ROSE is in good agreement with the final pathology.

Conclusion: The combination of TBLB,bush biopsy and ROSE which are common bronchoscopy techniques can greatly improve the positive diagnosis rate of patients with peripheral pulmonary lesions. The examination cost is low and has no serious complications. It is worth to promote in undeveloped regions and countries without endobronchial ultrasound.

PO-153

Initial experience in combined Cone-Beam CT (CBCT) and Veran Electromagnetic Navigation Bronchoscopy (ENB) in pulmonary nodule diagnosis

Browning,Robert1、Keung,Jonathon1、De Ruiter,Quirina2、Fontana,Joseph2、Baarson,Chad 1、Luca,Michael 1、Collins,Jeanette1、Karanian,John 2、Pritchard,William2、Wood,Bradford2、Mckay,Sean1
1. Walter Reed National Military Medical Center
2. National Institutes of Health

Objective: Background Bronchoscopic biopsy of peripheral lung nodules using electromagnetic navigation bronchoscopy (ENB) systems have inherent limitations in that the virtual image often diverges from the actual location of the target nodule due to intra-procedural changes in lung volume due to atelectasis and/or bleeding, as well as lung deformation from the bronchoscope and devices. Cone-beam Computerized Tomography (CBCT) bronchoscopy provides 3-dimensional confirmation of biopsy instrument location. However, given its static nature, CBCT is limited during precision biopsy movement Fluoroscopy is most often used to guide instrument advancement and positioning. The VeranSPiN Thoracic Navigation SystemTM (ENB) system tracks biopsy devices and provides virtual image-guidance for the navigation and biopsy. Adding CBCT overlays to the VeranENB is a new technique that allows for a

non-radiation based navigation for the dynamic portions of the procedure to be combined with the static CBCT image for confirmation of instrument position and to update and refine target location.

Methods: Case Report We report our initial experience with the first 5 cases of ENB-CBCT using the Veran ENB system in our institution with tip-tracked instruments to biopsy pulmonary nodules with CBCT images integrated into the virtual guidance of the ENB system. Patients included 2 males and 3 females with ages ranging from 34 to 86 years old. All patients underwent general anesthesia and were paralyzed for the procedure. Lung nodules targeted included mixed and solid nodules with largest dimensions 9 – 20 mm (average 12 mm). In two cases, lesions were directly adjacent to pleural fissures. CBCT was performed at least once in all cases and uploaded to the ENB for an integrated overlay. All biopsies and navigation were performed using the ENB system.

Results: Specific diagnosis of the nodules included lung adenocarcinoma (2), squamous cell carcinoma, renal cell carcinoma and one benign reactive. There were no complications.

Conclusion: Our initial experience has been favorable but limited. The CBCT overlay allowed for real time confirmation and documentation of biopsy location as well as increased confidence in the virtual guidance during biopsy. CBCT with fluoroscopy and augmented fluoroscopy has previously been shown to be effective in lung nodule biopsy and diagnosis, but it still requires radiation in addition to the CBCT and specialized software for the augmented fluoroscopy. CBCT with "augmented" ENB using the Veran system provides an alternative non radiation based method for navigation and biopsy for lung nodules in challenging locations.

PO-154

Foreign body aspiration in children: diversity of presentation and challenges of it's management by flexible bronchoscope

Tahura,Sarabon
Bangladesh Institute of Child Health(BICH), Dhaka Shishu (Children) Hospital

Objective: Foreign body (FB) aspiration is a common occurrence in children. However, it is acute emergency and sometimes causes death, also notorious for its delayed or subtle presentation. Again, it is not always diagnosed (especially in radiolucent FB) due to non-specific symptoms of varying severity, can masquerade as myriad entities, from bronchial asthma to persistent/recurrent pneumonia and bronchiectasis, causing diagnostic and therapeutic challenges. This study emphasises the importance of considering airway foreign body as a cause of acute and chronic respiratory symptoms in children and outline the clinical evidences of the utility and feasibility of flexible bronchoscopy for management of airway FB in children.

Methods: This prospective study was performed on children (aged 6 months to 16 year) having acute or recurrent or long standing, non-resolving or partially resolving respiratory complaints who underwent Flexible Bronchoscopy for suspected FB from July 2018 to october 2019 in a tertiary care hospital in Bangladesh. History, clinical, radiological, bronchoscopic findings and immediate effect after bronchoscopy were analysed.

Results: Among total 32 children, only 25% (n=8) had definite history of FB aspiration. The most frequent symptom was paroxysmal cough (72.7%) followed by wheezing, stridor and recurrent and persistent pneumonia. FB was found in 47% (n=15) children and removed successfully by Dormia Busket in 9 children, 4 by rat-tooth forceps and 2 by cryo probe. The most common (n=7) FB was peanut. Others are pin, metallic clip, plastic bead of Taasbih, Filament of pencil torch light, custard apple seed, pea pulse, plastic safety ware joint and plastic toy whistle. Thick mucus plugs were found in four children. Respiratory symptoms improved after removal of foreign bodies in all cases. During procedure, transient hypoxia developed in 3 children which was alleviated by temporary cessation of the procedure.

Conclusion: Possibility of FB aspiration should be considered in any child who present with acute severe or

persistent/recurrent respiratory symptoms. Flexible Bronchoscopy documented a crucial diagnostic and safe therapeutic tool for airway foreign body management in pediatric age group.

PO-155

Broncho dx device performance in radial EBUS positive SPNs

Votruba,Jiri、Bruha ,Tomas 、Sedliak,Marek
1 st chest clinic

Objective: Solitary pulmonary nodules are increasingly encountered in current pulmonary medicine. There are interesting new technologies available to diagnose those difficult pathologies like endobronchial navigation techniques and transparietal CT guided biopsy. In order to increase diagnostic yield of those techniques precise biopsy instruments are needed.). Light scattering and absorption can provide information about tissue structure and chromophore content; these are features that can be used to distinguish between normal tissues, malignant lesions, and other pathologies. Therefore NIR light penetrating normal lung parenchyma will have different spectral and intensity characteristics than will the light from the same source when penetrating a solitary pulmonary nodule.

Methods: We have had the possibility to evaluate new diagnostic instrument Broncho dx based on near infrared penetrating spectroscopy (patent pending). We performed 40 consecutive examinations of SPN (diameter 1-3cm) using fluoroscopy and radial EBUS in order to navigate to the lesion in 38 patients . Guided sheath catheter technique was invariably used. In the case of SPN visualisation both concentric and excentric Bronchodx catheter has been introduced into the guide sheath. Positive and negative readings of Bronchodx were recorded as well as cytology and histology results.

Results: Concentric or excentric visualisation of the SPN by rEBUS was possible in 34 from 40 cases. There were 23 conclusively diagnostic morphologies from 25 centrally visualized nodules and 4 conclusively diagnostic morphologies from 9 excentrically visualized nodules. (overall sensitivity was 79 %, while 44 % for excentric and 92 % for concentric visualisation). Bronchodx results were positive in all 23 cases of concentric rEBUS visualization and in 5 cases of excentric rEBUS visualization. (overall sensitivity was 82%, while 55 % for excentric and 92% for concentric visualisation) Interestingly in cases of excentric visualisation on rEBUS and Bronchodx positivity there were positive morphology findings in 4 from 5 measurements.

Conclusion: Bronchodx appears be as good confirmatory method as rEBUS in the diagnosis of SPNs. More extensive studies are needed to prove diagnostic potency of this device.

PO-156

clinical analysis on respiratory endoscopy intervention therapy in 9 patients with benign central airway stenosis

wu,yufeng、Zhang,Guoliang、Xie,Shuanshuan
Shanghai Tenth people's hospital

Objective: Benign central airway stenosis refers to the narrowing of the airways caused by various benign lesions of the trachea, left and right main bronchi, and right middle bronchus, which can cause patients to have different degrees of dyspnea or even suffocation. Transbronchoscopic interventional therapy has less trauma, lower requirements for patients' cardiopulmonary function, and avoids the pain and higher risks caused by surgical operations. It has become one of the main treatment methods for benign central airway stenosis. To summarize and analyze application value of respiratory endoscopy intervention therapy for benign central airway stenosis.

Methods: The clinical manifestations, imaging and bronchoscope characteristics, pathological types, bronchoscopic interventional methods and outcomes of 9 patients with benign central airway stenosis admitted in our hospital were summarized and analyzed.

Results: The course of this group of patients is from 1 week to 4 years. The ratio of male and female was 2:1. The pathological types were: 2 cases of traumatic airway stenosis (22.2%), 1 case of bronchial fibroma (11.1%), 1 case of bronchial lipoma(11.1%), and 1 case of fibrous epithelial polyps with squamous metaplasia (11.1%) 1 case (11.1%) oftracheobroncheopathia osteochondroplastica, 2 case of pulmonary amyloidosis (22.2%), 1 case of tuberculosis (11.1%). Of the 9 patients, 3 had balloon dilation, 4 had laser treatment, 1 had freeze-thaw, and 1 had argon plasma coagulation. All cases were treated with cryotherapy in combination with the wound. The airway was completely open and released after surgery. The airway obstructions reached the full effective standard. Granulation tissue formation was observed in 2 cases, and 2 surgical removals were performed. No severe complication such as major hemorrhage , bronchial wall perforation , pulmonary atelectasis caused by dropped necrosis occurred during and after operation.

Conclusion: Respiratory endoscopic interventional therapy for benign central airway stenosis is effective, with less trauma, fewer complications, and well tolerated by patients.

PO-157

APPLICATION OF SOFTWARE TO EVALUATE STENT FIT FOR PATIENT-SPECIFIC AIRWAY STENTS

Gildea,Thomas、Baiera,Adrianna
Cleveland Clinic

Objective: Currently, there are no studies available defining the best way to size airway stents. The literature that does exist lacks quantitative measures and the correlation of clinical efficacy but does remark on the value of a better fitting stent reducing some complications associated with airway stenting. The purpose of this study was to evaluate a software-based visual assessment of stent fit for patient-specific airway stents and determine if there were any clinical correlates. A total of nine patient-specific airway stents were implanted over 3 years in a patient with a long-standing history of granulomatosis with polyangiitis (Wegner's), whom had required bilateral stents for the multifocal airway disease. Understanding stent fit and its clinical effect could be used as a tool to help inform clinical decisions about stent sizing.

Methods: A retrospective review of a patient implanted with nine patient-specific airway stents over 3 years (5 left main stem and 4 right main stem) was conducted by comparing the prescribed stent to the CT airway model from which the stent prescription was designed using the Visionair Stent Architect proprietary software. A novel method

of describing stent fit using visual (heat map) and dimensional ascertainment was performed and correlated with the radiographic and clinical course in one patient.

Results: Although the patient-specific stents did not exhibit a specific pattern of fit, the stents were capable of treating the airway with a more durable response than seen with other airway stents and stent free periods. A notable reduction of wall thickness and lumen patency was associated with the patient-specific airway stents, as observed on the CT images (figure1). The observed changes in the airway allowed proceeding patient-specific stent designs to increase in diameter while maintaining good clinical effect.

Conclusion: Based on the results of this study, the patient-specific airway stent may not only be used as a sufficient treatment for airway patency but also used as a correctional treatment over time to re-shape a patient' s airway anatomy. Additionally, the use of software applications to define stent fit may have some value in either predicting or describing best fit for airway stents.

PO-158

Incidence of Pneumothorax recurrence after re-implantation of valves following their explantation by prolonged air leak after endoscopic valve placement

Eberhardt,Ralf1,3、Derossi,Susanne1、Hoffmann,Hans2、Gompelmann,Daniela 1,3、Heussel,Claus-Peter1,3、Herth,Felix JF1,3
1. Thoraxklinik at the University Heidelberg
2. Klinikum rechts der Isar Technische Universität M ü nchen
3. Translational Research Center (TLRC) Heidelberg, German Center for Lung Research (DZL)

Objective: Endoscopic valve placement is an etsablished treatment option in patients with severe lung emphysema nowadays. The most common complication after valve placement for endoscopic lung volume reduction (ELVR) is a postinterventional pneumothorax (PTx), currently the risk being estimated between 20 – 25 %. In cases with prolonged air leak valve removal may be necessary. After recovering, reinsertion of valves for ELVR is possible. The aim of this study was to investigate the rate of re-PTx after re-implantation of the valves.

Methods: All patients with PTx and chest tube draining after ELVR between 2010 and 2018 in our hospital were retrospectively analyzed (N = 116). The rate of valve explantation (N = 60) and re-implantation (N = 31) was evaluated and pulmonary function (FEV1 and RV), 6-minute walk test (6-MWT) and dyspnoe score (mMRC) before and 90 days after intervention were assessed. Outcomes between the patients without valve re-implantation (N = 29), those with re-implantation but without PTx (N = 31) and those with recurrent PTx after valve re-implantation (N = 9) were compared.

Results: 51.7 % (60 of 116) of patients with post interventional PTx after ELVR required valve removal due to prolonged air leak. 51.6 % (31 of 60) of these patients underwent a re-implantation of valves a few months later and 29 % of them suffered from a recurrent PTx. However, the group of patients with re-implantation of valves improved significantly in FEV1 (+ 0.12 l ± 0.20 l) and in mMRC (- 1,0 points) mMRC in the 90 days follow up compared to baseline ($p<0.05$), whereas differences in RV and 6-MWT didn´t reached statistical significance.

Conclusion: Compared to the risk of PTx after valve implantation, it seems that the risk of a new PTx development after valve re-implantation is with 29 % only moderately higher. However patients may benefit from replacement in lung function, exercising and dyspnea. Further elucidation of possible PTx predictors and also protectors is anticipated.

PO-159

2 cases of bronchial artery malformation

Zhang,Yixiang、Zeng,Yiming、Liu,Dexin、Chen,Xiaoyang、Zhang,Huaping、Yang,Dongyong
2nd Affiliated Hospital of Fujian Medical University

Objective: To increase physicians' understanding of bronchial artery malformation as one of the causes of hemoptysis and the role of interventional pulmonary.

Methods: Two cases of hemotysis were confirmed bronchial artery malformation by bronchial arteriography. the two cases were differential from tuberculosis, lung cancer, cardiovascular diseases etc. Two cases were also found abnormalities by bronchoscope and were treated by interventional therapy. One patient was a 49 years old woman who was cough with blood about 5 years. In 5 years she was treated by antibiotics and hemostatics, but hemoptysis was recurrent.This time hemoptysis recurred. there was not found any abnormal by physical examination and CT scan. And there was not abnormal about ANCA. During bronchial arteriography, there was found bronchial artery malformation, and some of them were arteriovenous malformation. By brochoscope, we discovered there was abnormally dilated vessel in the submucosa. The other patient was a 38 years old man who repeated cough and hemoptysis for 2 years. In 2 years he was always diagnosed bronchiectasis with infection, and treated by antibiotics and hemostatics, but hemoptysis recurred. During this period, he also treated by bronchial artery embolism, but this time(5 hours ago) hemoptysis recurred. this time we did not found any abnormal physical examination and the thorax CT scan. and we also checked there was any microbe in the sputum. meanwhile there was not any abnormal about immunology. We checked bronchoscope and found there was an abnormal bulge at the right middle lobe and bronchial artery malformation.

Results: One was found abnormally dilated vessel in the submucosa of the trachea and was treated by cryotheray. The other was found submucosal bulge at right middle lobe and was confirmed Dieulafoy's disease and was treated by bronchial artery embolism.

Conclusion: Bronchial artery malformation is one of the causes of cryptogenic hemoptysis. interventional therapy is an effective treatment.

PO-160

Bronchoscopy with transbronchial biopsy shortens the time to treatment in pulmonary tuberculosis

Kuo,Tzu-Yu
Kaohsiung Municipal Siaogang Hospital

Objective: Pulmonary tuberculosis (TB) still bears a high global burden and carries intermediate to high incident rates in Asia. The sputum specimens, obtained by spontaneous cough, cannot always provide definite evidence of pulmonary TB infection, and bronchoscopy with bronchoalveolar lavage with or without transbronchial biopsy might play an important role in pulmonary TB diagnosis. However, there is still an unmet need in delaying diagnosing TB. For the early diagnosis of TB, we hypothesize that bronchoscopy-aid lung biopsy shortens to pulmonary TB treatment.

Methods: We retrospectively enrolled patients who had a bronchoscopy and then staring anti-TB treatment according to specimens obtained by the bronchoscopy from August 2018 to July 2019. We excluded those who had pulmonary TB diagnosis & treatment according to sputum specimens and those who already had pulmonary TB diagnosis. We used Mann-Whitney U Test and Chi-square test to find out factors that shorten the time interval between the bronchoscopy to start the anti-TB treatment.

Results: A total of 50 pulmonary TB patients were identified according to the inclusion and exclusion criteria for further analysis. The 50 patients, 70% of whom were male, had 59.5 years old of median age (interquartile range =

28.75). 58% of total patients had bronchoscopy with transbronchial biopsy and had 7 days of the median time interval between the bronchoscopy to start the anti-TB treatment (interquartile range = 15.25). Compared with those who without biopsy during bronchoscopy, patients with transbronchial biopsy had a significantly higher rate of starting anti-TB treatment within 8 days (Pearson Chi-square test, P = 0.015) after the bronchoscopy. In 21 patients who are negative for PCR from BAL, 14.29% of them had positive pathology finding for TB from the transbronchial biopsy specimens. Besides, in these 21 patients, significantly shorter treatment interval after the bronchoscopy was noted in patients who had positive pathology finding for TB (Mann-Whitney U Test, median = 8.0 vs 20.0, P = 0.048).

Conclusion: This retrospective study identified the significantly shorter time interval from the bronchoscopy to initiate anti-TB treatment in patients who were positive for the PCR test from BAL. The patients with bronchoscopy biopsy had a significantly higher rate of starting anti-TB treatment within 8 days. Further study should be conducted to confirm the efficacy of routinely performing bronchoscopy biopsy in pulmonary TB diagnosis.

PO-161

DIAGNOSTIC YIELD AND SAFETY OF TRANSBRONCHIAL LUNG CRYOBIOPSY IN DIFFUSE PARENCHYMAL LUNG DISEASES

Kavanakudiyil,Tinku Joseph、Perathur,Arvind、Kochucheruroor,Sreeraj Nair、Nambiar,Ajit
Amrita Institute of Medical Sciences & Research center, Kochi, Kerala, India

Objective: Work up of Diffuse Parenchymal Lung Disease(DPLD). has always befuddled clinicians. Transbronchial Lung Cryobiopsy(TBLC) has recently been recognized as a safe and effective tool hence found a spot in the diagnostic algorithm of DPLD.Evaluate the diagnostic yield of TBLC and its complication rate in our cohort

Methods: All patients that underwent TBLC at Interventional Pulmonology unit of Amrita Institute of Medical Sciences, Kochi between February 2018 and August 2019 were reviewed. TLC was performed under general anesthesia, via rigid bronchoscope. Biopsies performed with flexible cryoprobes (Diameter of 1.9 mm or 2.4 mm), introduced through a flexible scope

Results: Out of 102 patients definitive diagnosis was obtained in 95 (diagnostic yield- 93.13%)Specimens were not adequate in five cases. Multi disciplinary team finalized the diagnosis as : Chronic Hypersensitivity pneumonitis (35), NSIP(15),UIP (10), Sarcoidosis (10), Organizing Pneumonia (5), Adenocarcinoma (5), Eosinophilic pneumonia (1), Alveolar Microlithiasis (2), Pulmonary Haemosiderosis (1), Chronic GVHD (2), Pulmonary TB (1), RA-ILD (2), Lipoid Pneumonia (1), Viral Pneumonia (3) and (2) resolving infectious process. The final diagnosis of etiology of diffuse interstitial lung disease was made after discussing all cases in a multidisciplinary team meeting that involves pulmonologists, radiologists and pathologists. Close collaboration between these different areas of expertise is required to define which patients will need a biopsy and those in whom biopsy is not necessary to reach a final diagnosis. Minor bleeding was the most common complication 22%, major bleeding 5% and 8% had pneumothorax. Significant bleeding was managed with the help of 5F Fogarty-balloon tamponade, cold saline & adrenaline. Blood transfusion was needed in one of the patient who had a major bleed associated with TBLC.

Conclusion: TBLC, together with the clinic-radiological features, is valuable and safe technique in diagnosis of DPLD. TBLC might, therefore, be considered first diagnostic approach for obtaining tissue diagnosis in ILDs, reserving surgical approach for cases where TBLC is non-diagnostic.

PO-162

Sequential non-surgical therapies for refractory pneumothorax

Shi,Zhihui、Zhou,Rui
The Second Xiangya Hospital, Central South University

Objective: Spontaneous pneumothorax is a common emergency. Currently two main regimens including surgical and non-surgical, including percutaneous needle aspiration, thoracic drain, video-assisted surgery and open thoracotomy, could be selected for pneumothorax treatment. Closed drainage is a non-surgical therapeutic method supposed to be safe as first-line therapy for pneumothorax. Pneumothorax that remains leaky longer than two weeks after closed drainage has been defined as "refractory pneumothorax". According to previous agreement, patients of refractory pneumothorax, should be arrange to subsequent surgery. However, there is no optimal treatment for such patients with surgical contradiction. A simple screening procedure has been established to assist grouping of these patients for following treatments.

Methods: A screening procedure grouped patients of spontaneous pneumothorax into 3 categories due to their responses to closed drainage. In this case, closed drainage has been considered as an conservative "first choice". If lung recruitment was successful without further intervention, patients would be treated by pleurodesis using autologous blood through chest tube. If lung recruitment failed after a period of closed drainage, evaluation on the overall situation of the patients would be carried out according to whether they were tolerable to bronchoscopy or not. The former ones received detection by balloon for "leaky site" and then occlusion. For the remaining patients, more invasive operation was performed. Finally, success rates have been calculated.

Results: In 35 cases of successful pulmonary recruitment, pleurodesis by autologous blood were performed. In 8 cases of failed lung recruitment after negative pressure drainage, balloon intervention were performed under bronchoscope. The rest 13 cases were given pleural adhesion release combined with pleurodesis by talc through thoracoscopy. The success rate of these groups were respectively 70%, 100% and 78%.

Conclusion: Therapeutic responses after closed drainage can be applied as selective criteria for subsequent treatment methods. Non-surgical sequential interventions were practical and effective among refractory pneumothorax.

PO-163

Safety and feasibility study of bronchoscopic cryobiopsy under conscious sedation and local anaesthesia without fluoroscopy guidance

Guliani,Abhinav、Nawani,Sumeet、Ghosh,Shuvranu、Basu,Arup、Dhamija,Amit
Sir Ganga Ram Hospital, New Delhi, India

Objective: Conventionally lung biopsies have been performed either surgically or transbronchially using bronchoscope. Surgical biopsy requires hospitalization, surgery, general anaesthesia and mandates ICD post procedure. Many studies have proven the worth of CryoTBB, but most studies highlight use of GA, fluoroscopy and some have also used a fogarty catheter or a bronchoflex tube because of fear of major risk of bleeding. We planned to study the safety and efficacy of cryo TBLB done in bronchoscopy suite using local anaesthesia and moderate sedation without fluoroscopic guidance.

Methods: Patients with either diffuse or focal parenchymal lesions requiring lung biopsy were enrolled. Patients with either diffuse or focal parenchymal lesions requiring lung biopsy were enrolled between April 2015 till November2019. Clinical and radiological data were recorded. Cryoprobe guided transbronchial lung biopsy was

performed in bronchoscopy suite under sedation and local anaesthesia with recording of procedure details. The method to perform biopsy will be described in detail with video as well. Fluoroscopy was not used (as it was not available) and radial probe EBUS was used to localize focal lung lesions where required. Note was made of complications such as bleeding, pneumothorax and respiratory failure. Biopsy was sent for histopathological examination. Diagnostic yield was calculated.

Results: 93 patients were enrolled with 53(57%) males and 40(43%) females. Age was 51.47 ±13.74 (Mean ± SD) years. Median biopsy size was 16 sq.mm (Range: 1- 225 sq.mm). Bleeding was most common complication observed in 39 patients but mostly mild, resolving spontaneously. Pneumothorax occurred in 5 (5.4%) patients. Yield was 82.8%. ILD and granulomatous inflammation were major diffuse lesions and malignancy was commonest focal lesion.

Conclusion: Cryoprobe TBLB is a safe and efficacious method of lung biopsy with good yield and acceptable complication rate and can be performed safely in bronchoscopy room without general anaesthesia and routine use of fluoroscopy is not warranted for DPLDs.

PO-164

A case of malignant pleural mesothelioma treated through medical thoracoscopy with snare ligation

Yao,Zhouhong、Li,Dezhi、Wan,Yunyan、Zhu,Ling、Lin,Dianjie
Shandong Provincial Hospital

Objective: Malignant pleural mesothelioma (MPM) is a rare and highly aggressive malignancy related with environmental exposure to asbestos. Despite the recent advances in clinical treatments including surgery, chemotherapy, radiotherapy and trimodality therapy, they don’t have ideal curative effects. MPM remains difficult to treat and standard therapies are still in flux. Therefore, a novel and more effective treatment strategy is urgently required. Now, we report a case of MPM treated through medical thoracoscopy with snare ligation. And then the patient was treated with chemotherapy after thoracoscopy. The treatment is very effective.

Methods: Malignant pleural mesothelioma (MPM) is a rare and highly aggressive malignancy related with environmental exposure to asbestos. Despite the recent advances in clinical treatments including surgery, chemotherapy, radiotherapy and trimodality therapy, they don’t have ideal curative effects. MPM remains difficult to treat and standard therapies are still in flux. Therefore, a novel and more effective treatment strategy is urgently required. Now, we report a case of MPM treated through medical thoracoscopy with snare ligation. And then the patient was treated with chemotherapy after thoracoscopy. The treatment is very effective.

Results: The treatment effect of the patient was obvious. The pleural tissue and pleural effusion on the right side were significantly reduced. Only a little pleural effusion was observed.The patient has been stable for 30 months since diagnosis.

Conclusion: With the development of medical thoracoscopy, its application is not only limited to the diagnosis of pleural diseases, but also more and more applications in the treatment of pleural diseases. The treatment using snare ligation can reduce the tumor load, and then combined with systemic chemotherapy bring more benefits to patients with pleural malignant tumors, which is worth advocating.

PO-165

A rare case of primary pleural extranodal marginal zone lymphoma of mucosa-associated lymphoid tissue diagnosed by medical thoracoscopy

Xiao,Kui1、Wang,Yaohui1、Tang,Yu1,2、Zhu,Zhiruo1、Xia,Shulan1、Shi,Zhihui1、Xiang,Jing1、Zhou,Rui1
1. The Second Xiangya Hospital, Central South University
2. Hunan Cancer Hospital

Objective: Primary pleural extranodal marginal zone lymphoma of mucosa-associated lymphoid tissue is a rare cause of pleural effusions. We present a rare case for further understand this disease.

Methods: A 54-year-old male presented with recurrent shortness of breath for 4 months. The patient went to a local tertiary hospital 3 months ago and found pleural effusion of the right side pleural cavity only. The pleural biopsy under B-ultrasonography showed infiltration of inflammatory cells in the tissue and fibroplastic proliferation. He was suspected of having tuberculous pleuritis because the exudate nature of the pleural fluid. He was also given a closed drainage of right side pleural cavity and a standard anti-tuberculosis therapy of RFP, INH, PZA and EMB for two and a half months, while he still feel dyspnea. He then went to our hospital for further diagnosis and treatment. We reviewed his medical history and suspected him of malignant pleural disease. Then, we performed a medical thoracoscopy(MT) for him in this May.

Results: Under the MT, we observed the congestion and swelling of his posterior costal pleura, small nodules on the diaphragmatic pleura and big mass in the posterior costal diaphragm angle. We performed the forceps biopsy and cryobiopsy of the pleural lesions. The rapid on-site evaluation found suspected malignant cells. Then the immunohistochemical pathology showed a diagnosis of low grade B cell non-Hodgkin's lymphoma: extranodal marginal zone lymphoma of mucosa-associated lymphoid tissue, a high-power view showed tumor cells consisted of small to moderate sized lymphoid cells with irregular nuclear outlines and a moderate amount of pale to clear cytoplasm (CD20+, CD3-, CD23-, Ki-67 10%). The molecular pathology showed positive B lymph cell gene rearrangement (FR1-JH & FR3-JH). After a group consultation, he was transferred to the hematology department and received the R-CHOP chemotherapy for multiply cycles.

Conclusion: MT could be an effective way to diagnose primary pleural extranodal marginal zone lymphoma of mucosa-associated lymphoid tissue.

PO-166

ROLE OF FLEXIBLE CRYOPROBE IN EXTRACTION OF ASPIRATED FOREIGN BODIES

Kavanakudiyil,Tinku Joseph、Kochucheruroor,Sreeraj Nair
Amrita Institute of Medical Sciences & Research center, Kochi, Kerala, India

Objectivex: Foreign body aspiration is the most common cause of mortality due to asphyxia in children and source of morbidity in adults. Cryo-extraction is a novel technique based on Joule-Thomson principle by which a flexible cryoprobe freezes the concerned object or tissue enabling quick and easy removal of foreign bodies depending on the cryoadhesive properties of the retrieved object. The main objective of our study was to highlight the cryoadhesive properties of commonly aspirated foreign bodies.

Methods: All patients (Adult/Pediatric) with suspected foreign body aspiration were included in the study group. Foreign body extraction was performed in all cases under general anesthesia with rigid bronchoscope. Flexible cryoprobes (1.9 / 2.4mm) was introduced through working channel of bronchoscope to retrieve foreign body in all

cases. Haemostasis in cases of impacted foreign bodies was achieved with the help of fogarty balloon, cold saline and adrenaline solution.

Results: During study period 24 aspirated foreign body cases were enrolled. Among these in 20 cases presence of foreign body in the lung was confirmed with the help of chest xray/CT chest and flexible bronchoscopy. Out of 20 aspirated foreign bodies, 18 were retreived using flexible cryo-probes (1.9/2.4mm). Generally cryo is considered as an excellent tool for retreival of organic foreign bodies. In our study we managed to retreive 4 non organic foreign bodies with the help of cryo-probe after istilling 2ml saline around the impacted foreignbody. In our experience, dental cap, calcium tablet and broncholith even though inorganic was cryoadhesive, despite of low water content. Spraying of normal saline over the non organic foreign body enables crystalisation of the water molecules that results in strong adhesion leading to successful retrival. Cryoadhesion / extraction is the ideal procedure for retrieval of certain impacted organic/ non organic aspirated foreign bodies.

Conclusion: Cryo is an effective tool to remove impacted organic foreign bodies. Instilling small amount of normal saline around non-organic foreign bodies helps in its retrieval using cryo.

PO-167

Concordance between virtual bronchoscopic navigation and radial endobronchial ultrasound in the diagnosis of peripheral pulmonary lesions

Chesalina,Yana、Dedushkin,Dmitry 、Shabalina,Irina、Berezovsky,Yuri、Evgushenko,Galina、Karpina,Natalya、Sivokozov,Ilya
Central Tuberculosis Research Institute

Objective: Data regarding comparative efficacy of two main navigation techniques - radial endobronchial ultrasound (rEBUS) and virtual bronchoscopic navigation (VBN) are still controversial. The aim is to assess comparative efficacy of VBN and rEBUS in guiding target lesion and final diagnostic yield in unselected population of patients with perpipheral pulmonary lesions (PPLs).

Methods: 17 patients with PPLs detected by HRCT (mean size 12 mm) were referred to navigation bronchoscopy, in all cases VBN (using Osirix system) was done as a planning procedure before real bronchoscopy with rEBUS navigation (Olympus UM-S20-17S) using standard diagnostic bronchoscope (Olympus Q190 or Pentax EB15J10). For VBN procedure technical/clinical failure incidence, detection of target segmental/subsegmental/deeper bronchial divisions was assessed. For rEBUS, incidence of target visualization (central/adjacent probe position), efficacy of TBLB/brushing for malignant/benign diseases, possible factors influencing on efficacy of VBN/rEBUS was analyzed.

Results: According to HRCT, target lesions were found in RUL (5), RML (2), RLL (6), LUL (2), LLL (2). VBN was technically possible in all cases. Among them detection of target bronchus was achieved in 16/17 cases: segmental airway in 4 (25%), subsegmental - in 7 (43,7%), deeper generations – in 5 (31,2%). In one case achievement of target bronchus was failed due to stenosis of lobar bronchus. In 9 cases (53%) positive bronchus sign was found according to HRCT data. rEBUS was applied in 17 cases: central probe position was reached in 3 cases (17,6%), adjacent probe position - in 5 (29,4%), lesion wasn’t reached in 9 cases (53%). All of RUL lesions were reached by rEBUS. In positive bronchus sign group target lesion was reached by rEBUS in 66% (6/9); in negative bronchus sign group – in 25% (2/8). Total procedure duration was less in positive bronchus sign group (16 min versus 19 min in negative bronchus sign group). Concordance between VBN and rEBUS in terms of target correct positioning reached 88%. Lesions were divided into three groups depending on size: <2 cm – 6/17, <2 cm, >3 cm – 2/17, >3 cm – 9/17; most of them were located in middle third of lung (9/17). The detection rate of rEBUS probe was significantly higher in third group (83%). Diagnostic yield of TBLB was 62%, of brushing – 50%, total yield reached 83% for malignant diaseases, 27% - for benign diseases.

Conclusion: There is high concordance between VBN and rEBUS. Bronchus sign, lesion size, location and depth could influence on efficacy of VBN and rEBUS.

PO-168

Tracheobronchopathia Osteochondroplastica: A Cause of Chronic Cough

Xu,Chuancai、Ni,Chongjun、Huang,Jian'an、徐传财
The First Affiliated Hospital of Soochow University

Objective: We report a case of chronic cough caused by tracheobronchopathia osteochondroplastica (TO) confirmed by bronchoscopy.

Methods: A 44-year-old male patient presented to the local hospital with a 3 years history of chronic cough and chest tightness. The patient exhibited normal appearances of blood tests and pulmonary function tests. Bronchial provocation test was negative, but in the procedure, the patient had persistent cough. The patient was admitted to our hospital for further examination and treatment. The FeNO value of the patient was 44 ppb. Budesonide/formoterol inhalation powder 9μg/320μg (Symbicort turbuhaler, AstraZeneca, Sweden) was used but it didn't relieve symptoms. The patient had no history of smoking or underlying diseases.

Results: Computed tomography scanning revealed there was slight calcification in the trachea (Figure.1A). Bronchoscopy demonstrated extensive tracheal nodular excrescences sparing the posterior membranous wall (Figure.1B). Histological examination of the nodular lesions showed ossification and calcification in the submucosal region, consistent with tracheobronchopathia osteochondroplastica (Figure.1C). After the procedure, the patient was followed up in 4 years and the trachea nodular lesions were stable (Figure.1D).

Conclusion: TO is a rare benign airway disease characterized by multiple submucosal osteocartilaginous nodules that project into the lumen of large airways. Numerous inconsistent etiologic factors of TO have been suggested, including reduction of mucociliary transport, metaplasia of the connective tissue, exostosis arising in the cartilaginous ring, chronic inflammation, trauma, and amyloidosis. Previous reviews of TO cases have reported incidences varying from 0.01% to 0.41%. Because nodular lesions arise from cartilage, the posterior membranous wall of trachea is typically spared. Cough is the most common complaint, seen in 66% of the symptomatic patients. Due to non-specific and inexplicit symptoms, TO may be misdiagnosed as asthma or chronic obstructive pulmonary disease. The diagnosis is made during bronchoscopy by visualizing the characteristic rock garden or beaded appearance of multiple cartilaginous or bony lesions most commonly in the lower trachea. Treatment is seldom required except in cases of severe airway obstruction in which bronchoscopic dilation may be indicated.

PO-169

To discuss the diagnostic vale of EBUS-TBNA in mediastinal lymph node enlargement under bronchoscope.

Li,Shufen
Inner Mongolia People's Hospital

Objective: Mediastinal lymph node enlargement is common in chest CT and medical diseases,but the nature of lymph nodes is always difficult to determine,to discuss the diagnostic vale of EBUS-TBNA in mediastina lymph node enlargement under bronchoscope.

Methods: Clinical data of 79 patients with EBUS-TBNA under tracheoscopy in our hospital in the 3yeas were retrospectively analyzed,and the pathological results and complications of puncture were summarized.

Results: A total of 79 patients with mediastinal lymph node enlargement of the male:51,female cancer:28 people,age between 25 to 80 yeas old,line bronchoscopeEBUS-TBNA pathological returns:inflammatatory:7 cases,small cell lung cancer:19cases,cases of squamous cell carcinomas:16case of adenocarcinoma 12cases of mesothelioma: 1case,granuloma:6cases of adenocarcinoma with squamous tumble:5cases,sarcoidosis:1case,the source of thymic tumor:1case,not a definitive diagnosis:11cases.Among them,13.9%were not clearly idagnosed 86.1% were definitely diagnosed(68.4%were tumors and 17.7% were benign lesins).The diagnostic rate of ebus-tbna under tracheal microscopy was as high as86.1% in patientswith mediastinallymph node enlargement,especially in patients with tumors. Due to the uneven level of pathological examination results in different hospitals, the diagnostic rate was different.All patients had no adverse reactions and complications during and after operation. A total of 79 patients with mediastinal lymph node enlargement of the male:51,female cancer:28 people,age between 25 to 80 yeas old,line bronchoscopeEBUS-TBNA pathological returns:inflammatatory:7 cases,small cell lung cancer:19cases,cases of squamous cell carcinomas:16case of adenocarcinoma 12cases of mesothelioma:1case,granuloma:6cases of adenocarcinoma with squamous tumble:5c ases,sarcoidosis:1case,the source of thymic tumor:1case,not a definitive diagnosis:11cases.Among them,13.9%were not clearly idagnosed 86.1% were definitely diagnosed(68.4%were tumors and 17.7% were benign lesins).The diagnostic rate of ebus-tbna under tracheal microscopy was as high as86.1% in patientswith mediastinallymph node enlargement,especially in patients with tumors. Due to the uneven level of pathological examination results in different hospitals, the diagnostic rate was different.All patients had no adverse reactions and complications during and after operation.

Conclusion: Tracheal endoscopy ebs-tbna has high positive rate,sensitivity and accuracy,and few complications. It has high diagnostic value in various diseases of mediastinal lymph node enlargement.

PO-170

Values of qualitative and quantitative methods of endobronchial ultrasound elastography in diagnosing intrathoracic lesions

Xie,Fangfang1,2、Zheng,Xiaoxuan1,2、Wang,Lei1、Chen,Junxiang1,2、Li,Ying1,2、Sun,Jiayuan1,2
1. Shanghai Chest Hospital, Shanghai Jiao Tong University
2. Shanghai Engineering Research Center of Respiratory Endoscopy

Objective: We have proposed a five scores assessing system of endobronchial ultrasound (EBUS) elastography in differentiating benign and malignant thoracic lesions. The current study was conducted to investigate the diagnostic value of this qualitative method. Moreover, four quantitative methods were explored in this study.

Methods: Patients with at least one enlarged intrathoracic lymph node or lesion that can undergo EBUS guided transbronchial needle aspiration (EBUS-TBNA) from April 2015 to June 2015 were prospectively enrolled. Target lesions were examined by B-mode, vascular and elastography patterns using a linear array ultrasonic bronchoscope. Samples were obtained for pathological examination, and microbiologic assessment if necessary. Qualitative analysis of elastography image used the five scores assessing system. Score 1 to score 3 was defined as benign disease and score 4 to score 5 was defined as malignant disease. Quantitative methods, including the stiff area ratio, the mean gray value, mean hue histogram value, and elasticity ratio of the mean histogram values of blue versus green channels, were analyzed in the study.

Results: A total of 105 patients with 117 lesions, including 106 lymph nodes and 11 masses with the mean long-axis diameter of 21.8±9.0 mm and 27.8±7.3 mm, respectively, were enrolled in the study. Of the 117 lesions, including 90 malignant and 27 benign, 104 were diagnosed by EBUS-TBNA with the diagnostic yield of 88.9%. The mean number of needle passes per lesion was 3.3, ranging from 1 to 6. The sensitivity, specificity, positive predictive value, negative predictive value, and accuracy was 86.7%, 88.9%, 96.3%, 66.7%, 87.2%, respectively, using qualitative methods in distinguishing malignant and benign lesions with the mean qualitative elastographic scores of 4.16±0.63 and 2.78±1.01 (p=7.18E-14). The stiff area ratio, mean gray value, mean hue histogram value, and elasticity ratio showed a better differentiation of malignant and benign lesions at the cut-off value of 0.42, 192.92, 119.55, and 1.11 with an area under the ROC curve of 0.831, 0.846, 0.863, 0.845, respectively, which yielded a sensitivity, specificity and accuracy of 80.0%, 81.5% and 80.3%; 86.7%, 77.8% and 84.6%; 90.0%, 81.5% and 88.0%; 81.1%, 77.8% and 80.3%. When qualitative analysis combined with mean hue histogram value, the sensitivity, specificity and accuracy can improve to 90.0%, 88.9% and 89.7%.

Conclusion: EBUS elastography is a promising method in differentiating malignant from benign thoracic lesions. Both qualitative and quantitative methods can yield good performance in distinguishing benign and malignant thoracic lesions.

PO-171

The Assessment ofthe Efficacy and Safety of Bronchoscopy Interventional Therapy of Bronchopleural Fistula:Reports of 23 Cases

Zhang,Wei、Huang,Haidong、Wang,Qin、Sun,Qingyin、Dong,Yuchao、Yang,Yuguang、Li,Qiang、Bai,Chong
Department of Respiratory and Critical Care Medicine, Shanghai Changhai Hospital, The Second Military Medical University, Shanghai, P. R. China.

Objective: To assess the efficacy and safety of bronchoscopy interventional therapy of BPF.

Methods: Clinical data of 23 cases of bronchopleural fistula were retrospectively analyzed to assess the efficacy and safety of bronchoscopy interventional therapy. The bronchopleural fistula patients were divided into two types depending on the location of fistula: peripheral bronchopleural fistula(fistula located on remote end of segmental bronchus) and central bronchopleural fistula (fistula located on segmental bronchus and above). Central bronchopleural fistula patients were divided into two groups according to the diameter of fistula: small-fistula-group (fistula diameter≤3mm) and big-fistula-group (fistula diameter ＞ 3mm). A variety of bronchoscopy interventional treatment were used and the efficacy and safety of bronchoscopy interventional therapy on each group of patients was analyzed separately.

Results: 23 bronchopleural fistula patients include peripheral type bronchopleural fistula 7 cases and central bronchopleural fistula 16 cases. 23 cases of bronchopleural fistula, through bronchoscopy interventional therapy, cured 13 cases (56.5%), effective in 6 cases (26.1%), invalid 4 cases (17.4%). 7 cases of peripheral-type bronchopleural fistula fistula patients underwent the bronchoscopy interventional therapy and the cure rate is 100%. 16 cases of central bronchopleural fistula patients, nine cases of fistula diameter ≤ 3mm center type bronchopleural fistula, after intervention by bronchoscope, where six cases were cured, three cases treatment is effective; seven cases of fistula> 3mm center bronchopleural fistula, by bronchoscopy intervention, three cases effective, four cases invalid. For bronchopleural fistula of peripheral and central type of fistula ≤ 3mm, the bronchoscopy interventional treatment cure rate was 81.3%, the effective rate was 18.7%. There were no serious complications in the treatment process.

Conclusion: For the bronchopleural fistula, bronchoscopy interventional therapy has better efficacy and safety. For bronchopleural fistula of peripheral and central type of fistula ≤ 3mm, the method should be the preferred treatment. For fistula diameter> 3mm center type BPF, this method is effective for some patients. The patients with the bronchoscopy interventional treatment failure still need surgery.

PO-172

Safety and feasibility of bronchial thermoplasty in low FEV1 (<50%) patients

Guliani,Abhinav、Basu,Arup、Dhamija,Amit
Sir Ganga Ram Hospital, New Delhi, India

Objective: Bronchial thermoplasty is now an established modality for the treatment of severe asthma. It has been extensively studied for patients with FEV1>60%. Reports have also been published for more severe cases but the data is scant. We share our experience from a tertiary center in India.

Methods: We present the analysis from 3 cases with FEV1 <50%, who underwent bronchial thermoplasty at our hospital between May 2018 till November 2019. The demographic data, ACQ scores, spirometry and procedural details including number of activations were recorded. The patients were given oral prednisone 40mg 2 days prior to the procedure and 2 days post procedure. They were given a bolus of methylprednisolone on the day of the procedure (60mg)

Results: All three patients underwent the procedure in three sittings 3-4 weeks apart. They were all above 50years of age. Two had chronic steroid dependent asthma whilst one had relatively recent onset with steroid dependence. None of the patients had any adverse events during the procedure. All procedures were carried out under general anaesthesia with muscle relaxant via ET tube. We could achieve more than 100 activations per sittting in all patients. 2 out of 3 patients post second sitting had an infective exacerbation that could be managed by oral antibiotics on outpatient basis. The ACQ score improved in all 3. However, steroids have not been tapered off yet, in one patient. The quality of life has significantly improved in 2 patients with more severe disease, however it's marginally better in the third one. We could also document muscle mass reduction on biopsy in one patient.

Conclusion: Bronchial thermoplasty is successful in reducing airway smooth muscle mass as demonstrated on biopsy in chronic persistent asthma. It reduces the ACQ score and improves quality of life. It is feasible, safe and as effective in severe obstruction (FEV1 <50%) patients also.

PO-173

A case of long term maintain stent patency of Self-expandable metallic stent for benign tracheal stenosis.

Utsumi,Kenta、Nakashima,Masanao、Terada,Tomoko、Aoyama,Azusa、Nagai,Atsushi、Shiga,Koujirou、Oda,Minoru
Shinyurigaoka general hospital

Objective: Airway stent is used for stenosis of airway due to malignant tumor or other disease. Rescue from dyspea is main purpose of airway stents. Airway stents is divided into two classes, silicon stent and metallic stent. Metallic stent is indicated for stenosis of trachea or bronchus. Self-expandable metallic stent (SEMS) is insterted under local aneshtesia and Fexible Bronchoscope. SEMS enable immidiate improvement of dyspnea due to airway stenosis. Benign stenosis must be opened by Silicon stent such as Dumon stent , because removing of stent will be need ater improvement of stenosis due to any other therapies such as chemotherapy or irradiation. Rare situation was indicated for metallic stent of benign airway stenosis. We selected SEMS for benign stenosis of Symmetric lipomatosis(Madelung`s disease) and long term patency was observed.

Methods: A case of Symmetric polylipomatosis (Madelung Disease) suffered for dyspnea. He had growthing neck lipomatosis and resection of lipomatosis of neck was performed . But dyspea was not improved after resection. Bronchoscopy revealed the proximal tracheal stenosis from the outsideof tracheal wall. Tracheal stenosis was funnel-shaped. Baloon dilatation of tracheal stenosis was performed but no improvement of dyspnea. We selected SEMS (un-

covered nitinol stent) for this tracheal stenosis. His dyspnea was improved quickly after Instertion of SEMS.

Results: After 17years, He was suffered of aspiration pneumonia and dyspnea. After improvement of aspiration pneumonia, dyspnea was almost vanished. Bronchoscopy was performed. SEMS maintained the same position of inserted time. No damage of SEMS was observed. A few granuloma of tracheal wall was exsisted at the terminal position on SEMS.

Conclusion: Symmetric polylipomatosis is regarded as benign disaeses. We had experience of a case of tracheal stenosis due to Symmetrical polylipomatosis and long term (17 years) patency of trachea by SEMS. Some cases of long term patency of SEMS was reported. Benign airway stenosis of selected cases are adaptable of metallic stent.

PO-174

A retrospective study of percutaneous tracheotomy retrograde dilatation assisted implantable Montgomery T-tube under flexible bronchoscopy for subglottic stenosis

Zhang,Wei、Dong,Yuchao、Zhang,Wei、Dong,Yuchao、Qin,Hao、Yang,Yuguang、Huang,Haidong 、Wang,Qin、Bai,Chong
Department of Respiratory and Critical Care Medicine, Shanghai Changhai Hospital, The Second Military Medical University, Shanghai, P. R. China.

Objective: To evaluate the feasibility and safety of flexible bronchoscopy guided percutaneous tracheotomy retrograde expansion assisted implantation of Montgomery T-tube for the treatment of subglottic stenosis.

Methods: Retrospective analysis of data from December 2017 to October 2019. A total of 6 patients underwent surgery under general anesthesia or painless conditions. During the procedure, a mask is inserted to maintain ventilation. During the operation, first, local treatment of subglottic stenosis is performed under flexible bronchoscopy, including laser, high frequency resection, high frequency electrocoagulation, etc., and then a J-shaped guide wire is inserted into the trachea through tracheotomy. After entering the Laryngeal Mask Airway, use a biopsy forceps to pull the guide wire out of the mouth, and then place a single step dilator retrograde to expand the narrow subglottic gland along the guide wire through the tracheotomy opening. The dilator is inserted through the skin branch of the T-tube and exits the glottis. Under the guidance of the flexible bronchoscope, implant the T-tube retrogradely along the J-shaped guide wire from the tracheostomy opening, then use the bronchoscope and hemostat to adjust the T-tube to the desired position, and then use the balloon to fully expand the T-tube.

Results: Six patients were severe subglottic stenosis, of which 2 were subglottic atresia, 4 were subglottic stenosis, the average diameter of the stenosed segment was 4mm, the average length of the stenotic segment was 15.8mm, and the average distance of the stenotic segment from the vocal cord was 27.5mm. During the operation, 2 patients underwent tracheotomy + T-tube implantation at the scene, and the remaining 4 patients underwent surgical operations through the original tracheotomy fistula. All 6 patients successfully completed the operation, with an average operation time of 8.3 minutes. Mild hypoxemia occurred in 2 patients during the operation, and the bleeding volume was less than 20ml. No serious complications occurred.

Conclusion: The use of flexible bronchoscopy combined with percutaneous tracheotomy for retrograde expansion and implantation of T-tubes to treat subglottic stenosis is safe and effective. This method has not been reported before. This method avoids the use of rigid bronchoscopy and surgery, reduces trauma, and saves time and cost of surgery.

PO-175

Analysis of circular RNAs expression profile in tuberculous pleurisy

Li,Xi、Xiao,Qiang 、Liang,Luoqi、Lu,Yanshan、Chen,Mingzhen、Ouyang,Yandi、Rong,Fu
Shunde Hospital，Southern Medical University（The First People’s Hospital of Shunde）

Objective: Circular RNAs (CircRNAs) has been shown to be potential diagnostic biomarkers for active tuberculosis[1-3], however, its relationship with tuberculous pleurisy is not clear. This study used high-throughput sequencing technology to analyze the differential expression and clinical significance of CircRNAs in patients with tuberculous pleurisy,in order to provide new ideas for the diagnosis of tuberculous pleurisy.

Methods: 13 patients with tuberculous pleurisy and 13 patients without tuberculosis nor neoplasm were enrolled in this study. The consultation time of these patients was from January 2018 to December 2018 and the location was at the Department of Respiratory Medicine, Shunde Hospital, Southern Medical University (the First People's Hospital of Shunde Foshan). The selected patients can be clearly diagnosed and meet the inclusion criteria.All patients underwent pleural biopsy tissues through thoracoscopy. High-throughput circRNAs expression profiling analysis was performed on the samples from 3 patients with tuberculous pleurisy and 3 patients without tuberculosis nor neoplasm, volcanic maps and cluster maps show the difference in circRNAs. Target gene analysis software to predict target miRNAs that may interact with up-regulated and down-regulated circRNAs, functional analysis of differential genes was performed by genetic bioinformatics to explore the potential role of circRNAs in patients with tuberculous pleurisy in order to find potential diagnostic markers. qRT-PCR was then performed on the remaining samples for verification of the top 6 circRNAs with the most significant differential expression.

Results: Analysis of circRNAs expression profile showed 134 circRNAs significantly differentiate tuberculous pleurisy tissues from non-tuberculous nor non-neoplastic tissues. Among them, 53 expressions were up-regulated and 81 expressions were down-regulated. Compared with the non-tuberculous nor non-neoplastic tissues, qRT-PCR verification showed that the expressions of hsa_circ_0008433 in the tuberculous pleurisy tissues was up-regulated, while the expressions of hsa_circ_0008234 and hsa_circ_0001368 in the tuberculous pleurisy tissues were down-regulated. The prediction of miRanda software suggested that hsa-miR-17, hsa-miR-20b-3p and hsa-miR-320a were the target genes of hsa_circ_0008234. (Figure)

Conclusio: CircRNAs expression profile was changed in tuberculous pleurisy tissues compared with that in non-tuberculous nor non-neoplastic tissues. A panel including 3 circRNAs was proposed for potential diagnostic biomarkers of tuberculous pleurisy.

PO-176

Treasure hunt in the mediastinum lesions or lung lesions by EBUS-TBNA and EUS-B-FNA : A road map for the best route

Cheng,Wen Chien、Shen,Meng-Fang、Wu,Biing-Ru、Liao,Wei-Chih、Chen,Chih-Yu、Shen,Yi-Cheng、Chen,Wei-Chun、Chen,Chia-Hung、Tu,Chih-Yen
China Medical University Hospital， pulmonary department

Objective: Endobronchial ultrasound-guided transbronchial needle aspiration (EBUS-TBNA) and endoscopic ultrasound with an echobronchoscope guided fine needle aspiration (EUS-B-FNA) are useful modalities in the evaluation of mediastinal lymphadenopathy (LAP) and pulmonary lesions in adults; however, a guided on how to choose a best one from these two methods is limited. The aim of this study is to identify the best route for chest physician for diagnosis of the mediastinum LAP and pulmonary lesions.

Methods: 43 Consecutive patients with mediastinum LAP underwent EUS-B-FNA with or without EBUS-TBNA (EUS-B group) through a single linear ultrasound bronchoscope from January 2017 to December 2019. We randomly picked up another 44 patients with mediastinum LAP or pulmonary lesions underwent EBUS-TBNA alone (TBNA group). We tried to identify the independent clinical characteristics of these patients who needed to undergo EUS-B-FNA for the target lesions assessment from these two groups.

Results: The patient's lymphadenopathy (LAP) size in the EUS-B group is larger than those in the EBUS-TBNA group (3.47 cm vs 2.93 cm; $p < 0.001$.) The location of lymph nodes or lung lesions were significant difference between these two groups. (53.5% vs 9.1%; $p <0.001$) The patients in the EUS-B group had much higher proportion of airway narrowing compared to those in EBUS-TBNA group. (44.2% vs 13.6%; $p <0.001$) The availability of rapid-on-site evaluation (ROSE) was higher in EUS-B group than EBUS-TBNA group. (83.7% vs 63.6%; $p = 0.034$) After univariate and multivariate analysis, the location of target lesions, airway narrowing of the subjects, and the availability of ROSE were independent factors influencing diagnostic methods decision.

Conclusion: EBUS-TBNA and EUS-B-FNA are safe techniques with a good diagnostic yield in the assessment of patients with mediastinum LAP or lung lesions. We can choice the best one from these two methods based on the location of target lesions, airway narrowing or not, and the availability of ROSE.

PO-177

Analysis of circular RNAs expression profile in pleural metastasis of lung adenocarcinoma

Li,Xi、Xiao,Qiang、Liang,Luoqi、Lu,Yanshan、Chen,Mingzhen、Ouyang,Yandi、Rong,Fu
Shunde Hospital，Southern Medical University（The First People’s Hospital of Shunde）

Objective: Circular RNAs (CircRNAs) have been shown to be a potential biomarkers for the diagnosis or prognosis of lung cancer[1-3], however, their relationship with pleural metastasis of lung adenocarcinoma has not yet been clarified. We aim to investigate the relationship between circRNAs and pleural metastasis of lung adenocarcinoma.

Methods: 13 patients with pleural metastases from lung adenocarcinoma were enrolled in this study. The consultation time of these patients was from January 2018 to December 2018 and the location was at the Department of Respiratory Medicine, Shunde Hospital, Southern Medical University (the First People's Hospital of Shunde Foshan). The selected patients can be clearly diagnosed and meet the inclusion criteria. All patients underwent pleural biopsy tissues through thoracoscopy. Pleural metastatic cancer tissues and adjacent tissues were collected from all the participants. High-throughput circRNAs expression profiling analysis was performed on the samples collected from

3 of these patients. Volcanic maps and cluster maps show the difference in circRNAs. Target gene analysis software to predict target miRNAs that may interact with up-regulated and down-regulated circRNAs, functional analysis of differential genes was performed by genetic bioinformatics to explore the potential role of circRNAs in patients with pleural metastasis of lung adenocarcinoma in order to find potential diagnostic markers. qRT-PCR was then performed on the remaining samples for verification of the top 5 circRNAs with the most significant differential expression.

Results: Analysis of circRNAs expression profile showed 148 circRNAs significantly differentiate pleural metastatic cancer tissues from paracancer pleural tissues. Among them, 27 expressions were up-regulated and 121 expressions were down-regulated. qRT-PCR verification showed that the expressions of hsa_circ_0007443, hsa_circ_0013093 and hsa_circ_0003218 in the pleural metastatic carcinoma were down-regulated compared with those in the adjacent tissues. The prediction of miRanda software suggested that hsa-miR-15a-3p and miR-187-5p were the target genes of hsa_circ_0003218, while hsa-miR-125a-3p were the target gene of hsa_circ_0007443. (Figure)

Conclusion: CircRNAs expression profile was changed in pleural metastatic cancer tissues compared with adjacent tissues. A panel including 3 circRNAs was proposed for potential prediction of pleural metastasis of lung adenocarcinoma.

PO-178

Role of Interventional Bronchoscopy in management of Central Airway Tumours

Kavanakudiyil,Tinku Joseph
Amrita Institute of Medical Sciences & research center, Kochi, Kerala, India

Objective: To assess the successful outcome of patients who underwent rigid bronchoscopy and endobronchial tumour debulking for the management of central airway tumours

Methods: Prospective study of patient who underwent rigid bronchoscopy and endobronchial tumour debulking for the management of central airway (trachea and mainstem bronchi) tumors over a period from January 2018 – October 2019. "Successful" outcome was defined as procedure leading to reduction of luminal obstruction to <80% and improvement of respiratory distress. "Unsuccessful" outcome was defined in cases where the luminal obstruction could not be reduced by >or= 80% or there was lack of improvement in the clinical status of the patient. All tumours was initially serial cryoablated at multiple sites to decrease the vascularity and debulked using snare electrocautery then retrieved with 2.4 mm cyroprobe. The base of the lesion was ablated with cryoprobe.

Results: During the study period, 42 patients with symptomatic central airway tumors were encountered who underwent rigid bronchoscopic procedures. 19 patients had tracheal tumour, 17 and 6 patients had right and left main bronchus endobronchial mass lesion respectively. Poorly differentiated Squamous cell carcinoma was the most common primary tracheal tumour, whereas poorly differentiated adenocarcinoma was the most common secondary tracheobronchial tumour. The procedure was successful in 38(90.40%) patients.

Conclusion: Multimodality therapeutic bronchoscopy approach facilitates the management of tracheobronchial tumors by removing the tumour and restoring ventilation to collapsed lung. It is as an effective, quick, and safe procedure in the management of tracheobronchial tumors

PO-179
Electrocautery in Complicated Pleuritis Tuberculosis

Singh,Gurmeet
Universitas Indonesia

Objective: to understand the role of electrocautery in complicated pleuritis tuberculosis

Methods: Case report: 68 year old male with complicated pleuritis TB underwent electrocautery via thoracoscopy to release adhesions in pleural space. Patient previously underwent thoracentesis twice and chest tube insertion

Results: electrocautery via thoracoscopy was done to the patient and serial chest x-ray showed improvement post-procedure. patient was put on anti-tuberculosis treatment and steroids

Conclusion: Pleuritis TB is the second most common extra-pulmonary TB after lymphadenitis Unilateral complicated pleuritis TB may complicate TB treatment and worsen patient's quality of life electrocautery via thoracoscopy is one of the treatment options to release adhesions besides anti-tuberculosis treatment

PO-180
A case of diffuse large B cell lung non Hodgkin's lymphoma

Jiang,Yanxia、Che,Yuhu
The people's hospital of liaoning province

Objective: Diffuse large B-cell lymphoma (DLBCL) is the most common adult non-Hodgkin's lymphoma, but the primary intranodal and extranodal DLBCL is very rare. In clinic, some patients did not meet the diagnostic criteria of DLBCL and had no history of lymphoma. They only treated with lung lesions as the first symptom. The imaging findings were complex and easy to be misdiagnosed. Here is a case of diffuse large B-cell lung non-Hodgkin's lymphoma.

Methods: CT: the diffuse lesions of both lungs were more severe than that of the former. There were cavities in the upper left lung lobe, GM (-), (±), igg53.31au/l, fungal antigen (-). Percutaneous lung biopsy was performed at the right lower lung consolidation.

Results: Pathological return: see some cells, nucleus big deep dye, have heteromorphism, diffuse distribution. Ki67 (80-90%), P40 (-), LCA (+), syn (-), CD56 (-), CK5 / 6 (-), CK7 (-), napsina (-), TTF-1 (-), supplementary immunohistochemistry: CK (-), WT-1 (-), CD3 (spot spot spot +, CD5 (+ +), CD20 (+ +), CD79a (+ +), CD21 (-), CD10 (+), mum-1 (+), bcl-6 (+), bcl-2 (+ + +)), small round cell lung cancer is more likely, combined immunity The results of immunohistochemistry showed that non-Hodgkin's lymphoma: diffuse large B-cell lymphoma (germinal center B-cell like) was more likely. After 18 days in hospital, the patient died because of the rapid progress of the disease.

Conclusion: 肺淋巴瘤缺乏特异性的临床表现，同时肺 CT 也缺乏特异性影像特征，而确诊主要依靠经皮肺穿刺活检术、胸腔镜或开胸手术获得病理学依据，诊疗过程中非常容易漏诊及误诊，我们此例患者肺 CT 演变过程经历了经积极抗感染、抗炎无效，短时间肺病变进展迅速，终于在 CT 引导下穿刺予明确。为临床诊治积累了经验。CT 引导下经皮肺穿刺活检阳性率较高，且操作简便、安全、创伤性小，已被我科广泛应用于各种肺内病变的确诊

PO-181

Bronchoscopy Using Virtual Navigation with or without Endobronchial Ultrasonography with a Guide Sheath (EBUS-GS) for Peripheral Pulmonary Lesions:One-month Results

Xu,Li、Wang,Xiaodong、Wang,Xiaoqing、Shan,Chengyan、Ma,Xiuli、Wang,Jinyan、Wang,Xiaoping
Shandong Chest Hospital

Objective: Virtual Bronchoscopy Navigation (VBN) System or Endobronchial ultrasonography and guide sheath (EBUS-GS) is a minimally invasive technology that can lead bronchoscope to the target bronchi.The aim of this study was to compare the diagnostic yield of benign lesion and malignant lesion for peripheral pulmonary lesions (PPLs) :Bronchoscopy under and VBN with or without EBUS-GS with apparent CT-bronchus sign.

Methods: This is a retrospective, single-center study with more than 1 month of follow-up.140 patients with PPLs which had apparent CT-bronchus sign between June 1,2019, and November 30, 2019. The bronchoscope was introduced into the target bronchus using the Archimedes (LungPro) VBN System(Broncus Medical) . Sites of specimen sampling were verified using VBN with or with out EBUS-GS.

Results: The median lesion size was 24.5 mm in the benign lesion and 28.0mm in the malignant lesion.The average procedure time for 140 patients was 22.5 minutes.Follow-up was completed in 100% of subjects at 1 month. The overall diagnostic yield was 82% （27/33）in the malignant lesion,and there were 30 cases through the EBUS-GS in 33 malignant cases.There are three levels of evidence, depending on the level of evidence in the benign lesion group:Confirmed,Consistent with clinical diagnosis,Insufficient evidence.There are 41 cases was confirmed and 37 cases was Consistent with clinical diagnosis.The overall diagnostic yield was 72%（78/107）in the benign lesion,and there were 74 cases through the EBUS-GS in 107 benign cases.The only adverse event was mild pneumothorax in a patient.

Conclusion: The overall diagnostic yield was can be obtained in approximately three-quarters of evaluable patients with VBN.After 1 month of follow-up,the diagnostic yield of malignant lesion was higher than the benign lesion for PPLs.Benign lesions are difficult to diagnose due to the complicated etiology.Sometimes need to combine a variety of technologies, such sa tuberculosis patients , through bronchoalveolar lavage to bacteria culture, pathology or XpertMTB/RIF and other technology comprehensive diagnosis.Further multi-center randomized study may be desired.

PO-182

A simplified technique for self-expandable metallic Y-shaped airway stent deployment without use of rigid bronchoscope and fluoroscopic guidance

Guo,Shuliang、Liu,Xinzhu、Li,Yishi、Xiao,Yang、Xiao,Meiling、Jin,Xingxing
The First Affiliated Hospital of Chongqing Medical University

Objective: Self-expanding metallic Y-shaped airway stents（SEMYS）are frequently used for airway stenosis and fistulae caused by thoracic neoplasm. The standard deployment procedure of SEMYS requires rigid bronchoscopy and fluoroscopy, which are not widely accessible in less privileged areas.

Methods: We have developed a new technique for SEMYS deployment with moderate sedation, under flexible bronchoscopy and without fluoroscopic guidance. An 8 internal diameter endotracheal tube (ETT) is used to secure the airway and to guide the delivery system through the curves around the glottis. The ETT is cut open lengthwise in advance except its distal tip is kept intact. After intubation with the modified ETT, the guide wire is inserted through the

ETT, and a flexible bronchoscope is inserted beside the ETT, and subsequently the delivery system is advanced along the guide wire all the way to the carina and deployed under broncoscopic monitor.

Results: By the time of submission, we have completed 17 cases of SEMYS deployment in this method with no major complications.

Conclusion: This technique, safe, simple and swift, improves accessibility of SEMYS in less privileged areas.

PO-183

Comparison in efficacy and safety of forceps biopsy for peripheral lung lesions guided by endobronchial ultrasound-guided sheath (EBUS-GS) and electromagnetic navigation bronchoscopy combined with EBUS (ENB-EBUS)

Ma,Lijie1,2、Fang,Yanfeng2、Zhang,Tingxiu1、Xue,Peini2、Bo,Liyan2、Liu,Wei2、Zhang,Tao2、Jin,Faguang2、马李杰
1. General Hospital of Western Theater Command
2. Tangdu Hospital, Air Force Military Medical University

Objective: Adoption of less invasive methods to diagnose space-occupying diseases of the lung is of significant benefit for those patients with advanced lung cancer. This study retrospectively summarized the case data of two diagnostic methods: endobronchial ultrasound-guided sheath (EBUS-GS) and electromagnetic navigation bronchoscopy combined with EBUS (ENB-EBUS), both performed at the respiratory endoscopy center of Tangdu Hospital, and the study investigated the diagnostic efficacy and complications of these two methods.

Methods: This single-center, retrospective clinical study enrolled 109 patients including 61 males and 48 females. The study was approved by the ethics committee of the Tangdu Hospital affiliated to the Air Force Military Medical University, and was registered in the Chinese Clinical Trial Registry (ChiCTR) (registration number ChiCTR1900023937). The diagnostic accuracy, specificity, sensitivity and complication rate of EBUS-GS and ENB-EBUS were evaluated.

Results: The study included 93 patients who underwent EBUS-GS and 26 who underwent ENB-EBUS. The diagnostic rates of EBUS-GS and ENB-EBUS were 71.1% and 65.4%, respectively, with no statistical difference (P=0.581). Furthermore, 89.2% of patients in the EBUS-GS group were diagnosed with malignant disease, which was significantly higher than 23.5% diagnosed with malignant disease in the ENB-EBUS group (P=0.00). An analysis of the factors influencing the diagnosis rate showed that the diagnosis rate of EBUS-GS in cases with bronchial signs was 82.5%, which was significantly higher than the 42.9% in the cases in the ENB-EBUS group with bronchial signs ($P<0.05$). There was no difference between the diagnostic rate of the two in terms of the length and distance of the lesions. The distance from lesion to the pleura had no significant effect on the diagnostic rate of the two groups. An analysis of the complications showed that the incidence of complications in the EBUS-GS group was 8.4%, and the incidence of complications in the ENB-EBUS group was 3.8%, with no statistical difference ($P> 0.05$).

Conclusion: These findings indicted that both EBUS-GS and ENB-EBUS can be used for the diagnosis of peripheral pulmonary disease. However, the diagnostic rate of EBUS-GS is significantly higher than ENB-EBUS in cases with bronchial signs associated with the lesion, and the diagnostic rate of ENB-EBUS in cases with no bronchial signs was higher than that of EBUS-GS with no statistical difference.

PO-184

Application and potential of 3D printing for stent implantation in tracheal stenosis

Xu,Zhixiao、Ye,Min、Lin,Xiaoxiao、Chen,Chengshui
The First Affiliated Hospital of Wenzhou Medical University

Objective: In the past few decades, 3D printing technology has developed rapidly, and it has been applied in many different fields. The use of 3D printing has been reported in many literature on airway surgery. This study aims to describe the use of 3D printed airway models to describe the application of tracheal stenosis in stent implantation, and to discuss the potential applications of 3D printed models.

Methods: We load the results obtained after CT scanning in the form of DICOM file into the 3D data visualization software AMIRA (Fig.1-A), and build a 3D model on the basis of the 2-dimensional images from 3 planes (axial, coronal, and sagittal) 1,2. Once the 3D-model is created, it is smoothed to remove the rough outer edges(Fig.1-B). Then the model which is soild is exported as a STL file.and loaded into the ICEM CFD 16.0 to separate the geometry into the INLET and BODY1. By deleting the INLET parts, we can get a hollow bronchial model(Fig.1-C).We export the STL file of the final model and transfer it to 3D printer for printing(Fig.1-D). The model can be used to evaluate tracheal stenosis before stent implantation and to select suitable stent to to fit the patient.

Results: Three-dimensional printing was performed in one case of tracheal stenosis. A suitable metal stent was selected to place on the patient.

Conclusion: Through the 3D model, Individual recommendations can be provided when we choose stent to place in patient’s airway. For complex tracheal stenosis, the 3D model can help us assess the airway condition before operation. These 3D model provides visual tools when discussing stent implantation with family members.

PO-185

Effective Comparison on Rapid-, and Standard Pleurodesis Procedure Results to Malignant Pleural Effusion Patients

MARHANA,ISNIN、Wahyudi,Andri
Dr. Soetomo Hospital Surabaya

Objective: The end state of NSCLC related to the remote metastasis, and the occurrence of malignant pleural effusion (MPE) in about 25-50% lung cancer complication. Some techniques that applicable to palliative therapy of out-of-breath symptoms related to malignant pleural effusion are: (1) repeated thoracentesis, (2) pleurodesis, and (3) tunneled pleural catheters (TPC) implantation. However, no significant ideal modalities were found from all of those techniques, because the modalities still required repeated procedures, continuous inpatient days, or long term catheters drainage. Rapid pleurodesis is a pleurodesis treatment with sclerosis agent through a thoracic drain after the evacuation, verified by the expanded, non-trapped lung photo thorax. This research aims to recognize whether such rapid- and standard procedure pleurodesis are equally useful to treat those malignant pleural effusion patients.

Methods: This research is an experimental study with the randomized posttest only control group research design. Samples of this research were all inpatient patients in Dr. Soetomo hospital due to malignant pleural effusion with pleurodesis treatment and qualified to sample selection criteria. Samples would be divided into two groups, namely of standard procedure-, an rapid-pleurodesis, and to be evaluated one month after the treatment. Statistical analysis was conducted using Mann Whitney analysis test to estimate the comparisons between variable.

Results: Total subjects involved in this study were 25 MPE patients. In standard procedure pleurodesis group, there were a total of 9 patients with success pleurodesis category (81.81%); 2 (18.18%) with failed pleurodesis category and one was not evaluated. While in rapid pleurodesis group, there were 10 patients with success pleurodesis category (90.9%), 1 with failed pleurodesis category, and 2 were not evaluated. P-value is 0.300 (p>0,05). Pain and fever experienced as complications in this study. The long term effect after pleurodesis has not been considered.

Conclusion: There is no marked different outcome between rapid pleurodesis and standard procedure pleurodesis in MPE patients.

PO-186
A lung model simulating respiratory movement

Chen,Chengshui、Xu,Zhixiao、Lin,Xiaoxiao、Ye,Min
The First Affiliated Hospital of Wenzhou Medical University

Objective: With the rapid development of bronchology and interventional pulmonology, many doctors participate in it, but the model which can simulate the normal and pathological condition of lung has not been established. Our research aims to establish a model that can simulate the respiratory movement and some pathological states of the lung and, hoping to benefit the students in the study of bronchoscopy.

Methods: First of all, we design a chest shaped lung box that meets the requirements, and print it with 3D printing technology(Fig.1-A). We use this lung box to hold a fresh pig lung without air leakage, which is similar to human lung and can be operated by tracheoscope. At the same time, it is important to ensure that the lung box is well sealed. Second, the water column pressure in the water-sealed bottle is the primary condition for generating negative pressure(Fig.1-B1). We then connect the negative pressure pump outside the lung box to strengthen the negative pressure, which can be adjusted to -1.5~ -1.0kpa(Fig.1-B2). Through these measures, the negative pressure in the lung box can be maintained. Third, we use two 350ml needles, linear guide rail and other accessories to assemble the device to simulate the contraction and relaxation of diaphragm. The control system is set up, which can adjust frequency, rhythm and speed,to simulate the different activities of diaphragm(Fig.1-C).

Results: We build a model that simulates respiratory movement and use a pig lung, and these designs give people a sense of reality.

Conclusion: This lung model can simulate different tidal volume, respiratory rate and other conditions, and can also simulate some pathologic conditions like pneumothorax. We hope to use this model to provide students with pathological and physiological conditions to help them learn.In the future, we hope to establish the blood circulation system of lung model.

PO-187

Clinical effect of different anesthesia modes of ultrasound bronchoneedle aspiration biopsy

Zhan,Xianghui、Xiao,Jianhong、Peng,Jinyun、Song, bin
Mindong hospital, Ningde

Objective: To compare the clinical effect of local anesthesia with conscious sedation and general anesthesia (intravenous anesthesia combined with laryngeal mask) in transbronchial needle aspiration biopsy (EBUS-TBNA) guided by endobronchial ultrasound, and to explore and select the most appropriate anesthesia.

Methods: From March 2017 to March 2019, 80 patients with EBUS-TBNA were randomly divided into conscious sedation group (group A) and general anesthesia group (group B). The general anesthesia group was anesthetized by intravenous anesthesia combined with laryngeal mask, and the local anesthesia group was anesthetized by conventional lidocaine local anesthesia with midazolam 0.6mg/kg+ sufentanil citrate injection 0.1ug/kg. The differences of diagnosis rate, operation time, and oxygen status of finger pulse during operation between the two groups were analyzed retrospectively.

Results: The diagnosis rate was 85% in general anesthesia group and 70% in conscious sedation group.There was no significant difference between the two groups (χ 2 = 2.58, P > 0.05）.The average operation time of general anesthesia group was (20.45 ± 2.02) min, the conscious sedation group was (28.90 ± 2.39) min, they had significant difference (t = 16.71, P < 0.05).The mean finger pulse oxygen during operation in general anesthesia group was higher than that in conscious sedation group (t = 10.40, P < 0.05).

Conclusion: Compared with EBUS-TBNA operation under conscious sedation, there was no difference in the diagnosis rate of operation under general anesthesia, but the time was short, the patient's finger pulse oxygen was stable, and the operation risk was reduced, which is worth clinical promotion.

PO-188

Airway stent placement for malignant respiratory complications with esophageal cancer

Sata,Yuki、Nakajima,Takahiro、Uesato,Masaya、Yamamoto,Takayoshi、Tanaka,Kazuhisa、Sakairi,Yuichi、Wada,Hironobu、Suzuki,Hidemi、Toyozumi,Takeshi、Murakami,Kentaro、Matsubara,Hisahiro、Yoshino,Ichiro
Chiba University Graduate School of Medicine

Objective: Airway constriction and esophago-respiratory tract fistula associated with advanced esophageal cancer are serious complications and have a poor prognosis. Bronchial stent placement is an effective treatment for airway lesions to reduce respiratory symptoms. This retrospective study aimed to evaluate the efficacy and safety of airway stenting in esophageal cancer patients with malignant airway lesions.

Methods: We retrospectively reviewed the medical records of 21 patients (19 men, 2 women) who underwent airway stenting between January 2009 and January 2019. The mean age was 63.7 years (range 49-78 years). All of them had esophageal cancer with airway lesions, and airway stent placement was performed. Indications for stent placement included direct airway invasion, esophago-respiratory tract fistula and extrinsic compression. Airway stent placement was performed when the patient prognosis and the symptoms caused by airway lesions were expected to improve consequently. All patients who received stent placement had too severe a condition to tolerate surgery.

Results: There were 6 cases of airway stenosis and 15 cases of airway esophageal fistula. The causes of 21

were therapeutic complications in 16 cases (11 of which were irradiated) and esophageal cancer progression without treatment in 5 cases. Airway stenting was successful in 21 cases (90.4%). There were 15 patients (71.4%) whose subjective symptoms improved after treatment. The overall survival from the day of airway stenting was 5.6 months. The patients who underwent chemotherapy after the intervention had a significantly better prognosis than those who received best supportive care. The median survival was 8.6 months for the chemotherapy group and 1.1 months for the best supportive care group (p = 0.01). Complications were observed in 7 cases (33.3%), including 3 cases of lung hemoptysis or hematemesis, 2 cases of fistula recurrence, 1 case of bronchial pericardial perforation and 1 case of mediastinitis.

Conclusion: Although airway stenting for advanced esophageal cancer with airway complications often made it difficult to manage the physical condition after the intervention, it effectively improved symptoms and the prognosis in patients who were able to receive chemotherapy. However, close attention must be paid after the intervention in order to catch fatal complications.

PO-189

The efficacy of the real-time spectrum analysis of endobronchial ultrasound radiofrequency of lymph nodes during endobronchial ultrasound-guided transbronchial needle aspiration in patients with lung cancer

NAKAJIMA,TAKAHIRO、Yamamoto,Takayoshi、Sata,Yuki、Inage,Terunaga、Shiina,Yuki、Tanaka,Kazuhisa、Sakairi,Yuichi、Wada,Hironobu、Suzuki,Hidemi、Yoshino,Ichiro

Chiba University Graduate School of Medicine

Objective: The classification of ultrasonographic features of mediastinal lymph nodes during endobronchial ultrasound-guided transbronchial needle aspiration (EBUS-TBNA) can be used to predict malignant and benign diagnoses by well-experienced physicians. However, this subjective categorization might limit the interobserver agreement and reproducibility. We reported the high predictive ability of nodal metastasis by measuring unique ultrasonic spectrum features, especially the combination of "intercept (dB/MHz) and slope (dB)." The spectrum analysis of endobronchial ultrasound radiofrequency involves the objective measurement of the ultrasonic spectral parameters. We conducted a prospective trial to assess the utility of a spectrum analysis during EBUS-TBNA using a real-time spectrum analysis ultrasound scanner.

Methods: Between April 2017 and March 2018, patients who underwent EBUS-TBNA and were diagnosed with or suspected of having lung cancer were prospectively enrolled in this study. A dedicated ultrasound scanner (EU-Y0005; Olympus, Tokyo, Japan), which was capable of the real-time measurement of "intercept (dB)" of the region of interest (tissue spectrum mode: TS mode), was used in this study. During the initial observation and recording of the targeted lymph nodes before TBNA, the targeted lymph nodes' "intercept" value was measured and recorded. While concealing the information on the "intercept" (cut-off value: 0.6 dB) from the operator, TBNA for the targeted lymph nodes was performed with a rapid on-site evaluation. An independent physician then compared the results of the "intercept" judgment and the pathological diagnosis (UMIN prospective trial ID: UMIN000026934).

Results : A total of 97 cases (72 males and 25 females) with 183 lymph nodes (mean size: 9.87 mm [range: 3.0-26.8 mm]) were evaluated and analyzed. The prevalence of malignant lymph nodes was 36.6% (67/183). The mean size of malignant lymph nodes was 12.59 mm (range: 4.5-26.8 mm), and that of benign lymph nodes was 7.66 mm (range: 3.0-22.5 mm). The diagnostic yield of the TS mode, real-time "intercept" classifiers, was as follows: sensitivity 85.1%, specificity 76.7%, positive predictive value 67.9%, negative predictive value 89.9%, and diagnostic accuracy 79.7%.

Conclusion: By the use of the TS mode, we could predict negative lymph nodes with approximately 90% accuracy. This technology may support the development of the automated real-time evaluation of targeted lymph nodes, which may reduce unnecessary biopsies and shorten the examination time even for non-experts.

PO-190

Strategy of fasting and abstinence in preschool children during perioperative period of bronchoscopy

Jia,Xiaohui、Zhang,Shuanghong、Hu,Shidong、Zhang,Liping
The 2nd affiliated hospital and Yuying children's hospital of Wenzhou Medical University

Objective: According to the guidelines of ERAS, fasting time is generally 8 hours of solid, 6 hours of milk, 4 hours of breast milk, 2 hours of clear drink before operative, and fasting 2 hours after operative. For preschoolers, fasting and no drinking can cause a variety of discomfort, risk of hypoglycemia and emotional instability, which has a great impact on the physical and mental health of children and their families. Therefore, it is important to find the best time to fast and drink in preschool children with security, so as to improve the comfort of perioperative period.

Methods: The latest guidelines pointed out that most of children's stomach emptied in 30 minutes after drinking clear drinks. APAGBI, the European Society of Pediatric Anesthetists and the French-Language Society of Paediatric Anaesthesiologists issued a joint statement, which encourages clear fluids to be given up to 1 h before elective general anaesthesia. There were 126 preschoolers underwent bronchoscopy under elective general anesthesia. They were randomly divided into experimental group (n=63) and control group (n=63). The experimental group began to fast after taking 3ml/kg of clear drink 1 hour before the operation, and drank clear drink immediately after the anesthesia awake. The control group was routinely prohibited from drinking for 2 hours before the operation and no drink 2 hours after the operation. The crying and emotional scores, hunger level, intraoperative safety, postoperative cough, vomiting and family satisfaction of the 2 groups were observed.

Results: In the experimental group, childre’s emotional scores were lower than those in the the control group($P<0.05$). The satisfaction of family members in the experimental group was higher than that in the control group ($P<0.05$). In terms of intraoperative safety, postoperative nausea and vomiting and other adverse reactions, postoperative cough and choking, there was no statistically significant difference between the two groups.

Conclusion: It is safe to take 3ml/kg of clear drink 1 hour before the operation, and drank clear drink immediately after the anesthesia awake for preschoolers who undergo bronchoscopy under elective general anesthesia. Shorter time of abstinence and fasting can be alleviated the patient's bad mood, feeling of hunger and improve satisfaction.

PO-191

Performance of bronchoscopic fiducial marker localization of pulmonary nodule: a feasibility study in porcine model

Chen,Junxiang1,2、Zheng,Xiaoxuan1,2、Yuan,Haibin1,2、Sun,Jiayuan1,2
1. Shanghai Chest Hospital, Shanghai Jiao Tong University, Shanghai, China
2. Shanghai Engineering Research Center of Respiratory Endoscopy, Shanghai, China

Objective: To evaluate the efficacy and safety of bronchoscopic placement of a new fiducial marker for preoperative pulmonary nodule localization.

Methods: Three healthy domestic swine were selected. Twelve pulmonary nodules were simulated by injecting mixed lipiodol into the upper and lower lobe of the bilateral lungs respectively. CT scan was performed one week later to evaluate the stability and visualization of the simulated nodules, then under the guidance of virtual bronchoscopic navigation, two fiducial markers were implanted into the nearby bronchi for each nodule with X-ray confirmation. CT scans were performed 1 day, 1 week, 2 weeks, and 4 weeks post-procedurally to verify the position of fiducial markers and complications. Wedge resection of simulated nodules was performed under fluoroscopy after the final CT scanning, after that animals were euthanized. The precision of the fiducial marker localization and associated complications were evaluated.

Results: The mean diameter of the 12 simulated nodules is 9.55±2.36 mm, and the mean distance from the pleura is 8.29±2.99 mm. Each nodule was implanted with 2 fiducial markers, and a total of 24 fiducial markers were implanted. CT scans confirmed that all markers were precisely implanted in the bronchi around the simulated nodules one day after the implantation, which was taken as baseline to evaluate marker migration. Four weeks after implantation, the mean migration of the marker relative to the nodule center was 3.48±4.56 mm, which 0-5 mm accounted for 87.5% (21/24), 5-10 mm accounted for 8.33% (2/24), and>10 mm accounted for 4.17% (1/24). The localization success rate was 100%. Fiducial markers can assist in determining the location of all nodules and guide the successful removal of them. The markers and nodules were located in the same tissue specimen which allowed quickly identify nodules in vitro. Resection success rate was 100%. No complications such as pneumothorax and bleeding were observed during fiducial marker implantation and follow-up.

Conclusion: This new fiducial marker can be accurately and safely by bronchoscopy, and remains stable throughout the follow-up. This fiducial marker can effectively assist the localization of pulmonary nodule before surgery, and showed promising potential in clinical application.

PO-192

Endobronchial hamartoma: a case report and literature review

Cai,Cunliang1、Yao,Jingjing2、Zhao,Jingquan1、Mu,Xiangdong1、Cunliang Cai
1. Department of respiratory and critical care medicine, Beijing Tsinghua Changgung hospital, Tshinghua University
2. Department of pathology, Beijing Tsinghua Changgung hospital, Tsinghua University

Objective: To emphasis the understanding of the diagnosis and treatment of the disease by sharing a rare case of intrabronchial hamartoma.

Methods: We present a case of patient with endobronchial hamartoma. The epidemiology, clinical symptoms, diagnosis, treatment, and prognosis of patients with endobronchial hamartomas were discussed.

Results: The patient were admitted to our ward with chronic cough suspected for lung cancer on computed tomography (CT) scan of the chest. Bronchoscopy biopsy of the mass were obtained and revealed benign lesions consistent with hamartoma. With laser and carbon dioxide cryoablation we removed the majority of the mass by repeat bronchoscopy. It was found that the mass grew from the medial segment of the right middle lobe. Complete open of the lateral segment was achieved after the procedure, and the medial segment partially reopened. The results of pathological examination showed that the tumor was composed of epithelium, fibers, cartilage and adipose tissue. There were fibrous tissue hyperplasia, edema with mucus degeneration, and enveloping adipose tissue and cartilage tissue partly covered with ciliated columnar cells. No malignant cells were found. Therefor the lesion was diagnosed as a lung hamartoma. The patient's symptoms were eventually resolved and no hemoptysis was reported on one month follow-up.

Conclusion: We describe an unusual case of endobronchial hamartoma successfully debulked under interventional bronchoscopy. Endoscopic intervention appear to be safe and effective therapeutic option for selected cases. The difficulty of pathological diagnosis lies in the need to carefully identify whether malignant components are incorporated. Regular follow-up is needed, but the interval and frequency of follow-up are yet to be explore.

PO-193

Tuberculosis and lung cancer - similarities and differences

Simon,Marioara1、Harangus,Antonia1、Simon,Ioan2
1. Pulmonology Clinic, Cluj-Napoca, Romania
2. University of Medicine and Pharmacy, Cluj-Napoca, Romania

Objective: Lung cancer (LC) has been recognized as one of the greatest common cancers, causing the annual mortality rate of about 1.2 million people in the world. LC is the most prevalent cancer in men and the third-most common cancer among women (after breast and digestive cancers). Tuberculosis (TB) is one of the important mortality factors throughout the world, and 205.000 death cases are reported annually due to this disease. Our purpose is to outlines the differences and similarities between TB and LC , that have the infaust prognostic without specific treatment.

Methods: Recent evidences have shown the inflammatory process as one of the potential factors of cancer. TB, pneumonia, and chronic bronchitis are among the most important inflammation-inducing factors in the lungs. It is assumed that TB is one of the risk factors for cancer. Numerous studies have been conducted in this regard throughout the world and it has been observed that there is a significant relationship between previous TB infection and lung cancer.

Results: One of the main challenges of lung cancer is its correct and timely diagnosis. Unfortunately, clinical symptoms (such as continuous cough, hemoptysis, weight loss, fever, chest pain, dyspnea, and loss of appetite) and

radiological images are similar in TB and lung cancer and the differential diagnosis of these diseases is important. Regarding the similarity in clinical symptoms and radiological findings of lung cancer and TB a proper diagnosis is important. There are also a lot of differences between LC and TB.

Conclusion: TB is a challenge in lung cancer diagnosis and management.Patients with lung cancer are often misdiagnosed as pulmonary tuberculosis leading to delay in the correct diagnosis as well as exposure to inappropriate medication.

PO-194

Ultrathin Bronchoscope Improves Diagnostic Yield in Small Size Lung Lesions

Sadoughi,Ali、Schecter,David
Albert Einstein College of Medicine/ Montefiore Medical Center

Objective: Different technologies are in development to increase diagnostic yield of bronchoscopy for peripheral lung lesions. Thin bronchoscope with radial endobronchial ultrasound (rEBUS) has a good diagnostic yield for lesions >2 cm in diameter, however smaller size lesions are challenging. Ultrathin bronchoscope improves visualization of small caliber peripheral airways.

Methods: In our routine practice in a major academic center we use thin bronchoscope [4.2 mm outer tip diameter (OD)] with rEBUS under fluoroscopy surveillance for lesions as small as 10 mm in diameter. In this study we switched to ultrathin bronchoscope [3.0 mm OD] when the lesion was not found, or the rEBUS view was eccentric (rEBUS probe adjacent to the target), and/or the tip of the scope was not close enough to the lesion to provide a reliable pathway for multiple sampling attempts. Minimal sampling included 3 needle aspirations and 3 forceps biopsies. The primary outcome was improvement in rEBUS view and detection of target. Concentric (rEBUS probe inside the target) view by rEBUS is an objective measurement which has been numerously reported to be associated with increased diagnostic yield. Secondary outcome was achievement of a definite diagnosis. The longest axial diameter of the lesion in most recent imaging, the distance of the center of the lesion to the closest parietal pleura and rate of pneumothorax or any other major complication were recorded.

Results: 21 patients from 3/2019 to 10/2019 (plus 1 patient in 8/2018-the ultrathin scope was not available in between) were eligible for this study. The mean of the longest diameter is 19 mm and the median is 16 mm, with range of 7 to 40 mm. The mean of the distance from parietal pleura is 15 mm. In 19 out of 20 patients, eccentric view was changed to concentric, and in one other patient the nodule which was not found by thin scope was detected by ultrathin scope (95% success in primary outcome). A diagnosis was confirmed in 18 out of 21 patients (86% success in secondary outcome), and 15 malignant disease was confirmed. There was only one patient with pneumothorax post procedure, and there was no other major complication.

Conclusion: Ultrathin bronchoscope along with rEBUS imaging, a relatively inexpensive technology, improved peripheral airway bronchoscopy for better localization of small and hard to reach lung lesions, led to increased diagnostic yield. Larger and comparison studies are needed to evaluate its utility in diagnosis of small size lung lesions.

PO-195

Bronchoscopic electroresection of a mucoepidermoid carcinoma - case report

Harangus,Antonia1、Simon,Marioara1、Simon,Ioan1,2
1. Pneumology Clinic, Cluj-Napoca, Romania
2. University of Medicine and Pharmacy, Cluj-Napoca, Romania

Objective: Electrocautery and electrosurgical snaring can be effective alternatives in the bronchoscopic treatment of endobronchial masses. The aim of this case presentation is to underline the utility of electroresection in endobronchial tumors.

Methods: We would like to present a case of electrosurgical resection of an endobronchial mucoepidermoid carcinoma.

Results: We present the case of 51-year-old women, with a history of asthma, who presented with dyspnea and mild posterior thoracic pain. On clinical evaluation, she had diminished right basal breath sounds. Spirometry showed a mixed moderate obstructive and restrictive ventilatory impairment. Evaluation by computer tomography revealed a well-defined 1,4x2cm mass on the main right bronchus. The bronchoscopy showed right main bronchus obstruction by a round, smooth tumor. Multiple samples taken during bronchoscopy showed no concrete sign of malignancy. The flexible bronchoscopy was repeated with complete electroresection of the tumor using an electrosurgical snare. The procedure caused mild bleeding that was stopped by electrocauterization. The final histopathologic examination revealed a low-grade mucoepidermoid carcinoma, mentioning a complete resection with margins free of tumor. The patient was referred to an oncologist and evaluated by PET-CT with no pathologic findings. The patient has been followed-up with no signs of remission.

Conclusion: Mucoepidermoid carcinoma is a rare finding in everyday bronchology practice. It represents a type of salivary gland-type carcinoma and tends to occur in younger patients, affecting the central parts of the airways. In our case, the differential diagnosis included hamartoma or a carcinoid tumor, because of its well-defined shape seen at bronchoscopy. The decision for electroresection was taken together with the surgeon, the other option being total right pneumectomy, since the tumor’s broad base was located on the medial wall of right main bronchus, at its division in bronchus intermedius and superior right bronchus. Endoscopic tumor removal is considered the treatment of choice to improve respiratory status. Electrocautery and electrosurgical snaring may be effective alternatives in the bronchoscopic treatment of endobronchial masses.

PO-196

Molecular testing on cryobiopsy versus conventional biopsy in NSCLC

Simon,Marioara1、Harangus,Antonia 1、Simon,Ioan2
1. Pulmonology Clinic, Cluj-Napoca, Romania
2. University of Medicine and Pharmacy, Cluj-Napoca, Romania

Objective: Forceps biopsy is the standard bronchoscopic approach for endobronchial lesions. Endobronchial cryobiopsy provides larger specimens with less crush artifacts and increase diagnostic yield in lung cancer diagnostic. The purpose of our study is to evaluate the utility of cryobiopsy in the initial diagnosis of lung cancer and to determine its yield and utility for molecular testing in NSCLC.

Methods: A prospective, comparative study between endobronchial conventional biopsies and cryobiopsies was conducted at Bronchoscopy Department of Cluj-Napoca, Romania Pulmonology Clinic. The examinations were carried

out under local anesthesia and moderate sedation. Patients with a suspicion of lung cancer with visible endobronchial tumors were selected and conventional forceps biopsy and cryobiopsy were both performed. Cryobiopsy via flexible bronchoscopy was performed using 1.9 mm cryoprobe. Data was collected on baseline patient demographics, number of biopsies, complications, final histology and molecular markers.

Results: From the total number of 36 patients we obtained diagnosis of non small cell lung carcinoma NSCLC in 28 cases both in forceps biopsies and cryobiopsies. Small cell lung carcinoma (SCLC) was diagnosed in 8 patients. Mean age was 60 years, with 64% male, 36% female patients. The mean number of biopsies was 2 cryobiopsies and 5 forceps biopsy specimens. The cryobiopsy samples were larger than those using forceps. All the NSCLC specimens were referred for molecular testing and both forceps biopsy and cryobiopsy provided enough tissues for molecular testing, but cryobiopsy samples had excellent tissue preservation and were free of artifacts. The EGFR and ALK testing had comparable results but regarding the PD-L1 testing we obtained the same results, but the level of PD-L1 expression was higher in cryobiopsy specimens than in forceps biopsy samples. Complications of cryobiopsy were mild bleeding in 64.2% cases and moderate bleeding in 35.7%, higher than with forceps biopsy.

Conclusion: Cryobiopsy is a valuable method in the diagnosis and molecular testing of NSCLC and provides larger volume and better preservation of tissue, with higher level of PD-L1 expression than traditional forceps biopsy and may therefore improve the diagnosis in lung cancer.

PO-197

Core Mediastinal Lymph Node Biopsy with Transbronchial Forceps – Experience of a Tertiary Care Center

Crutu,Adrian1、Ghigna,Maria Rosa1、Hanna,Amir1、Feuillet,Severine1、Florea,Valentina1、Mercier,Olaf1,2、Baldeyrou,Pierre1、Fadel,Elie1,2
1. Hopital Marie Lannelongue
2. Universite Paris Sud

Objective: Endobronchial ultrasound-guided transbronchial needle aspiration (EBUS-TBNA) is a well-established technique for sampling mediastinal or hilar lymph nodes with high diagnostic yields in lung cancer. However, EBUS-TBNA fails to provide robust histopathological evaluation of the lymph node architecture, cellular composition and growth pattern in lymphoma or sarcoidosis cases. We therefore evaluate the contribution of transbronchial forceps (TBF) to the improvement of the quality of tissue sample in a series of thoracic lymph nodes.

Methods: In this paper, we report the experience with a transbronchial forceps in the bioptical approach to mediastinal masses suspected to be a lymphoma or sarcoidosis. 14 consecutive cases of EBUS-TBNA associated with EBUS-TBF in the same lymph nodes were analyzed.

Results: 14 patients (11 males, 3 females; mean age 57y) with enlarged mediastinal lymph nodes were included in this analysis. The 4R station was biopsied in 14.2% of cases and the 7 station in 85.8% of cases. In 3 patients (21.4%) TBF could not be inserted through the bronchial wall. In the cases where both procedures could be performed (TBNA and TBF), TBF provided better tissue samples for histological diagnosis (in terms of cellular density, presence of tissue micro fragments, degree of contamination) in 10 out of 11 patients (90.9%). A diagnosis was obtained using TBF in 7 cases (70%) (lymphoma in 2 and sarcoidosis in 5). No significant procedure-related complications were encountered.

Conclusion: In our experience, TBF safely provides diagnostic histologic specimens of mediastinal lymph nodes, with better tissue sample quality than TBNA. In selected cases of mediastinal diseases such as lymphoma and sarcoidosis, transbronchial forceps core biopsy could be considered a safe and valid diagnostic technique and maybe an alternative one to more invasive surgical approach. Prospective studies are needed.

PO-198

Indications for performing flexible bronchoscopy in low income countries: Sudan an example

Elhag,Omer
Alneelain university

Objective: Due to easy performing, patients comfort and documented safety as an outpatient procedure flexible bronchoscopy has had replaced rigid bronchoscopy, here we reported our 10 years experience at Shaab teaching hospital –Khartoum-Sudan as an example of low income country

Methods: MATERIAL-METHOD: This was retrospective study of all patients underwent FOB between 2006 and 2016 in tertiary care hospital, demographic data and indications of FOB, and annual trend were studied from medical records

Results: A total of 456 bronchoscopies were performed during this period, majority of patients (42%)are of age group more than 60 years, male to female ratio of 1,2:1,there is increase of number of bronchoscopy performed from 19 cases in 2006 to 70 cases 1n 2016 an absolute increase of 368%, the most common indication for FOB was suspected carcinoma of bronchus –lung mass on chest Xray and chest CT scan357 (78%) followed by hemoptesis 39(8%), pleural diseases 28(6%),lung collapse26 (5%) and Tuberculosis 5(1%),tracheal stenosis 1(0,2%) no deaths encountered during the study in patients undergoing Bronchocopy.

Conclusion: FOB is increasingly being performed in the diagnosis of respiratory disorders and is a safe outpatient procedure. Although bronchogenic carcinoma remains a common indication for performing FOB, benign conditions such as pulmonary infections like tuberculosis constitute important indications in the Sudan

PO-199

Safety and diagnostic yield of echobronchoscopy guided transvascular punction

Mohamed Choukri,Marwan1、Gim é nez Velando,Andr é s1、Izquierdo P é rez,Ainhoa1、Morales Garc í a,Andr é s Mauricio2、Fern á ndez-Navamuel Basozabal,Íker1、Alfayate S á nchez,Javier1、Flandes Aldeyturriaga,Javier1
1. Hospital Universitario Fundaci ó n Jim é nez D í az, Madrid, Spain
2. Hospital Universitario Dr. Jos é Eleuterio Gonz á lez, Monterrey, M é xico

Objective: Endoscopic puncture techniques, both guided by echobronchoscopy (EBUS) and by echoendoscopy (EUS), have been established as an essential tool for the diagnosis of pulmonary and mediastinal lesions and lung cancer staging. Adenopathies located in stations 5 (aortopulmonary window) and 6 (para-aortic region) are usually inaccessible with this technique because they require crossing large vessels, and a surgical approach is often required by cervical mediastinoscopy or anterior mediastinotomy. Similarly, central parenchymal lesions may be located in regions that require going through medium or large caliber vessels for access. One of the possibilities to overcome this limitation, in high complexity centers, is the Transvascular Needle Aspiration puncture (TVNA). This has been proved to be a safe method, without complications added to those of the technique.

Methods: We performed a retrospective observational study of patients who underwent a TVNA in the course of usual clinical practice in our institution. Patient filliation and clinical information, location of the target lesion, diagnosis by EBUS / EUS-TVNA, the final diagnosis, complications, the validity of the sample (sufficient quantity and representative of the target lesion), the need for additional pathological studies , wether the pre-surgical or definitive pathological diagnosis was achieved by transvascular puncture or not, and other data was collected.

Results: We analyzed a total of 18 patients, mean age of 64.5 years, 72.2% males. 28% of the patients were

antiaggregated, while none were anticoagulated. The target lesion was a lymph node in 39% of cases, a pulmonary nodule in 33%, and a parenchymal mass in the rest of cases. The most frequently crossed vessel was the left pulmonary artery or its branches in 55% of cases ; the most frequent location was station 5, in case of adenopathies and the left and right lower lobes (33% each) in the case of nodules and masses. In 89% of the cases the procedure was performed via EBUS. The sample was valid in 67% of the cases, reaching a pathological diagnosis in 63.2% of the cases. In addition, in 39% of cases, the pathological diagnosis could only be achieved with the TVNA puncture. Two cases of mild self-limited bleeding were reported. There were no additional complications associated with the procedure.

Conclusion: According to our data, TVNA punction via EBUS or EUS is a safe procedure, without added complications, and with an acceptable diagnostic yield, avoiding much more aggressive approaches.

PO-200

Placement of Y-shaped silicone stent in rapid progressive malignant central airway stenosis: A case report

Liu,Nian、Chen,XiaoKe、Zhou,YiPing、Xia,LiPing、Chen,HaiQin、Lin,HaiRong、Cao,WenJuan
The Eighth Affiliated Hospital，SUN YAT-SEN University

Objective: Now we report a case of placement of a Y-shaped silicone stent following ablation in malignant central obstruction which grew rapidly in a short period of time. The patient was diagnosed with poorly differentiated adenocarcinoma, which grown rapidly. After repeated ablation, the airway was still obstructed. With placement of Y-shaped silicone stent, the patient was relieved from dyspnea, and his quality of life was apparently improved.

Methods: A 68-year-old male was admitted to the hospital for hemoptysis and dyspnea on Oct 5th, 2019. Blood Gas Analysis (FiO2：0.21): PH 7.45, PO2 54mmHg，PCO2 27mmHg. Chest CT showed masses among distal trachea, carina and the right main bronchus, right main bronchus completely blocked with a 29×22×28mm nodule in the right upper lung, and enlarged mediastinal and right hilar lymph nodes. Poorly differentiated adenocarcinoma was confirmed by pathologic diagnosis, with PD-L1 80% expression and no targeted gene mutation. Rigid bronchoscopy were performed on Oct 8th and found that the mass had completely obstructed the right main bronchus and nearly 50% of the proximal left main bronchus. By shovel cut, APC and cryoablation, the right main bronchus was recanalized. And patient’s symptoms improved significantly. However, 5 days later the patient suffered from dyspnea again. Flexible bronchoscopy under noninvasive ventilation were performed to improve dyspneawith APC and cryotherapy on Oct 18th. Rigid bronchoscopy was performed on Oct 23rd and showed mixed stenosis, 90% of the right main bronchus, 80% of the right middle bronchus and the left main bronchus was obstructed. After recanalization by shovel cut, APC and cryotherapy, a Y-shaped silicone stent (15-12-12, Tracheal 4cm, left branch 2.5cm, right branch 4cm, perforation on-site at the right branch for right upper lobe) was successfully implanted.

Results: The patient’s symptoms alleviated immediately，get out of bed the next day. Three days later, review of tracheoscope shows that the position of the stent was good. The patient discharged 5 days later. After that, the patients received regular " Keytruda 200mg" immunotherapy, with a total of 10 courses until June 18, 2020. Chest CT examination showed that the lesions were significantly reduced. At present, the patients are generally in good condition.

Conclusion: In China, due to the higher cost and rigid bronchoscopy support for placement of silicone stent, metallic stents are widely used in malignant central obstruction. With the prominent advantages of tumor targeting drugs and immunotherapy, the survival time of tumor patients is significantly longer than before. The long-term complications after the placement of metal stents cause more problems to patients, while the complications of silicone stents are less, and the patient's quality of life is improved.Hence, we suspect that silicone stent has a great future in the management of malignant central airway obstruction.

PO-201

Microbiology Result From Bronchial Washing Specimen via Fiberoptic Bronchoscopy From Patients With Pneumonia and Suspect Lung Cancer

Sugiri,Jani Jane Rosihaningsih1、Santoso,Agus Andreas2、Kurniawan,Kristo2、Musthafa,Muhamad Yusuf2、Haris,Abdul2
1. Saiful Anwar General Hospital, Malang, East Java, Indonesia / Faculty Medicine Brawijaya University
2. Resident of Pulmonology and Respiratory Medicine of Faculty Medicine Brawijaya University

Objective: Pneumonia is still an important cause of morbidity and mortality in immunocompromised state. Patients with lung cancer suffer frequent infections which will affect the survival. The type of bacterial pneumonia that develops in a cancer patient depends on several factors, including immunologic defect and whether the infection is community acquired or nosocomial. Diagnosis of pneumonia is based on history taking, clinical finding and confirmed by a chest X-ray. To establish an etiologic diagnosis of pneumonia, sputum culture was done. The last decade has witnessed the evolution of bronchoscopy from an experimental procedure to a diagnostic tool with important clinical applications. The aim of this study is to evaluate the result of microbiology culture from bronchial washing specimen taken via fiberoptic bronchoscopy from pneumonia patients with suspected of lung cancer.

Methods: Retrospective, observational studies, Bronchial specimens were cultured in microbiology laboratorium Saiful Anwar General Hospital. Totally 318 samples, eligible for inclusion and exclusion were 238 patients. We analyzed the results of microbiology culture examination of bronchial washing specimens

Results: Based on the data majority were men 69%, with an average age of 57 years. Bronchoscopy finding stenosis compressive (38%), intraluminal mass (16%), inflammation (24.5%), infiltrative (13.5%), normal (8%). Actions performed during bronchoscopy include 9% washing, 71% washing-brushing, 20% washing-brush-biopsy. The culture of the specimen yielded the most Klebsiella pneumoniae (38%) followed by Streptococcus mitis (28%), Candida albicans (24%), Staphylococcus aureus (21%), and Acinetobacter baumannii (21%).

Conclusion: Bronchoscopy for pneumonia patient with suspected of lung cancer, can assist to identification of bacteria that might be used to guide the choice of effective antibiotics for the treatment of pulmonary infections. Bronchoscopy is a very useful tool for diagnosing lower respiratory tract infections in immunocompetent and immunocompromised patients.

PO-202

The culprit of pulmonary lesion in a patient with myelodysplastic syndrome

Wang,Jiajia、Zhang,Xiaohui、Bao,Xiebing、Lei,Wei、Zhu,Yehan、Huang,Jian-an
The First Affiliated Hospital of Soochow University

Objective: Tuberculosis(TB), a well known mimicker of other diseases , is often a life-threatening complication in patients with hematologic malignancies. This study aimed to highlight the value of bronchoscopy combined with next generation sequencing (NGS) in the diagnosis of TB among hematologic patients.

Methods: -

Results: A 36-year-old male was admitted to our hospital on May 23, 2019 due to recurrent fever and chest tightness for two months. He was diagonsed as myelodysplastic syndrome (MDS) four months ago. The patient developed moderate fever since March 27 and was admitted to Hospital A. The chest CT scan on March 28

demonstrated enlarged mediastinal and hilar lymph nodes, accompanied with little opacity in right lung (Figure 1A). The co-administration of antibiotics was initiated for one week, but it didn't work. The chest CT scan on April 6 indicated no alleviation. The patient was tranfered to Hospital B. The PET-CT indicated enlarged mediastinal and hilar lymph nodes accompanied with significantly abnormal metabolic activity, then the malignancies were suspected. Bronchoscopy on April 17 and May 6 showed neoformation located in upper lobe of the right lung covering with white secretion, and anterior segment bronchus were obstructed by the neoformation. The pathologic results of specimen obtained through lung tissue and lymph node biopsy revealed chronic inflammation. The CT scan on May 10 indicated significantly opacity in right lung (Figure 1B). During hospitalization, the patient developed obvious cough and chest tightness. Finally, the patient visited our hospital and was admitted immediately due to the suspicion of TB. Bronchoscopy was performed on May 24 and the lesion showed the similar features as before (Figure 1C). Repeated secretion smears were negative, stunningly, the NGS detected the fragments of mycobacteria DNA and the pathological findings revealed granulomatous inflammation. Accordingly, the diagnosis of TB was considered and the anti-TB treatment was given. Seven days after anti-TB initiation, the patients's symptoms were obviously alleviated. The CT scan on June 5 showed the lesions were partly absorbed (Figure 1D). The patient was finally discharged on June 14. During the follow-up, the lesions were gradually dissolved through the continous anti-TB therapy (Figure 1E and F).

Conclusion: Patients with hematologic malignancies are often exposed to a high risk of tuberculosis. NGS, a high sensitive and specific technology for etiological detection, combined with bronchoscopy, could be benefical for early diagnosis and better treatment of TB in this special population.

PO-203

Assessment of the reliability of ultrasound to predict the tracheal wall pressure during intubation by measuring the tracheal diameter difference in a porcine model

Ye,Ran、Chen,Chengshui
The First Affiliated Hospital of Wenzhou Medical University

Objective: The aim of this study was to investigate the reliability of ultrasound in measuring the tracheal diameter. Furthermore, we tried to determine the tracheal wall pressure (TWP) based on the tracheal diameter difference measured by ultrasound during inflation.

Methods: Forty-five porcine tracheas were intubated with 8.0 mm cuffed ETT, which were connected to the injector and manometer through a three-way tap. We inflated the cuff and recorded the cuff pressure before and after intubation. During intubation, ultrasound was used to simultaneously measure the tracheal diameter, including the tracheal outer transverse diameter (OTD), tracheal internal transverse diameter (ITD), and anterior tracheal wall thicknesses (ATWT). Thereafter, a precision electronic vernier caliper (PEVC) was used to measure the tracheal diameter. The pressure difference technique was used to calculate the TWP. We calculated the percentage of change in tracheal diameter. Forty-five porcine tracheas were analyzed by the Bland-Altman analysis. Thereafter, four tracheas were excluded because of the excessively large diameter. Forty-one porcine tracheas were included in the next analysis, and we recorded 451 sets of measurements. The LOESS, the generalized estimating equation (GEE) model, and the general linear model were used to analyze the data.

Results: Based on the Bland–Altman analysis, we found good consistency in the tracheal diameter measured by ultrasound and PEVC (n=45). In this part, our results showed that ultrasonic measurement error was OTD (3.90%) less than that of ITD (9.73%) and ATWT (32.14%). Through LOESS, we found that the percentage of change in the outer transverse diameter (OTD%) and the percentage of change in the internal transverse diameter (ITD%) were approximately linear with the TWP (n=451). The equations relating TWP and a combination of tracheal diameter and cuff inflation volume (CIV) were estimated using the GEE: TWP=-0.5593-2.2535×OTD%+1.0556×CIV+0.5323×C

IV×OTD% (r=0.93259, p<0.0001);TWP=-0.4460-1.1014×ITD%+0.9460×CIV+0.3041×CIV×ITD%(r=0.92478, p<0.0001). The prediction results of both equations were significantly correlated with the raw value. Thereafter, the general linear regression equations was constructed that relating TWP to tracheal diameter on ultrasound: In(TWP+2) =1.4442In(OTD%+2)+0.0791 (adj.R2=0.8145, p<0.0001; In(TWP+2) = 1.1239In(ITD%+2)+ 0.2085(adj.R2=0.7301, p<0.0001). This result showed that OTD was better than ITD as an optimal indicator to predict the TWP.

Conclusion: In conclusion, we showed that ultrasound measurement of tracheal diameter was reliable, and the TWP could be predicted by measuring the tracheal diameter difference during cuff inflation. Additionally, OTD% can be used as an optimal indicator to predict the TWP. Our study showed the clinical potential of using ultrasound lower respiratory passageways.

PO-204

Curative effect of bronchoscopy-guided 125I seeds implantation combined with bronchial artery infusion chemotherapy embolization for advanced central squamous cell carcinoma of the lung

Lin,Hui、Xiao,Jianhong
Mindong Hospital of Fujian Medical University

Objective: To explore the curative effect and safety of bronchoscopy-guided radioactive 125I seeds implantation combination with bronchial artery infusion chemotherapy embolization for advanced central squamous cell carcinoma of the lung

Methods: Collection of 68 cases of advanced central squamous cell carcinoma of the lung patients (stage Ⅲ b~ Ⅳ) was treated in our department during the period from June 2016 to February 2019. The 68 patients with central squamous cell carcinoma of the lung (stage Ⅲ b~ Ⅳ) were randomly divided into two groups: bronchoscopy-guided 125I seeds implantation combined with bronchial artery infusion chemotherapy embolization group (experimental group, n=32) and pure bronchial artery infusion chemotherapy embolization group (control group, n=36), two groups were both accepted GP regimen (gemcitabine plus cisplatin) chemotherapy. And they were followed up by CT an EB examination after l, 3, 5 months. According to WHO unified standard to judge the efficacy and adverse effects.

Results: In the bronchoscopy-guided seeds implantation combined with chemotherapy group and the pure chemotherapy group, the response rate (complete response plus partial response) was 81.25% and 52.77%, respectively. There were significant differences in two groups (P<0.05). The incidence rate of hemoptysis in the experimental group was higher than that in the control group,with significant difference (P ＜ 0.05).There was no significant difference between the two groups in the incidence rate of pneumothorax，fever and bone marrow suppression (P ＞ 0.05).All adverse reactions were light and could be controlled.

Conclusion: It is better near-term clinical efficacy in the bronchoscopy-guided 125I seeds implantation combined with bronchial artery infusion chemotherapy embolization group. So, it is an safe and minimally invasive treatment for advanced central squamous cell carcinoma of the lung

PO-205

Comparison：of pleural cryobiopsy under medical thoracoscopy with conventional pleural biopsy

Zhang,Dexin、Yang,Shuanying、Zhang,Jie、Zhang,Yonghong、Xie,Mei
Department of Respiratory Medicine， Second Affiliated Hospital of Medical College， Xi’an Jiaotong University

Objective： To compare the difference between conventional thoracoscopy biopsy and frozen pleural biopsy in diagnosis of pleural disease.

Methods： Ten patients with pleural disease who underwent routine thoracoscopy biopsy undergraduate from January 2019 to November 2019 were set up as group A, and 8 patients who underwent thoracoscopy cryopleural biopsy were selected as group B. Positive rate of pathological diagnosis and postoperative complications in the two groups. Group A used conventional biopsy forceps to perform multi-point biopsy of the lesion on the parietal pleura; Group B used cryoprobes to perform multi-point frozen biopsy on the parietal pleura for 5 seconds. All specimens were fixed with 10% formaldehyde.

Results： Group A diagnosed 3 cases of tuberculosis, 2 cases of tumor, and 5 cases of chronic inflammation; group B diagnosed 4 cases of tuberculosis, 2 cases of tumor, and 2 cases of chronic inflammation. The positive rate of diagnosis in group B was significantly higher than that in group A, and the difference was statistically significant ($P < 0.05$). In group A, chest pain occurred in 1 patient, which was relieved after rest, and low fever in 1 patient. After symptomatic treatment, the body temperature dropped to normal. Chest pain occurred in 3 patients in group B after surgery, and alleviated after rest. No fever, and no other serious complications were seen in either. There was no significant difference in the incidence of complications between the two groups ($P > 0.05$).

Conclusion： The positive rate of thoracoscopy pleural cryobiopsy is higher than that of conventional pleural biopsy, and there is no significant difference in complications.

PO-206

Seven cases report about Tracheobronchial tuberculosis（lymph fistula）as a Complication after Endobronchial Ultrasound-Guided Transbronchial Needle Aspirationaspiration

luo,li
Hunan Chest Hospital

Objective： We presented seven cases of unusual endobronchial inflammatory polyps as a complication following endobronchial ultrasound-guided transbronchial needle aspiration (EBUS-TBNA) in patients with tuberculous lymphadenitis(2014-2019).

Methods： EBUS-TBNA of the 7 #, 4R, and 11R lymph node were performed，the patients were confirmed with tuberculous lymphadenitis and received antituberculosis medication. Endobronchial inflammatory polyps(six cases in 7 #, one case in 4R) were found following the EBUS-TBNA, histological examinations revealed chronic granulomatous inflammation, they were confirmed with Tracheobronchial tuberculosis（lymph fistula）;

Results： After bronchoscopic forceps and cryotherapy,the inflammatory polyps of six cases had reduced,one case had enlarged; the lymph nodes of five cases had decreased in size in comparison with the baseline CT.

Conclusion： EBUS-TBNA has been widely used for the evaluation of mediastinal and hilar lesions for several

reasons, such as its minimally invasive nature, high diagnostic accuracy, needle aspiration under real-time visualization and excellent safety profile. we need to consider the possibility of endobronchial inflammatory polyp as a complication after EBUS-TBNA in patients with tuberculous lymphadenitis and follow up with bronchoscopy after the examination.

PO-207

Analysis of airway repair time and related factors of ulceration necrosis tracheobronchial tuberculosis

luo,li
Hunan Chest Hospital

Objective: Ulceration necrosis tracheobronchial tuberculosis (subtype II) is the focus and difficulty of interventional treatment for tuberculosis,taking the disappearance time of airway necrosis and repair time of airway scar stenosis as the entry points to analyze relevant factors, it may be providing the basis for the optimization of the interventional treatment course and the improvement of the efficacy.

Methods: The clinical data of 222 TBTB(subtype II) patients admitted to Hunan Chest Hospital from January 2015 to December 2018 were collected, bronchoscopic interventional treatment was performed on time, the disappearance time of airway necrosis and repair time of airway scar stenosis and its influencing factors were recorded and analyzed.

Results: In 222 patients, 508 ulceration necrosis airway lesions were found under bronchoscopy, with a median of 2 (1-6); 170 (76.6%) cases of airway lesions had different degrees of stenosis before treatment. 79 (35.6%) patients had tough necrosis, and 86 (38.7%) patients had necrosis blocking the lumen; 132 (59.5%) patients had granulomatosis. After treatment, there were 201/222（90.5%） patients with different degrees of scarring in the airways; the disappearance time of airway necrosis after treatment was 1 to 32 weeks, and [M (Q1, Q3)] was 6 (3,9) weeks; the repair time of airway scar stenosis was 2 to 73 weeks, [M (Q1, Q3)] was 14 (10,19) weeks; Cox multivariate analysis showed that the risk factor for the disappearance time of airway necrosis was tough tough necrosis (HR=1.52, 95%CI=1.10-2.10); the risk factor for the repair time of airway scar stenosis was the disappearance time of airway necrosis 6- 9 weeks (HR=2.73, 95%CI=1.84-4.05).

Conclusion: 90.5% of patients with type II TBTB developed airway scar stenosis after treatment. The median time for the disappearance of airway necrosis was 6 weeks, and the median time for the repair time of airway scar stenosis was 14 weeks.In the interventional process, attention should be paid to the removal of tough necrosis and the efficiency of necrosis removal to reduce the risk of airway scar stenosis.

PO-208

Transglottic metallic stent implantation in thyroid cancer with subglottic stenosis: a case report

Chen,Xiaoke、Zhou,Yiping、Liu,Nian、Xia,Liping、Chen,Haiqin、Cao,Wenjuan、Xu,Wenjun
The Eighth Affiliated Hospital, Sun Yat-sen University, Shenzhen, China, 518033

Objective: Straight airway stents with suture buttons or T-tube implantation is likely to be used in patient with subglottic stenosis. Now we report a transglottic stent implantation for a patient with subglottic stenosis.

Methods: A 52 year-old female was admitted to the hospital on December 7th, 2019 due to a neck mass enlarging for 2 months, shortness of breath for 2 weeks, aggravation and coma for 5 days. Neck mass was coming up with hoarseness and choking cough since 2 months ago, and the patient was diagnosed of undifferentiated thyroid cancer with cervical lymph node and lung metastases in another hospital. The patient took anlotinib 10mg once daily, and developed cough and dyspnea 2 weeks ago, which improved after anti-inflammatory treatment, and reexamination indicated severe subglottic stenosis (2*7mm). However, symptoms of the patient aggravated and became coma for 5 days with blood gas analysis of PH7.08, PaCO2 103mmHg, and after insertion of size 6# tracheal tube, indwelling of gastric tube, anti-infection and other treatment, the patient was transferred to our hospital with improved condition. Admission examination showed the thyroid was enlarged to 3 degrees, and the mass in the upper tracheal segment was enveloped and moved to the left. On December 9th, 2019, under sedation and analgesia, the distal trachea and bilateral bronchus of the catheter were patency via transbronchial ultra-fine bronchoscopy. By inserting the ultra-hard guide wire through the ultra-fine bronchoscope, pulling out the tracheal catheter, and inserting the stent pusher along the ultra-hard wire, the Boston Science covered metallic stent (16*60mm) was successfully released under the direct vision with a transnasal bronchoscope. the upper edge of the stent was 5mm below the small angular nodules and the distal end was 7cm above the carina.

Results: After the operation, the patient could whisper, however, with pharyngalgia, dysphagia and choking cough. which were improved significantly after the stomach tube pulled out. Since the patient refused gastrostomy, a fine gastric tube was re-indwelling and lidocaine atomization was used. Pharyngalgia was finally relieved.

Conclusion: The transglottic airway stent can be used as a palliative treatment for subglottic stenosis patients with difficult tracheotomy. After stent implantation, patients can speak softly. Theoretically, it won't affect the swallowing function if the upper edge of the stent does not exceed the small angle nodules, which needs further observation to confirm.

PO-209

Dieulafoy's disease of the bronchus: A case of massive hemoptysis saved by high pressure balloon occlusion and review of literature

Luo,Jiayou、Hua,Feng、Wang,Bin、Zhou,Jia、罗家友
Huzhou hospital, Zhejiang University

Objective: Through sum up the clinical manifestations、chest CT and bronchoscopy, bronchial arteriography characteristics of bronchial Dieulafoy's disease and explore the best treatment for this disease, making clinical doctor understanding of the disease better.

Methods: Analysis one case of bronchial Dieulafoy's disease confirmed by surgery pathology in our hospital, andresearchfor the references that about bronchial Dieulafoy's disease from January 1, 1995 toMay 31, 2016 through the database of human health medical network.

Results: A total of 33 case reports were retrieved, including 1 case reported in this paper and 51 cases reported inreferences, totaling 52 cases.Patients aged from 13 to 70 years old, common in male (34/52), 17 cases with a history of smoking, 13 cases with a history of tuberculosis, the main clinical manifestations were unexplained recurrent hemoptysis.Disease located in right lung (30/52)more than left lung (15/52), located in both lungswere rare (3/52).Chest CT showed there were 6 cases of bronchiectasis;Bronchoscopy showedthat there were 33 cases whichcharacterized by bronchial lumen surface smooth small nodular protrusion, 5 cases were the earthworm sample blood vessels,4 cases were small white capsample,biopsy 20 cases bleeding was observed in all patients;Bronchial artery angiography and embolization treatment of 30 cases, surgical removal of the 20 cases,most of the abnormal vessels determined by bronchial arteriography and pathology came from bronchial artery (36 / 50), a few from pulmonary artery (2 / 50); EBUS inspection 3 cases, NBI in 2 cases.Bronchial artery embolization, surgery is the main method of treatment, such as recurrent hemoptysis after embolization,lobectomy can be cured.

Conclusion: Hemoptysis is the main performance of Dieulafoy's disease.Bronchoscopy is characterized bysmooth nodules protuberant, earthworm sample blood vessels,avoiding blind biopsy.EBUS and NBI have become a new means of early diagnosis.The operation of balloon sealing hemostasis is simple, but effective whichcreates conditions for radical treatment such as bronchial artery embolization or lobectomy,also improves hemoptysis Rescue success rate.

PO-210

Utility of cartridge based nucleic acid amplification test (CB-NAAT/GeneXpert) in mediastinal lymph node aspirates via endobronchial ultrasound

Guliani,Abhinav、Reddy,Vakamala Haritha、Ghosh,Shuvranu、Basu,Arup、Dhamija,Amit
Sir Ganga Ram Hospital, New Delhi, India

Objective: Drug resistance in tuberculosis is a major public health problem. The emergence of drug resistant, multi drug resistant and extensively drug resistant TB has emphasized the importance of establishing the correct diagnosis and drug susceptibilities of Mycobacterium tuberculosis before starting antitubercular therapy. Molecular tests for tuberculosis (including CB-NAAT/GeneXpert (Cepheid)) are widely available and established for pulmonary samples but data for mediastinal lymph nodes is scant. Our aim was to assess efficacy of GeneXpert in mediastinal lymphadenopathy with the help of endobronchial ultrasound guided transbronchial needle aspiration.

Methods: This was a prospective study at a tertiary care teaching hospital in New Delhi, where 160 patients of suspected tubercular mediastinal adenopathy sampled with the help of EBUS were enrolled over 12 months (June2017

to June2018). The results of GeneXpert were compared with cytopathological or microbiological diagnosis of tuberculosis and drug resistance if seen was validated by phenotypic sensitivity (gold standard).

Results: Mean age of our population was 38.75years with majority being males (64%). Total of 204 lymph nodes were sampled, most common being subcarinal (44%). 147(91.77%) cases were positive by cytopathology(having Necrotizing granuloma/granulomas/necrosis with or without AFB smear positivity). 100(64.1%) were microbiologically positive(smear/culture). 6 cases were excluded from final analysis in view of alternate diagnosis. Sensitivity of Cytopathology alone was 92%(141/154). Sensitivity of GeneXpert (overall) was 76.6%(118/154) and specificity was 100%. The sensitivity in microbiologically proven cases was 90%(90/100) and 53.7%(29/54) in microbiologically negative cases. PPV/NPV were 100%/15%. Among the probable cases 6% cases were detected only by GeneXpert. Sensitivity of GeneXpert in detection of Rifampicin resistance was 100%. However in 5 culture positive cases, GeneXpert did not detect MTB. All the rifampicin resistant cases were MDR.

Conclusion: GeneXpert improves the diagnostic accuracy of EBUS TBNA. It also detects Rifampicin resistance in minimal time thus helping early detection and prompt treatment of drug resistant tuberculosis.

PO-211

The Utility of a Multi-orifice Epidural Catheter when Using the "Spray-as-You-Go" Technique for Topical Airway Anesthesia during Flexible Bronchoscopy

chen,limei
The First Affiliat Hospital of Wenzhou Medical University

Objective: Lidocaine administered through the working channel of a flexible bronchoscope can provide effective local anesthesia but cannot achieve good distribution in the airway. This study was undertaken to determine whether lidocaine delivered via a multi-orifice epidural catheter (three orifices/openings) is superior to conventional method and if a better distribution and decreased the cough reflex can be achieved.

Methods: The patients (N=100; 50 in each group) were randomized to receive either topical airway anesthesia by the "spray-as-you-go" technique via conventional application (group C) through the working channel of the bronchoscope or via a triple-orifice epidural catheter (group E). The primary outcome measurement was the cough severity, which was documented using a 4-point scale. Bronchoscopists and nurses assessed the coughing.

Results: There was a significant difference in the median cough severity scores between the two groups (group C: 3 vs group E: 2, P=0.004). The median visual analogue scale (VAS) scores for the cough, were significantly higher in group C than those in group E (bronchoscopist: 3 vs 2 P=0.002; nurse: 3 vs 2, P<0.001). The incidence of cough was significantly higher in group C in the trachea, left and right bronchi. The highest respiratory rate was higher in group C than in group E (P<0.01). Eight patients in group C and two patients in group E had an oxygen saturation below 90% during flexible bronchoscopy(FB) (P=0.046). More patients in group C required extra topical anesthesia than in group E (P<0.001). The total lidocaine consumption was also lower in group C than that in group E (P<0.001).

Conclusion: Endotracheal topical anesthesia via the multi-orifice epidural catheter (three holes/openings) during flexible bronchoscopy using the "spray-as-you-go" technique was appeared to be superior to the conventional method.

PO-212

The application of the second generation gene sequencing of alveolar lavage fluid in the etiology diagnosis of severe pneumonia

zhu,fuyao
The Second Affiliated Hospital of Nanjing University of Chinese Medicine

Objective: to explore the application of second generation gene sequencing (mNGS) of BALF in the etiological diagnosis of adult severe neumonia

Methods: from June 2018 to June 2019, 48 patients with severe pneumonia who were hospitalized in the pulmonary disease department of the second middle school hospital of jiangsu province were randomly divided into observation group and control group, 24 cases in each group. Control group patients were sputum, blood and bronchoalveolar lavage fluid samples do general microbial cultures, adjustment to the results of the cultivation of antimicrobial drug use, observation group of patients were sputum, blood and bronchoalveolar lavage fluid do general microbial cultures, also add do alveolar lavage mNGS, according to the testing results of mNGS again to adjust the use of antimicrobial agents. The rates of positive etiology, mortality, hospital stay and complications were compared between the two groups.

Results: there were 21 cases in the observation group with a positive rate of 87.5%, and 16 cases in the control group with a positive rate of 66.67%. There was a statistical difference in the positive rate between the two groups. In addition, the 28-day and 90-day mortality rates in the observation group were significantly lower than those in the control group. There was no significant statistical difference in the occurrence of complications

Conclusion: alveolar lavage second generation sequencing may lead to faster, more accurate diagnosis and better clinical prognosis than conventional methods for treating severe pneumonia.

PO-213

The application of electromagnetic navigation bronchoscope in the diagnosis and treatment of peripheral pulmonary lesion

Cheng,Yu、LV,Liping、Tang,Fei
Anhui Chest Hospital

Objective: Electromagnetic navigation bronchoscope is a new technology that can accurately locate the lesion, diagnose and treat the central and peripheral lung lesions through bronchoscope with the help of high-resolution spiral CT and computer virtual bronchoscope.

Methods: Its characteristic is that it can guide the bronchoscope according to the path planned before operation or guide the bronchoscope to the lesion in real time To reach the focus, so as to carry out the diagnosis or treatment of peripheral pulmonary lesion(PPL).

Results: The purpose of this paper is to review the application of electromagnetic navigation system in the diagnosis and treatment of PPL such as the clear nature of pulmonary nodules, preoperative positioning and planning of guided surgery, photodynamic therapy, radiofrequency ablation, etc.

Conclusion: in order to find a simple and minimally invasive diagnosis method, accurate positioning method and provide more effective treatment models for patients with advanced lung cancer type.

PO-214

A case of tuberculous right upper lobe bronchial occlusion and endoscopic reopen

Wu,Chi、Zou,Jun、Zhu,Jiang、Chen ,Xian-Xia、Li ,Lin、Liu ,Xin-Ren、Yang, Yang
Sichuan provincial people' s hospital

Objective: Bronchial tuberculosis often lead to secondary atelectasis and obstructive pneumonia and is one of the most important causes of lung damage. Systemic anti-tubercular drug treatment is necessary but not enough, and bronchoscopic interventional treatment should be implemented as soon as possible to prevent the bronchus and lungs from dysfunction. However, for scarring bronchial occlusion, due to severe damage to the bronchial wall and structural reconstruction, interventional treatment is at high risk and the effect is not satisfying. Here we report a case in which the right upper lobe bronchus is completely occluded and the airway is recanalized by interventional treatment.

Methods: bronchial Three-dimensional CT reconstruction was performed to evaluate the airway and surrounding structures before operation. Local anesthesia and venous sedation were applied. Interventional procedure include high-frequency electrocautery, balloon dilation, cryotherapy, and local injection of triamcinolone acetonide.

Results: after endoscopic treatment, the right upper lobe bronchus was successfully recanalized and the lumen was stable in follow-up. Postoperative CT showed that the right upper lobe reinflate.

Conclusion: the necessity of reopening of scarring bronchial occlusion should be carefully evaluated, and interventional therapy need be given cautiously while the distal airways and pulmonary tissues were reserved.

PO-215

Diagnostic value of transbronchial cryobiopsy in diffuse interstitial lung disease

Cheng,Yu、LV,Liping、Tang,Fei
Anhui Chest Hospital

Objective: To investigate the diagnostic efficacy and safety of transbronchial cryobiopsy (TBCB) and transbronchoscopic lung biopsy (TBLB) in diffuse interstitial lung disease (DILD).

Methods: A total of 46 patients with diffuse interstitial lung disease treated in Anhui Chest Hospital from January 2019 to December 2019 were selected, of which 21 patients were treated with transbronchial cryobiopsy(TBCB group) and 25 patients were treated with transbronchoscopic lung biopsy (TBLB group).The laryngeal mask was placed under general anesthesia through non-intubated spontaneous ventilation. After routine examination of tracheoscopy, according to chest imaging and multidisciplinary discussion before operation, it is suggested to select the most active (exudative) lesions near 1-2cm below the pleura for biopsy. In the TBCB group, 2.4mm cryoprobe was sent through the bronchoscope biopsy hole to the lung lesions, and the cryoprobe was taken out together with the bronchoscope after 3-6s of cryopreservation. To compare the tissue area, sensitivity, specificity and the incidence of complications between TBCB and TBLB.

Results: According to the diagnostic gold standard of Pathology, the tissue area of TBCB specimens was (35.6 ± 13.2) mm2, the sensitivity was 90.48%, the specificity was 100%; the tissue area of TBLB specimens was (5.8 ± 4.1) mm2, the sensitivity was 36.00%, the specificity was 100%. The area of TBCB was significantly higher than that by TBLB ($P < 0.05$), and the diagnostic efficacy of TBCB for diffuse interstitial lung disease was higher ($P < 0.05$). The incidence of bleeding (14 vs 13), pneumothorax and mediastinal subcutaneous emphysema (2 vs 0) did not increase significantly.

Conclusion: TBCB is a safe and new minimally invasive technology platform, which has high sensitivity, specificity and accuracy.

PO–216

Predictor of new–onset tracheoesophageal fistula following tracheal stent implantation for severe tracheobronchial lesions

Li,Jingli、Ye,Ming、Lin,Xiaoxiao、Chen,Chengshui
the First Affiliated Hospitals of Wenzhou Medical University

Objective: To evaluate the incidence and predictors of new-onset tracheoesophageal fistula following tracheal stent implantation in patients with severe tracheobronchial lesions.

Methods: Retrospective cohort study including all patients with severe tracheobronchial lesions, including tracheoesophageal fistula, bronchopleural fistula, or tracheal stenosis that were successfully treated with tracheal stent implantation in the First Affiliated Hospitals of Wenzhou Medical University from 2014 to 2018. The patients were divided into two groups based on the occurrence of new-onset tracheoesophageal fistula. Univariate and multivariate analysis was performed to evaluate the predictive factors of esophageal fistula.

Results: One hundred fifty-four patients aged between 47 and 81years were included, and all symptoms of them were varying degrees relieved after tracheal stent implantation. The average follow-up for patients was 6 months (range of 1–18 months). During the follow-up, new-onset tracheoesophageal fistula occurred in 27 of 154 patients 29-134 days following stent implantation. The incidence of tracheoesophageal fistula was significantly higher among patients with esophageal cancer, concomitant esophageal stents, and history of local radiotherapy compared with those with neither condition. No significant relationship was identified between the incidence of tracheoesophageal fistula and age, sex, stent location, stent type, history of tracheal intubation, surgery, chemotherapy, gastrostomy or jejunostomy. Multivariate regression analysis revealed that the presence of esophageal cancer, concomitant esophageal stent, and prior radiotherapy were predictors of new-onset tracheoesophageal fistula following stenting.

Conclusion: Treatment of a severe tracheobronchial lesion by means of tracheal stent implantation is feasible. The presence of esophageal cancer, concomitant oesophageal stent, and prior radiotherapy are important factors contributing to tracheoesophageal fistula following tracheal stent implantation. If the patient has an esophageal fistula, the prognosis is likely to be fatal. A multidisciplinary approach is mandatory to ensure favorable long-term outcomes.

PO-217

Therapeutic bronchoscopy for malignant central airway obstruction: A ten-year review of outcomes and survival

Yagnik,Lokesh1、Ramarmuty,Hema1、Sidhu,Calvinjit1、Morey,Sue1,2、Philips,Martin1、Thomas,Rajesh1,2,3
1. Sir Charles Gairdner Hospital
2. Institute for Respiratory Health, Perth, AUSTRALIA
3. University of Western Australia, Perth, AUSTRALIA

Objective: Central airways obstruction (CAO) in patients with primary lung and metastatic cancers is common and usually indicates advanced disease. Urgent therapeutic bronchoscopy is often required to relieve the malignant obstruction and palliate symptoms. Complex therapeutic interventions including rigid bronchoscopy, tumour debulking and stent placement can help restore lumen patency but are associated with high risks and morbidity. Our objective is to describe the outcomes, complications and survival following therapeutic bronchoscopy for treatment of malignant CAO in a single tertiary centre.

Methods: A retrospective review was performed of all patients with malignant CAO who underwent therapeutic bronchoscopy at Sir Charles Gairdner hospital, Perth during a ten-year period (2008-2017). Demographics, cancer type, symptoms, number and type of bronchoscopic interventions, outcomes, complications and survival data were recorded.

Results: 75 patients (Male 41; median age 65 years) with malignant CAO who underwent therapeutic bronchoscopy were identified from the bronchoscopy database. The most common primary aetiology was lung cancer (39 patients, 52%) and carcinoid (9 patients, 12%). Therapeutic bronchoscopic procedures were performed primarily by two experienced operators in the operating theatre with the patients under general anaesthesia and spontaneous ventilation. Rigid bronchoscopy was performed in 42 (56%) patients. Airway dilatation and tumour debulking by balloon, diathermy, electrocautery, laser and cryotherapy were the main bronchoscopic techniques used. Airway stent was placed in 34 (45%) patients. Rate of severe procedure-related complications was low. 7- and 30-day all-cause mortality following the initial bronchoscopic intervention was 2.6% and 14.6%, respectively and mainly due to cancer progression. Median survival after bronchoscopy was 97 days (range 3-2589). 30 (40%) patients required repeat bronchoscopy after median 28 days.

Conclusion: Therapeutic bronchoscopy is useful to relieve malignant CAO and is associated with a low complication and mortality rate in experienced hands.

PO-218

Therapeutic bronchoscopy for the management of central airway stenosis after lung transplantation

Ding,Yinfeng、Ning,Yunye、Wang,Qin、Huang,Haidong、Dong,Yuchao、Yao,Xiaopeng、Zhang,Wei、Bai,Chong
Changhai Hospital, Second Military Medical University

Objective: Bronchial stenosis is the most common airway complication after lung transplantation and has a significant effect on lung function. Few data are available with regard to the value of bronchoscopic techniques for central airway stenosis. The objective of our study was to evaluate the clinical efficacy of balloon bronchoplasty and metallic stents in lung transplant-related central airway stenosis.

Methods: Data of adult lung transplant recipients with central airway stenosis who underwent therapeutic bronchoscopic interventions between January 2011 and January 2019 at our institution were retrospectively reviewed. The clinical follow-up included symptoms, forced expiratory volume in 1 second, six-minute walk distance, and the rate of bronchoscopic dilation.

Results: Twentynine lung transplant recipients, with airway stenosis were inclued in our study. All these patients

were treated by balloon bronchoplasty through flexural bronchoscopy, and seven additionally needed temporary metal stent inserted rang 28 to 67 days in order to palliate recurrent central airway stenosis. Immediate improvement of symptoms was noted in all patients. After serial balloon dilatation, recipients with central airway stenosis had significantly higher FEV1 (1.41+/-0.28L versus 1.73+/-0.32L, p<0.01) and farther 6MWD (316.50+/-69.04m versus 368.65+/-57.38m, p<0.01). Mean improvement in FEV1 for patients treated with stent insertion was (0.51+/-0.06) L. Seven recipients with central airway stenosis received 33 interventions in 6 months before stent insertion and 10 interventions in 6 months after stent extraction. No severe complications occurred in these patients.

Conclusion: Lung transplant recipients with central airway stenosis have a good respond to balloon bronchoplasty and stent placement. Application of temporary metal stent placement for selective patients may be associated with a reduction in frequency of interventions.

PO-219

A Novel Flexible Bronchoscopy-Guided Cryoablation In Peripheral Porcine Lung In Vivo

Yuan,Haibin1、Zheng, Xiaoxuan1、Sun,Jiayuan1、 Yang,Chi2、Xu,Binkai2、Haibin Yuan
1. Shanghai Chest Hospital
2. AccuTarget MediPharma [Shanghai] Co., Ltd.

Objective: Percutaneous Cryoablation proved to be a common ablation technique and could cause an amazing "cryoimmunology". However, percutaneous operation may be associated with pneumothorax, hemorrhage and other complications. With the development of several guided-bronchoscopy technologies such as electromagnetic navigation bronchoscopy (ENB) ,cone-beam CT (CBCT), ablation under guided-bronchoscopy seemed to be a reliable therapeutic method for lung cancer. A novel flexible transbronchial cryoablation was created at peripheral normal porcine lungs in vivo and it was attempt to prove the feasibility and safety of this method.

Methods: A novel flexible cryoprobe (a 12-mm-long, 2.2-mm diameter cryotip and a 1-m-long 13 gauge flexible catheter) was used in this study. A cylinder of nitrogen (full pressure = 2,100 psi; working pressure = 1,500 psi) was throttled to -160 to -150° C in the cryotip. We evaluated the flexible transbronchial cryoablation created at peripheral normal porcine lungs under general anesthesia in vivo. The cryotip and catheter was delivered to the distal bronchus in bilateral lungs through the work channel and confirmed by real-time computed tomography (CT). A bracket was used to fix the whole apparatus. The whole operation included two freezing cycles with each freezing cycle consisted of 15 minutes freezing time and 2 minutes rewarming time. CT, bronchoscope and monitoring were used to evaluate the effectiveness and safety. Ablation zone samples were taken at 24 hours and 4 weeks respectively. Long-axis diameter (Dl) and short-axis diameter (Ds) were measured and tissues were sectioned for pathological examination.

Results: Ablations (n=12) were performed successfully. Round ablation lesions could be obviously imaged under CT different from the normal surrounding tissue. No major complications (e.g. pneumothorax and pulmonary parenchymal hemorrhage) occurred during the procedure and the observation period. Pathological results showed that the lesions had completely formed coagulative necrotic zone along the target bronchus, with obvious vascular occlusion and necrosis at 24 hours, and the lesion had gradually formed fibrosis at 4 weeks.

Conclusion: The novel flexible bronchoscopy-guided cryoablation in porcine peripheral normal lung in vivo is a sufficiently feasible and safe interventional method. It can be a potential therapeutic tool Peripheral Lung Cancer.

PO-220

The Efficacy and Safety of a Covered Self-Expandable Metallic Stent in Tracheal Stenosis Caused by Tracheal Tuberculosis

Qin,Lin、Ding,Weimin、Guo,Yang、Fu,Yu、Wang,Wenjie、Wang,Guochun、Fu,Wenxia
Beijing Chest Hospital, Capital Medical University

Objective: Tracheal stenosis caused by tracheal tuberculosis is one of the most common causes of benign tracheal stenosis. Covered self-expandable metallic stent placement has become one of the modalities for treatment of benign airway stenosis. This study aimed to analyze the efficacy and safety of a covered self-expandable metallic stent in tracheal stenosis caused by tracheal tuberculosis.

Methods: From May 2016 to December 2018, 39 patients (30 males, 9 females,24.5±3.4y) of tracheal stenosis caused by tracheal tuberculosis were diagnosed by microbiology, histopathology, CT scan, bronchoscopy and airway reconstructions scan. All patients treated with routine anti-tuberculosis chemotherapy and covered self-expandable metallic stents placement. The indications of clinical efficacy,modified medical research council (mMRC) dyspnea scale,complications and long-term outcomes were analyzed.

Results: Total 40 stents were inserted in 39 patients successfully.Tracheal stenosis was immediately relieved after stenting. All patients demonstrated clinical improvement after stent insertion. The average of mMRC score changed from (3.7±0.5) to (0.2±0.4) after stent insertion（t=35.816，P ＜ 0.001）.Some stent-related complications were observed by bronchoscopy:stent migration（5%）,stent obstruction by granulation（10%） and stent obstruction by secretions（18%）. There were no cases of stent-related mortality. Complications after stenting could be effectively managed using bronchoscopic procedures.All stents were removed successfully after a median of 51.6±5.1 days. At follow-up (median: 12 months; range, 6-16 months) ,two patients occurred re-stenosis of the airway.One received balloon dilatation,and additional stent insertion was performed for another one successfully.

Conclusion: Covered self-expandable metallic stent is a very safe and effective method in the management of tracheal stenosis caused by tracheal tuberculosis.

PO-221

EXPERIENCE WITH STRATX REPORT IN ORDER TO PRODUCE LOBAR ATELECTASIS IN THE ENDOSCOPIC PULMONARY EMPHYSEMA TREATMENT WITH VALVES

ENRIQUE,CASES-VIEDMA、RAQUEL,MARTINEZ-TOMÁS、ANDRES,BRIONES-GOMEZ、CHELO,SANZ-FRANCES、CRISTINA,CARMONA-MOLLA、CATALINA,MARMOL-ALBERT
Pneumology

Objective: StratX Lung Report (PulmonX) study provides, in addition to lung density, of the fissures integrity. Based on this information it's possible treat patients with endobronchial valves without the need of a previous study with a Chartis test if the fissure integrity is bigger than 95%. The objetive of this study is to evaluate the results of the StratX assisted fissures in the production of lobar atelectasis.

Methods: Descriptive study between August 2018 and November 2019, when the treated patient's data based on the results of the StratX study of the clefts were collected. Zephyr endobronchial valves (Pulmonx) were placed in all segments or subsegments of the target lobe as previously described, with the patient under either general anesthesia.

Results: Fifty StratX studies have been performed, and 21 patients (42%) have been treated with endobronchial

valves, based on lung density and fissure completeness results. The fissure completeness average was 97.56%, 13 patients with 100% fissure completeness. Two patients also required a Chartis Test. The most frequently treated lobe was upper left lobe, and lobar atelectasis was obtained in 14 patients (66%). Complications were: pneumothorax in 6 patients (28.57%), and three valve expulsions (14.28%). Valves were removed in 4 patients (19%), two of them because never produced atelectasis or clinical improvement, and the other two patients because of pneumothorax and persistent air leakage.

Conclusion: StratX study of the integrity of the fissures helps to select the target lobe, however, it doesn't warrantee that a lobar atelectasis will happen.

PO-222

Primary lung sarcoma obstructing trachea treated with transbronchial tumor resection followed by anlotinib: a case report

Du,Wei1,2、Sun,Xianwen1,2、Chen,Wei1,2、Xiang,Yi1,2
1. Ruijin Hospital, Shanghai Jiao Tong University School of Medicine
2. Institute of Respiratory Diseases, School of Medicine, Shanghai Jiao Tong University School of Medicine

Objective: Primary lung sarcoma has been known as rare and often aggressive tumor, and surgical removal might be the best treatment choice for these patients. However, for patients who cannot be treated with surgery, effective therapy is lacking since both radiotherapy and chemotherapy have limited therapeutic effects.

Methods: Herein we describe a case of primary lung sarcoma extending to and obstructing trachea who has been treated with endobronchial resection followed by anlotinib and has achieved relatively favorable prognosis.

Results: The patient was an 80-year-old man who was diagnosed as primary lung sarcoma based on radiology, pathology and immunohistochemical results. The tumor was originated from the right middle lobe but had invaded trachea along the bronchus, with rapid growth pattern. No distant organ metastasis was observed. Transbronchial tumor resection was performed and anlotinib was added thereafter. Follow-up evaluations via computed tomography and bronchoscopy have shown stable disease and total progression free survival have been more than 8 months.

Conclusion: And in this case report we have shown that for primary lung sarcoma invading main bronchus and unable to be surgically removed, transbronchial tumor resection followed by anlotinib might be an effective therapy.

PO-223

Safety Profile of Endobronchial Valves for Bronchoscopic Lung Volume Reduction

Criner,Gerard1、Dransfield,Mark2、Shah,Pallav3、Sue,Richard 4、Sciurba,Frank5、Shargill,Narinder6、Slebos,Dirk-Jan7

1. Temple University
2. University of Alabama
3. Royal Brompton Hospital
4. Arizona Pulmonary and Medical Specialists
5. University Of Pittsburgh
6. Pulmonx Corp.
7. University of Groningen

Objective: Two types of endobronchial valves are in use for Bronchoscopic Lung Volume Reduction (BLVR) in hyperinflated severe emphysema patients with absence of collateral ventilation in the lobe targeted for treatment. The Zephyr® Valve (Pulmonx Corp., Redwood City, CA) has been shown to improve lung function, exercise tolerance and overall quality of life (QoL) (AJRCCM, 2018; 198: 1151-1164). In contrast, the Spiration® Valve System (SVS; Olympus Corp.) shows improvements in lung function and QoL (AJRCCM, 2019; 200: 1354-1362). The present analysis looks at the relative safety profiles of the two valve types based on the published data from the LIBERATE Study (Zephyr Valves) and the EMPROVE trial (SVS).

Methods: LIBERATE enrolled 190 severe heterogeneous emphysema patients (53% female, mean age, 64 years; baseline post-BD FEV127.4% predicted and Residual Volume (RV), 225% predicted) with a 2:1 randomization (Zephyr Valve, n=128) and Standard of Care (SoC), n=62) with little to no collateral ventilation (CV) assessed using the Chartis System. EMPROVE enrolled 172 participants (53.5% male; mean age, 67.4 years, Post-BD FEV1 30.0% predicted and RV, 209.5% predicted) with a 2:1 randomization to treatment (n=113) or control (n= 59) with collateral ventilation assessed by quantitative Computed Tomography. Effectiveness and safety outcomes were assessed at 6 and 12 months.

Results: The all-cause mortality rates versus the control group over 12 months were comparable with 2.3% in LIBERATE and 2.0% in EMPROVE. Serious pneumothorax rates (pneumothorax requiring surgical intervention or prolonged air leak >7 days defined as the time from chest tube insertion to the time the air leak is not present) were similar in the LIBERATE (17.2%) and EMPROVE (14.2%) trials. The absolute difference in incidence of other study-related respiratory serious adverse events including COPD exacerbations, pneumonia and respiratory failure between treatment and control groups from data for Zephyr Valves and the published data for SVS are shown below.

Conclusion : Both endobronchial valves had similar all-cause mortality risk and serious pneumothorax rates at 1-year vs control. LIBERATE patients had less reported serious adverse events including COPD exacerbations, pneumonia, and respiratory failure compared to EMPROVE patients especially during 6 to 12 months following the procedure.

PO-224

Endobronchial valves for severe COPD: A single service Australian experience

Rangamuwa,Kanishka1、Sidhu,Calvin1、Wilsmore,Nicholas1,2
1. Eastern Health
2. Epworth Eastern Hospital

Objective: Multiple trials have shown that bronchoscopic lung volume reduction (BLVR) with endobronchial valves can have a meaningful benefit in patients with advanced COPD. However, knowledge of long-term outcomes with BLVR is limited. We reviewed all patients that underwent BLVR through a single service provider in Australia to further assess the long-term outcomes of BLVR and describe our clinical experience.

Methods: All patients that underwent BLVR from 2015 to 2019 were retrospectively reviewed. Baseline characteristics, procedural details and post procedural details were collected. Success of procedure was determined by three measures: atelectasis, lung function testing and symptomatic improvement at last clinic review. Data was analysed to determine success, complication rates and factors affecting long-term outcomes.

Results: 41 patients underwent BLVR with a mean age of 72.41 years (range 57-87). Pre-procedure mean forced expiratory volume in 1 second (FEV1) and residual volume (RV) were 0.75L (29%) and 5.2L (227%) respectively. The most common site of BLVR was the left upper lobe (n=16, 39%). The Zephyr® valve (Pulmonx) was used for all patients. Post procedure 37 (90%) had atelectasis on chest imaging at day one post procedure. Long-term, 25 (61%) patients had a significant reduction in RV (mean reduction of 1.3L); 20 (49%) had a significant improvement in FEV1 (mean improvement 0.26L) and 32 (78%) had symptomatic benefit at last clinic review. Mean follow up was 259 days (range 28 – 1240 days). 15 (37%) had a pneumothorax post procedure, of those 11 required intercostal catheter insertion and 8 required valve removal/revision. Sputum impaction was a complication in 11 (27%) patients. 3 patients died in the follow up period to unrelated causes, 2 progressed to lung transplantation. Of the 16 without improvement in RV, 13 had atelectasis at day one and 8 had symptomatic benefit at last clinic review. There was a higher rate of sputum impaction in this group (7/16, 44% vs 4/25, 16%) with a trend towards significance (p=0.0743).

Conclusion: Our study demonstrates that the outcomes from BLVR at our service were comparable to the success rates described in the literature. The effect of BLVR is not always sustained over a prolonged period of time and further studies with larger patient numbers would be needed to assess this further

PO-225

The Outcome of Self-expandable Metallic Stent for Malignant Tracheobronchial Stenosis Following Esophageal Stenting

Li,Yahua、Zhou,Zihe、Ren,Kewei 、Ren,Jianzhuang、Han,Xinwei
the first affiliated hospital of zhengzhou university

Objective: Tracheobronchial stenosis following esophageal stenting is rare. We aim to explore the outcome of SEMS for malignant tracheobronchial stenosis following esophageal stenting.

Methods: Clinical and imaging data of 20 patients (12 males, 8 females) with malignant tracheobronchial stenosis following esophageal stenting from Jan 2014 to Jan 2019 were retrospectively analyzed. Data of the location of tracheobronchial stenosis, stent types, Borg score before and after airway stenting, indication of esophageal stent placement, interval between double stents placement and survival time after airway stenting were collected.

Results: A total of 20 stents (13 Y-shaped stents, 7 tube stents) were successful placement in all patients without procedure-related complications happened. Seven of them are tracheal stenosis, 5 carina stenosis and 8 multiple stenosis. The mean Borg score before and after airway stenting are 6.6±1.1 and 1±0.5 ($P<0.001$). The interval between double stents placement in patients who received chemoradiotherapy is 146.29±106.77 days, while in palliation therapy is 41.83±146.29 days($P<0.05$). The mean survival time after esophageal stenting in patients who received chemoradiotherapy is 232.79 ±97.71 days, while in palliation therapy is 163 ± 113.50 days($P=0.230$). The mean survival time after airway stenting in patients who received chemoradiotherapy is 86.5 ±52.47 days, while in palliation therapy is 121.17 ± 113.48 days($P=0.461$).

Conclusion: The application of SEMS in malignant tracheobronchial stenosis following esophageal stenting is safe and effective. Chemoradiotherapy is a factor affect the interval between double stents placement.

PO-226

Diagnostic and therapeutic utility of thoracoscopy with specially designed metallic conduits and fiber optic bronchoscope in various undiagnosed pleural diseases

Shah,Bhavya Atul、Jain,Swapnil、Varudkar,Hanmant Ganpanti、Julka,Arti
RD Gardi Medical College， Ujjain MP， INDIA

Objective: To assess various diagnostic and therapeutic uses of our special technique in various pleural diseases.

Methods: Study setting- Tertiary care hospital of a rural medical college, in central India All the patients with various pleural diseases were investigated routinely to clinch the diagnosis, and the patients with undiagnosed pathology were included in this study. After completion of preset protocol, these patients were subjected for this technique. Instruments- this set, autoclavable, consists of 1) Straight simple conduit-2) Curved simple conduit-3) Parietal introducer conduit 4) Parietal retractor conduit- 6) Visceral conduit- they all have different features to accentuate their function(Fig No.1) After making suitable stoma under local and conscious sedation, first straight conduit was inserted in pleural cavity to drain all the contents. Then the conduits are passed in serial order one after another as numbered above. FOB is passed through the conduit and systematic inspection of complete pleural cavity is done. Procedures like biopsy, adhesiolysis, debridement, ICD manipulations were done. After removal of the conduit and FOB, chest tube was kept and post operative management was done as usual.

Results: During the period of Jan 2017 to Oct 2019,107 patients with – 1) Pneumothoraces – 18 (17%) 2) Pleural effusions-38 (35%) 3) Hydropneumothoraces –22(20%) 4) Empyema -29 (28%) were subjected to the technique. Histopathology showed that there were total 32 cases of tuberculosis and 17 cases of malignancies. A foreign body- synthetic suture was retrieved in one case of recurrent empyemas. Post operative lung expansion was complete and tubes removed between 3 to 5 days. There were complications like minimal bleeds, pain, and correctable hypoxia.

Conclusion: We conclude that this technique is easy, safe, and useful both, diagnostic and therapeutic uses, with usual complications, and no damage to FOB.

PO-227

Rapid Onsite Cytologic Examination (ROSE) by cytotechnician during EBUS-TBNA reduces procedure time with high concordance to final diagnosis

Sriprasart,Thitiwat、Yingsirichaiyos,Napassorn、Leelayuwatanakul,Nophol、Thanthitaweewat,Vorawut、Kawkitinarong,Kamol、Chantranuwatana,Poonchavist
Faculty of Medicine Chulalongkorn University

Objective: To explore the benefit of Rapid Onsite Cytologic Examination (ROSE) by cytotechnician during EBUS-TBNA in term of procedure time and diagnosis

Methods: This is a prospective two-phase study. We collected 150 cases of EBUS-TBNA without ROSE and 150 cases of EBUS-TBNA with ROSE (Total 300 cases) during 2018-2019. All procedures performed by same group of intervention pulmonologist. We compared procedure time between EBUS-TBNA with ROSE and without ROSE. We compared result of cytologic examination of ROSE and final diagnosis.

Results: The mean (±SD)of procedure time of EBUS-TBNA without ROSE and with ROSE were 65±19.77 minutes and 51±15.75 minutes respectively. The procedure time with ROSE reduce on average 14 minutes per case due to fewer passes of TBNA. In 150 cases of EBUS-TBNA with ROSE, we found concordance diagnosis in 144 cases. (96%)There were 6 cases (4%)of discordance between ROSE and final diagnosis.(Figure 1) In 6 cases, ROSE revealed abnormal cell but no malignancy reported in final diagnosis. The final Surgical pathologic report from cell block in 6 cases revealed positive for malignancy.

Conclusion: ROSE by cytotechnician reduces procedure time with average 14 minutes per case and provide high concordance to final diagnosis.

PO-228

A case of pulmonary capillary hemangiomatosis treated by Interventional bronchoscopy

Ma,Tingting、Liu,Chunhui、He,Yuanbing
the first affiliated hospital of Xinjiang Medical Univesity

Objective: Interventional bronchoscopic treatment in airway pulmonary capillary hemangiomatosis（PCH）: a case report.Discuss the safety and effectiveness of interventional bronchoscopic treatment in airway pulmonary capillary hemangiomatosis.

Methods: Elaborate throughout a case of pulmonary capillary hemangiomatosis（PCH） that was diagnosed and treated by interventional bronchoscopy in our hospital.

Results: A fifty-year-old female patient, visited in our hospital three times because of cough and bloody sputum. She was previously diagnosed with "pulmonary capillary hemangiomatosis (bilateral)" after a biopsy at the previous hospital and treated with bronchoscopy (Left lung upper lobe and right lung lower lobe) tumor resection (electric band ligation, cryotherapy , argon plasma coagulation). Pathological diagnosis: moderate atypical hyperplasia of the mucosal squamous along with metaplasia, hyperplasia of the interstitial vessels and spindle cell. Act (-), ALK (ALK1) (-), Bcl 2 (-), CD10 (+), CD31 (+), CD34 (+), cyclinD1 (scattered +), D2-40 (lesions +), Vim (+), Ki-67 labeling index was 3%, and immunohistochemical results were consistent with capillary hemangioma. Her first medical visit to our hospital was due to symptoms (without obvious triggers) of chest tightness, shortness of breath, dyspnea, and hemoptysis. Blood gas measurements indicated hypoxemia in patients, CT scan of the lungs displayed left bronchus obstructed severly, while bronchoscopy showed tumor tissue severely obstructed the right and left main bronchus, caused severe stenosis of the trachea in right middle bronchus. Cryobiopsy showed that a capillary hemangioma, and then under general anesthesia, the tumor was ligated with an electric snare through a rigid bronchoscope, removed by electric resection. After that, another part of of the tumor was removed by crytherapy with a carbon dioxide freezing probe. Finally, the rest of the tumors were ablated with an argon plate coagulation, and the trachea was basically unobstructed after repeated treatment. Postoperative blood gas analysis suggested that the hypoxemia of patient was significantly improved. Second time of medical visit occured in 2 months later because of her symptom of blood sputum with gross hematuria and acute nosebleeds. Relevant examinations suggested that the patient had a progressive increase in white blood cells, a progressive decrease in hemoglobin and platelets, and renal function damage. Mitral valve vegetation could be seen under B- ultrasound. She was taken into the hospital with diagnosis of multipal organ failure. Symptomatic anti-infection, dialysis and blood transfusion treatment were given during treatment. After multi-disciplinary consultation, it was concluded that patient's excrescence of mitral valve was most possibly transferred by the large area of pulmonary capillary hemangioma. Surgical treatment was recommended, but the patient had poor cardiopulmonary functions and could not tolerate the surgical treatment. She was discharged after the symptoms improved. Two weeks after, in her third medical visit related to her chest tightness, shortness of breath, the examination showed infection, anemia, and hypercoagulable state. The treatment was terminated after family members gave up and patient passed away from hypoxia.

Conclusion: Pulmonary capillary hemangiomatosis is an extremely rare vascular proliferative disease. Accurate diagnosis requires integrate clinical, imaging, and histopathological data. Among these, histopathological examination is recognized as the most reliable method and is decisive for the diagnosis. There is no clear guideline for the treatment of capillary hemangiomatosis, and most are mainly based on case reports. There is only one case report of airway capillary hemangiomatosis in both Chinese and foreign literature. This specific patient only saw the common symptoms of the respiratory tract and was repeatedly hospitalized in multiple hospitals. The treatment was mainly to relieve the symptoms, and the effect was not obvious. Interventional bronchoscope therapy has been used as the main method to alleviate dyspnea and shortness of breath in airway capillary hemangiomas, but the basis for its treatment has not been

clarified yet. Nonetheless, the interventional treatment of this patient effectively mitigated the capillary hemangioma's occupancies in the large airway. However, because of its high recurrence rate and rapid growth rate, close follow-up and attention is recommended in the treatment. Currently, the most commonly accepted treatment of pulmonary capillary hemangiomastosis is still the lung transplantation. Hence, and further alternative treatment that is more non-invasive, safe, and effective still need to be researched to outperform surgical treatment of pulmonary capillary hemangiomastosis.

PO-229

Evaluation of the Efficacy of Interventional Bronchoscopic Treatment of Tracheal and Bronchial Malignancies tumor

Mamateli,MIhrinur、Abulikemu,Xianmusinuer、He,Yuanbing
The First Affiliated Hospital of Xinjiang Medical Univesity

Objective: Compare the efficacy of flexible and rigid bronchoscopic interventions treatment in treating tracheal and bronchial malignant tumors.

Methods: A total of 39 cases of trachea and bronchial malignant tumor were collected from the First Affiliated Hospital of Xinjiang Medical University between 2015 to 2019. 19cases are primary squamas cell carcinoma, 2 cases are small cell carcinoma, 2 cases are adenocarcinoma, 3 cases are adenoid cystic carcinoma, 2 cases are mucoepididermoid carcinoma, 3cases are metastasis of esophagus cancer , 2cases are metastasis of thyroid cancer, 3cases are metastasis of clear cell carcinoma of kidney,2 cases are metastasis of breast carcinoma,1case is metastasis of liver carcinoma, 19cases were treated by flexible bronchoscope , 20 cases were treated by rigid bronchoscope, Observe Physical conditions to illustrate treatment effect. Mearuement the airway diameter, blood gas analysis (PaO 2, PaCO2, SaO 2), and shortness of breath index before and after treatment.

Results: After interventional bronchoscope treatment , two grope improved markedly , statistical analysis show the grope of rigid bronchoscope have a short operating time than that of flexible bronchoscope.

Conclusion: Rigid bronchoscopic interventional treatment is faster than traditional flexible bronchoscopical treatment of tracheal and bronchial malignancies tumor, bronchoscopic interventional treatment has a higher tumor resection rate and improves pulmonary function more significantly.

PO-230

Endobronchial Valve and chemical pleurodesis for the treatment of chylous hydropneumothorax

Hu,Zhanwei、Zhang,Wei、Cheng,Yuan、Zhang,Hong、Wang,Guangfa、胡展维
Peking University First Hospital

Objective: Endobronchial valve is now playing an important role in the treatment of bronchopleural fistula. This case shows the successful treatment of a chylous hydropneumothorax case using EBV and chemical pleurodesis.

Methods: A 65 year old male patient presented with shortness of breath for 1 month. He was diagnosed with lung cancer 10 months ago. Chest CT showed massive pleural effusion on the right side. A chest tube was inserted and subsequent laboratory study led to the diagnosis of chylothorax. At first, chemical pleurodesis was planned for the treatment. But after drainage of the pleural effusion, the patient developed pneumothorax that could not be resolved despite closed drainage. Chest CT was performed again and a bronchopleural fistula was noted.

Results: A endobronchial valve was placed in the right upper lobe bronchus to block the fistula and chemical

pleurodesis using diluted iodophor. Subsequent chest X-ray and CT showed no relapse of pneumothorax and chylothorax.

Conclusion: Bronchopleural fistula should be suspected in patients with unresolved pneumothorax despite closed drainage. EBV is an useful tool for the treatment of bronchopleural fistula.

PO-231

The value of DNA polyploidy combined with radial EBUS in the diagnosis of peripheral lung diseases

Guo,Cuiyan、Hu,Yan、Yu,Qing、Zhang,Hong、Zhang,Wei、Cheng,Yuan、Gong,Yu hong、Wang,Shi xuan、Guo,Lin、Jia,Ya li、Wang,Guangfa
Peking University First Hospital

Objective: To explore the diagnostic value of DNA polyploidy analysis combined with radial EBUS in peripheral lung diseases

Methods: We take a retrospective analysis of patients who underwent radial EBUS examination at Peking University First Hospital from October 1, 2016 to April 1, 2018,Meanwhile,DNA aneuploid in bronchial washing from from target bronchial segment was performed.The general demographic characteristic,chest CT manifestations, radial EBUS data, pathological results and DNA polyploid results were collected. For patients who were not clearly diagnosed after bronchoscopy, follow-up information was recorded

Results: A total of 62 cases were collected. 7out-patients were excluded due to incomplete data, and 5 patients were lost to follow-up. Finally, 50 cases were included. There were 26 males and 24 females with an average age of 61 years.30 patients were confirmed malignant tumor,19 of them were confirmed by pathology after the bronchoscope, and the rest 11 cases were confirmed by later surgery or CT guided puncture.20 cases were finally considered to be benign,including 7 confirmed cases and 13 cases with uncertain diagnosis.Among them,3 cases of pulmonary abscess, 1case of sarcoidosis, 1 case of tuberculosis, 1 case of chronic pulmonary aspergillosis infection, 1 case of AFOP.During follow-up,5 case with pulmonary lesions smaller or disappeared, and 5 cases maintained unchanged within 2 years, 3 cases maintained unchanged within 1 year.In the malignant cases，the pathological sensitivity is 63.3% and the specificity is 100%. Aneuploid has a sensitivity of 76.7% and a specificity of 55%. When combine the two methods,which positive defined as either method is positive ,the sensitivity is 90%,and specificity 55%. None of the above bronchoscopy operations had serious complications that required clinical management.We further analyzed smoking, the size and location of lesions on chest CT, the number of aneuploid cells and the maximum value of aneuploidy.The results showed that the lesions located in the upper lobe and increased number of aneuploidy cells,associated with higher probability of malignant tumor

Conclusion: DNA polyploidy analysis combined with radial-EBUS can improve the diagnostic sensitivity of malignant peripheral lung lesions.It was further found that lesions located in the upper lobe and increased number of aneuploid cells may indicate that the lesions are more likely to be malignant

PO-232

Manifestation and safety of bronchoscopy for mediastinal fibrosis: a retrospective analysis

Liao,Jiping、Hu,Yan、Zhang,Hong、Zhang,Wei、Wang,Guangfa
北京大学第一医院

Objective: To explore the manifestation and safety of bronchoscopy for mediastinal fibrosis

Methods: We conducted a retrospective observational study reviewing clinical, endobronchial characteristics and outcome of mediastinal fibrosis patients received bronchoscopy in our hospital from 2008 to 2019.

Results: Eight men and 10 women with a mean age of 68.3 ± 8.5 were included. Tuberculosis (n=12) were the leading causes. Tracheoscopy was used to exclude tumor, active infection, sarcoidosis and other diseases. Patients received endobronchial ultrasound guided transbronchial needle aspiration (EBUS-TBNA) (n=14), bronchial brush biopsy (n=17), mucosal biopsy (n=10) and transbronchial lung biopsy (n=3). 14 cases were under general anesthesia. The principal endobronchial findings were distortion of bronchus with stenosis (n=14), multiple pigmentation of bronchial mucosa (n=14), and bronchial mucosal edema (n=9), 10 cases were bilateral involvement. Ultrasound findings of mediastinal tissue were obscure boundary, heterogenous internal echoes and sometimes with calcification. Two patients suffered serious complications, one patient of massive hemoptysis received mechanical ventilation, one patient died of glottic edema after operation. Transient complications included bleeding (8 cases), postoperative wheezing (n=2), oxygen saturation decrease (n=3) and pneumothorax (n=1).

Conclusion: Tracheobronchial centric narrowing, multiple pigmentation and mucosal edema were the endobronchial features of mediastinal fibrosis. As the risk of bleeding is high, we should assess the risks and the benefits of bronchoscopy for patients with mediastinal fibrosis.

PO-233

Repeating bronchoscopy for the diagnosis of diffuse parenchymal lung disease

Hu,Zhanwei、Zhang,Wei、Que,Chengli、Jia,Peng、胡展维
Peking University First Hospital

Objective: Bronchoscopy is an useful tool in the diagnosis of DPLD(diffuse parenchymal lung disease).BALF might provide key information.

Methods: A 45-year-old man presented with repeated fever, cough and shortness of breath for 3 months. 3 months ago when he first had a fever, he was diagnosed with myelodysplastic syndrome (MDS) in a local hospital. He was given antibiotics and blood transfusion. Chest CT revealed bilateral ground glass opacities. Despite various kinds of antibiotics, the opacities in his lungs became worse.

Results: Bronchoscopy was performed and BALF lymphocytes and neutrophils were elevated(34% and 13%). NGS revealed Neisseria, Candida and Mycobacterium Tuberculosis（only 1 copy）. As no infection could explain the situation, PAP(pulmonary aveolar proteinosis) was suspected after disscusion. Bronchoscopy was performed for the second time. The color of the BALF was not typical for PAP. But PAS staining confirmed the diagnosis. He was diagnosed with PAP secondary to MDS. And received bone marrow transplantation. Subsequent CT showed improvement of the ground glass opacities.

Conclusion: Atypical character of BALF should not exclude the diagnosis of PAP. Character of BALF should always be observed and recorded carefully. Careful laboratory study of BALF might provide key information for diagnosis.

PO-234

Advances in next generation gene sequencing for lung cancer prognosis

Du,Yuxia
the Second Affiliated Hospital of Fujian Medical Univercity

Objective: Purpose: To analyze and summarize the progress and characteristics of the studies on the prognosis of NGS in non-small cell carcinoma based on DNA, RNA and epigenetics.

Methods: Methods: Literature retrieval, trials' selection and assessment and data collection were performed according to the Revman 5.0 guidelines.

Results: Result: Any predictive model has its limited scope of study, population, and identification of the source and combination of genomes to better understand the prognostic utility.

Conclusion: Conclusion: Genomic sequencing technology can provide a powerful new platform for the study of the pathogenesis of lung cancer and the screening of effective diagnostic and therapeutic markers, thus laying a good foundation for the development of new drugs and individualized treatment.

PO-235

Transbronchial amphotericin B injection therapy for pulmonary aspergillomas: report of four cases

Furuse,Hideaki、Ueda,Takahiro、Uenishi,Riki、Nakatsuji,Yuko、Fujii,Yoshinori、Tanaka,Hidenori、Yagyu,Kyoko、Matsushita,Haruhiko
Department of Respiratory medicine, Izumi City General Hospital, Izumi, Japan

Objective: Although the first choice of treatment for pulmonary aspergillomas is surgical resection, this is sometimes difficult to perform because of poor lung function or disease complications. Systemic antifungal agents are often used in such cases; however, the response to this treatment is not necessarily sufficient and sometimes results in progression to lesions. There have been some case reports of local antifungal agent injection therapy for aspergillomas, but the efficacy and safety of this treatment remains unclear. We reviewed our experience of transbronchial antifungal agent injection therapy for pulmonary aspergillomas.

Methods: Using medical records, we retrospectively reviewed cases of transbronchial antifungal agent injection therapy for pulmonary aspergillomas at Izumi City General Hospital over 10 years.

Results: Four patients underwent transbronchial antifungal agent injection therapy. The antifungal agents amphotericin B or liposomal amphotericin B were used in all cases. All patients were male and their median age was 65 years (range: 54–72). One patient had a history of pulmonary tuberculosis, one had interstitial pneumonia, one had both pulmonary tuberculosis and interstitial pneumonia, and one had invasive pulmonary aspergillosis following influenza pneumonia. Three of the four patients were taking prednisolones for immunosuppression. The lesion locations were as follows: two patients had lesions in the right upper lobe, one in the left lower lobe, and one in both the right middle lobe and right lower lobe. All patients underwent transbronchial injection using a thin or ultrathin bronchoscope. Two patients had injections into the lesion through the bronchus and two had injections directly into the lesion cavity. The median duration of therapy was 31 days (range: 20–33) and the mean number of injections was 11 (range: 9–16). In addition, all patients were taking a systemic antifungal agent at the time of therapy. During the therapy period, all patients had local improvement of the lesion confirmed by chest CT scan and bronchoscopic findings. Three of four patients completed the therapy and continued systemic antifungal treatment. However, one patient died due to pneumonia that occurred during the therapy period.

Conclusion: Thus, transbronchial amphotericin B injection therapy for pulmonary aspergillomas was found to be effective as a local control of the lesions. There was one case of pneumonia complication during the therapy period.

PO-236

THE ROLE OF BRONCHOSCOPY FOR SUCCESSFUL REMOVING OF A CHRONIC FOREIGN BODY AFTER TWENTY YEARS

Parsama Putra,Ngakan Putu
Medical Faculty Brawijaya University

Objective: Chronic aspirations of foreign bodies are uncommon, but can lead to intolerant systemic and respiratory symptoms. Fiber optic bronchoscopy (FOB) may demonstrate tissue response characteristics to foreign bodies, including tissue granulation, endobronchial stenosis. Diagnosis of foreign body aspiration is often difficult to define in some patients may not give a clear history of aspiration. Furthermore, patients may be misdiagnosed with other diseases such as malignancy, lung tuberculosis, chronic pneumonia.

Methods: -

Results: We present the case of a 50-year-old man who had chronically foreign body metal bullet in the right medius bronchus for 20 years, with pleural effusion dextra and atelectasis lung dextra, radiographic evaluation and bronchoscopic examination revealed the foreign body which was successfully extracted by basket forceps

Conclusion: Our case highlights and shows that chronic foreign body is still missing and ignored in doagnosed, fiber optic bronchoscopy has been secure and effective procedure in the management of foreign body in the airway, pneumonia has been the most common complication with accompanied pleural effusion.

PO-237

Prevention and Management of PDT Related Complications for Lung Cancer

Furukawa,Kinya1、Ono,Shotaro 1、Yazaki,Yuuki 1、Nakajima,Eiji1、 Ikeda,Norihiko1,2
1. Tokyo Medical University Ibaraki Medical Center
2. Tokyo Medical University

Objective: Photodynamic therapy (PDT) was first applied clinically for endoscopically early stage lung cancer (ESLC) at Tokyo Medical University in 1980. Since then, PDT has gained considerable acceptance in the world as a minimally invasive modality. While the effectiveness of PDT using porfimer sodium (Photofrin®) has been recognized clinically, it is not widely employed, partly because of the problems posed by skin photosensitization. The 2nd generation photosensitizer, talaporfin sodium (Laserphyrin®, Meiji Seika Parma Ltd. Japan) possess lower skin photosensitivity. We investigated the PDT related complications.

Methods: We compared complications of the phase II studies of PDT for ESLC in 2 different photosensitizers. Other complications from our experiences were also investigated. Moreover, we compared complications of PDT to Nd:YAG laser treatment for advanced lung carcinoma treated as palliative laser therapy for the purposes of opening endobronchial stenosis or obstruction.

Results: The skin photosensitization of Photofrin® was recognized 28.8% in grade 1 and 1.9% in grade 2. Meanwhile, Laserphyrin® showed very low skin photosensitivity, 10% in grade 1 and 0% in grade 2, and was confirmed that the reactivity to light disappeared in most patients (84.8%) by 2 weeks after administration. Patients should be kept

in room under 500 Lux until 2 weeks after administration in case of Photofrin®, and 300 Lux until 1 week in case of Laserphyrin®. After PDT, usually bronchial obstruction occurs due to edema, exudates and/or tumor necrosis, therefore, to prevent following obstructive pneumonia, bronchial toileting is necessary no later than 7 days. Stricture due to necrosis or scar tissue after PDT is rare complication, however, sever PDT reaction by excessive laser irradiation makes possibility of bronchial stricture. In that case, balloon dilatation and/or stenting to dilate airway lumen is necessary. For advanced cancer with obstruction, no fatal complications occurred in any of the PDT treated patients. Meanwhile, in the Nd-YAG treated group, severe complications, including massive bleeding in 6% and bronchial perforation in 3%, were occurred. The mortalities were 0% in PDT and 1.7% in Nd-YAG laser treatment, therefore, the greatest advantage of PDT over Nd-YAG treatment was safety.

Conclusion: Laserphyrin® demonstrated lower skin photosensitivity. The relative safety and effectiveness of PDT for early and advanced lung cancer were demonstrated. However, there are some possibilities of serious complications such as bronchial necrosis and stenosis even in minimally invasive treatment like PDT, therefore, patients should be closely followed-up by repeated bronchoscopies after undergoing PDT.

PO-238

Rigid bronchoscopic intervention for endobronchial metastasis of renal cell carcinoma

Wang,Xi、Wang,Guangfa、Zhang,Hong、Zhang,Wei、Hu,Zhanwei、Huang,Junjun、Hu,Yan
Peking University First Hospital

Objective: Renal cell carcinoma(RCC) is one of the major endobronchial metastases. It often causes hemoptysis due to the highly vascular nature of the tumor, and it occasionally leads life-threatening airway obstruction. Rigid bronchoscopy is useful as a palliative intervention，however, its utility for metastatic RCC has not been elucidated. The purpose of this study was to evaluate the safety and efficacy of rigid bronchoscopic treatment for endobronchial metastasis of RCC.

Methods: Clinical data of patients with metastatic RCC who underwent rigid bronchoscopic intervention from January 2014 to December 2018 were collected and reviewed in this retrospective study. Procedures were performed with rigid and flexible bronchoscopes under general anesthesia. As needed, electrocautery, APC, cryotherapy, laser, or high-pressure balloon were used to recanalize the airway. Significant bleeding was defined as requiring APC or high-pressure balloon for hemostasis.

Results: Seven patients with RCC and airway obstruction underwent rigid bronchoscopic treatment. There were 6 males and 1 female, with a median age of 63 (51-70 years). Significant bleeding was observed as an intraoperative complication in 6 patients, the remaining 1 patient who treated with bronchial artery embolization (BAE) before endoscopic treatments had minor bleeding. All patients experienced significant improvement in dyspnea, hemoptysis and cough scores after therapy when compared to pre-treatment state. There was no procedure-related mortality.

Conclusion: Rigid bronchoscopic intervention is feasible with safety and effectiveness for airway obstruction caused by endobronchial metastasis of RCC. Significant bleeding is common, BAE before interventional bronchoscopy may avoid significant bleeding.

PO-239

Application of different types of congenital heart disease occluder in bronchopleural fistula

Wang,Xiangqi、Huang,Haidong、Zhang,Wei、Dong,Yuchao、Xia,Ying、Wang,Qin、Bai,Chong
Changhai Hospital， Naval Medical University(Second Military Medical University)

Objective: This paper introduces the preliminary effect of different types of occluder for congenital heart disease in the treatment of bronchopleural fistula (BPF)

Methods: The clinical data of 3 BPF patients in our department were reviewed, and the relevant literature was analyzed.

Results: Case 1: male, 67 years old, Case 1: male, 67 years old, was diagnosed as right upper lobe bronchial stump fistula（postoperative lung cancer） and right empyema。In the past, silicone plug placement and Y-type silicone stent placement were used, but all of them failed due to implant displacement, and the diameter of the fistula was 6 mm. Under the guidance of rigid bronchoscope, ASD（atrial septal defects） occluder (18mm * 18mm) was placed in the stump of right upper lobe bronchus. It was confirmed by X-ray fluoroscopy that the occluder was fully released and in good position. After 25 months follow-up, there was no recurrence of empyema, displacement of occluder and local infection. Case 2: male, 64 years old, was diagnosed as left upper lobe bronchial stump fistula（postoperative lung cancer）, left empyema, the diameter of the fistula was 3 mm. Under the guidance of rigid bronchoscope, VSD（Ventricular Septal Defect） occluder (A3B2, 6mm) was placed in the stump of left upper lobe bronchus. It was confirmed by X-ray fluoroscopy that the occluder was fully released and in good position. After 25 months follow-up, there was no recurrence of empyema, displacement of occluder and local infection. Case 3: male, 49 years old, was diagnosed as left upper lobe bronchial stump fistula（postoperative organic pneumonia）, left empyema, the diameter of the fistula was 8 mm. Under the guidance of electronic bronchoscope, PDA（Patent Ductus Arteriosus） occluder (14mm) was placed in the stump of the left upper lobe bronchus. It was confirmed by X-ray fluoroscopy that the occluder was fully released and in good position. After 7 months of follow-up, there was no recurrence of empyema, displacement of occluder or local infection.

Conclusion: ASD, VSD and PDA occluder can effectively treat BPF with fistula more than 3mm, and the safety is acceptable.

PO-240

Frozen section of pleural biopsies during flex-rigid medical thoracoscopy assists in correctly identifying malignant disease.

Oh,Jongyeol、Lim,Jeong Uk、Lee,Sang Haak、Ha,Jick Hwan
Catholic University of Korea

Objective: Medical thoracoscopy (MT) is generally considered a safe and effective method, not only in the diagnosis of undiagnosed pleural effusion, but also in the management of pleural disease. MT allows both tissue diagnosis and pleurodesis to be achieved reliably in one procedure. But there is not enough study about the effectiveness of frozen sections during procedure. The aim of this study was to assess the feasibility and accuracy of using frozen section analysis of samples taken during MT to assist the operator’s decision to complete the procedure with a thoracoscopic talc poudrage.

Methods: This retrospective study included 172 patients with undiagnosed pleural effusion who underwent MT and biopsy between February 2017 and November 2019. Frozen and paraffin sections were performed by flex-rigid MT.

Talc poudrage was performed when frozen section was suspicious to malignancy. The final diagnoses based on paraffin sections were compared to results of frozen sections.

Results: Frozen sections were performed during MT in 172 patients. The diagnosis based on frozen sections was malignant in 75 cases and benign in 97 cases. 75 patients of malignancy cases on frozen sections underwent talc poudrage. The final diagnosis based on paraffin sections was malignant in 85 cases, benign in 87 cases. In case of 75 malignant frozen sections, 75 cases (100%) were correctly identified by malignancy through the final diagnoses of paraffin sections. In case of 97 benign frozen sections, 87 cases (89.7%) were benign, 10 cases (10.3%) were malignancy.

Conclusion: The diagnoses between frozen sections and paraffin sections are strongly correlated. Frozen sections taken during semi-rigid MT have the potential to facilitate decision-making prior to talc poudrage, particularly in malignant histology.

PO-241

Application of Comprehensive Nursing Modes in the Treatment of Complicated Central Airway Stenosis with Silicone Stent Placement

Wang,Qin、Wang,Xiangqi、Meng,Lihua
Changhai Hospital, Naval Medical University(Second Military Medical University)

Objective: To explore the nursing interventions for the treatment of complex airway stenosis with silicone tubular stent through a rigid bronchoscope under systemic anesthesia.

Methods: Eighty patients who underwent silicone stenting by a rigid bronchoscope in the treatment of complicated airway lesions from May 2014 to March 2017 were selected. The patients were randomly divided into conventional nursing group (40 patients) and comprehensive nursing group (40 patients). All patients were followed up for 24 months, improvement in shortness of breath, the main complication rate and unintended removal of the stent were observed and compared between the two groups.

Results: After stent placement, improvement in shortness of breath were observed in both groups which was more obvious in comprehensive nursing group ($P<0.05$). Compared with routine nursing group, the incidences of complications were less in comprehensive nursing group, especially in granulation, infection and sputum retention ($P<0.05$). After 24 months of follow-up, the unintended removal rate of stents in patients with comprehensive nursing intervention was significantly lower than that of the routine nursing group ($P<0.05$)

Conclusion: Comprehensive nursing interventions during the treatment of placing silicone tubular stents by rigid Bronchoscopy under systemic anesthesia is of great significance for improving the symptoms of shortness of breath, reducing the incidence of complications and unintended removal rate of the stent. It is worthy of clinical promotion.

PO-242

Photodynamic thoracoscopic fluorescence observation using 5-aminolevulinic acid (5-ALA)

Sakao,Yukinori、Saito,Yuichi、Yamauchi,Yoshikane、Kawamura,Masafumi
Teikyo University Shool of Medicene

Objective: The new possibilities of 5-ALA fluorescent navigation surgery were investigated.

Methods: 60's male. Nodules of 2 cm in size were found on the left S1 + 2 and left S5, and sub-aortic lymph nodes was swollen to 3 cm in size. Positron emission tomography (PET) CT showed accumulation of fluoro-deoxyglucose (FDG) in all three lesions. Three lesions were biopsied under thoracoscopy (partial lung resection, lymph node needle biopsy) to determine the course of treatment. Three hours before the operation, 5-aminolevulinic acid (5-ALA) was taken at 20 mg / kg, and three ports were performed under the arthroscopy.

Results: Intrathoracic observation showed strong red fluorescence in S1 + 2 lesions. There was no apparent red fluorescence in the sub-aortic lymph nodes and S5 lesions. The pathology of each lesion was large cell carcinoma in S1 + 2, granuloma in S5, and metastasis of epithelial malignancy in lymph nodes. In this case, it was suggested that lung lesions may be useful for distinguishing non-neoplastic tumors from tumors. On the other hand, almost no fluorescence was observed in the lymph nodes, despite bulky metastases. The cause may be that viable tumor cells were scarce on the observation surface.

Conclusion: It was suggested that thoracoscopic fluorescence observation using 5-ALA could distinguish between neoplastic and inflammatory changes in lesions.

PO-243

Customised treatments for Airway fistula- Two case reports

Subramanian,Santhakumar、Jaganathan,Venugopal、TH,Deepak
Consultant Pulmonologist

Objective: Airway fistulas are complicated clinical problems and difficult to manage. Though surgical methods are the main stay of treatment, due to patients' clinical condition and comorbidities, alternatively, bronchoscopic methods have to be tried in special situations. Herein we present two such patients, in whom, we had to customise the bronchoscopic methods.

Methods: Case 1 41 years old male, presented to us with an ulcer with pouring pus, on right chest wall. Pus poured out with every cough episode. He had cough and purulent sputum which was more on lying on left lateral position. He had undergone surgical treatment thrice in the past for recurrent bronchopleural fistulae. The last surgery was a right pneumonectomy. Clinically he was thin and emaciated, afebrile with stable vitals. Imaging and subsequent bronchoscopy confirmed a tracheo, broncho cutaneous fistula. As he refused for any surgical procedure, he was tried with bronchoscopic cyano acrylate glue injections, spigot placement, submucosal silver nitrate injections, all of which have failed to close the fistula. Finally, a custom-made silicon 'J' stent was placed from trachea to left main bronchus and appropriate culture guided antibiotic therapy was given for which the fistula has responded very well and the chest wall wound started healing well. Case 2 61 years old male presented with cough, breathing difficulty and right sided chest pain. Clinico radiologically large right recurrent pneumothorax was confirmed and an intercostal tube was placed. Previously he was treated elsewhere with Intercostal tube for traumatic right pneumothorax and ICD was removed after lung expansion. Persistent air leak was noted and it failed to heal by conservative treatment. Patient refused surgery and bronchoscopic glue injection was attempted after localising fistula to right middle lobe. However, as

a persistent air leak could be noticed after glue injection, a medical thoracoscopy was done on the same sitting and glue was sprayed on the visceral pleura where air bubbles could be noticed after pouring saline on lung surface. The fistula started responding in 48 hours and the ICD was removed.

Results: Both the patients did well

Conclusion: There are various medical and surgical options in the treatment of airway fistulas. Clinically presentation varies from patient to patient. There is no guidelines, consensus, or algorithms for the treatment of this entity and there is no strong evidence supporting the use of any one particular device or technique. Hence the treatment of airway fistula should be individualized to each patient.

PO-244

Clinical analysis of 5 cases of tracheobronchial tumors in children and literature review

Zhang,Hailin、Zheng,Yangming、Hu,Xiaoguang、Yu,Gang
The second affiliated hospital of wenzhou medical university

Objective: Tracheobronchial tumors is rare disease in children. This report aim to summarize the clinical features of tracheobronchial tumors in children and to improve the understanding of the disease.

Methods: 5 patients with tracheobronchial tumors with histological confirmed in our hospital from 2017 to 2019 were analyzed, and their clinical manifestations, imaging features, treatment were compared with those reported in literature.

Results: Among the 5 cases, there were 2 males and 3 females, the youngest was 5 years old, the oldest was 15 years old, and the average age was 10.6 years old. The average time from the onset of symptoms to the diagnosis was 3 months, with a minimum of half a month to a maximum of 6 months. The most common clinical symptom was cough, followed by wheezing, fever and hemoptysis, and physical examination revealed the most common sign was decreased respiratory sound. 1 patient with sudden onset respiratory failure was transfered to intensive care unit for mechanical ventilation. Image findings: Chest CT scan revealed presence of tumor in 3 out of 5 cases. Diagnosis: Bronchoscopy revealed tumor in all 5 cases. 4 cases were diagnosed by endoscopic biopsy and 1 case by cervical lymph node biopsy. Pathologically, there were 2 cases of mucoepidermoid carcinoma, 2 cases of anaplastic large cell lymphoma and 1 case of capillary hemangioma. Treatment: 2 cases of mucoepidermoid carcinoma were removed with electrocautery snare resection and received surgical treatment after histological confirmation, 2 cases of lymphoma were treated with chemotherapy, and 1 case of capillary hemangioma presented with massive hemoptysis was received forceps excision under rigid bronchoscope after ronchial artery embolization There were no deaths.

Conclusion: The clinical manifestations of tracheobronchial tumors in children are not specific, which often leads to delayed diagnosis. Imaging examination can provide diagnostic information in most cases. Bronchoscopy and biopsy are the most important diagnostic methods. Option of treatment based on Pathological diagnosis.

PO-245

CT-guided intracavitary drainage for patients with giant emphysematous bulla who were invalid after placement of EBV

Liu,Zhiguang、WU,Huaiqiu、Liu,Wei、Tan,Jianlong、Zhang,Weidong、Deng,Hongying
Hunan Provincial People's Hospital

Objective: For the surgically unfit candidates, CT-guided intracavitary drainage of giant emphysematous bulla(GEB) can be considered as an alternative strategy when one-way endobronchial valves (EBVs) failed.

Methods: In this report, we presented three surgery unfit patients with GEB who were not effective 30-180 days after EBV placement with frequent acute exacerbation. After the EBV were removed under the bronchoscope, CT-guided GEB drainage were performed. By Seldinger method, A central venous catheter with a diameter of 1.7 mm was placed in the bulla. Subsequently, erythromycin lactobionate (0.75 g diluted in 40 ml 50% glucose) was injected in the GEB, the constant negative pressure drainage was begun by a closed drainage bottle after 4 h. In addition, erythromycin lactobionate (0.5 g diluted in 20 ml 50% glucose) was injected in the targeted lobe bronchus in correspondence to the bulla by bronchoscope on d7.

Results: CT scan showed Sufficient collapse of the bulla (Figure1-3). And symptomatic relief was observed after the CT-guided drainage treatment. Patient 1 A 69-year-old male smoker，who was presented to our respiratory department with worsening dyspnea for 6 years. The patient with GEB in the left lower lobe was invalid one month after EBV placement. Figure 1. (A) Chest CT showed a large bulla in the left lower lobe Before the drainage. (B)Chest CT showed a Sufficient collapse of the bulla 14 months after drainage. Patient 2 A 72-year-old male smoker，who was presented to our respiratory department with worsening dyspnea for 7 years. The patient with GEB was not effective after EBV placement in the right middle lobe. But CT scan showed a large bulla in the right lower lobe . Figure 2. (A) Chest CT showed a large bulla in the right lower lobe Before the drainage. (B)Chest CT showed a Significant collapse of the bulla one month after drainage. Patient 3 A 55-year-old female, who was presented to our respiratory department with worsening dyspnea for 3 years. The patient with GEB in the right middle lobe was invalid 3 months after EBV placement. Figure 3. (A) Chest CT showed a large bulla in the right middle lobe Before the drainage. (B) Chest CT showed a Significant collapse of the bulla 15days after drainage.

Conclusion: CT-guided intracavitarybulla drainage is a simple, minimally invasive treatment method for inoperable GEB patients.

PO-246

Recurrent endobronchial metastasis from hepatocellular carcinoma: A case report

Kong,Chen、Ning,Yunye、Xia,Yang、Wang,Qin、Bai,Chong
Changhai Hospital, Second Military Medical University

Objective: Hepatocellular carcinoma is the most common primary hepatic malignancy and represent a poor prognosis. Endobronchial metastasis of hepatocellular carcinoma is rare but life-threatening. Here, we report a case in order to provide a prospective strategy of treatment on endobronchial metastasis.

Methods: In retrospect, there are overall 9 cases with endobronchial metastasis have been reported worldwide and none of them received target therapy. For the first time, we represent a 67-year-old women with recurrent endobronchial metastasis of hepatocellular carcinoma is well controlled by combination of target medicine and bronchoscopy.

Results: A 67-year-old women was diagnosed by hepatocellular carcinoma in 2010. The symptom of cough and hemoptysis appeared and deteriorated rapidly in October 2017. Computed tomography of chest showed masses in right lung and right inferior lobar bronchial, which was confirmed hepatocellular carcinoma by immunohistochemical staining. After several electrosurgical snare resections, the mass continuously recurrented during October 2017 and July 2019. The patient started using Lenvatinib at the dose of 8mg and received electrosurgical snare resection again in July 2019. Computed tomography of chest in November 2019 indicated that the masses in right inferior lobar bronchial shrunk drastically and atelectasis of distal lung improved.

Conclusion: Despite endobronchial metastasis being a rare occurrence, it could cause severe cough, dyspnea and hemoptysis endangering lives. Varies of interventional therapeutic bronchoscopy method, including Nd-YAG laser, ablation, mechanical resection, stent insertion, cryotherapy and brachytherapy, have been utilized on primary and secondary tracheobronchial tumor and turned out to be effective in symptom alleviation. In the era of precision medicine, the combination of the interventional pulmonology technique and systemic therapy based on clinical manifestations and radiography imaging findings of each patient could provide us a promising improvement in treatment strategy.

PO-247

COMPUTED TOMOGRAPHIC STUDY OF COMBINED PULMONARY FIBROSIS AND EMPHYSEMA AND LUNG CANCER

Uenishi,Riki、Ueda,Takahiro、Furuse,Hideaki、Nakatsuji,Yuko、Fujii,Yoshinori、Tanaka,Hidenori、
Yagyu,Kyoko、Matsushita,Haruhiko
Department of Respiratory Medicine, Izumi City General Hospital

Objective: An extremely high incidence of lung cancer has been reported as a complication of combined pulmonary fibrosis and emphysema (CPFE). However, the relationship between the predilection region of the incidence of lung cancer and emphysema or interstitial lesions is still unknown. Furthermore, a highly advanced state of this cancer has been found in several cases, and its complications have reportedly become a poor prognostic factor.

Methods: Study involved 19 patients with CPFE on chest CT examination who were diagnosed with lung cancer by bronchoscopy at Izumi City General Hospital from April 2016 to April 2018 . They were classified into 3 types: A, upper lung emphysema + UIP pattern; B, upper lung emphysema + lower lung interstitial pneumonia; and C, whole lung emphysema + lower lung interstitial pneumonia.

Results: The male:female ratio and mean age were 15:4 and 73.1 years, respectively. Also, the numbers of cases in types A, B, and C were 9 (male:female ratio, 8/1), 6 (3/3), and 4 (4/0), respectively. In addition, the lung cancer sites included the borderline between the fibrotic lesions and normal area (n = 11: A, 6; B, 4; and C, 1) and the emphysema area (n = 8: A, 3; B, 2; and example C).

Conclusion: Some boundary areas have been reported as the most frequent sites of lung cancer with CPFE. Consistent with the published data, in this study, the lung cancer incidence at the boundaries was more frequent. Furthermore, it was more common inside the area affected by emphysema with the case of a prominent emphysematous change.

PO-248

Coexistence of active tuberculosis and cancer: a cases report

Tudor,Elena1、Simionic,Iuriea1、Levcenco,Petru 1、Cozlovschi,Victor1、Simionica,Vadim 1、Bilba,Valeriu2
1. Institute of Phthisiopneumology
2. Institute of Oncology

Objective: Lung cancer and pulmonary tuberculosis are two major public health problems. Tuberculosis and lung cancer rarely coincide with each other and can be mutually imitated [1, 2].

Methods: There are presented two clinical cases with tuberculosis and cancer, including a case with tuberculosis recurrence.

Results: The association of tuberculosis and cancer is intriguing and diverse. A rare case with recurrence of pulmonary tuberculosis, lung cancer and sublingual cancer. These patients suffer from active pulmonary tuberculosis and cancer. The coexistence of tuberculosis and cancer complicates the diagnosis of cancer in a patient with tuberculosis. A diagnostic approach focused on fibrobronchoscopy is essential for early diagnosis. A major problem remains the treatment of cancer in active pulmonary tuberculosis.

Conclusion: The symptoms of tuberculosis and lung cancer overlap. If the health condition of a patient with pulmonary tuberculosis does not improve while being treated for TB, the diagnosis of cancer should be considered. Fibrobronchoscopy performed in patients with tuberculosis contributes to the diagnosis of bronchopulmonary cancer.

PO-249

Management of post-traumatic tracheobronchial injury: multidisciplinary approach

Guliani,Abhinav、Basu,Arup、Kumar,Arvind、Dhamija,Amit
Sir Ganga Ram Hospital， New Delhi， India

Objective: Therapeutic goal in airway injuries is early attainment of safe and patent airway. Primary repair with direct suture or end-to-end anastomosis is the treatment of choice. Many injuries can be missed during the first 24–48hours because of nonspecific symptoms. With time fibro-granulation tissue and organizing hematoma block the distal airway making surgery and post-op period difficult. We present 2 complicated cases of delayed presentation managed by collective effort.

Methods: Case 1: 28year old female developed pneumothorax and subcutaneous emphysema requiring chest-tube drainage following trauma. She had a persistent left lung collapse. She was referred to our hospital on ventilator, 7days post trauma, with a provisional diagnosis of LMB mass. Bronchoscopy revealed near total transection of the

left main bronchus 2cm proximal to the secondary carina with granulation tissue. She was taken up for VATS repair and anastomosis immediately. Post-op she had weaning failure and would require PEEP to maintain airway patency. Check bronchoscopy revealed a stenosis of the repaired site causing retained secretions and recurrent lung collapse. To salvage the anastomosis, dilatation of stenosed airway followed by 10mmX4cm covered SEMS placement under direct bronchoscopic guidance was done. Airway patency was restored upto subsegmental level. Patient could later be weaned and her current X-Ray, 3months later, shows fully expanded left lung. Case2: 20yr old female following trauma developed pneumomediastinum. Bronchoscopy showed complete transection of RMB. She underwent partial thoracoscopic repair at a peripheral center. She came to our hospital, 11days post trauma for weaning failure. Bronchoscopy revealed persisting oblique transection of the RMB involving lower trachea. VATS repair with end-to-end anastomosis was done but she also had active infective mediastinitis. Post-op weaning failure prompted bronchoscopy, which revealed suture dehiscence at lower tracheal level. She was already tracheostomized for weaning failure. Covered Y-SEMS stenting was planned to salvage anastomosis. Involving critical-care and anaesthesia teams, tracheostomy was removed and patient ventilated via LMA. Stent deployer was inserted via tracheal stoma under direct vision of bronchoscope placed at cords. Stent was deployed under direct vision, following which; trachesotomy was put within the stent through the same stoma. Patient was weaned off ventilator within 2days. Video will be presented.

Results: Near normal airway anatomy achieved.

Conclusion: Multidisciplinary approach is necessary for successful management of delayed tracheobronchial injury. Bronchoscopy is crucial at many steps pre and post surgery in such patients. Stenting may be necessary and is effective for salvaging anastomosis.

PO-250
Endobronchial aspects in pulmonary tuberculosis

Tudor,Elena、Simionica,Iurie 、Levcenco,Petru 、Cozlovschi,Victor、Simionica,Vadim
Institute of Phthisiopneumology

Objective: Pulmonary tuberculosis is an infectious disease with high prevalence and incidence [1]. A number of studies demonstrate the importance of bronchoscopy in diagnosing pulmonary tuberculosis in patients with sputum negative, but it is important to determine the role of fibrobronchoscopy in diagnosing endobronchial pathology in patients with pulmonary TB [2, 3, 4]. The aim of the study was to determine the importance of fibrobronchoscopy in the diagnosis of endobronchial pathology, concurrent with pulmonary tuberculosis.

Methods: A retrospective study, which included the examination of 1403 patients with pulmonary TB, over the age of 18 years, at which diagnostic bronchoscopes were performed, within the Institute of Phthisiopneumology "Chiril Draganiuc", between 2016-2018.

Results: During 2016-2018 there were performed 1403 diagnostic bronchoscopes in patients with pulmonary tuberculosis, (2016 – 462, 2017 - 517, 2018 - 424). Bronchial cancer was diagnosed in 86 (6.2%) cases, in particular, neoplastic lesions were present in patients with infiltrative tuberculosis (58% cases). Tuberculosis of the bronchi was diagnosed in 111 cases (7.9%), of which: bronchial tuberculosis, infiltrative phase 15 (13.5%) cases, the edematous-hyperemic-oedematous-hyperaemic form and fibrostenotic 5 (4.5%) cases, scar stenosis - 91 (82.0%). Non-specific endobronchitis was found in 780 (55.6%) patients, catarrhal form in 487 (62.3%) patients, purulent - 167 (21.5%), hypertrophic - 61 (7.9%) and atrophic - 65 (8.3%) patients. The endoscopic picture within the norm limits was established in 426 (30.3%) patients.

Conclusion: The obtained results demonstrate the need to perform fibrobronchoscopy in patients with pulmonary tuberculosis in order to properly diagnose endobronchial pathology in pulmonary tuberculosis, including the detection of early-stage lung cancer. An important moment to take measures to develop the strategy of an effective treatment, to prevent the formation of post-tubercular scars, to heal the non-specific process.

PO-251

Rapid on-site evaluation in medical thoracoscopy specimens for diagnostic performance and consistency in pleural disease

Xiao,Kui、Zhu,Zhiruo、Wang,Yaohui、Xia,Shulan、Xiang,Jing、He,Wenlong、Shi,Zhihui、Huang,Shi、Zhang,Yeying、Zheng,Dongyuan、Zhou,Rui、Chen,Ping
The Second Xiangya Hospital, Central South University

Objective: Medical thoracoscopy is a useful and efficient tool in the diagnosis and management of pleural disease. The clinical value of rapid on-site evaluation (ROSE) have been proved to be useful in transbronchial lung biopsy and transbronchial needle aspiration. We evaluated the diagnostic performance of ROSE in MT biopsy specimens and the consistency between ROSE and final histopathologic diagnosis.

Methods: 154 exudative pleural effusion patients received MT for further diagnosis were enrolled. MT was performed during local anaesthesia with or without conscious sedation, using the semi-rigid pleuroscope. The biopsy specimens were stained by the Hemacolor rapid staining method to perform ROSE. The initial impression of the macroscopic appearance of thoracoscopists was recorded and compared with the ROSE results and final pathological diagnosis by immunohistochemistry(IHC) .

Results: All patients received MT, thoracoscopic pleural biopsies and ROSE. Group A (n=64) consisted of patients with benign disorders and group B (n=90) with malignancy. Area under the curve of ROSE for the diagnosis of malignancy was 0.938 (95% CI: 0.781–0.974, P<0.001), with a sensitivity of 90.48%, specificity=97.14%, diagnostic accuracy of 89.2%, positive predictive value of 97.44% and negative predictive value of 89.47%. Intermodality agreement between ROSE and histopathology was good (κ ± SE=0.628 ± 0.089, P<0.001). Area under the curve of the thoracoscopists' impression of macroscopic appearance was 0.74 (95% CI: 0.59–0.86, P=0.001), with a sensitivity of 83.12%, specificity of 45.7%, positive predictive value of 54.18% and negative predictive value of 88.53%.

Conclusion: Rapid on - site evaluation showed high accuracy for predicting malignancy during MT. The thoracoscopist can use ROSE as an on - site preliminary diagnosis, especially when the macroscopic appearance seemed indeterminate.

PO-252

A Case Report Of Pulmonary Blastoma

Zhan,Xiaoyan1、Shi,Liyong1,2
1. the Second Affiliated Hospital of Fujian Medical University
2. Respiratory Medicine Center of Fujian Province, Quanzhou, China

Objective: To explore the main points of clinical diagnosis of pulmonary blastoma in order to improve the understanding diagnosis and treatment of the disease.

Methods: A 72-year-old man presented with symptoms of hemoptysis for 1 month and aggravated for 3 days. One year ago, the patient visited a hospital in our city for hemoptysis,biopsy of lung by electronic bronchoscope and CT-guided percutaneous lung biopsy failed to confirm the diagnosis. After referrals to multiple hospitals, repeated bronchoscopy and lung biopsy, most of multiple hospitals say that it will more probably be lung cancer. With irregular taking of immunotherapy, he still had recurrent hemoptysis with weight loss of 5Kg in the past year. Three days ago, there was no obvious inducement to re-spit hemoptysis, and the whole mouth was bright red blood sputum. The amount of each hemoptysis was about 3-5ml and 10-20 times a day,with exertional dyspnea Symptoms caused by light ctivity, and relieved after rest.Then he was admitted the emergency department of our hospital. The patient has a heavy smoking for more than 20 years. The pathological result of biopsy of lung by electronic bronchoscope and CT-guided percutaneous lung biopsy support diagnosis of teratoma. Consider the diagnosis of teratoma, transferred to thoracic surgery for surgical treatment, postoperative pathology: "left pulmonary epithelial pneumoblastoma with bleeding, necrosis, calcification, ossification (cystic solid).

Results: Pulmonary Blastoma

Conclusion: Pulmonary blastoma(PB) is a rare primary lung malignant tumor.For pulmonary space-occupying lesions that cannot be clearly diagnosed by repeated biopsy, the possibility of this disease should be considered, and multi-site biopsy should be carried out on the tumor to fully communicate with the pathology department, which is expected to improve the diagnosis rate. pulmonary blastoma is mainly treated by surgical resection, which is similar to radical resection of lung cancer. Extended surgical resection plus mediastinal and hilar lymph node dissection, postoperative radiotherapy and chemotherapy can be used as auxiliary methods.

PO-253

Peripherally located lung Cancer diagnosed by endobronchial ultrasound-guided transbronchial biopsy and bronchial washing with or without a guide sheath: retrospective data from a teaching hospital.

Xiao,Kui1、Jiang,Jiehan1,2、Zhu,Zhiruo1、Wang,Yaohui1、Xia,Shulan1、Shi,Zhihui1、He,Wenlong1、Huang,Shi1、Zhang,Yeying1、Zheng,Dongyuan1、Zhou,Rui1、Chen,Ping1
1. The Second Xiangya Hospital, Central South University
2. Changsha Central Hospital

Objective: Endobronchial ultrasound-guided transbronchial biopsy with a guide sheath (EBUS-GS) is developed for diagnosing peripherally located lung cancers. However, the diagnostic yield varies among different centers. This study aimed to evaluate the efficiency of transbronchial biopsy (TBB) and bronchial washing guided by EBUS with or without GS.

Methods: The results of 890 patients underwent TBB and bronchial washing for diagnosis of peripheral lung cancer were retrospectively evaluated. EBUS-GS-TBB was performed in 431 (group A), and 459 patients (group B)

underwent EBUS and TBB without GS, respectively; the medical records were examined, and results from the two groups were compared by using the Student t-test.

Results: The diagnostic sensitivity for lung cancer was 71.7% in group A and 57.8% in group B (P=0.066) while using TBB and bronchial washing. The diagnostic sensitivity for lesions ≥20mm was 82.6% in group A and 73.9% in group B (P=0.289). Moreover, the diagnostic sensitivity for lesions 10-20mm was 56% in group A and 33.4% in group B (P=0.0003); the diagnostic sensitivity with TBB alone was 61.4% in group A and 43% in group B (P=0.047). The diagnostic sensitivity with TBB alone for lesions ≥20mm was 72.5% in group A and 46.9% in group B (P=0.055). Moreover, the diagnostic sensitivity for lesions 10-20mm in size was 41.3% in group A and 23.7% in group B with TBB alone (P=0.134).

Conclusion: EBUS-GS with TBB and bronchial washing is more effective in diagnosing peripherally located lung cancers sized < 20mm.

PO-254

Treatment of central airway stenosis secondary to tracheal tumor by holmium laser bronchoscopy in 1 case and literature review

Liu,Xiangteng、刘翔腾
Boai Hospital of Zhongshan Affiliated to Southern Medical University

Objective: To strengthen the understanding of central airway stenosis in children and observe the clinical effect of holmium laser therapy.

Methods: A case of central airway stenosis caused by secondary granulation tissue and suture after tracheal schwannoma resection in an 11-year-old male was performed by holmium laser bronchoscopy, and the literature was reviewed.

Results: After the operation of tracheal schwannoma, the child presented progressive cough, wheezeing and dyspnea, and could not lie supine.Pulse oscillation lung function index: Respiratory impedance (Zrs) : 281.4%, Total airway resistance (R5) 245.8%, airway resistance increased obviously.After the treatment with holmium laser bronchoscopy, the cough of the children was significantly alleviated, and the wheezing and dyspnea were alleviated. The pulmonary function indexes of pulsed oscillation were reviewed: Z5 138.7% and R5 136.0%. The airway resistance was significantly decreased, and there were no complications during the treatment.

Conclusion: Secondary central airway stenosis after tracheal schwannoma in children is rare, and bronchoscopy can definitely diagnose it.Resection of granulation and sutures by holmium laser under bronchobronchial guidance was effective, safe and reliable.

PO-255

Study on the correlation of the activation site and number with the clinical response of bronchthermoplasty

Long,Fa、Huang,Zhihui、Huang,Wenting、Long,Liang、Hu,Fengbo、Fu,Peng、Gan,Jingfan、Dong,Hongbo、Yan,Guomei、龙发
University of Chinese Academy of Sciences Shenzhen Hospital

Objective: To analyze the efficacy of 106 patients with refractory asthma treated by bronchial thermoplasty (BT), and to explore the correlation of the activition site and number with the clinical response post BT.

Methods: A total of 106 consecutive patients with refractory asthma who underwent three BT procedures in our hospital from May 2016 to May 2019 were included as study subjects. The preoperative baseline data, the number of activations of each BT operations including the left and right main bronchus were collected from 106 patients. The pre-bronchodilator FEV 1%, FEV1, and FVC were measured in the 1 day before and 6 months after each operation, meanwhile, ACQ scores were estimated, and changes in lung function and ACQ scores were evaluated before and after BT. The clinical response measure was change in the ACQ score measured at 6 months post BT. The correlation of the activition site and number with clinical response were explored.

Results: 106 patients with refractory asthma delivered 191.34 ± 31.13 activitions, and the ACQ score and lung function were improved compared with those before BT (both $p < 0.05$). According to whether include the left and right main bronchus were ablated, the 106 patients were divided into the unablated group (n = 55) and the ablated group (n = 51). There were no significant differences in the baseline,activation frequency, ACQ score and lung function of both groups (both $P > 0.05$). The activation frequency ≥200 is significantly better than the activation frequency <170 in ACQ score and lung function. Among them, the minimal clinically significant improvement in ACQ of ≥0.5 was observed in 89 out of 106 patients named response group, other than 17 patients named non-response group. The age, smoking rate, activation frequency, the third BT activation frequency, FEV1% predicted and baseline ACQ score of the two groups have statistically significant (all $p < 0.05$). Using multiple linear regression models, baseline ACQ and baseline FEV1% predicted predicted the response($p<0.05$). There is a negative correlation between the change in ACQ scores at the 6 months after BT and the third BT surgery activation frequency, $r = -0.239$ ($p = 0.013$).

Conclusion: The number of activations has a certain correlation with the clinical response after BT. Patients with an activation frequency > 200 are significantly better than patients with an activation frequency <170; activation of the main bronchus has no significant effect on clinical response post BT.

PO-256

A case report of Aspergillus Empyema

Zhang,Yan、Zhou,Rui
The Second Xiangya Hospital, Central South University

Objective: Aspergillus species is one of the commonest causes of fungal infections, ant it is a mycelial fungus formed of filaments that penetrate the airways when its spores are inhaled, and is rarely located in the pleura.

Methods: We report a case of aspergillus empyema thoracisin a previously healthy male. He had a fever, night sweats and left-sided chest pain. Chest CT showed a left encapsulated pleural effusion with a thick wall, and local hospital drained 1400ml of brown exudative pleural effusion.He did not show a clinical improvement despite antituberculous and antibacterial treatment. The patient presented to our department, we performed medical thoracoscopic debridement which revealed tough fibrinous adhesions with pleural thickening and did chest tube drainage. Pleural fungus culture showed Aspergillus fumigatus and chest wall biopsy revealed numerous fungal hyphae.

He received treatment with medical thoracoscopic debridement for four times, antifungal irrigation of the pleural cavity with sodium bicarbonate and urokinase, systemic antifungal combination therapy containing voriconazole.

Results: He was showed good clinical and radiological recovery.

Conclusion: Empyemas are rare presentations of fungal infection, the aspergillus empyema is a rare clinical entity.

PO-257

Endoscopic metallic stents implantation for patients with malignant central airway stenosis

Zhou,Yiping、Chen,Xiaoke、Liu,Hui、Xia,Liping、Liu,Nian、Yu,Haiqiong、Lin,Hairong
The Eighth Affiliated Hospital, Sun Yat-sen University

Objective: To investigate the feasibility and efficacy of metallic stentsfg for patients with malignant central airway stenosis

Methods: 24 patients with malignant central airway stenosis received metallic stents implantation since December 2014. The patients ranged in age from 40 to 87 years, including 14 patients>60 years old. In all cases, tumor growth patterns were divided into 4 cases of extra-luminal, 2 cases of intra-luminal, and 18 cases of mixed. Tumor source were as follows: bronchogenic carcinoma(n=15), thyroid cancer(n=4), esophageal cancer(n=4) and lymphoma(n=1).Pathological types were as follows: squamous cell carcinoma(n=12), adenocarcinoma(n=8), small-cell carcinoma(n=3) and lymphoma(n=1). Locations of airway obstruction and stenosis were distributed as trachea(n=10), unilateral main bronchus(n=6), trachea and one side main bronchus（n=3）, bilateral main bronchus with carina(n=3), trachea and both sides main bronchus(n=2).Of the 19 patients evaluated as stage IV according to The Medical Research Council (MRC) dyspnea scale, respiratory failure occurred in 6 patients from the outer court with endotracheal intubation. 13 patients received stent placement through rigid bronchoscope, and 11 patients underwent stent placement through flexible bronchoscope. Category of stent types were as follows: L-type stent(n=1), Y-type stent(n=4), sigma coated stents(n=12), bare stents(n=7), Boston science stents (n=5). No complication such as infection, increased hemoptysis. 22 patients received postoperative radiotherapy or continued chemotherapy or tumor targeted therapy, whereas 1 patient with thyroid cancer and 1 patient with esophageal bronchial fistula of esophageal cancer did not receive any anticancer treatment. The postoperative survival period of the 21 deceased patients was 26 days to 31 months, with median 6.2 months. Short survival period was mainly associated with systemic failure, involvement of more than two branches of the air passage or rapid tumor growth.

Results: The stents was successfully implanted in 22 patients, while 2 stents was improperly removed and reinserted immediately in 2 patients. After stent implantation, the blood oxygen saturation improved in the whole cases. The symptoms of dyspnea were completely alleviated in 18 patients and improved in 6 patients.

Conclusion: Bronchoscopy guided metallic stent implantation can alleviate dyspnea in patient with malignant central airway stenosis. Rigid bronchoscopy and/or ablation technology should be performed for patients with obvious intracavitary stenosis. However, stent can be placed directly to alleviate dyspnea in patient with critical situation. Comprehensive antitumor therapy after stenting results in extended survival period.

PO-258

Silicone stent implantation in post-tuberculosis tracheobronchial malacia with cicatricial stenosis: a case report

Chen,Xiaoke、Zhou,Yiping、Peng,Yue、Liu,Nian、Xia,Liping
The Eighth Affiliated Hospital, Sun Yat-sen University, Shenzhen, China, 518033

Objective: Silicone stent can be placed for long-term with less incidence of sputum retention, granulation hyperplasia and other complications, which is suitable for benign airway stenosis. Post-tuberculosis tracheobronchial stenosis is common in China. However, as silicone stents cannot be customized in China, it is difficult to place them sometimes. Now we report a case in such a clinical setting.

Methods: A 57-year-old female was admitted to the hospital on September 25, 2018 due to "repeated cough and sputum coughing for more than 2 years, aggravation with wheezing for more than 1 year and recurrence for 20 days". The patient was diagnosed as bronchial tuberculosis in outer hospital in January 2016, and received balloon dilatation of the right main bronchus one years ago. However, bronchoscopy 20 days ago suggest severe softening of the lower trachea and right main bronchial with cicatricial stenosis, and right upper bronchial atresia, so this patient was transferred to our hospital for stent insertionA Y-shaped silicone stent (14-10-10, tracheal branch 5cm, right branch 2.7cm, left branch 1.5cm) was selected. 13# rigid bronchoscopy was inserted under general anesthesia, and the access was limited 1cm above the carina and tracheal tear was found. Then the fully lubricating stent with tubers removed and shorter thacheal branch (4cm) was installed in a 10.75mm pusher difficultly. The stent was successfully implanted through 12# rigid bronchoscope.

Results: CT reexamination showed mediastinal emphysema. The patient recovered well and discharged 10 days later. And the following 4 times bronchoscopy indicated appropriate stent position with little sputum retention and mild granulation hyperplasia, for which cryotherapy was performed twice.

Conclusion: In this case, tracheobronchial malacia with cicatricial stenosis is suitable for silicone stent implantation. The conventional Y-type stent pusher matched the13 # rigid bronchoscope, whereas, due to the cicatricial stenosis, it’s hard to place the 13 # rigid bronchoscope, then the stent was customized to place in a 10.75mm pusher difficultly. A customized Y-type stent with a small trachea branch and/or a larger pusher (such as 11.75mm) with a 12# rigid bronchoscope may be a solution in such a case.

PO-259

Two fiberoptic bronchoscopy guidance for the treatment of tracheoesophageal fistula by using ventricular septal defect occlude device

Zhang,Changwen1、Gan ,Luoman2、Li,Yu1、Li,Wentao1、Fang,Ni1、Liang,Xiangdong1、Liu,Guangnan1

1. Second Affiliated Hospital of Guangxi Medical University
2. Qinghai University

Objective: To explore the effect of ventricular septal defect occluder in the treatment of a complex tracheoesophageal fistula（TEF）and share experience.

Methods: We report a case of a 54-year-old woman with a complex tracheoesophageal fistula（TEF）,which was successfully closed by using ventricular septal defect occlude device.

Results: The tracheoesophageal fistula was successfully treated by using ventricular septal defect occlude device with two fiberoptic bronchoscopy guidance , which was larger than 5 mm in diameter, by means of the insertion of ventricular septal defect occlude device (MJFVM06(6-10-10)). The initial outcome was as expected.

Conclusion: Using of a ventricular septal defect occlude device may be a promising option for the treatment of tracheoesophageal fistula.

PO-260

Virtual bronchoscopy-guided transbronchial biopsy for aiding the diagnosis of peripheral lung lesions

Huang,Kuo-Yang1、Chen,Huang-Chi 2、Chung,Che-Liang2、Chen,Chih-Yu2、Lin,Sheng-Hao1
1. Changhua Christian Hospital
2. Yuanlin Christian Hospital

Objective: This study aimed to evaluate the clinical value of virtual bronchoscopy (VB) in aiding the diagnosis of peripheral lung lesions by transbronchial biopsy (TBB).

Methods: A total of 24 consecutive patients with peripheral pulmonary shadows or lesions who received VB-guided TBB were evaluated retrospectively. VB was reconstructed from 1 mm-thick slice images of multi-detector computed tomography (MDCT) and established by OsiriX, an open source software. Experienced pulmonologists inserted the conventional ultrathin bronchoscopes into the target bronchus under direct vision following the VB images.

Results: A total of 24 patients were finally enrolled (17 men and 7 women; age range, 33–93 years; median, 65.5 years). Diagnosis was established in 20 patients (17 malignant and 3 benign lesions) with diagnostic yield of 83.3% (sensitivity: 89.5%, specificity: 40.0%, positive predictive value: 85.0%, negative predictive value: 50.0%, and accuracy: 79.17%). The diagnostic rate was 92.3% with CT bronchus sign and 72.7% without CT bronchus sign ($p = 0.209$). The diagnostic rate was 80% with the lesions measuring less than 30 mm and 85.7% with lesions more than 30 mm ($p = 0.717$). One patient whose lesion was 24 mm over RUL exhibited a complication of pneumothorax and recovered spontaneously without drainage.

Conclusion: The use of an ultrathin bronchoscope and simulation with VB reconstructed using high-quality MDCT image with OsiriX is considered to improve the pathological diagnosis of peripheral lung lesions. The proposed method is also easy, low cost and an available measure for correct diagnosis by interventional pulmonologist when no endobronchial ultrasound bronchoscopy is available.

PO-261

The application of extended nasotracheal intubation for rescuing from massive hemoptysis during rigid bronchoscopy

Zhang,Meihua、Xu,Xiaoping、Chen,Lili、Ke,Mingyao
The Second Affiliated Hospital of Xiamen Medical College

Objective: Massive hemoptysis is a fatal intraoperative complication during rigid bronchoscopy. The aim of our study is to explore the value of extended nasotracheal intubation in the management of massive hemoptysis during rigid bronchoscopy.

Methods: We reviewed the history medical from March 2018 to November 2019. A total of 5 patients who suffered from massive hemoptysis during rigid bronchoscopy and was rescued by extended nasotracheal intubation were enrolled. Procedure process: stainless steel guidewire was placed in the lower trachea (lesions at the upper and middle trachea) or the contralateral inferior lobar bronchus(the lesions at the right/left bronchus) by transnasal endoscopy. The extended nasotracheal intubation (size: 5.5#) assembled with inner core was connected with the guidewire. And the extended nasotracheal intubation was left in vitro and stood by. After all the preparation, the rigid bronchoscopy was inserted into the airway to detect and manage the lesion. The rigid bronchoscopy was removed immediately once the massive hemoptysis occurred. The extended nasotracheal intubation was pushed into the airway through nasal cavity and across the lesion rapidly. After that, the guidewire and inner core was pulled out and the aerocyst was inflated to fix the intubation. The target of application of the nasotracheal intubation was compression hemostasis. Meanwhile the intubation could be connected to ventilator that provide assisted ventilation. The success of hemostasis and the improvement of blood oxygen were recorded.

Results: All the 5 patients suffered from massive hemoptysis during the procedure achieved hemostasis immediately after insertion of the extended nasotracheal intubation. Hypoxemia was happened in 2 patients during the procedure and the blood oxygen of them was returned to normal quickly after ventilation.

Conclusion: The insertion of extended nasotracheal tracheal was an quick and easy step to prevent the blood flow into the normal side of airway and provide channel for ventilation. It may increase the successful rate of hemostasis and improved the safety of rigid bronchoscopy.

PO-262

Experimental staphylococcus aureus pleural empyema model: The effect of urokinase and DNase in biofilms

Li,Jinlong1、Zhang,Zhenqiang 1、Liang,Jinhua1、Wang,Ke2
1. Guangxi Medical University
2. The First Affiliated Hospital of Guangxi Medical University Respiratory and critical care medicine

Objective: The study was to observe the formation of biofilm in Chest tubes and to determine if a combination of DNase is effective in preventing the formation of pleural pus and adhesion and reducing biofilm in a rabbit model of empyema.

Methods: Twelve male New Zealand rabbits, weighting 2.5±0.2kg, were randomly divided into two groups: a control group and a preventive group. Chest tubes were placed into the right pleural cavities of all rabbits in the sixth intercostal space. The control group was infused with 108 CFU staphylococcus aureus via the intrapleural injection and flush the tube with 3ml saline. The treatment drugs (30,000 IU urokinase/ml， and 1mg DNase/ml) were introduced into the right pleural cavities in the preventive group and flush the tube with 1ml saline while received the same dose of S.

aureus as control group. The Chest tubes was buried in the chest cavities of the rabbits. We evaluated pleural adhesion scores and collected the Chest tubes to conduct bacterial culture and crystal violet staining. And Part of the pleural tissue was taken to perform HE staining.

Results: The pleural adhesion scores in prevention group (0.833±0.408) was significantly lower than that in control group (2.600±0.540, P<0.05). Large amount of pus and fibrin deposits were observed in the pleural cavity of the control group rabbits with the obvious pleural adhesion. On the contrary, the rabbits of prevention group had less pus and pleural adhesion. Colony counting of the drainage tube from control group was log10(4.49±0.22) CFU/ml, while that from prevention group was log10(6.20±0.22) CFU/ml. And the OD value (OD570) of catheter crystal violet staining was 0.1656±0.0356 and 0.6362±0.7248 respectively. The above two indicators in the prevention group were significantly lower than those in the control group (P<0.05). Histopathological analysis showed that there were obvious pleural thickening, vascular congestion and neutrophil infiltration in the control group, while the pleural injury in the prevention group was slighter, and the pleural thickening as well as neutrophil infiltration were not as serious as those in the control group.

Conclusion: In the experimental rabbit model of S. aureus empyema, biofilms were observed in the thoracic drainage tube. While the application of Urokinase and DNase in the pleural cavity can significantly prevent the formation of S. aureus empyema and reduce the formation of biofilms on the thoracic drainage tube.

PO-263

Pulmonary alveolar proteinosis due to Pneumocystis carinii in type 1 hyper-IgM syndrome

Zhang,Feizhou、Tang,Lanfang
Zhejiang University School of Medicine of Children’s Hospital

Objective: Pulmonary alveolar proteinosis (PAP) is a rare diffuse lung disease. Reports of rare cases of PAP due to Pneumocystis carinii (P. carinii) exist in infants with immunodeficiency diseases, but no cases have been reported till date in pediatric patients with type 1 hyper-IgM syndrome (HIGM1).

Methods: Herein, we present a case of PAP secondary to P. carinii in an infant with HIGM1. He was admitted to our unit because of cough and tachypnea.

Results: Lung biopsy confirmed the diagnosis of PAP, whereas hexamine-silver staining of the bronchoalveolar lavage fluid identified P. carinii infection. No other probable cause of PAP was observed. Whole exome sequencing indicated a novel c.511dupA (p.I171N*30) hemizygous mutation in the CD40 ligand (CD40LG) gene. He was cured with bronchoalveolar lavage and compound sulfamethoxazole tablets.

Conclusion: To our knowledge, this is the first reported case of P. carinii as a reversible cause of PAP in an infant with HIGM1.

PO-264

Plastic bronchitis due to Adenovirus infection

Zhang,Feizhou、Tang,Lanfang
Zhejiang University School of Medicine of Children's Hospital

Objective: Plastic bronchitis (PB) frequently occurs as a serious postoperative complication of the Fontan procedure. The definitive causes of PB are unknown.

Methods: Herein, we report a pediatric case of PB secondary to adenovirus infection. A 4-year-old girl was admitted at general pediatric ward for cough since 2 weeks and fever since 11 days. Consolidated lesions were noted in the right upper and both lower lung lobes. Extracorporeal membrane oxygenation was performed because the patient's respiratory failure remained unalleviated despite the use of a ventilator. Bronchial dendritic casts were extracted by flexible bronchoscopy, and the patient's breathing improved.

Results: Pathological examination of the dendritic cast confirmed the diagnosis of type I PB. The exfoliated cells of sputum and cells from bronchoalveolar lavage fluid were positive for adenoviral antigen. Human adenovirus 7 was detected by next-generation sequencing of the bronchoalveolar lavage fluid. She recovered and was discharged 39 days after admission without recurrence of cough or wheezing.

Conclusion: PB due to human adenovirus 7 infection should be considered in children with persistent respiratory failure. Flexible bronchoscopy should be performed early to confirm diagnosis and to remove airway obstructions if any.

PO-265

Different Airway Structure Changes on Computed Tomography and Efficacy after Bronchoscopic Volme Reduction Using Two Different Valves Respectively for Advanced Chronic Obstructive Pulmonary Disease

Guo,Fangfang、Wang,Guangfa
Peking university first hospital

Objective: Bronchoscopic lung volume reduction (BLVR) using Zephyr Endobronchial Valve (EBV) and Intrabronchial Valve (IBV) has been showed to improve lung function and exercise capacity in advanced Chronic obstructive pulmonary disease (COPD). It is unclear whether the airway structure changes after the therapy and if there is any difference of efficacy between different valves.

Methods: We performed a retrospective study on patients treated with EBV or IBV in our institution. We compared the changes of 2nd-, 3rd- and 4th-generation bronchial structure after therapy including wall thickness (WT), WT%, intraluminal area (LA), wall area (WA) and WA% at the midpoint of each level of airways, measured by high-resolution computed tomography (HRCT) automatic analysis software. The clinical outcomes including lung function testing, 6-min walk distance (6MWD) and modified Medical Research Council (mMRC) dyspnea scale between two groups were also compared.

Results : 19 of 24 patients were included in this study, 11 treated with EBV and 8 with IBV. The 1-month,6-month and 12-month follow up were conducted. At level of 2nd-generation, the LA significantly increased in EBV group while decreased in IBV group at 1-month (EBV group with 13.50[2.70, 18.00]mm3 while IBV group with -7.85[-28.13, 0.43] mm3; P=0.017) in the ipsilateral non-target bronchi. At level of 3rd-generation, there was statistically significant difference in changes of WT% (1-month: -5.00[-12.00, 1.00]% in EBV group and -0.50[-6.75, 8.00]% in IBV group,

P=0.043), in changes of LA (1-month: 1.60[-1.50,9.90]mm3 in EBV group and -3.00[-10.55, 0.58]mm3 in IBV group, P=0.005) and in changes of WA% (1-month: -9.00[-17.00, -1.00]% in EBV group and -1.00[-9.75, 11.25]% in IBV group, P=0.037) in the ipsilateral non-target bronchi. As for the contralateral bronchi, only WT% and WA% decreased at 12-month in EBV group. At level of 4th-generation, there was no significant difference in airway structure changes in the ipsilateral non-target bronchi between two groups. However, in the contralateral bronchi, the WT% and WA% decreased significantly at 6-month in EBV group (△ WT% with -2.50[-7.00, -1.00]%, P=0.047; △ WA% with -3.50[-10.75, -1.25]%, P=0.046) compared to IBV group. For the clinical outcomes, patients treated with EBV who were more severe got greater improvements in 6MWD when compared with patients with IBV (1-month: 150.00[84.00, 169.50]m vs -5[-74, 106]m, P=0.019; 12-month: 145.50[69.00, 204.00]m vs -50.00[-153.00, 113]m, P=0.024).

Conclusion: Patients receiving BLVR with different valves including EBV and IBV could present with different airway structure changes and responsiveness.

PO-266

Post intubation tracheal stenosis and the role of cryotherapy

Tashi,Eritjan、Teferici,Alma、Kokici,Fahri、Kapisyzi FCCP,Prof.Dr. Perlat
University Hospital Shefqet Ndroqi. Tirana. Albania

Objective: Tracheal stenosis after intubation is the most common cause of benign narrowing1. Treatment of stenosis requires complex approach and can be done surgically or with endoscopic techniques. Endoscopic cryotherapy technique is a safe method for the removal of granulation or fibrous tissue and restoration of airway lumen. Cryotherapy induces coagulation necrosis of selected tissue and destruction of the lesion. Cryotherapy can be done in two ways. The first involves repeat freezing and thawing to induce tissue necrosis. The second is a pulling out method or cryoadhesion extracting frozen tissue which is attached to a cryoprobe. We report a case of post intubation tracheal stenosis that was successfully treated with bronchoscopic cryotherapy.

Methods: Case report of post intubation tracheal stenosis treated successfully with cryotherapy

Results: A 50 year old man was admitted to hospital due to severe stridor and severe hypercapnic respiratory failure. Two months prior he had been under endotracheal intubation for three weeks while being treated for cerebral hemoarragy do to automobile trauma. The symptoms of dyspnoea and wheezing worsened after discharge from hospital. Tracheal stenosis was suspected on Chest CT done in the emergency unit due to history of trauma and long intubation time. CT image showed irregular luminal narrowing of the trachea with the smallest diameter 4 mm and bronchoscopy revealed web like tracheal stenosis. The diameter of the lesion was appoximatley 4 mm. Tracheostomy was done under the level of stenosis for secure ventilation during and after the procedure. Under conscious sedation with propofol a flexible cryoprobe in the working channel of the bronchoscope was passed in the transoral route. The tip of the bronchoscope was positioned directly on the web like stenosis and a freeze – thaw course of 30 seconds was applied.

The procedures lasted 1 hour approximately with directions from 9 o' clock to 3 o' clock. Interval of intervention was every two weeks and showed gradual improvement of the lesion with luminal enlargement up to 12 mm in diameter after 3 months. Short course of steroids was applied after each procedure. Cryotherapy was performed in 6 sessions and patency of more than 70% of tracheal lumen was achieved in 6 months. No complication occurred during and after the procedure.

Conclusion: Bronchoscopic cryotherapy can be considered as an alternative or primary treatment for simple post intubation tracheal stenosis. Endoscopic procedures can provide good results without complication.

PO-267

Application of alveolar lavage fluid to detect common pathogen nucleic acid in community acquired pneumonia

LI,XI、ZHANG,QIAN、GUO,YEHUI、XIAO,QIANG、RONG,FU
Shunde Hospital, Southern Medical University (The First People's Hospital of Shunde)

Objective: Loop-mediated isothermal amplification (LAMP) was first proposed by Notomi in 2000, and it has the advantages of quickness, simplicity, sensitivity, and high specificity in the diagnosis of pathogens. In this study, LAMP technology was used to rapidly detect 11 respiratory pathogenic nucleic acids in alveolar lavage fluid from patients with community-acquired pneumonia(CAP), in order to prove the clinical significance of this method.

Methods: 175 patients with CAP were enrolled in this study. The consultation time of these patients was from September 2018 to August 2019 and the location was at the Department of Respiratory Medicine, Shunde Hospital, Southern Medical University (the First People's Hospital of Shunde Foshan). The selected patients can be clearly diagnosed and meet the inclusion criteria. All patients obtained bronchoalveolar lavage fluid(BALF) through bronchoscopy. 175 BALF specimen were detected by loop-mediated isothermal amplification(LAMP) technique, and then the distribution of pathogenic bacteria was analyzed. Statistical analysis was performed using the SPSS software.

Results: In 175 cases of BALF from patients with CAP, the overall positive rate of LAMP was 36.57% and bacterial culture was 10.28%. The positive rate of LAMP technique was higher than that of bacterial culture. The main pathogens were Pseudomonas aeruginosa, Haemophilus influenzae and Mycoplasma pneumoniae. The results of the two methods were consistent in 124 cases, accounting for 70.86%. The consistency of Pseudomonas was high (Kappa=0.675) by two different methods. According to age group, the infection rate of Mycoplasma pneumoniae in the young group was higher than in the middle-aged group ($P<0.05$). According to the presence or absence of underlying diseases, there was no significant difference in the positive rate between the two methods ($P>0.05$).

Conclusion: LAMP has the advantages of rapidity and accuracy, which may be may be helpful to know the pathogenic bacteria as soon as possible, and therefore may improve the choice of antibiotic therapy and the efficacy of antibacterial therapy.

PO-268

The Airway Structure Changes on CT after bronchoscopic Lung Volume Reduction with Valves for Advanced COPD

Guo,Fangfang、Wang,Guangfa
Peking university first hospital

Objective: Bronchoscopic lung volume reduction (BLVR) using valves has been shown to improve lung function and exercise capacity in advanced chronic obstructive pulmonary disease. However, the changes of airway structure after the therapy is still unclear.

Methods: A retrospective study on patients treated with valves was performed to evaluate the changes of airway structure including wall thickness (WT), WT%, intraluminal area (LA), wall area (WA) and WA% in 2nd-to 4th-generation bronchi basing on high-resolution computed tomography (HRCT) as well as the volumes of different lobes.

Results: 19 patients were included. In ipsilateral non-target lobes, the WT and WA in airways showed some decrease, but the significance was only observed in bronchi of the 3rd-and 4th-generation at 1-month. The WT% was reduced significantly in 3rd-generation bronchi at 1-month, 3-month and 6-month, so did their WA% at 1-month and 6-month respectively. In the contralateral bronchi, significant reduction of WT% and WA% (in 4th-generation) and enlargement of LA (in 3rd-generation) were observed at 6-month. Non-responders, who was defined as not achieve meaningful improvements in clinical, showed no significant changes. A significant decrease in the target lobe volume and increase in the ipsilateral non-target lobes were observed.

Conclusion: After BLVR-valve therapy, the non-target bronchial wall tended to become thinning which may predict its responsiveness. The treatment could result in a meaningful volume shift especially between the target lobe and the non-target ipsilateral lobes. The AI software could be successfully used for airway structure analysis basing on HRCT.

PO-269

Medical thoracoscopic thermal ablation therapy for metastatic pleural tumor: An exploratory study

Mai,Zhonglun、Feng,Qixiao
TCM-Integrated Hospital of Southern Medical University

Objective: To explore the clinical efficacy and safety of medical thoracoscopic thermal ablation therapy for metastatic pleural tumor.

Methods: We retrospectively analyzed clinical data of 141 patients diagnosed of metastatic pleural tumor with pleural effusion at TCM-Integrated Hospital of Southern Medical University. All cases received standard systemic treatment according to the NCCN guidelines, and were locally injected platinum-based chemotherapy drugs through thoracic drainage tube. Among those patients, 50 were in the thoracic drainage catheter group, and 91 were examined and treated by thoracoscopy. The thoracoscopy group was further divided into the non-ablation group (n=44) and thermal ablation group (n=47) according to whether thermal ablation was performed. The thermal ablation group included 24 cases receiving Argon Plasma Coagulation（APC） treatment and 23 cases receiving laser treatment. The efficacy of pleural effusion control and patient survival time were compared among different groups, and the incidence of complications and the changes of vital signs were observed.

Results: The effective rate of pleural effusion control in both the thermal ablation group (89.3%) and non-ablation group (77.3%) was significantly higher than that of the thoracic drainage catheter group (56.0%). The median

survival time of the thermal ablation group, non-ablation group, and thoracic drainage catheter group was 14.7 months, 12.5 months and 10.2 months, respectively (P<0.01). Among the thermal ablation group, 17 cases (70.8%) achieved complete response（CR） and 5 cases (20.8%) achieved partial response(PR) in patients receiving APC treatment, 9 cases (39.1%) achieved CR and 11 cases (47.8%) achieved PR in patients receiving laser treatment (P=0.044). The overall survival time of the APC and laser treatment group was 18.4 months and 14.6 months, respectively (P=0.041). There was no significant difference in terms of the incidence of complications (such as fever, chest pain, intraoperative bleeding) and changes of vital signs between the thermal ablation group and the non-ablation group.

Conclusion: Medical thoracoscopic thermal ablation therapy (especially APC) was effective and safe in the treatment of metastatic pleural tumor with pleural effusion, and can be promoted in the clinical practice.

PO-270

The Clinical value of DNA polyploidy analysis on bronchial washing fluid for the diagnosis of pulmonary malignancy

Hu,Yan、Yu,Qing、Hu,Zhanwei、Su,Li、Wang,Guangfa
Peking Universeity First Hospital

Objective: Background: The DNA polyploidy analysis was performed on the bronchial washing fluid in the patients who had pulmonary shadow on CT scans. The aim of the present study is to evaluate the diagnostic value of the DNA polyploidy analysis on bronchial washing fluid.

Methods: We retrospectively studied 126 cases, in which 62 cases were malignancy and 64 cases were benign. Bronchial washing fluid was obtained by clinicians during bronchoscopy. Each bronchial washing fluid specimen was made into two slides. One slide was stained by HE for cytology analysis, and the other one was stained with Feulgen for DNA polyploidy analysis by the automatic imaging cytometer.

Results: The sensitivity and specificity of the DNA polyploidy analysis was 82.3% and 69.4%. The positive rate of bronchoscopic biopsy (including transbronchial ultrasound-guided biopsy) was 85.5%. There was no significant difference between the results of the biopsy and DNA polyploidy analysis ($\chi 2 = 0.238$, P = 0.625). The positive rates of traditional cytology analysis on bronchial brush and washing fluid were 60.3% and 33.3% respectively, which were significantly lower than those of DNA polyploidy analysis ($\chi 2 = 7.087$, $\chi 2 = 30.001$, P <0.01). In the case with abnormalities at bronchoscopy, the positive rates of DNA polyploidy analysis of bronchial washing fluid was 82.9%. The positive rate of cytology analysis on bronchial brush was 71.9%. There was no significant difference between them ($\chi 2 = 1.160$, P = 0.281). But the positive rate of cytology analysis of bronchial washing fluid was 55.9%, which was significantly lower than that of DNA polyploidy analysis ($\chi 2 = 5.927$, P <0.05). In the cases without significant abnormalities at bronchoscopy, the positive rates of DNA polyploidy analysis, cytology analysis of bronchial brush and bronchial washing fluid were 81.5%, 44.0%, and 42.3% respectively. There was a significant statistical difference between them ($\chi 2 = 10.571$, P <0.01).

Conclusion: Conclusion: The DNA polyploidy analysis on bronchial washing fluid is an effective adjunct to diagnosis of lung malignant tumor. It is more sensitive than the traditional cytology analysis on bronchial brush and bronchial washing fluid.

PO-271

Using atrial septal defect occlude block bronchial stump fistula:initial experience in 5 cases

Li,Xiao、Liu,Zhiguang、Liu,Wei、Tan,Jianlong、Wu,Huaiqiu、Deng,Hongying
the First Affiliated Hospital of Hunan Normal University(Hunan Provincial Hospital)

Objective: To discuss the feasibility and efficacy of atrial septal defect occlude implantation technique in treating bronchial stump fistula.

Methods: From June 2018 to November 2019， a total of 5 patients with bronchial stump fistula after pneumonectomy or lobectomy were admitted to the Department of Respiratory Medicine,the First Affiliated Hospital of Hunan Normal University(Hunan Provincial Hospital).Under fiberoptic bronchoscopy guiding,the occluders were successfully implanted in all the five patiens with bronchial stump fistula. The clinical effect of atrial septal defect occlude implantation technique for bronchial stump fistula was evaluated by bronchoscopy, chest CT, and symptoms.

Results: Both the atrial septal defect occlude were successfully placed with single procedure.Complete occlusion of the fistulae was obtained in all the 5 patients. The patients were followed up for 1-11months.4 patients had no recurrence of fistula and thoracic infection,and the clinical symptoms improved and the quality of life was significantly higher than before occlusion;Three of the 4 cases had their thoracic drainage tube removed 7-30 days after closure, and no recurrence of fistula and thoracic infection was found after thoracic drainage tube removal;As the granulation tissue around the occlude was rather thin and thoracic infection was still not cleared,one had a thoracic drainage tube as of the follow-up time. In a elderly patient with advanced tumor, although the fistula was completely closed after the occluder was inserted, the thoracic infection was aggravated and pleural effusion was increased after the removal of the thoracic drainage tube on the third day after surgery and the treatment was abandoned.

Conclusion: For the treatment of bronchial stump fistula after pneumonectomy or lobectomy, atrial septal defect occlude implantation technique is technically-simple and clinically-safe with reliable short-term effect. Therefore, atrial septal defect occlude implantation technique should be recommended in clinical practice.However, attention should also be paid to the timing of thoracic purification and thoracic drainage tube removal after closure.

PO-272

A Novel Electromagnetic Navigation Bronchoscopy System Combined with Endobronchial Ultrasound for the Diagnosis of Peripheral Pulmonary Lesions: A Prospective Multicenter Randomized Controlled Clinical Trial

Zheng,Xiaoxuan1、Cao,Liming 2、Zhang,Yan 3、Yang,Huaping 2、Liu,Jingjing 2、Qu,Shuoyao 3、Zhang,Jian 3、Sun,Jiayuan1
1. Shanghai Chest Hospital， Shanghai Jiao Tong University
2. Xiangya Hospital，Central South University
3. The First Affiliated Hospital Of Air Force Medical University

Objective: Electromagnetic navigation bronchoscopy (ENB) has been demonstrated to increase the diagnostic yield of peripheral pulmonary lesions in transbronchial lung biopsy (TBLB). The traditional ENB system should use a bronchoscope with a large diameter of the working channel (>2.6mm) with a thick locatable sensor probe (1.9mm) and corresponding thick extended working channel (EWC, 2.6mm). However, this system limits bronchial insertion and visibility of the peripheral small bronchi is poor. In contrast, the novel LungCare ENB system consists of several thinner locatable sensor probes that are suitable for a conventional bronchoscope with a 2mm-diameter working channel or an

ultra-thin bronchoscope. The aim of this prospective multi-center randomized controlled clinical trial was to determine the diagnostic efficiency of LungCare ENB system.

Methods: Patients with peripheral pulmonary lesions (diameter≤3cm, with suspected malignancy) were enrolled in the study and randomly assigned to one of two groups based on the presence of a bronchus sign and the lesion size and location: the ENB-EBUS-GS group (LungCare ENB system ,endobronchial ultrasound [EBUS]and guide sheath [GS]) or the EBUS-GS group (EBUS and GS only) .The final diagnosis was based on the histological/cytological or microbiological results of a specimen obtained via bronchoscopy (biopsy, brush, and/or GS flush) and/or other means. A follow-up of at least 6 months was used to exclude malignancy in patients with benign disease.

Results: A total of 346 patients (ENB-EBUS-GS group, n=175; EBUS-GS group, n=171) recruited from three centers were enrolled from July 2018 to June 2019. There was no significant difference in the average lesion size between the ENB-EBUS-GS vs. EBUS-GS groups (21.92 ± 5.34 mm vs. 21.46 ± 5.39 mm, respectively), while there was a significant difference in the diagnostic yield (82.86% [42 benign and 133 malignant lesions] vs. 73.10% [28 benign and 143 malignant lesions], respectively, p = 0.037). There was no statistical difference in total procedure time between the two groups. Also, there was no severe complication in either group.

Conclusion: The diagnostic yield of the ENB-EBUS-GS group was superior to that of EBUS-GS group. The novel LungCare ENB system is an effective and safe option for the diagnosis of peripheral pulmonary lesions.

PO-273

Hybrid Argon Plasma Coagulation as a Novel Local Treatment Method for Early Stage Central Lung Neoplasms: A Prospective Multicenter Clinical Trial

Zheng,Xiaoxuan1、 Gu,Ye2、Chen,Xiaobo3、Wang,Hao 2、Li,Shiyue 3、Sun,Jiayuan1
1. Shanghai Chest Hospital, Shanghai Jiao Tong University
2. Shanghai Pulmonary Hospital, Tongji University School of Medicine, Shanghai, China
3. The First Affiliated Hospital of Guangzhou Medical University, Guangzhou Institute for Respiratory Health, Guangzhou, Guangdong, China.

Objective: Surgical resection remains the main treatment strategy for early stage central lung neoplasms and traditional endobronchial ablation has been confirmed as a useful supplemental treatment. Hybrid argon plasma coagulation (Hybrid APC) is an innovative minimally invasive ablation technique that combines argon plasma coagulation with a water cushion function to protect the submucosal and normal surrounding tissues. The aim of this prospective multicenter single-arm clinical trial was to evaluate the efficacy and safety of Hybrid APC for local treatment of early stage central lung neoplasms.

Methods: Patients diagnosed with early stage central lung neoplasms were eligible to enroll in this study. Every patient who refused or was unfit for surgery underwent a general examination, which included radial endobronchial ultrasound (R-EBUS), thin-section computed tomography (CT), white light bronchoscopy (WLB), autofluorescence bronchoscopy (AFB), and narrow band bronchoscopy (NBB), etc. in order to determine whether the neoplasm had invaded other normal tissue. All procedures were carried out under general anesthesia. The APC and water cushion function were completed using the same instrument through the working channel of the flexible bronchoscope. Thin-section CT, WLB, AFB, NBB, R-EBUS, and pathological examinations were conducted again at 3 months after the procedure. Afterward, patient prognosis was assessed via regular follow-up examinations.

Results: In total, five adult patients were enrolled in this study from February 2019 to December 2019. Hybrid APC ablation was successfully completed in all patients with no complications as of December 2019. Images obtained at the 3-month follow-up revealed the presence of some scar tissue due to WLB, AFB, and NBB. The lesion depth was reduced from the initial finding by R-EBUS. Pathologically, the biopsy specimens showed no malignant tumor cells.

Conclusion: Hybrid APC is a useful and safe treatment option for early stage central lung neoplasms. Further controlled clinical studies with longer follow-up periods are needed to confirm these findings.

PO-274

Diagnostic Significance of CT-guided Percutaneous Transthoracic Lung Biopsy of Non-peripheral Lesions of the Lung and Analysis of Complication Causes

zhang,yonghong、Yang,Shuanying、Zhang,Dexin、Li,Wei、张永红
Department of Respiratory and Critical Care Medicine， The Second Affiliated Hospital， Xi'an Jiao tong University

Objective: To explore the diagnostic significance of CT-guided percutaneous lung biopsy for Non-peripheral Lesions of the Lung and analyze the causes of complications.

Methods: From January 2017 to December 2019, 119 patients who underwent CT-guided percutaneous lung biopsy for non-peripheral occupying lesions of the lung in the Department of Respiratory and Critical Care Medicine, the Second Affiliated Hospital of Xi'an Jiaotong University, were analyzed and summarized. Diagnostic significance and complications of CT-guided percutaneous lung biopsy for lung lesions.

Results: A total of 130 punctures were performed in 119 patients. The success rate of puncture was 100%, and the biopsy results were satisfactory. Among them, 94 were lung malignant tumors and 25 were benign lesions. After lung puncture, there were 51 complications.including 27cases of pneumothorax, 11 cases of intrapulmonary hemorrhage, 6 cases of hemothorax, 5 cases of pleural reaction, and 2 cases of puncture-related infection. No serious complications such as air embolism, needle implantation of tumor, and death occurred. Multivariate analysis suggested independent risk factors for the occurrence of pneumothorax.

Conclusion: CT-guided percutaneous lung biopsy plays an irreplaceable role in lung lesions that cannot be reached by other interventional methods, but it needs sufficient preoperative evaluation.

PO-275

Bronchopleural fistula treated with ASD occluder: A case report and review of the literature

Bian,Cui Xia、Zhou,Jin Hua
Jining No.1 People's Hospital

Objective: Clinical value of atrial septum occlusive device in the treatment of bronchopleural fistula. ASD occluder is currently controversial in the treatment of BPF [3]. The main advantages are performed through Bronchoscope and use flexible tracheoscope with simple operation, high safety and good effect. It is basically the same as the requirements of patients for routine tracheoscopy.

Methods: Treatment of bronchial pleural fistula with atrial septal blocker under bronchoscope. According to the data, we finally selected atrial septal defect occluder. The waist diameter of the occluder is preferably 1-2mm larger than the diameter of the fistula, Under direct vision of the bronchoscope, the delivery sheath passed through the fistula along the guide wire, opened the disk of the occluder into the distal end of the fistula , placed the waist at the fistula, and then opened the second disk into the end of the fistula, and fixed at the bronchial ridge.

Results: According to the measured data, we finally chose ASD occluder for the treatment. The whole process was safe and no adverse reaction. Postoperative review showed a good effect, and the occluder was not displaced. The patients were in good condition up to now. Most of all, the patients were in good condition up to now.

Conclusion: ASD occluder is a new and effective therapy for BPF treatment with the advantages of rapid fistula healing, good safety, simple operation and less postoperative complications. The future for the application of occluder in BPF is bright. It is believed that there will be improvements in the occluder in accordance with the anatomical and physiological characteristics of the airway, and BPF will be more effectively treated.

PO-276

Comparison of autofluorescence and white-light bronchoscopies performed with the Evis Lucera Spectrum for the detection of bronchial cancers: a meta-analysis

Yang,Yang、Sun,Shuangshuang、Wan,Bing、Zhu,Ying、Wu,Liangquan、Yang,Jian、Zhang,Xiuwei
the Affiliated Jiangning Hospital of Nanjing Medical University， Nanjing， 210002， China.

Objective: Many recent studies have reported that autofluorescence bronchoscopy (AFB) has a superior sensitivity and decreased specificity in the diagnosis of bronchial cancers when compared with white-light bronchoscopy (WLB). We specifically analyzed the diagnostic performances of autofluorescence imaging video bronchoscopy (AFI) performed with the Evis Lucera Spectrum from Olympus, which is a relatively novel approach in detecting and delineating bronchial cancers, and compared it to the older WLB method.

Methods: We searched the PubMed, Embase, Web of Science, and CNKI databases from inception to July 12th, 2018 for trials in which patients were diagnosed with lung cancer via concurrent or combined use of AFI and WLB. The included studies were required to have a histologic diagnosis as the gold standard comparison, and a sufficient amount of data was extracted to assess the diagnostic capacity. A 2×2 table was constructed, and the area under the receiver-operating characteristic curve (AUC) of AFI and WLB was estimated by using a stochastic model for diagnostic meta-analysis using STATA software.

Results: A total of 10 articles were eligible for the metaanalysis, comprising 1830 patients with complete data included in the analysis. AFI showed a superior sensitivity of 0.92 (95 %, CI 0.88–0.95) over WLB’s 0.70 (95 %, CI 0.58–0.80) with p<0.01, and a comparable specificity of 0.67 (95 %, CI 0.51–0.80) compared with WLB’s 0.78 (95 %, CI 0.68–0.86) with p=0.056. Egger’s test P value (0.225) demonstrated that there was no publication bias.

Conclusion: Our research showed that in the evaluation of bronchial cancers, AFI was superior to conventional WLB. With its higher sensitivity, AFI could be valuable for avoiding misdiagnosis.

PO-277

Clincal Analysis on the Medical Intervention Treatment of Pulmonary Bulla

Shen,Wei1、Chen,Chengshui2、沈伟
1. xiangtan central hospital
2. The first affiliated hospital of wenzhou medical university

Objective: To evaluate the easibility and efficacy of the medical intervention treatment for pulmonary bulla in surgically unfit patients.

Methods: 480 patients with pulmonary bulla are in Our hospital in 2004 January to 2014 September , 17 cases in which had the medical intervention treatment, including medical thoracoscopy lung volume reduction surgery in 13 cases and bullae biological glue injection volume reduction surgery in 4 cases. After the treatment, review of the chest CT and 6-minute walk test (6MWT). To observe the complications, pulmonary function changes, chest CT, 6MWT, blood gas analysis to assess the efficacy.

Results: Postoperative complications include seven cases had fever, four cases had pleural effusion, one case had pneumothorax, one case of subcutaneous emphysema, and one case of hemoptysis. After six months, Mean value of forced expiratory volume in 1 s (FEV1) (from 46.5% to 65.0%, p<0.05), forced vital capacity (FVC) (from 27.0% to 46.0%, p<0.05) and FEV1/FVC (from 45.9% to 57.6%, p<0.05), PO2(from 55.91mmHg to 71.18mmHg, p<0.05),

6MWT(from 259.7m to 383.2m, p<0.01); improved with respect to baseline value significantly. Conversely, mean value of total lung capacity (TLC) (from 75.3% to 55.5%, p < 0.01) and Modified Medical Research Council Scale (MMRC) score (from 3.0 to 1.7, p < 0.01) was lower than baseline data significantly.

Conclusion: Our preliminary data confirm the feasibility and the potential efficacy of this strategy with significantly immediate improvement of respiration and quality of life, to those unfit for surgery, the treatment is a safe and effective messure.

PO-278

Use of Holmium Laser for removal of chronic impacted foreign bodies from the airways.

JAIN,SUSHIL、Srivastava,Sagar、N,Thejaswi、Nanda,Vivek
RAMKRISHNA CARE HOSPITAL, RAIPUR (CG), INDIA

Objective: BACKGROUND : Chronic Impacted foreign bodies pose a major challenge for the Interventional Pulmonologists during their removal from the airways[1]. There are only few case reports in the literature regarding the use of lasers for removal of chronic impacted foreign bodies from the airways [2, 3].

Methods: We present our experience of using holmium laser in removal of chronic impacted foreign bodies from the airways. A total of 56 foreign bodies were removed by us from the airways in the last 10 years (2009-2019). Out of 56 foreign bodies, 12 were chronically impacted and were removed using holmium laser. The age of the patients in this subgroup was between 16 months to 74 years, of which there were 5 females and 7 males. The removed foreign bodies included cashew nut, peanut, betel nut, peas, part of pen cap, broken part of a toy, board pin etc. (Table 1). We used holmium laser to coagulate and burn the granulation tissue, dislodge the impacted FB from airways and to blunt the edges of FB. Then they were removed with the help of various tools including toothed forceps, foreign body removal forceps, dormia basket, fishnet basket, rigid biopsy forceps etc. All the chronically impacted foreign bodies in our study were successfully removed by us.

Results: We were able to remove all chronically impacted foreign bodies from the airways with the help of holmium laser. No major complications occurred during their removal (except minor bleeding which could be controlled easily).

Conclusion: Holmium laser can be safely used for removing chronic impacted foreign bodies from the airways. It is very safe and effective in coagulating and burning the granulation tissue surrounding the chronic impacted foreign bodies [4].Laser can assist in removing FBs by breaking large foreign bodies (e.g., chicken bones) [5] or by vaporizing surrounding granulation tissue [6]. The laser can also be used to dislodge the sharp ends of an FB (e.g., pins, needles, tacks, etc.) embedded in the bronchial mucosa, as well as to blunt the edges to prevent airway injury during foreign body removal [7]. As the depth of penetration of holmium laser is quite less, the chances of injury to the normal airways surrounding the foreign bodies is minimal. Also, as the holmium laser can be used as a direct contact laser, it is potentially safer and easier to use [8].

PO-279

Transbronchial Cryobiopsy: a case of primary lung mucinous adenocarcinoma and literature review

zhang,yonghong、Yang,Shuanying、张永红
Department of Respiratory and Critical Care Medicine， The Second Affiliated Hospital， Xi'an Jiao tong University

Objective: To investigate the clinical manifestations, molecular biological characteristics and treatment of primary pulmonary mucinous adenocarcinoma (PPMA).

Methods: This study reported a 39-year-old male farmer who presented with cough, cough, and shortness of breath, chest CT high-density patch of bilateral lungs, and histopathological diagnosis of primary pulmonary mucinous adenocarcinoma by transbronchial cryobiopsy. The literature review was carried out by searching the Chinese Journal Full-text database CJFD primary pulmonary mucinous adenocarcinoma as the key words, primary pulmonary mucinous adenocarcinoma or mucinous adenocarcinoma of the lung was searched for PubMed, and the system literature was systematically reviewed.

Results: primary pulmonary mucinous adenocarcinoma cough, sputum often presents as chronic cough and cough with sputum, etc, and there was no typical feature of imaging findings, the pathology was the sole standard of diagnosis. The overall mutation rate of PPMA is poor, ALK rearrangement and KRAS mutation were the most common alteration, the lungs were easy to relapse after surgical resection. and the prognosis is similar to non-mucinous adenocarcinoma.

Conclusion: primary pulmonary mucinous adenocarcinoma is a unique histologic subtype of lung cancer, and the clinical manifestations are not specific, which is easily misdiagnosed.

PO-280

Evaluation of mediastinal lymphadenopathy in pediatric population: our experience

Guliani,Abhinav、Basu,Arup、Dhamija,Amit
Sir Ganga Ram Hospital， New Delhi， India

Objective: Endobronchial ultrasound guided transbronchial needle aspiration (EBUS-TBNA) and endoscopic ultrasound with an EBUS scope guided fine needle aspiration (EUS-B-FNA) are established modalities in the evaluation of mediastinal lymphadenopathy in adults. The data in children is limited. We describe the methods, feasibility and complications of mediastinal lymphadenoapathy sampling in patients aged <18years from a tertiary centre in India.

Methods: Retrospective single center analysis of consecutive patients <18years undergoing evaluation by EBUS for undiagnosed mediastinal lymphadenopathy from May 2011 to November 2019 in the department of chest medicine, Sir Ganga Ram Hospital, New Delhi, India. Procedural details including type of anaesthesia, pathological and microbiological diagnosis, diagnostic yield and complications were analysed and presented.

Results: Eighty-four children underwent endobronchial ultrasound guided FNAC. Fourty-six(55%) were females. The age range was 2-17years with mean age being 13 years. The youngest patient was 2years old. Transtracheal aspiration was done in most cases, however EUS-B FNA using the same EBUS scope (Olympus) by the same operator had to be done in a small number of cases where airway size was assessed to be smaller. All cases were done in conscious sedation/moderate sedation using various combinations of midazolam, propofol and in some cases ketamine, with pediatric ICU fellow being standby. Mild, self-limiting hemorrhage was the most common complication and all patients tolerated the procedure well. Granulomatous disease like tuberculosis was the most common diagnosis seen (70%

cases). Tuberculosis was confirmed microbiologically in 38(45%) cases. The sampling method was also able to pick up 3 cases of lymphoma and 1 Cryptococcosis in the given population.

Conclusion: EBUS is equally safe, easy and efficient in children as in adults. The bronchoscopist should assess for feasibility of EUS-B FNA in all cases to enhance safety and decrease trauma to the narrower pediatric airway. Ketamine as a sedative agent is safe for performing EBUS in the bronchoscopy suite. All patients with mediastinal lymphadenopathy should undergo sampling before initiation of treatment.

PO-281

All post extubation stridor are not due to tracheal stenosis

Patra,Jeetendra Kumar、Pattnaik,Manoranjan、Sethy,H K、Mohanty,Thitta、Panda,Geetanjali、Dash,Nrusingha Charan、Trilochan,Biswal Pradipta、Meher,B K
S.C.B. Medical College and Hospital

Objective: Post-extubation stridor is defined as presence of an inspiratory noise following extubation. It is a consequence of narrowing of the airway, resulting in an increased effort of breathing.

Methods: A 61 year old male admitted with high grade fever, dry cough, dyspnea on exertion and stridor for 2 days. He was admitted in a hospital 20 days back for acute coronary syndrome. After CAG and PTCA, patient developed acute pulmonary edema and was intubated and mechanically ventilated for 5 days. On examination patient was tachypneic ,pulse rate – 106/min, Resp rate – 30/min, BP – 164/90 mmHg, SP2 – 90% with audible stridor . On auscultation there was bilaterally decreased vescicular breath sound. Provisionally diagnosed as a case of Post intubation tracheal stenosis. Routine tests revealed anemia, leucocytosis, neutrophilia ,hyperglcemia. Chest Xray was normal .CT thorax showed short segment irregular tracheal wall thickening(5-6 mm) with moderate luminal stenosis.

Results: Bronchoscopy revealed subglottic and tracheal membranous tenacious mucus encircling the lumen which was dislodged and removed by bronchoscope and biopsy forceps. Tracheal wall was hyperemic and edematous. Finally diagnosed as Obstructive Fibrinous Tracheal Pseudomembrane(OFTP) with Tracheitis.

Conclusion: OFTP is an uncommon complication of endotracheal intubation. Symptoms are nonspecific and can mimic as laryngeal spasm, laryngeal edema , vocal cord palsy, vocal cord dysfunction, heart failure, and retention of tracheobronchial secretions. Delay in making diagnosis may result in respiratory failure that requires re-intubation and occasionally lead to death. Treatment involves confirmation by flexible bronchoscopy and removal of the membrane using either rigid or flexible bronchoscopy

PO-282

Covered airway stent loaded with 125I seeds for tracheal adenoid cystic carcinoma: A clinical observation of 8 cases

Luo,Bingqing、Ke,Mingyao、Zeng,Junli、Huang,Rui、Lin,Liancheng、Wu,Xuemei、Yong,Yazhi
The Second Affiliated Hospital of Xiamen medical college

Objective: To explore the efficacy and safety of the covered airway stent loaded with 125I seeds for the treatment of tracheal adenoid cystic carcinoma (TACC).

Methods: We recruited eight patients with TACC who underwent placement of the covered stent loaded with 125I seeds between December 2014 and July 2017 in our endoscopic center. We compared the dyspnea index,the diameter of the airway lumen and the lesion surrounding the airway wall before and after treatment. The complications were also recorded during follow-up.

Results: Eight patients underwent successful placement of a total of 11 radioactive stents. Displacement of these stents took place within two weeks in two patients, who were managed with re-stenting and fixation. No further displacement occurred during follow-up. The median time to stent removal was 2.9(2.3,3.0) months. After stent removal, the dyspnea index was significantly decreased compared with pre-treatment level (mean:0.1 vs.3.4, P<0.001). Bronchoscopic reassessment showed that the residual tumor within the airway was detected in only one patient and that the tumor completely disappeared in the remaining patients. Chest CT reassessment demonstrated significantly larger luminal diameter than pre-treatment levels (mean:13.1mm vs.3.3mm, P<0.001). Airway wall thickness was notably reduced after treatment (mean:4.3mm vs.14.4 mm, P<0.001). The lesions surrounding the airway wall completely disappeared in seven patients and decreased for more than 50% in a single patient. The median follow-up time was 28.0(24.8,31.5) months. Recurrence of tumor was documented in a single case within 2 years. The 2-year recurrence-free survival rate was 85.7%(6/7) . No death and severe complications was recorded during follow-up.

Conclusion: The radioactive stent has favorable effects on dilating the stenotic airway and ameliorate the symptoms, and thus might be an effective and safe method for the treatment of TACC.

PO-283

The application of laser curve in the treatment of symptomatic tracheobronchomalacia

Wang,Hongwu、Zhang ,Nan、Zhou,Yunzhi、Tao,Meimei、Zou,Heng、Wang,Zhina
Emergency General Hospital

Objective: The management of tracheobronchomalacia is a very challenging problem with few treatment options. This study aims to evaluate the effectiveness and complications of laser curve for primary and secondary membranous tracheobronchomalacia.

Methods: A consecutive series of patients with primary and secondary tracheobronchomalacia were treated with two to three semiconductor laser curve of the hyperdynamic tracheal and bronchial walls. The Karnofsky score and dysnea score were used to evaluate the quality of life and symptom before and after treatment.

Results: Sixteen patients were treated for their tracheobronchomalacia with a mean age of 52 years. Symptoms included severe dyspnea, dry cough, recurrent pulmonary infections, and respiratory failure. All patients presented with wheezing refractory to traditional treatment. All cases showed significant improvement of their respiratory symptoms. Mean KPS was 71.6 before laser curve and mean KPS was 83.5 after laser curve ($P < 0.05$). Mean dyspnea score decreased from 2.5 to 1.1 before and after treatment ($P < 0.05$). The mean number of procedures was 2.2 per patient with the average laser energy delivered per procedure of 1000 J.

Conclusion: Laser curve is a safe, easy to adopt, and effective technique for the treatment of membranous tracheobronchomalacia.

PO-284

The development of bronchoscopy in China: a national cross-sectional study

Shi,Dongchen1、Li,Fuqi1、Wang,Kaicheng1、Kong,Chen1、Shi,Hui1、Hu,Zhenli1、Huang,Haidong1、Dong,Yuchao1、Ning,Yunye1、Li,Qiang2、Jin,Faguang3、Hu,Chenping4、Wang,Changhui5、Bai,Chong1

1. Changhai Hospital, Naval Medical University
2. East Hospital, Tongji University
3. Tangdu Hospital, Air Force Medical University
4. Xiangya Hospital, Central South University
5. Shanghai Tenth People's Hospital, Tongji University

Objective: To investigate the development of bronchoscopy in China and compare it with its application in the early 21st century.

Methods: The data collection was based on questionnaires. Three hundred and nineteen hospitals, which distributed across 30 provinces and 130 cities, were included in the study. Data about the application of bronchoscopy in Shanghai and Hunan province in the early 21st century are also involved for comparison.

Results: The median period of performing diagnostic and therapeutic bronchoscopy was 19.7±11.0 and 7.4±7.0 years, respectively. On average, about 155.2 cases and 28.4 cases received diagnostic and therapeutic bronchoscopy in each hospital per month. The average area and number of the examination room was 122.7m2 and 2.2 m2, respectively. More examination items were performed in specialty hospitals than those in general hospitals ($P<0.05$) and specialty hospitals owned more rooms exclusively for bronchoscopy ($P<0.05$), while no difference of the number of allocated doctors was found ($P>0.05$). On the other side, the whole amount of diagnosis and therapeutic items in teaching hospitals was slightly higher than that in non-teaching hospitals ($P<0.01$). Comparison of diagnosis and therapeutic endoscopy in Shanghai and Hunan province shows that the number of flexible bronchoscopy increased by 5.8 times in Shanghai from 2002 to 2017, while that increased by 3.4 times in Hunan province from 2005 to 2017. Furthermore, the average number of allocated doctors increased by 0.85 times in Shanghai, which was more rapidly compared with that of Hunan province (0.66 times) ($P<0.05$). Besides, the development rate of the diagnosis and therapeutic projects in Shanghai was significantly higher than that in Hunan province ($P<0.05$).

Conclusion: All different classes of hospitals in China are capable of carrying out conventional bronchoscopy diagnosis and therapeutic projects, and newly developed bronchoscopy technology has been gradually spread in high-level hospitals since 21st century. The higher class the hospital was, the earlier bronchoscopy was performed. Respiratory endoscopy in China has developed rapidly since the early 21st century and the construction of respiratory endoscopy center and the personnel training are on the right track, but it is also faced with inadequate equipment, unbalanced regional development and insufficient personnel allocation.

PO-285

Modified silicone stent for bronchopleural fistula: A pilot study of 15 cases

Zeng,Junli、Wu,Xuemei、Chen,Zhide、Zhang,Meihua、Ke,Mingyao
The Second Affiliated Hospital of Xiamen Medical College,

Objective: Bronchopleural fistula is a rare but life-threatening event with limited therapeutic options. We aimed to investigate the efficacy and safety of the modified silicone stent for bronchopleural fistula.

Methods: Between March 2016 and September 2019, we retrospectively collected 15 patients with bronchopleural fistula who underwent bronchoscopic placement of the modified silicone stent. The stent was fabricated manually based on the Y-shaped silicone stent by tailoring and suturing on site. One of the lateral branches of the Y-shaped stent would be selected as the occluded branch randomly. During the follow-up, the initial success, clinical success, the rate of complete cure and complications were recorded.

Results: The modified silicone stents were successfully placed into the culprit bronchus in all 15 patients. Placement of the modified silicone stent was successful in 14 patients on the first attempt (initial success rate: 93.3%). The median follow-up time was 130 (range, 5-431) days. The amelioration of respiratory symptoms was reported in all patients. There were 12 patients with empyema, and the daily drainage was significantly decreased in 10 patients over time, whereas the purulent fluid completely disappeared in 6 patients. The overall clinical success rate was 80%. The residual cavity was remarkably diminished over time in 9 patients, and completely disappeared in 5 patients. There were six stents that were removed during follow-up, four (26.7%) were removed because of complete cure of the fistula and two because of the severe proliferation of granulomatous tissues. Stent placement was well tolerated. No severe adverse events of stent migration and suture dehiscence took place. There were three cases lost to follow-up and five patients succumbed.

Conclusion: The modified silicone stent might be an effective and safe option for bronchopleural fistula patients in whom the conventional therapy is inappropriate and contraindicated.

PO-286

Endobronchoscopic ultrasound-guided radioactive seeds implantation in metastatic mediastinal lymph node carcinoma: A pilot observational study of 41 cases.

Yong,Yazhi、Zeng,Junli、Xie,Yanping、Jiefang,Shen、Ke,Mingyao
The Second Affiliated Hospital of Xiamen Medical College

Objective : Metastasis of the mediastinal lymph node has been a strong indicator of advanced stage of cancer that is unresectable and correlates with poor prognosis. We aimed to explore the efficacy and feasibility of endobronchoscopic ultrasound (EBUS) guided implantation of 125I seeds for metastatic mediastinal lymph node carcinoma.

Methods: We reviewed the medical history and enrolled 41 patients with mediastinal lymph node metastasis and received EBUS guided I125 seeds implantation in our center from January 2015 to May 2019. The prescribed dose of radioactive seeds was 120 Gy. The number and distribution of the seeds was determined according to the dedicated treatment planning system before the procedures. The activity of each seed was 0.5mCi. The 125I seeds were implanted through the airway wall with the CookÒ needle by EBUS. The change of lesion in the mediastinal lymph node was assessed according to RECIST 1.1 criteria. Patients were followed up for recording of the objective response rate and complications.

Results: Implantation of the 125I seeds was successful in all 41 patients. The mean number of I125 seeds in each patient was 15 (range: 7-23). The mean diameter of the lesion was 1.8(rang: 1.0-2.5) cm. Within three months after implantation of the seeds, there were 15 patients (36.6%) who achieved complete response, 16 (39.0%) achieved partial response, eight (19.5%) had stable disease whereas two (4.9%) had progressive disease. The objective response rate was 75.6%. The median follow-up duration was 10.2 months (range: 7.6-28.3 months). Mediastinal emphysema took place in one case, blood-stained sputum occurred in 15 cases and sore throat was reported in night cases. No severe complications such as massive hemoptysis, off-target, radiation damage, trachea mediastinal fistula, tracheoesophageal fistula were observed during follow-up.

Conclusion: EBUS guided 125I seeds implantation is effective and safe for metastatic mediastinal lymph node carcinoma.

PO-287

Percutaneous microwave ablation for stage I peripheral non-small cell lung cancer in patients with chronic obstructive pulmonary disease

Xie,Zhenyu、Xue,Keying、Wu,Xuemei、Luo,Bingqing、Li,Na、Ke,Mingyao
The Second Affiliated Hospital of Xiamen Medical College

Objective: Surgery is the standard treatment for early non-small cell lung cancer (NSCLC). However, some patients with concomitant chronic obstructive pulmonary disease (COPD) are unsuitable to undergo surgery. We sought to explore the efficacy and safety of CT-guided percutaneous microwave ablation (MWA) for stage I peripheral NSCLC in patients with COPD.

Methods: A total of 13 patients with early-stage NSCLC and COPD who underwent percutaneous WMA were enrolled between March 2015 and April 2019. The percentage predicted of forced expiratory volume in the first second was less than 50%. All patients were unsuitable or unwilling to undergo surgery and radiotherapy. The rate of ablation was determined by performing enhanced CT one month after MWA. During the follow-up, the tumor recurrence, cumulative survival rate and complications were recorded.

Results: The operation was successful in all 13 patients. Of these, 10 had squamous cell carcinoma and 3 had adenocarcinoma. There were 11 patients with stage IA and two patients with stage IB. The enhanced CT results showed that 11 cases were completely ablated (84.62%) and 2 cases were partially ablated (15.38%). The median follow-up duration was 26 months (range, 8.4 to 32.1 months). The cumulative survival rate at year 1 and 2 was 81% and 68%, respectively. Two cases died of respiratory failure, one died of heart failure and one died of tumor progression. During the follow-up, four cases suffered from local tumor recurrence, and three suffered from distal metastasis. Postoperative complications included pneumothorax in four (30.8%) cases and mild hemoptysis in four (30.8%) cases. No severe and intolerable complication was noted.

Conclusion: MWA is feasible and safe for patients with stage I NSCLC who have COPD, including those with poor lung function.

PO-288

Rare case of double hitch-stitch in a case of tracheo esophageal fistula with tracheal and esophageal stent: A novel technique

Arbat,Sameer、Arbat,Ashok、Bakamwar,Swapnil、Deshpande,Parimal
Ketki Research Institute of Medical Sciences

Objective: Tracheobronchial airway stents are used to relieve large airway obstruction, fistulas, stenosis in both benign and malignant disease. Caudal migration of tracheal stents can be a significant problem, and can be potentially life threatening by causing distal luminal obstruction. We present a rare case of double hitch-stitch in a case of tracheo esophageal fistula with tracheal and esophageal stent.

Methods: A 50-year-old male patient presented with cough and dyspnea. Patient was a known case of Ca Esophagus with Esophageal Stent in situ. CT Scan showed tracheo esophageal fistula with esophageal stent migrating into trachea. Tracheal stenting was done with Self Expanding Metallic Stent (SEMS). Patient followed up after one month with recurrent complaints of cough on deglutition. On follow-up bronchoscopy migration of stent was observed. A rare procedure of Double Hitch-Stitch was performed with fixation of the tracheal stent using a percutaneous anchoring stitch, embedded in the subcutaneous tissue.

Results Follow-up bronchoscopy after 1 month of Double Hitch Stitch showed no migration of stent.

Conclusion: Stent migration prevention using "hitch-stitch" is simple, safe and successful, without any complications. The advantages of the "hitch-stitch" include safety and efficacy. It can be useful in patient requiring endotracheal intubation. Stitch removal at the time of stent removal is also simple.

PO-289

Silicone stent versus covered metallic stent for malignant esophagorespiratory fistula

Lin,Liancheng、Zhang,Xiaoling、Zeng,Junli、Ke,Mingyao
The Second Affiliated Hospital of Xiamen Medical College,

Objective: Malignant esophagorespiratory fistula (ERF) is a devastating complication of esophageal and bronchogenic carcinomas, which are difficult to manage. The aim of our study was to investigate the efficacy and safety of silicone stent and covered metallic stent for malignant ERF.

Methods: Between November 2011 and April 2019, we enrolled 210 patients with ERF who were unsuitable to receive placement of the esophageal stent and underwent airway stent placement. 127 cases received silicone stent placement and 83 cases received metallic stent placement. According to the findings of iodine contrast radiography, bronchoscopy, the clinical symptoms and the control status of pneumonia, we categorized the clinical outcomes as complete remission (CR), partial remission (PR) and no effect (NE). The technical success of stent placement, the clinical outcomes and complications were evaluated.

Results: The airway stents were successfully placed in all 210 patients, with each patient receiving one stent. The technical success rate was 100%. There were seven straight-type and 120 Y-type stents in the silicone stent group, while three straight-type and 80 Y-type stents in the covered metallic stent group. The median follow-up duration was 11.3 months (range: 3, 24 months). The rate of CR in silicone stent group was significantly higher than that in metallic stent group (49.6% vs. 31.3%, $p<0.01$), and the total effective (CR+PR) rate in the silicone stent group was markedly higher than in metallic stent group (92.1% vs. 85.5%, $p<0.01$). The main complication included sputum plugging,

granuloma proliferation, cough and stent displacement. The incidence of the most common complications between the two groups were comparable, except that the incidence of granuloma proliferation was higher in metallic stent placement group (40.9% vs. 25.1%, p<0.01).

Conclusion: Both silicone stent and covered metallic stent are effective for the treatment of ERF. However, silicone stent might be superior in terms of efficacy and safety. Multi-center randomized trial with a larger sample size is warranted.

PO-290

Recanalization of endobronchial tumor with cryoprobe & electrocautery – Case series

Arbat,Sameer、Arbat,Ashok、Bakamwar,Swapnil、Deshpande,Parimal
Ketki Research Institute of Medical Sciences

Objective: Endobronchial tumor occluding tracheal or endobronchial lumen is very challenging site for any diagnostic or therapeutic interventions. Our aim in this study was to do recanalization by debulking endobronchial tumor with bronchoscopic cryoprobe & electrocautery.

Methods: Fourteen consecutive patients with unresectable endobronchial tumor were selected. Efficiency of the procedure was evaluated by pre-procedure & post-procedure bronchoscopy. Complete removal or partial removal of endobronchial lesion leading to recanalization was considered successful.

Results: Out of 14 patients 11 (78.57%) were male; 3 (21.43%) were female. 1 (7.14%) was smoker; 2 (14.29%) were ex-smoker and 11 (78.57%) were non-smoker. On subsequent histopathological assessment, 4 (28.57%) patients had neuroendocrine tumors; 3 had adenocarcinoma (21.43%); 2 had poorly differentiated carcinoma (14.29%) diagnosis and remaining 5 cases had diagnosis of small cell (7.14%), leiomyoma (7.14%), hemangioma (7.14%), squamous cell carcinoma (7.14%), and hematoma (7.14%). Out of fourteen, 8 (57.14%) patients had no complications; 5 (35.71%) were hospitalized post procedure for observation in view of mild bleeding and only 1 (7.14%) patient had moderate bleeding post procedure which required hospitalization.

Conclusion: Debulking of a tumor using cryotherapy is a useful & safe treatment modality for endobronchial obstruction.

PO-291

Diagnostic yield of Linear EBUS: case series of 61 patients.

Arbat,Sameer、Arbat,Ashok、Bakamwar,Swapnil、Deshpande,Parimal
Ketki Research Institute of Medical Sciences

Objective: Endobronchial ultrasound-guided transbronchial needle aspiration (EBUS-TBNA) is a minimally invasive diagnostic test with a high diagnostic yield for mediastinal lymph node staging. Study of ultrasonographic features can be used to predict malignant or abnormal lymph nodes. It also guides which lymph nodes to be biopsied to maximize the yield and avoid inconclusive results. It thus gives a guidance regarding further planning in case of inconclusive results. The main objective of this study was to describe the diagnostic yield of EBUS-TBNA for identification of lung cancer.

Methods: Retrospective study of patients of mediastinal lymphadenopathy ≥ 18 years of age undergoing EBUS-TBNA for diagnosis recruited between 17/01/2018 and 10/12/2019. All procedures were performed with Olympus

EBUS bronchoscope. Linear EBUS involves the use of a bronchoscope with a convex ultrasound transducer at its distal end to confirm the location of the lesion in real time, which allows fine-needle aspiration of the lesion contents (i.e., TBNA), significantly increasing the diagnostic yield. Anesthesia in accordance with standard recommendation was given after signing of written consent by the patients before undergoing the procedure. The airway and mediastinal lymph node stations were thoroughly inspected with a flexible bronchoscope. Subsequently, the lymph nodes were identified by radiological imaging study and linear transducer ultrasound. Mediastinal lymph nodes with suspected neoplastic involvement-defined as enlargement, irregular borders, and irregular shape-that was not confirmed by imaging was aspirated at least three times using a transbronchial needle.

Results: Our analysis included biopsies from 61 patients. Of those 61 patients, 70.49% were male and 29.51% were female. The mean age was 50.04 years. The diagnostic yield of this study was 84%. The most common histological diagnosis was Granulomatous inflammation. The major advantageous outcome of this study shows that the percentage of complication (mild bleeding) was found to be very low (8.20%).

Conclusion: EBUS-TBNA is a diagnostic tool that yields satisfactory results in the identification of lung carcinomas with low complication rate.

PO-292

Hybrid knife, a novel tool for treatment of tracheal stenosis: a case report

Yin,Yan1、Liang,Chao-nan 1、Ma,Wen-hui1、Ma,Hai-feng1、Kang,Jian1、Herth,Felix J.F. 2、Hou,Gang1
1. First Hospital of China Medical University
2. Department of Pneumology and Critical Care Medicine, Thoraxklinik University of Heidelberg, Heidelberg, Germany

Objective: The treatment of post-intubation subglottic stenosis remains a challenge due to anatomic and technological limitations, and there is no consensus regarding treatment. A tool with high efficiency for delivering drugs to the submucosal layer via injection may play an important role in treatment. A hybrid knife(HK) with a pressure water jet applied during endoscopy and pleural biopsy may be a useful tool. Here, we report the case of a man with complex subglottic stenosis who underwent balloon dilatation combined with cryotherapy and an adjuvant submucosal triamcinolone injection performed with an HK.

Methods: We applied a needle for endobronchial ultrasound-guided transbronchial needle aspiration (EBUS-TBNA) (Olympus, Tokyo, Japan) to probe the distal trachea following cryotherapy (ERBOKRYO CA, ERBE Elektromedizin, Tübingen, Germany) after the guide wire failed. Then, balloon dilatation (CRE balloon M00550330, Boston Scientific, Massachusetts, USA) and cryotherapy were performed repeatedly. Then the VIO 300D generator (ERBE Elektromedizin, Tübingen, Germany) was used as a surgical system. An HK (ERBE Hybrid Knife ® I-type I-jet, ERBE Elektromedizin, Tübingen, Germany) was applied to make an incision in the stenotic area from the left to the right of the narrow segment (VIO mode ENDO CUT I, effect3-width1-interval of incision 4, Coagulation effect 2 and 30W) followed by balloon dilatation to 8 mm. However, the efficacy of following balloon dilation and cryotherapy could not maintain, and restenosis occurred for the long length of the stenosis. Injection of topical medication combined with balloon dilatation and cryotherapy was considered. Triamcinolone (8mg/ml, total dose was 40 mg, Kunming Jida Pharmaceutical Co., LTD. Kunming, China) was delivered to submucosal layer of the stenotic area using the HK as a drug delivery system to prevent the occurrence of restenosis with 35 cm H2O of water jet pressure. Submucosal drug injection was performed every 3 weeks (3 times).

Results: The patient was successfully decannulated, no obvious growth of granulation tissue was observed, and the tracheal lumen was patent.

Conclusion: Hybrid knife, a diathermic knife with a high-pressure water jet, is a potentially useful tool for incision and drug injection for the treatment of tracheal stenosis, especially for patients with a long segment of stenosis and restenosis after recanalization.

PO-293

Role of radial endobronchial ultrasound-guided cryobiopsy in the diagnosis of peripheral pulmonary lesions: a case series

Arbat,Sameer、Arbat,Ashok、Bakamwar,Swapnil、Deshpande,Parimal
Ketki Research Institute of Medical Sciences

Objective: The diagnosis of peripheral pulmonary lesions (PPLs) may be challenging as they are bronchoscopically invisible. Radial endobronchial ultrasound (EBUS) is useful for accessing PPLs, with the help of TBLB and cryoprobe. Although PPLs can also be accessed with the help of transthoracic ultrasound or Computerised Tomography (CT)-guided Fine Needle Aspiration (FNA), there is a significant risk of pneumothorax.

Methods: This was a retrospective observational study. Patients with PPL on CT-Thorax were subjected for bronchoscopy. Radial EBUS via flexible bronchochoscope with Fluoroscope was used to determine the site and cryobiopsy were taken. Bleeding was controlled by endobronchial balloon placed through a rigid bronchoscope as conduit.

Results: Total 28 patients underwent radial EBUS with fluoroscopy guided cryobiopsy. Histopathological diagnosis was achieved in 25 (89.29%) cases. Out of total 28 cases, 9 were diagnosed as adenocarcinoma; 5 as TB; 3 as squamous cell carcinoma and so on. No complication was seen in 26 cases and 2 had mild bleeding.

Conclusion: Radial endobronchial ultrasound-guided cryobiopsy in the diagnosis of peripheral pulmonary lesions is a safe procedure with good diagnostic yield.

PO-294

Endobronchial valves for the treatment of bronchopleural fistula and pneumothorax caused by pulmonary cryptococcosis in an AIDS patient

Liang,Chaonan、Wen,Ying、Zhou,Ying、Ma,Hai-feng、Hou,Gang
First Hospital of China Medical University

Objective: Cryptococcal disease is an opportunistic infection that occurs primarily among people with advanced HIV disease and is an important cause of morbidity and mortality. Spontaneous pneumothorax (SP) is rare in AIDS patients with pulmonary cryptococcosis (PC), but when it occurs, rapid and effective treatment is crucial to the prognosis. We report a case of AIDS-related spontaneous pneumothorax(SP) in a patient infected with cryptococcus, resulting in a bronchopleural fistula that was successfully treated by the placement of endobronchial valves (EBVs) through a bronchoscope.

Methods: A patient with AIDS developed spontaneous pneumothorax(SP) during the treatment of cryptococcal disease. The pneumothorax remained despite chest tube drainage and evolved into a bronchopleural fistula. Because the patient was in poor clinical condition, had respiratory failure and cryptococcal meningitis and was not a surgical candidate, we inserted EBVs to block the air leak and facilitate healing. The source of the air leaks was in LB3 and LB4+5, which was identified by the Chartis system (Pulmonx SARL, CHARTIS CONSOLE, Switzerland). Two EBVs (EBV-TS-4.0 and EBV-TS-5.5) were implanted into the desired airway.

Results: The patient tolerated the procedure very well with an immediate reduction in air leakage and subjective alleviation of dyspnea. A follow-up chest CT one week later showed partial regression of the pneumothorax . Two months later, the valves were removed. The pneumothorax improved gradually, and no adverse events related to the EBVs were observed.

Conclusion: When immunocompromised patients suffer from refractory pneumothorax or prolonged air leaks, EBV implantation may be a feasible and minimally invasive procedure for this vulnerable population.

PO-295

MORTALITY POST RIGID BRONCHOSCOPIC INTERVENTIONS FOR CENTRAL AIRWAY OBSTRUCTION (CAO)

Albtoosh,Asma1、Chawla,Archit2、WU,Peter2、Mckevith ,James3、Zhao,Lisa3
1. University of Jordan , school of medicine
2. 2Westmead Private Hospital, NSW, Australia
3. 1Westmead Hospital, Westmead Sydney Local Health District, NSW, Australia

Objective: CAO is a relatively rare but critical medical problem, with outcome of therapeutic interventions having a complication rate of 3.9% and a 30 day mortality rate of 14.8% according to the Acquire Registry.1,2 Mortality rates were influenced Zubrod score, ASA score, intrinsic or mixed obstruction and stent placement. We examined the outcomes of rigid bronchoscopic interventions for CAO in a tertiary referral centre, including predictors of outcomes.

Methods: Retrospective audit of all rigid bronchoscopic procedures performed for CAO by a single operator conducted at Westmead Public and Private hospitals. Patient cohort collected from proceduralist log book. Data was collected from electronic and paper medical records on patients' demographics, anaesthetic requirements, interventions performed, complications and mortality. Data was analysed using Excel and SPSS.

Results: A total of 98 procedures were performed on 70 patients (39 male) between 2010 and 2018. Most had an ASA score of 3 or 4. All procedures were performed under general anaesthesia. Median pre-operative FEV1 was 1.46L (IQR 1.08L – 1.77L) with median FEV1% of 53% (IQR 44.5 – 64.3%). Median length of stay was 2 days post-procedure (IQR 1-5.5 days). Of the 60 patients with malignancy, 37/62 (59%) had a non-small cell lung carcinoma (58% squamous cell carcinoma [SCC], 32% adenocarcinoma), followed by oesophageal SCC (12%) and renal cell carcinoma (8%). 30-, 90- and 180-day mortality rates were 10%, 27% and 40%, respectively. Overall median survival of 4.1 months. Different malignancy types appeared to have differing median survival, with poorly differentiated carcinomas (n=4) having shortest survival of less than 1 month, followed by oesophageal SCC (4 months), lung non squamous cell carcinoma (6.1 months) and renal cell carcinoma (13.2 months). On univariate analysis, only age greater than 75 years was associated with increased mortality (median survival 2.4 months vs. 4.2 months; $p < 0.001$).

Conclusion: Rigid bronchoscopy was performed for CAO in an unwell cohort . 30-, 90- and 180-day mortality rates were 10%, 27% and 40%, respectively. Overall median survival of 4.1 months Our complication and 30-day mortality rates appeared to be similar to the American AQuiRE registry data. The only pre-operative characteristics associated with mortality appeared to be malignancy type and age. This is different from predictors of mortality found in AQuiRE registry data.

PO-296
EpiGELF, The GELF's 3.0 tool

LEGODEC,Julien1,7、DUTAU,Herv é 2,7、FEVBRE,Michel3,7、LORUT,Christine4,7、
FOURNIER,Cl é ment5,7、ESCARGUEL,Bruno 1,7、VERGNON,Jean Michel6,7
1. Saint Joseph Hospital
2. North Hospital of Marseille
3. TENON Hospital in Paris
4. COCHIN Hospital in Paris
5. CALMETTE Hospital of Lille
6. North Hospital of Saint Etienne
7. The French Bronchoscopic Group (GELF)

Objective: How many pulmonologists in France practice rigid bronchoscopy? How many center ? Do we all practice the same thing? Do we have the same complication? During tumoral airway obstruction, is stenting really always necessary to improve quality of life and symptoms ?...etc…etc.. To try to answer many questions like thoses, The French Bronchoscopic Groupe (GELF) opened in January 2019 the first on line registry about interventional pulmonology, called EpiGELF.

Methods: The 2019 on January the 26, during the Pulmonologist French Congress, the GELF inaugurated the first day EpiGELF starting. This data base was built on the same model as EpiTHOR, the famous French Thoracic Surgeon Society Registry. EpiGELF belong to The French Pulmonologist Society. EpiGELF is directly under the leadership of the Ministry of Health. EpiGELF is totally RGPD compatible. The recorded personals informations are fully anonymized. The access to our data base in completely single, confidential, and secure. Centers and interventional pulmonologists are frequently audited, to evaluate data quality, exhaustivity, and the legal way. Scientifically, priority is given to data about rigid bronchoscopy in case of tumoral pathologies.

Results: During the first twelve months, EpiGELF already bring together more than 60 pulmonologists in 25 centers, who practice rigid bronchoscopy in case of tumoral diseases. Always in this context, more than 650 patients have been included. 302 endotracheal or endobronchial stents have been dropped. Majority of procedure have been done in native therapeutic situation. Epidermoid carcinoma is the most frequent histology. We treat more than 15% of extra-thoracic tumoral diseases. The completeness rate is about 80%.

Conclusion: At the time of Big Data, EpiGELF have never been so actual and modern. Actually, EpiGELF is just starting. And we hope that data analyses will be pertinent and interesting. Exhaustivity will be the solution of that. In spite of that, EpiGELF is already according with the European rules in term of patient's data protection. EpiGELF is already recognized as a good recertification technique and as a good practice evaluation tool. EpiGELF bring also lot of human satisfaction. Cause since its beginning, EpiGELF represent a real federative adventure between different member of our group.

PO-297

ENDOBRONCHIAL ULTRASOUND ELASTOGRAPHY FOR BIOPSY IN A CHILD

Lo,Alvin、Lee,Pyng
National University Health System Singapore

Objective: Evaluating mediastinal adenopathy poses unique challenges in the pediatric population. EBUS-TBNA is of similar diagnostic accuracy to mediastinoscopy but without the attendant risks of general anesthesia.

Methods: A 10 year old boy (in the <3rd growth percentile) was referred for biopsy of an enlarged subcarinal lymph node that showed uptake of FDG on PET-MRI. He had undergone chemotherapy for AML 18 days prior and developed persistent fever despite broad-spectrum antibiotics. The subcarinal lymphadenopathy was amenable to biopsy using EBUS which would confer higher diagnostic accuracy and safety due to doppler and real-time needle confirmation, and less invasive than cervical mediastinoscopy. Parental consent was obtained for EBUS via the esophagus, endotracheal intubation and deep sedation. The subcarinal lymph node was visualized with convex EBUS (BF-UC260F, Olympus, Japan), and EBUS elastography revealed Type 2 pattern described as part-blue. Pus was aspirated from non-blue while tissue cores and needle aspirates were obtained from the blue areas. Specimens revealed abscess with numerous Candida and few Gram-positive cocci, and cultures yielded Candida krusei and Streptococcus mitis. The patient made good recovery following Caspofungin therapy for disseminated Candida infection. His disease is in remission.

Results: Convex EBUS scope has outer diameter 6.9 mm. Endotracheal tube size 8 and above or laryngeal mask airway size 4 can accommodate it. Because of our patient' s small stature the largest ETT was size 6, which precluded EBUS-TBNA via the trachea. EUS-B-TBNA using EBUS scope is better tolerated in children given its smaller size compared with endoscopic ultrasound gastroscope that measures 14.6mm in outer diameter.Ultrasound elastography measures tissue elasticity, and by characterizing differences in elasticity between pathological and normal tissues, data can be converted to RGB image where blue represents hard, green intermediate, and red soft tissue overlaid on B-mode image. Predominantly blue pattern (Type 3) is associated with malignancy, while non-blue (Type 1) and part-blue (Type 2) patterns are due to benign etiologies.The subcarinal lymph node of our patient demonstrated Type 2 pattern where pus was aspirated from red/green area, and tissue cores, cytology specimens obtained from the blue areas ruled out malignancy. PET-MRI is a promising imaging modality especially for children with malignancy who require repeated imaging since it reduces cumulative radiation exposure. Studies are required to define its role in diagnostic algorithm.

Conclusion: EUS-B-TBNA is an alternative to mediastinoscopy in children with mediastinal pathology. Ultrasound elastography is a useful adjunct that improves diagnostic yield.

PO-298

Customizing Airway Stent for Multicentric Malignant Airway Obstruction

Lo,Alvin、Lee,Pyng
National University Health System Singapore

Objective: Central Airway Obstruction interferes with airflow within trachea and primary bronchi. Insertion of airway stents provide effective relief and complement ablative techniques in patients.

Methods: A middle-aged man with metastatic sigmoid adenocarcinoma underwent neoadjuvant-chemotherapy followed by hemicolectomy and hepatectomy. The cancer progressed and he developed endobronchial metastasis with near-total obstruction of LMB. Laser photoresection of LMB tumor was performed followed by covered self-expanding metallic stent (SeMS). Six months later, he complained of worsening dyspnea and stridor. Imaging revealed complete occlusion of the distal end of stent with collapse of left lung. Rigid bronchoscopy revealed tumor in-growth through the stent; tumor at the main carina causing 70% obstruction of the RMB, and a polypoidal mass arising from the right middle lobe bronchus. Tumor debulking was performed within the stent and at the carina with APC and rigid forceps, and the polypoidal mass was removed with electrosurgical snare. The left limb of silicone Y stent was cut to accommodate the SeMS and circular cut was made just beyond the take-off of the right limb. The right limb of Y stent was deployed into bronchus intermedius, the circular cut maintained aeration to the right upper lobe. Post-procedural CXR showed re-expansion of the left lung.

Results : The metallic SeMS conforms to the airway, preserves mucociliary clearance and has low risk of migration due to airway epithelialization. The uncovered portion of SeMS allowed tumor ingrowth, which was recannalized by application of APC. If CAO affects trachea, main carina and bronchi, the silicone Y stent is preferred. The inner surface has silicone varnish to minimize mucus impaction, while the outer surface has studs to prevent migration. On-site modification can be performed by the physician. Charles Hull invented the world’s first 3D printer in 1983. This has extrapolated to medical use with CT/MRI data, which has led to the creation of personalised stents. To create an airway stent, the polymer must be able to withstand extrinsic compression without rupture, and adapt to complex shapes. Investigators from Spain and USA have produced silicone stents activated by platinum catalyzers, and one such stent has been successfully placed in a patient. Stents can be incorporated with Teflon coating to prevent bacterial colonisation and biofilm. Drug-eluting stents can slow-release chemotherapy over time to prevent tumor ingrowth and locoregional control or antifibrotic drugs to target granulation tissue are other attractive options.

Conclusion: Modification of stents may prove to be beneficial to patients with complex CAO.

PO-299

Utility of transbronchial cryobiopsy in diagnosis of diffuse interstitial lung disease

Wang,Guoan、Wu,Hongcheng、Ge,Ting、Zhou,Yingyan、Ye,Junkui、Guoan Wang
Department of Pulmonary and Critical Care Medicine， Ningbo Medical Center Li Huili Hospital

Objective: To evaluate the efficiency of transbronchial lung cryobiopsy(TBCB)in diagnosis of diffuse interstitial lung disease(DILD).

Methods: A total of 20 patients with radiographic features of DILD underwent TBCB in Ningbo Medical Center Li Huili Hospital from June 2019 to April 2020. The results of clinical data，radiological and TBCB were retrospectively analyzed.

Results: A total of 20 patients(male 6 female 14,meanage（52 ±16） years， range 40 to 75 years)with inconclusive diagnosis of interstitial lung disease wre sequentially enrolled. 5 patients under general anesthesia with rigid bronchoscopy and 15 patients under anesthesia with tracheal intubation. All the balloons were preset, and the frozen probe No. 19 was selected, and a suitable target site was selected for cryobiopsy. A total of 70 TBCB tissue samples were obtained with an average diameter of (4.5 ± 1.5) mm. 18 cases (90.O%) obtained a clear pathomorphological diagnosis, and the pathological type was 3 cases of organizing pneumonia (one of them considered related to lung cancer targeted therapy, and the other two considered cryptogenic organizing pneumonia), 3 cases of pulmonary alveolar proteinosis, one case of hypersensitivity,5 cases of idiopathic nonspecific interstitial pneumonia, 2 cases of asbestos-related interstitial lung disease, two cases of rheumatoid arthritis-related interstitial lung disease, one case of chronic eosinophil pneumonia, one case of usual interstitial pneumonia, and 2 cases of chronic inflammation disease, the diagnostic positive rate was 90.0% (18/20). The incidences of hemorrhage and pneumothorax were 50.0% (10/20) and 5% (1/20), respectively, and the amount of bleeding was small. One case had a bleeding volume of about 30ml, and the bleeding stopped after hemostatic treatment. The drainage tube is placed in the pneumothorax and absorbed after drainage.

Conclusion: Transbronchial crybiopsy has a high diagnosis rate for diffuse interstitial lung disease, less complications, and good safety. However, the sample size is small and needs to be further confirmed by large sample studies.

PO-300

Omalizumab Prescribed for Eosinophilic Granulomatosis With Polyangiitis Presenting as Asthma: A Case Report

Ma,Lijie1,2、Zhang,Hongjun2、Zhang,Haitao2、Gu,Xing2、马李杰
1. General Hospital of Western Theater Command
2. Tangdu Hospital， Air Force Military Medical University

Objective: Eosinophilic granulomatosis with polyangiitis (EGPA) is an autoimmune disease that affects multiple systems throughout the body. EGPA is characterized by allergic asthma, eosinophilia, fever, and systemic granulomatous vasculitis. Due to its low incidence, it is easily misdiagnosed and, therefore, often incorrectly treated.

Methods: We report an 8-year case history of a woman with EGPA whose symptoms manifested clinically mainly as asthma.

Results: The patient is a 42-year-old female teacher who has been suffering from an 8-year history of a respiratory-based illness since January 2011. We divided the medical history into 4 stages according to the treatment process: (1) stage 1 (suspicious bronchial asthma: slow start of disease, acute exacerbation); (2) stage 2 (diagnosed with EGPA); (3) stage 3 (routine treatment, including hormones, immunosuppressive agents, etc); and (4) stage 4 (treated with omalizumab). It was nearly 5.5 years, from January 12, 2011 to June 1, 2016, that the patient was finally diagnosed. And the condition was well controlled after treatment with omalizumab was initiated.

Conclusion: This case study promotes further understanding of EGPA in addition to providing a viable treatment option in the form of omalizumab for EGPA.

PO-301

Foreign Body Airway Obstruction Secondary to Pulmonary Artery Sling Surgery: A Case Report

Ma,Lijie1,2、Li,Chunmei2、Wang,Yan1、Li,Wangping2、Jin,Faguang2、马李杰
1. General Hospital of Western Theater Command
2. Tangdu Hospital， Air Force Military Medical University

Objective: Airway foreign bodies (AFBs) are more common in children, however, in most cases, AFBs are inhaled enters the airway by oral or nasal aspiration. Here, we report a case of 3-year-old female child who suffered from airway stenosis caused by iatrogenic, long-term foreign body secondary to pulmonary artery sling surgery.

Methods: The patient is a 3-year-old female child with no history of allergies or significant medical history other than a pulmonary artery sling and patent foramen ovale diagnosed and surgically repaired at 1.5 years of age. This admission, the child presents with the chief complaint, as told by the child’s mother, is coughing and wheezing that developed 18 months after she had pulmonary artery sling surgery. The symptoms have persisted for over 6 months and, upon evaluation, she was noted to have tracheal stenosis for more than 20 days.

Results: On cardiac color Doppler, a previous pulmonary artery sling surgery is evident. The left pulmonary artery has a fine inner diameter and accelerated blood flow. The mean concentration of exhaled nitric oxide is 21 parts per billion. Chest breathing analysis test shows moderate obstructive ventilation dysfunction. A chest computerized tomography (CT) report from October 23, 2017, revealed that the density of the tracheal lumen is not uniform above the carina, the left and right main bronchial lumina are still visible, the texture of both lungs is increased, and the shape and position of the heart shadow are within the normal range. The results of 3-dimensional (3-D) reconstruction of the chest reveal that the anterior chest wall is observed to have a surgical scar and the sternum was altered after the operation. Tracheal stenosis is evident at the level of the fifth or sixth vertebral body, and the narrowest anteroposterior diameter is approximately 0.38 cm and, the right diameter, approximately 0.44 cm. The hila of both lungs are not bigger than normal; the trachea and mediastinum are central. And this child was successfully treated with bronchoscopic interventional therapy.

Conclusion: This report shares the case of an iatrogenic foreign body that entered the airway due to tissue rejection and caused airway obstruction. It serves as a supplement to the airway foreign body and related literature, and provides insight into our chosen surgical techniques and experiences.

PO-302

Initial experience with bronchoscopic removal of airway foreign bodies: a retrospective study

Ma,Lijie1、Li,Chunmei2、Su,Zhenping1、Wang,Yan2、Li,Wangping2、Jin,Faguang2、马李杰
1. General Hospital of Western Theater Command
2. Tangdu Hospital， Air Force Military Medical University

Objective: Analysis of AFB-related data from specific countries and regions may provide meaningful information to guide treatment. This study was performed on 212 patients diagnosed with AFBs to share clinical experience of AFB treatments.

Methods: The present study retrospectively collected and analyzed clinical information of AFB patient at two centers from September 2008 to June 2019 and analyzed their demographic characteristics, foreign body types, clinical features, distribution sites, and treatment methods.

Results: The incidence of AFBs in male was 1.99 times to that of female patients, and 199 patients (93.87%)

had no clear risk factors for AFBs. A history of foreign body aspiration was reported in 43 of the patients (20.28%), and 39 patients (18.40%) were diagnosed and treated within 1 week after the onset of symptoms. The frequency of AFBs in the right lung was 2.13-fold to that in the left lung. AFBs in 210 patients were successfully removed by bronchoscopy, yielding a success rate of 98.58%. Biopsy forceps, foreign body forceps, cryotherapy probes, and foreign body baskets were used for removing of AFBs in in 55 (27.23%), 69 (34.16%), 41 (20.30%), and 12 (5.94%) patients, respectively. Granulation tissue hyperplasia was observed in 133 (62.74%) patients, and bronchoscopic cryotherapy was the most common treatment for granulation tissue and was solely used in 52 patients (24.53%).

Conclusion: patients with AFBs often had no identified risk factors and lacked specific clinical manifestations. Bronchoscopy was a reliable method for detecting and treating AFBs. Foreign body forceps, biopsy forceps, and cryotherapy probes were commonly used. Cryotherapy was the most common method for treating granulation tissue, alone or combined with other tools.

PO-303

Percutaneous transthoracic lung biopsy for peripheral lung lesions: a comparison between ultrasound and computed tomography guidance

Ma,Lijie、Zhang,Tingxiu、Wang,Qin、Qiao,Zanfeng、Shi,Guangqing、Xiao,Zhenliang、Zhang,Tao、马李杰
General Hospital of Western Theater Command

Objective: To compare the differences in puncture accuracy and complications between CT-PTLB and US-PTLB of adherent pulmonary space-occupying lesions.

Methods: This study retrospectively collected information on patients who underwent CT-PTLB or US-PTLB in the General Hospital of the Western Theater Command from January 2015 to December 2017 and compared accuracy, specificity, and sensitivity between CT-PTLB and US-PTLB. The incidence of complications, particularly pneumothorax and hemoptysis, was also compared between the two methods.

Results: The accuracy of CT-PTLB was significantly higher than that of US-PTLB (97.4% vs. 90.9%; P=0.034). However, there were no differences in sensitivity and specificity between the two methods. The total complication rate was higher for CT-PTLB than for US-PTLB (17.5% vs. 10.9%; P<0.05). Analysis of the diagnostic rates of CT-PTLB and US-PTLB in the different maximum diameter groups revealed no significant differences. However, when the maximum diameter was between 30 and 60 mm, the incidence of complications was significantly higher in CT-PTLB patients than in US-PTLB (P=0.036). Specifically, pneumothorax did not occur after US-PTLB, whereas its incidence was 6.84% after CT-PTLB. Additionally, the incidence of pneumothorax non significantly increased with a decrease in the maximum diameter in CT-PTLB patients.

Conclusion: Our results show that the accuracy of CT-PTLB is slightly higher than that of US-PTLB, although both were > 90% accurate. However, the incidence of general complications, particularly pneumothorax, is significantly higher for CT-PTLB than for US-PTLB. Our findings suggest that US-PTLB biopsy should be the technique of choice for pulmonary adherent mass lesions, if conditions permit.

PO-304

Persistent Left Pyopneumothorax on Patient With Systemic Lupus Erythematosus (SLE) Whom Performed Decortication

Hajar Azis,Andi Ibnu、Parsama Putra,Ngakan Putu
Medical Faculty of Brawijaya University Indonesia

Objective: Pyopneumothorax is a combination of air and pus in the pleural space, or a pneumothorax with accompanying empyema simultaneously on one side of the lung. The infection comes from microorganisms that form gas or from septic tears of lung tissue or esophagus into the pleural cavity. Most are from subpleural abscesses and often make bronchopleura fistulas. Systemic lupus erythematosus (SLE) is a chronic autoimmune inflammatory disease with an unknown etiology and clinical manifestations, progression of disease and prognosis. The clinical manifestations of SLE are extensive, involving the involvement of the skin and mucosa, joints, blood, heart, lung, kidney, central nervous system (CNS) and immune system.

Methods: -

Results: A 22-year-old-woman with shortness of breath since 1 week ago that got worsened within the last 3 days. There was no fever and weight loss. Patient was diagnosed with SLE since October 2015. At lung examination, there were decreased of vesicular breath sound and dullness on the left lung’s percussion. Chest X-ray examination showed narrowing of the left intercostal space and air fluid level of the left lung. Thoracic catheter extension was inserted to the left lung, and we maintained the pressure of water sealed drainage (WSD) to -20 mmH2O. After 27 days of treatment, the left lung did not inflate well; the patient was then referred to Department of Cardiothoracic Surgery for further decortication. The left lung was inflated back after decortication. Patient was discharged after one-week-post operation.

Conclusion: The insertion of thoracic catheter extension followed by decortication in persistent pneumothorax in patient with autoimmune disease demonstrated a good prognosis.

PO-305

Making inroads into no man's land!

Guliani,Abhinav、Ghosh,Shuvranu、Basu,Arup、Dhamija,Amit
Sir Ganga Ram Hospital, New Delhi, India

Objective : Endobronchial tuberculosis is a common manifestation of pulmonary TB. Incidence varies from 6-54%. Prognosis with treatment is variable, ranging from complete resolution to residual severe tracheobronchial stenosis. Interventional bronchoscopic procedures like balloon dilatation and at times, surgery may be required for patients who develop severe tracheobronchial stenosis causing significant symptoms. We present a unique case of complete occlusion of left main bronchus due to healed endobronchial tuberculosis, treated by bronchoscopic therapy.

Methods: 26year old female presented with severe intractable cough and dyspnea on exertion for 3 weeks. She was on ATT for 8 weeks prior to this for sputum positive tuberculosis with left-lung involvement. However, her initial symptoms had resolved. Her X-ray now had a complete left-lung collapse, CT showed a left main bronchus cut off with mucoceles in the left lower lobe with intact vasculature. Bronchoscopy revealed total occlusion of LMB with a web like stricture. There was a small dimple seen over the web and we probed it with a cautery knife creating a pinhole nick. Bubbling and later purulent discharge was seen coming from within assuring we were in the airway lumen. After extending the incision, serial balloon dilatation was done from 4 to 10mm. Scope could then be negotiated beyond; upto the secondary carina, showing intact integrity of the left main bronchus. Copious thick purulent secretions were

suctioned from within. Left lower division bronchus was also seen to be stenosed, which was dilated upto 8mm. Left upper division bronchus could hardly be seen and doubtful opening was probed using balloon dilator and serially dilated upto 8 mm. Underlying upper lobe and lingular bronchi were now visible and were inflammed. Secretions were cleared and in view of high likelihood of restenosis in such airways, 10mmX4cm SEMS was deployed in the left main bronchus ensuring patency of all sub-segmental bronchi. Video will be presented.

Results: Post procedure X-ray showed partially expanded left lung. She has been continued on ATT with oral steroids. Her follow up X-ray upto 2.5months has shown completely expanded left lung.

Conclusion: Airway fibrostenosis and stricture following healing are common sequelae of endobronchial tuberculosis. If diagnosed and treated early, the lung may be salvaged preventing auto-pneumonectomy. Subtle signs of probably viable lung(preserved vasculature/mucocele) should be looked for on CT in such cases. Subtle signs of possible path of airway(dimple sign) on bronchoscopy may guide further intervention helping save the lung.

PO-306

Hybrid approach for desobstruction and silicone t-tube stenting in blind-end tracheal stenosis – technique and early results

Cardoso,Paulo、Minamoto,Helio、Bibas,Benoit、Cremonese,Mariana、Rodrigues,Isaac、Pego-Fernandes,Paulo
Instituto do Coracao, Hospital das Clinicas HCFMUSP, Faculdade de Medicina, Universidade de Sao Paulo, Sao Paulo-SP, Brazil

Objective: Blind-end tracheal stenosis (Myer-Cotton type IV) is an extreme response to tracheal injury resulting in phonation ablation and need for a tracheostomy for breathing. This study presents a hybrid (endoscopic/surgical) approach for desobstruction and stenting to resume phonation and breathing through the natural airway.

Methods: Retrospective study of patients with blind-end post-intubation tracheal stenosis submitted to desobstruction by the hybrid approach between January/2017 and December/2019. All patients had a Myer-Cotton IV stenosis and a tracheostomy. Inclusion criteria: Spontaneous breathing; 14-70 years of age, non-eligibility for either primary repair or decannulation within 6 months or more, long segment (>10 mm) blind-end stenosis not amenable for dilatation as the only treatment. Exclusion criteria: Continuous anticoagulation, inability to undergo general anesthesia due to severe cardiovascular or pulmonary comorbidity, chronic aspiration. Planning used a neck and chest CT scan in all patients. Videoassisted suspension laryngoscopy was performed under general anesthesia. A 10 mm vertical cervicotomy was made in the midline of the upper border of the tracheostomy followed by desobstruction in 3 concurrent steps: 1) Puncture the obstructed airway through the enlarged tracheostomy stoma oriented by suspension laryngoscopy; 2) Tunneling using polyurethane dilators (#10 Fr through #28 Fr), and cutting forceps (Love-Gruenwald) for removal of the fibrotic posterior wall of the stenosis; 3) Placement of 12 mm or 14 mm T-tube silicone stent. Patients were evaluated every 6 months and the t-tube was changed on a yearly basis. Analysis included demographics and complications.

Results: Forty patients (32 males 8 females; median age 33 years) with post intubation tracheal stenosis were submitted to the procedure. The median intubation time prior to stenosis was 15 days. The mean extension of the stenotic segment on CT scan was 34±10 mm. The upper limb of the t-tube stent was placed in the infraglottic position in 36 patients (85.7%), and above the vocal cords in 6 (14.3%). Twelve complications occurred in 9 patients (22.5%) within 30 days after the procedure. The most frequent complications were subcutaneous emphysema (3), stent obstruction (3), bleeding (2) one requiring reintervention. There was no procedure related mortality. The median hospital stay was 2 days. All patients submitted to desobstruction resumed phonation after the procedure.

Conclusion: The hybrid approach for desobstruction of blind-end stenosis followed by a silicone t-tube stenting restored voice and breathing through the natural pathway in all patients.

PO-307

Effect of fundoplication for the treatment of gastro-esophageal reflux in the outcome of benign tracheal stenosis

Cardoso,Paulo1、Bianchi,Edno2、Minamoto,Helio1、Bibas,Benoit1、Salati,Michele3、Nasi,Ary2、Sallum,Rubens2、Cecconello,Ivan2、Pego-Fernandes,Paulo1

1. Instituto do Coracao, Hospital das Clinicas HCFMUSP, Faculdade de Medicina, Universidade de Sao Paulo, Sao Paulo-SP, Brazil
2. Department of Gastroenterology, Discipline of Surgery of the Digestive Tract, Esophageal Function Laboratory. Hospital das Clinicas, Faculty of Medicine of the University of Sao Paulo-SP, Brazil
3. Division of Thoracic Surgery, University of Ancona, Ancona, Italy

Objective: Association between gastroesophageal reflux (GER) and tracheal stenosis is scarcely reported and the available clinical data is not sufficient to support the assumption that the outcome of central airway stenosis worsens in the presence of GER. This study focuses on the outcome of benign tracheal stenosis in patients with gastroesophageal reflux treated by fundoplication.

Methods: Retrospective clinical study using propensity score matching (PSM) included patients with benign tracheal stenosis evaluated with esophageal manometry and esophageal dual probe 24-hour ambulatory esophageal pH study. The variables age, pH study and BMI were used in the model for pairing. Patients with abnormal pH study were managed either by laparoscopic modified Nissen fundoplication (Fundoplication group), or medical treatment with omeprazole 40mg bid (Omeprazole group). Patients with normal pH study were observed (Observation group). After a two-year follow-up, the outcome of the tracheal stenosis was compared between the groups using PSM. The outcome of the tracheal stenosis was considered satisfactory whenever the tracheal stenosis could be managed by tracheal resection with anastomosis, no need for further dilatation, or when definitive decannulation was achieved. The treatment groups were compared using a Fisher test. The statistical difference between groups used the Mann-Whitney and Brunner-Munzel t test. Groups were paired using the PSM by the method "nearest". Pairing quality was ascertained using distance density graphs. Group comparison was done by logistic regression using the method stepwise-forward. Statistical significance was assumed for $p< 0.05$.

Results: Of the 175 patients included (106 males and 69 females with a median age of 38.5 years), an abnormal pH study was found in 74 (42.3%), and 12.6% had typical GER symptoms. The 2-year follow-up was completed in 124 patients (20 in the Fundoplication group; 32 in the Omeprazole group; 72 in the Observation group). After PSM, the outcome of the tracheal stenosis in the Fundoplication group was similar to the Observation group (odds ratio 1 ; $p = 0.99$), and higher than in the omeprazole group (odds ratio 5.3 ; $p = 0.03$) (Figure). The observation group had a better chance of a satisfactory outcome of the tracheal stenosis when compared to patients in the Omeprazole group (odds ratio 3.5 ; $p = 0.02$).

Conclusion: The outcome of the airway stenosis was superior after laparoscopic fundoplication and was similar to patients without GER compared to medical treatment with omeprazole. A prospective randomized trial is warranted.

PO-308

Prospective evaluation of different EBUS-TBNA needles for molecular analysis in lung cancer

Darwiche,Kaid1、Theegarten,Dirk2、Schwarz,Birte1、Aigner,Clemens3、Wiesweg,Marcel4、Reis,Henning2、Schildhaus,Hans-Ulrich2、Schuler,Martin4、Karpf-Wissel,R ü diger1、Taube,Christian1
1. Department of Pneumology, Ruhrlandklinik - University Medicine Essen, Germany
2. Institute of Pathology - University Medicine Essen, Germany
3. Department of Thoracic Surgery, Ruhrlandklinik - University Medicine Essen, Germany
4. Division of Thoracic Oncology, Ruhrlandklinik - University Medicine Essen, Germany

Objective: In the era of targeted and immunotherapy of lung cancer the availability of adequate specimen samples allowing molecular analysis is of growing importance. EBUS-TBNA is considered to be the most frequently used procedure for tissue acquisition and the choice of the needle used for EBUS-TBNA might influence the rate of successful molecular analysis. The aim of this study is to prospectively evaluate quality and quantity of specimens obtained by different EBUS-TBNA needles.

Methods: Consecutive patients with suspected stage IV lung cancer referred for EBUS-TBNA were included in this study. Either a 22 G steel needle (Needle 1) or a more flexible 22G needle with a stylus made of nitinol (Needle 2) or a new developed core biopsy needle (Needle 3) were use for EBUS-TBNA with 3 needle passes. EBUS-TBNA specimens were placed on a slide and weighted. Then the material was placed in formalin and send to histopathological analysis, immunohistochemistry (including PD-L1 and ALK) and next-generation sequencing. The slide was transferred to an experienced pathologist who assessed the tumor cellularity.

Results: 66 patients were assessed for eligibility. After exclusion of 29 patients (no NSCLC n=15, no molecular analysis made out of the sample n=12, lost to follow-up n=2) 37 patients (23 men; mean age 65.4y) were finally analyzed. Histology confirmed NSCLC (Adenocarcinoma n=28; Squamous Cell Carcinoma n=4; Large Cell Carcinoma n=3; NOS n=2) in all cases with tumor stage IIIA in 4; IIIB in 2; IVA in 7 and IVB in 24 cases. 25 of 37 EBUS-TBNA specimen were obtained with needle 1. The mean weight of the specimen was 45.01 (± 43,19) mg with a mean DNA concentration of 11.63 (± 12,38) ng/µl. Tumor cellularity was assessed as follows: <5 in 6, 5-10 in 2, 10-20 in 5, 20-50 in 3, 50-100 in 2, 100-1000 in 7 and >1000 tumor cells in 12 cases. Immunohistochemistry could be performed in all but 2 cases (both with needle 2). Next-generation sequencing could be done in 29 cases (76.3%; 2 Needle 1 and 6 Needle 2-cases failed). Tumor cellularity, sample weight and rate of successful NGS was significantly lower when performed with needle 2. Results of needle 3 will be presented during the congress.

Conclusion: The needle used for EBUS-TBNA has an impact on quantity and quality of tumor tissue acquisition. The choice of the needle is of importance when aiming a high diagnostic yield for molecular analysis in lung cancer.

PO-309

A case of Allergic bronchopulmonary aspergillosis caused by Aspergillosis terreus presenting total left lung collapse

Wu,Bin
People's Hospital of Long hua Shen Zhen

Objective: Case report

A 56-yr-old non-smoker female presented with a week history of productive cough , purulent sputums and sweezing and was treated with antibiotics without any improvement.She was admitted to our hospitial on April 5,2018. Physical examination showed mediastinum was shifted to left,and breath sounds were decreated apparently at left lung field. The remainder of the examination was normal.Chest X-ray showed collapse of the left lobe(Fig.1A).The patient was health before.

Labratory data on admission demonstrated significant peripheral blood eosinophilia (0.85×109/L,13.5%) and elevated total serum IgE (1788 IU/ml);Arterial blood gas analysis showedPH:7.36,PO2:66mmHg,PCO2:40mmHg;Blood1,3-β-D-glucan(-),blood GM(-),Chest CT scan showed complete collapse of the left lung with mediastinal shift to the left(Fig.1B);Spirometry showed airflow limitation with forced expiratory volume in 1 second (FEV1) of 1.81 litres (62.3%of predicted), and FEV1/FVC of 69.86% of predicted,bronchodialator reversibility test was positive. Bronchoscopy revealed mucoid impaction which plugged the left mainstem bronchus(Fig.1C D);After removing the plug, yellow materials were observed in left lingual segment bronchial opening(Fig.1E),So EBUS-TBLB/PSB/BAL were performed(Fig.1F). Microscopic examination of brush cytology and histopathology showed them to be laden with branched mycelia(Fig.1G H), which was identified as A.terreusculture(Fig.1I),Meanwhile, BALF GM test was elevated(5.29).Thus, diagnosis of ABPA caused by Aspergillosis terreus was established and patient was started on oral itraconazole 200 mg/day and inhaled corticosteroid.She was followed up regularly with improvement in symptoms.

Discussion:

Allergic bronchopulmonary aspergillosis (ABPA) is a pulmonary disorder that is characterized by a hypersensitivity response to the allergens of the fun-gus Aspergillus fumigatus.A. fumigatus is by far responsible for the majority of these cases. but other fungi or yeasts have been identified when patients presented with features of ABPA,for instance, aspergillosis terreus monilia albicans rhizopus fusarium etc.The pathology of can be divided into There are two pathological categories of APBA: the characteristics of eosinophilic pneumonia, and the formation of airway mucus plugs, which contain lots of fungal hyphae,resulting in distal atelectasis and subsequent bronchiectasis.Based on the literatures, the diagnosis of APBA in this case, which caused by A. terreus was justified,with the similar characteristics including pathology,manifestations,laboratory data and radiographic features.

Methods Case report:

Results Case report:

Conclusion Case report:

PO-310

Research progress of bronchial occlusion in the treatment of pulmonary diseases

Wu,Weide、Wu,Weijing、Zeng,Yiming
Second affiliated Hospital of Fujian Medical University

Objective: With the continuous development of endotracheal interventional therapy technology, more and more interventional techniques have been used in clinical practice, and achieved good results. Bronchial occlusion is a new interventional technique in recent years. Compared with surgical operation, it is easier to operate and easier to learn. Bronchial occlusion is a kind of bronchial occlusive device made of silica gel. Through its blocking effect, it can be used to treat intractable pneumothorax, bronchopleural fistula, hemoptysis, pulmonary bullae and other diseases. So this review has been written to give people a better understanding of this technology.

Methods: The literature on technique of bronchial occlusion was reviewed.

Results: Clinical practice and exploration of bronchial occlusion find that this technique has the advantages of safety, effectiveness, less trauma, less complications and so on.

Conclusion: Bronchial occlusion has the advantages of safety, effectiveness, less trauma and less complications.

PO-311

Management of tracheo-esophageal fistulae post spine fixation.

HANNA,Amir1、Maurice,Karim 2、El Samadoni,Ayman 2、Zaki,Emad2、Attar,Ahmed2、Ahmed,Sabah2、Al Halafawy,Ahmed2、Nabil Al Kady,Mohamed2、Helal,Ashraf2、Mohsen,Tarek2
1. Marie Lannelongue Hospital
2. Kasr AL Ainy hospital, Cairo university

Objective: Management of chronic non tumoral tracheo-esophageal fistulae is sometimes challenging. We hereby present a novel technique using an excluded esophageal segment left in-situ to repair the fistulae and reconstructing the alimentary tract by a retrosternal left colon by-pass.

Methods: A 36 years old male patient, presented with a chronic tracheo-esophageal fistula related to a cervical spine fixation for Pott's disease 5 years before this presentation. Upper GIT endoscopy and fiberoptic bronchoscopy confirmed the presence of tracheo-esophageal fistulae 22 cm from the dental arch, 2 cm above the carinal level, and a perforation at the same level on the posterior wall of the esophagus by the fixator screws. Surgical repair was done by excluding a segment of the esophagus and a muscle flap was fashioned by incising and reflecting part of its wall in a "trap door fashion" to patch the fistula. The excluded segment was not closed from both sides, it was suture closed in the neck only while its lower part was plugged by an intercostal muscle flap to buttress the area of repair and to prevent mucocele formation. the alimentary tract was reconstructed by a retrostenal left colon bypass.

Results: The postoperative course of the patient was uneventful, fluids oral feeding started day 3 postoperative together with feeding by supplements through the jejunostomy tube. Patient was discharged at day 10 postoperative. The patient had good tolerance to oral fluids, 10 days later he started semisolid food. Long term follow up after 1 year, patient was tolerating solid food and had no dysphagia, no recurrent aspiration. CT chest and abdomen with IV and oral contrast revealed no abnormalities.

Conclusion: Management of chronic non tumoral tracheo-esophageal fistulae is sometimes challenging. Repair of chronic tracheo-esophageal fistulae can be done using a muscle flap from an excluded segment of the esophagus. Plugging the excluded segment with an intercostal muscle flap can potentially prevent mucocele formation. Retrosternal colon bypass is a successful approach to restore the alimentary tract in this situation.

PO-312

Efficacy and safety of transbronchial cryobiopsy through soft bronchoscope in diffuse parenchymal lung disease under conscious sedation and analgesia

Liu,Wei、Liu,Zhiguang、Wu,Huaiqiu、Deng,Hongying、Li,Yun
Hunan Provincial People's Hospital(The First Affiliated Hospital of Hunan Normal University)

Objective: To evaluate the efficacy and safety of transbronchial cryobiopsy(TBCB) under local anesthesia and conscious sedation and analgesia in parenchymal lung disease (DPLD)

Methods: Twenty-six patients(13 men and 13 women) aged 58.8±6.48ys (range 31-78y) with DPLD finished TBCB that performed in Hunan Provincial People's Hospital during March 2018 to December 2019 were selected. The clinical history, pulmonary function and chest high resolution CT of all patients were collected retrospectively. TBCB were performed under the conditions of local anesthesia with lidocaine (2-6ml, atomization), fentanyl (1-2μg/kg), midazolam (0.03-0.07mg/kg) intravenous sedation and analgesia. The results of hemorrhage, pneumothorax incidence, lesion size, pathology and microbiology during and after TBCB were recorded. The diagnostic rate and safety were evaluated.

Results: A total of 108 TBCB tissues were obtained in 26 patients, with an average of 4.2 pieces/person and an average diameter of 4.35± 1.09mm/piece. All patients successfully completed TBCB, of which 25 (96.2%) met the requirements of pathological diagnosis, 1 (3.8%) didn’t. 19 caese(73%) provided pathological diagnosis, including 3 cases of nonspecific interstitial pneumonia, 1 case of lung adenocarcinoma, 2 cases of alveolar proteinosis, 2 cases of pneumoconiosis, 3 cases of organic pneumonia, 2 cases of usual interstitial pneumonia, 2 cases of desquamation interstitial pneumonia, and 4 cases of connective tissue disease-related interstitial pneumonia; 5 cases (19.2%) provided effective diagnosis information. After multi-disciplinary consultation and follow-up after treatment, the diagnosis was confirmed as 1 case of mycoplasma infection, 1 case of IPF, 1 case of idiopathic interstitial pneumonia (non classifiable) and 2 cases of tuberculosis,the overall diagnosis rate was 92.3% (24/26). 2 cases (7.7%) could not be clearly diagnosed. During the operation, the bleeding was 10.9 ± 7.5ml/case, and stopped after local suction and spraying 1:10000 adrenaline,there was no serious bleeding requiring of surgery or vascular intervention. The incidence of pneumothorax was 23.1% (6/26), the compression degree range from 10%-80%, the average was 30.8%. Only one case needed closed drainage, the other five cases were treated with oxygen therapy. There was no significant difference with specimen diameter between the patients with(4.51±1.15mm) and without(4.29±1.07mm) pneumothorax(t=-0.917, P=0.361). Other operation related complications included paroxysmal supraventricular tachycardia in one case, no acute aggravation of interstitial lung disease, no anoxia, no unstable blood pressure and other complications.

Conclusion: The diagnosis rate of transbronchial cryobiopsy through soft bronchoscope under conscious sedation and analgesia is high in diffuse parenchymal lung disease, and there is no serious operation related complications.

PO-313

Efficacy of treatment based on trans-bronchoscopy interstitial brachytherapy for Lung cancer patients with airway stenosis

Kang,Xiuhua、Xu,Fei、Xie,Shiguang、Zuo,Wei、Luo,Feng、Hu,Min
The 1st Affiliated Hospital of Nanchang University

Objective: To evaluate the efficacy and safety of treatment based on iodine-125 radioactive seeds brachytherapy for airway stenosis caused by lung cancer.

Methods: We retrospectively analyzed 19 adults, who suffered from malignant airway stenosis, treated with trans-bronchoscopy interstitial brachytherapy in the 1st Affiliated hospital of Nanchang University from June 2018 to may 2019. All the patients were diagnosed of lung cancer by pathology and were followed up at least 6 months. The doses of iodine-125 radioactive seeds were planed by the treatment planning system (TPS). The treatment of enrolled patients could be iodine-125 radioactive seeds implantation alone or with other therapies. Re-examinations of bronchoscopy and CT scans were performed to determine the effectiveness of the treatment two months after the first trans-bronchoscopy iodine-125 radioactive seeds implantation. Then bronchoscopy or/and CT scans were selected to check based on the 1st follow up result. The following data were collected for analyzing: baseline characteristics, Dyspnea Index, Performance Status score, Airway Stenosis Degree, Stenosis Sites, Endoscopic measurements, Complications, Concurrent therapy. The Efficacy is evaluated by comparing the improvement of Dyspnea Index, Performance Status score, airway stenosis degree, the before and after treatment. Objective Response Rate(ORR, CR+PR) and Disease Control Rate (DCR, CR+PR+SD) were also applied to evaluation. Despite compared the efficacy before and after treatment, we have done the comparation between the subgroup(Iodine-125 seeds implantation alone vs combination with other endoscopic measurements, Iodine-125 seeds implantation alone vs combination with chemotherapy).

Results: Baseline characteristics:18 patients were male (94.7%), average age was 62 ys (range from 37-79 ys). For Histological type, 13 patients were squamous-cell carcinoma(68.4%), 2 patients were adenocarcinoma（10.5%）, 2 patients were small cell lung cancer（10.5%）, 1 patient was adenosarcomatoid carcinoma(5.3%), 1 patient was metastatic carcinoma (5.3%). TNM stage:1 patient were evaluated at stage II(5.2%), 8 patients in stage III(42.1%), while 10 patients in stage IV(52.6%) . Stenosis Sites: the stenosis sites were located at trachea(4/19, 21.1%), left main bronchus(8/19, 42.1%), right main bronchus(7/19, 36.8%), right middle bronchus(1, 5.3%), lobe bronchus(6, 31.6%) respectively. 7 patients had multiple sites stenosis. Endoscopic measurements: Interventions consisted of Iodine-125 radioactive seeds implantation alone(11, 57.9%), and combined with stenting(3, 15.7%)，Argon-plasma coagulation（4，21.1%）, high-frequency electrosurgical snare(2, 10.5%)，laser (2, 10.5%)，cryotherapy（3，15.8%）. 3 cases with exactly complicated airway stenosis procedured 3-6 interventions.Complications: There were no severe side effects related to the procedures except 3 patients had slightly blood-streaked phlegm or hemoptysis. Concurrent therapy: 8 patients underwent endoscopic measurements alone(42.1%) , while 11 patients combined with chemotherapy(57.9%). Dyspnea Index: Before treatment, the dyspnea index was 2.737±0.3044, while the post-treatment dyspnea index was 1.684±0.1881, this data showed significantly improvement of dyspnea index($P<0.05$). Airway Stenosis Degree: Airway stenosis degree was significant decreased after Iodine-125 radioactive seeds implantation (3.737 ± 0.2845 vs 1.842 ± 0.2566, $P<0.0001$) Performance Status score: There were slightly improvement of Performance Status score(2.474 ± 0.2689 vs1.895 ± 0.1509, $P>0.05$). Efficacy evaluation: The average follow-up time was 9.3M (5-17Months) ; For short term efficacy(as we defined in 6 months), we analyzed based on different treatment: Interventions consisted of Iodine-125 seeds combined with other endoscopic measurements showed a better ORR than Iodine-125 seeds implantation alone(62.5% vs 27.3%); Treatment of Iodine-125 seeds implantation combined with chemotherapy got a slightly benefit than Iodine-125 seeds implantation alone(45.4% vs 37.5%). DCR was over 90% among each group.

Conclusion: Trans-bronchoscopy implantation of Iodine-125 radioactive seeds is a safe and effective therapy for lung cancer patients suffered from airway stenosis. As different morphology of airway neoplasm, we need to apply other endoscopic measurements to remove airway obstruction, and hemostasis as well. Iodine-125 seeds implantation combined with other endoscopic measurements or chemotherapy could achieve better efficacy.

PO-314

Nerve ablation and M3 acetylcholine receptor reduction in both treated medium-sized airways and untreated small airways after BT of canine: role of neuronal effect in airways

Luo,Yulong、Chen,Yanqiuzi、Su,Zhuquan、Li,Shiyue

Objective: Ablation of smooth muscle is considered as main mechanism of bronchial thermoplasty (BT) in treating severe asthma by now. But this local effect in treated medium-size airways is insufficient to explain the symptom relief and lung function improvement post BT treatment. The effects of BT on untreated small airways and airway inervation may contribute to its therapeutic effect on asthma, but they are not clearly elaborated yet.

Methods: Twelve healthy male beagle dogs were randomly divided into a control group and a BT group and BT treatment was performed in medium-size airways (diameter > 3 mm) in the lower lobe of the lung in BT group. Twelve weeks later, lung sections were used to evaluate the histological changes in the treated medium-size airways and in the untreated distal small airways.

Results: In BT group, the amount of smooth muscle in the treated medium-size airways was significantly reduced, but not for untreated small airways. In the treated medium-size airways of dogs in BT group, PGP9.5 positive nerves was significantly decreased throughout the entire airway wall, and in the residual smooth muscle and nerve bundles. M3 receptor expression in the treated medium-size airways was significantly decreased in the epithelium, submucosal glands and residual smooth muscle in the BT group. In the untreated small airways, PGP9.5 positive nerves and M3 receptor expression in the entire airway wall were both significantly decreased in the BT group 12 weeks after treatment.

Conclusion: BT treatment at medium-size airways significantly decreased the distribution of PGP9.5-positive nerves and M3 receptors both in treated medium-size airways and untreated distal small airways. This suggests that neuronal effects are one of essential mechanism for BT in treating asthma.

PO-315

Preliminary experience of the ultrathin cryoprobe for the diagnosis of peripheral pulmonary ground-glass opacity lesions

Sun,Jiayuan1,3、Jiang,Simin1,4、Liu,Xiaojun2、Chen,Junxiang1,3
1. Shanghai Chest Hospital， Shanghai Jiao Tong University
2. First Hospital of Shanxi Medical University
3. Shanghai Engineering Research Center of Respiratory Endoscopy
4. Yongzhou central Hospital

Objective: It is very difficult to obtain samples for pathology diagnosis of peripheral pulmonary ground-glass opacity (GGO) lesions by traditional transbronchial lung biopsy (TBLB). The current study was conducted to evaluate the diagnostic value and safety of transbronchial lung cryobiopsy (TBCB) for peripheral pulmonary GGO lesions by a newly developed cryoprobe with a diameter of 1.1 mm.

Methods: Patients with peripheral pulmonary GGO lesions that received TBCB using the innovative cryoprobe was retrospectively analyzed from October 2018 to November 2019 in Shanghai Chest Hospital. All procedures were performed with the guidance of navigation bronchoscopy, radial probe endobronchial ultrasound and fluoroscopy. Data

including lesion size, proportion of ground-glass composition, freezing time, specimen size, specimen quality, positive rate of diagnosis and complications were collected.

Results: TBCB was performed in 20 patients with 23 lesions, of which 3 patients underwent biopsy at 2 sites respectively. The mean lesion size was 21.58±11.88mm, ground-glass composition over 50% existed in 21 lesions, and there were 12 pure GGO lesions. The freezing time ranged from 3s to 5s for each lesion. The qualified rate of specimens confirmed by pathology was 91.30% (21/23). The mean size of the specimens was 3.65±1.27mm after formalin fixation during the process of pathology examination. Among the 23 lesions, 19 were successfully diagnosed by TBCB with a diagnostic yield of 82.61%, of which, 12 were adenocarcinoma, one was occupational lung disease, one was pulmonary meningothelial-like nodule and 5 were inflammation which confirmed by clinical follow-up. All of the 4 lesions failed to be diagnosed by TBCB were diagnosed as adenocarcinoma by further analysis in combination of a second biopsy, surgery and clinical follow-up. No patients presented pneumothorax or severe hemorrhage in this study.

Conclusion: The study demonstrated that the ultrathin cryoprobe is feasible and safe for the diagnosis of pulmonary GGO lesions with high diagnostic yield, which provided a huge potential tool for the diagnosis of GGO lesions, especially for these suspicious of early-stage lung cancer.

PO-316

Cryo Lung biopsy with Supraglottic Airway

Subramanian,Santhakumar1、Jaganathan,Venugopal 1、TH,Deepak1、Mehta,Sangita sharma1,2、Varatharajan,Ramesh1,3
1. Consultant Pulmonologist
2. Cosultant Pathologist
3. Consultant Anaesthesiologist

Objective: Transbronchial cryo lung biopsy is usually done under general anaesthesia with rigid bronchoscopy as per current standards. Using rigid bronchoscopy is technically challenging, needs expertised training, needs deeper form of anaesthesia and paralytic agents and its is not without serious complications. Supraglottic airway is an alternate conduit through which cryobiopsy can be done safely with lesser anaesthesia, lesser time duration and with comparable yeild

Methods: Adult patients (>18 years) with 1.Clinico radiological suspicion of diffuse parenchymal lung disease, 2.Non-resolving pneumonia where a tissue diagnosis is warranted were included. We have done transbronchial cryo biopsy by using a supraglottic airway, with freezing time to 2-4 seconds, biopsy at most periphery with in 1 cm distance from pleura(DPLD Cases) or at a preferred site(non resolving pneumonia cases). Laryngeal mask airway was used in all patients. Prophylactic balloon and fluoroscopic monitoring were used in all the patients. The 1.9 size cryo probe was used in all patients. This technique was followed in 40 patients as an outpatient procedure and an observational analysis on anaesthesia required, complications and yield were done.

Results: Among the total of 40 patients, 15 were females. Majority (87.5%) were above 40 years of age. The average doses of anaesthetic agents were as follows – fentanyl 100 μg, midazolam 2 mg, propofol 200±50 mg. No relaxant was used in any of patients. Mean duration of procedure was around 39 min. There was one hospital admission due to pneumothorax (2.5%) requiring drainage. No patient significant airway bleed requiring further intervention. The mean cross-sectional area of the samples was 13.3±4.35 mm2. Mean number of alveoli present were 110±81). Histopathological diagnosis was made in 35 patients (87.5%) and 5 patients were non diagnostic

Conclusion: Tranbronchial cryobiopsy can be done by using a supraglottic airway. Although this technique yields results with positive trend, a further randomized comparitive analysis with large sample size is to be done to further elaborate this technique.

PO-317

Unique use of radial biopsy forceps to secure airway stent!

Guliani,Abhinav、Dhamija,Amit、Basu,Arup
Sir Ganga Ram Hosital

Objective: Stenting is a practical, universally available method to establish airway patency in tracheal stenosis. Migration of stents is reported to be a common complication (silicone:16.6–24% and metallic:2.2–6.4%). Various studies describe fixing stents using a transtracheal suture with negligible migration thereafter. We report an interesting case where a short metallic stent was fixed to the upper trachea after recurrent migration.

Methods: 17year old female initially presented with severe progressive respiratory distress, stridor and was found to have a peritracheal mass compressing the trachea and main bronchi. She was initially managed with a Y-SEMS to establish airway and allay symptoms. She had mediastinal fibrosis on biopsy and was initiated on steroids, with which she improved and the lesion decreased on a subsequent scan 3 months later. Y stent was removed and underlying trachea showed excessive granulation tissue with critical stenosis of around 7mm limited to proximal trachea starting just below the cords. Lower trachea and main bronchi were normal. To establish airway patency she was planned for balloon dilatation and silicon stent but Rigid bronchoscope(size 11) could not be negotiated beyond cords and was seen to cause significant trauma. Thus we converted to SEMS(size 4cmX10mm). She presented back within 3 weeks with excessive cough and radiology showed inferior migration of the stent, which was later repositioned into place. But this recurred after 10 days. We redeployed the stent and planned to fix it using sutures. 0.5cm vertical incision was made on the skin opposite 2-3rd tracheal cartilage. We inserted a 14G cannula into the tracheal lumen along anterolateral aspect on both sides sequentially from outside(via incision) under direct vision and trocar removed leaving sheath in place. Nylon monofilament suture(2-0) was inserted via the catheter from one side leaving suture within tracheal lumen and catheter removed. Radial biopsy forceps were inserted from the catheter sheath from the other side (inserted one ring below) and suture end was held and pulled out using the forceps and catheter withdrawn under direct vision from scope. The suture was tied outside and the knot buried under the skin. Video will be presented.

Results: There was no evidence of migration/skin infection after 3 months of observation and the stent was later removed.

Conclusion: Suture fixation of stent is an effective method to prevent migration. The described method is a simple, feasible and efficient way to fix a stent with already available equipment in bronchoscopy suite.

PO-318

Effects of cisplatin plus recombinant human endostatin (rh-endostatin) intratumoral injection on Maligment central airway obstruction

Zhou,Yunzhi、Gao ,Yongping、Zhang, Nan、Li ,Xiaoli、Wang ,Hui、Wang ,Shufang、Liu ,Jiankun、Gao ,Hong、Wang,Hongwu
Emergency General Hospital

Objective: Maligment central airway obstruction (MCAO) is offen caused by primary cancer or metastasis tumor which is associated with significant morbidity and mortality.The objective of this study was to determine the efficacy and safety of cisplatin plus recombinant human endostatin (rh-endostatin) intratumoral injection on cancer in central airway.

Methods: We conducted a retrospective analysis of patients with malignant airway obstruction treated with bronchoscopic intratumoral injection of cisplatin plus rh-endostatin.Subjects were treated with four injections of 20-

40 mg of cisplatin mixed in 2-4ml of 0.9% NaCl and 15mg of rh-endostatin(3ml). Treatments were completed 1 week apart.Symptoms,bronchoscopy,and spirometry was assessed at 30 days following final dosing.

Results: Symptoms were alleviated in 347 patients with MCAO treated with cisplatin plus rh-endostatin intratumoral injection at day 30 after treatment. Significant increases in FEV1 (mean difference: 0.31L, 95%CI: 0.06–0.52L, P <0.01) and FEV1/FVC%(mean difference: 7.40%, 95%CI: 0.03%–21.15%, P=0.025) at day 30 post-treatment was observed compared with baseline.Patients with both primary cancer and metastasis tumor achieved good response with reduction in airway obstruction.Most of the patients depend on histology had good response more than 80%.No severe adverse events were reported.

Conclusion: Cisplatin and rh-endostatin intratumoral injection is effective and well tolerated for the therapy of MCAO.

PO-319

Pulmonary eosinophilic granuloma diagnosed using bronchoscopy: a case report

NAKASHIMA,MASANAO、UTSUMI,KENTA、TERADA,TOMOKO、AOYAMA,AZUSA、SHIGA,KOUJIROU、ODA,MAKOTO、FUKUNAGA,MASAHARU、NAGAI,ATSUSHI
Shin-yurigaoka General Hospital

Objective: Pulmonary eosinophilic granuloma is a rare disease of unknown etiology. It is a non-cancerous growth with histopathologic characteristics of Langerhans' cell granulomatosis and eosinophilic infiltration. Herein, we report a rare case of pulmonary eosinophilic granuloma diagnosed using transbronchial lung biopsy (TBLB).

Methods: A 48-year-old man presented to our hospital with complaints of progressively worsening cough and breathlessness with chest pain. He had been smoking 10 cigarettes/day for 28 years. Chest computed tomography (CT) revealed multiple centrilobular small nodules and thin-walled cysts. TBLB was performed using bronchoscopy to obtain the diagnosis. Histopathological characteristics of the nodular lesions on chest CT were correlated with cellular granulomas, mainly composed of Langerhans' cells and eosinophils. The Langerhans' cells were positive for both S-100 protein on immunohistochemistry. We diagnosed the patient with pulmonary eosinophilic granuloma.

Results: Smoking cessation was the first-line treatment. The symptoms of cough and dyspnea improved poorly. We treated the patient with oral prednisolone 25 mg/kg (0.5 mg/kg). Follow-up chest CT showed absorption of the nodule and thin-walled cysts. The symptoms of cough and dyspnea improved significantly.

Conclusion: Herein, we presented a case of pulmonary eosinophilic granuloma diagnosed using TBLB.

PO-320

Correlation Between Carcinoembryonic Antigen (CEA) Serum Level With Endothelial Growth Factor Receptor (EGFR) Mutation From Tissue And Plasma Sample On Non Small Cell Lung Cancer Patients

Hardiyanto,Frenky、Dwi Pratiwi,Suryanti、Putu Parsama Putra,Ngakan
Medical Faculty Of Brawijaya University， Malang， Indonesia

Objective: Lung cancer is one of the leading causes of cancer deaths in the world. The most common type of lung cancer is Non Small Cell Lung Cancer (NSCLC). Patients with NSCLC can have EGFR mutation and increased level of CEA. EGFR mutation test on NSCLC has very important role for EGFR tyrosine kinase inhibitor (TKI) therapy. CEA is also expected to predict treatment efficiency of EGFR-TKI therapy. Tumor tissue biopsy is an invasive method and has come constraints, despite the golden standard testing. Circulating tumor DNA (ctDNA) is a new and less invasive for detecting EGFR mutation using plasma sample. In this study, we investigated the relationship between serum CEA and EGFR mutations in tissue and plasma in NSCLC patient.

Methods: This cross sectional observational research was conducted in Dr. Saiful Anwar General Hospital Malang from August 2018 until July 2019, 76 NSCLC patients who had undergone test of EGFR mutation from tissue, ctDNA, and serum CEA level. Extracted DNA from plasma and tissue samples from citology or biopsy was checked for the EGFR mutation. The serum CEA levels were analyzed using electrochemical luminescence.

Results: From 76 participants, EGFR mutation from tissue samples positive detected on 34 subjects and ctDNA detected 19 subjects. Serum level of CEA >5 ng/ml was significantly associated with EGFR mutation from tissue sample (p=0.037) with an odds ratio of 2.778 (95% CI: 1.050-7.348), the area under curve for CEA was 68,8% and cut off CEA 9.14 ng/ml. Serum level of CEA >5 ng/ml was also significantly associated with ctDNA (p=0.015) with an odds ratio of 4.8 (95% CI: 1.259-18.299), the area under curve for CEA was 78,1% and cut off CEA 14.8 ng/ml.

Conclusion: Serum CEA level has moderate correlation with mutation of EGFR from tissue and ctDNA in NSCLC patients. Patients with increased level of CEA >5 ng/ml are 2.778 times more at risk to had EGFR mutation and 4.8 times more at risk to had ctDNA positive mutation.

PO-321

Spray cryotherapy maybe a potential treatment of airway diseases--Physiologic and histopathologic effects of liquid nitrogen spray cryotherapy in the lung of canine models

Duan,Hongxia、Xie,Shuanshuan、Li,Xuan、Wang,Changhui
上海市第十人民医院（同济大学附属第十人民医院）

Objective: The evidence of bronchial epithelium playing a critical role in airway homeostasis is increasing these years which provide new therapeutic strategies. Liquid nitrogen spray cryotherapy is an experimental bronchoscopic procedure to disrupt epithelium cells by freezing. Detailed reports about the physiologic and histologic effects of spray cryotherapy were scarce so far. The feasibility, safety, and efficacy of cryotherapy in canine animals were assessed and the physiologic and histopathologic effects of spray cryotherapy in the lung of canine models were explored.

Methods: Eight labradors and two beagles underwent spray cryotherapies in different bronchi using a liquid nitrogen metered spray device provided by Senscure in Ningbo, China. All animals were assessed for the basic vital signs and health status prior to and following spray cryotherapy. Histological changes and IL-8, IL-10 levels in BALF

post cryotherapy immediately, 2 days, 7 days and 30 days were evaluated.

Results: A beagle died of sudden cardiac death during treatment in the preliminary experiments and no adverse effects were seen in formal experiments. Spray cryotherapy produced a loss of epithelium immediately and reduction of goblet cells amount and RBM thickness post 30 days. All treated bronchi exhibited airway integrity. Damage to nerves, vessels, smooth muscle and cartilage were minimal and the bronchial tissues proximal and distal to the treatment was normal. Spray cryotherapy procedure effectively descended the levels of IL-8 and IL-10 in BALF which provided an evidence to be applied to airway inflammation and research the relationship between epithelial structures and immune microenvironment post cryotherapy in the future.

Conclusion: We provide novel insights into the interventional therapy for airway diseases that liquid nitrogen spray cryotherapy uses to destruction of bronchial epithelial cells in target areas and repair quickly with no scars. We also uncover the reasonable spray time in bronchi with different diameters and upper limit of spray time, beyond which the risk of bleeding and heart attacks increases. Finally, the reduction of goblet cells number, the thinning of RBM thickness post operation make the effect of spray cryotherapy on bronchial epithelium very significant and the findings that IL-8, IL-10 levels in BALF reducing post cryotherapy indicates that cryotherapy also causes changes in the bronchial microenvironment and modulating these cytokines might be a novel mechanism for spray cryotherapy.

PO-322

Feasibility of low dose CT for bronchoscopy for peripheral lung lesion

SEOL,HEE YUN1、EOM,JUNG SEOP2、LEE,GEEWON3、KIM,INSU4、JEONG,YEON JOO3
1. Department of Internal Medicine, Pusan National University Yangsan Hospital, Yangsan, Korea
2. Department of Internal Medicine, Pusan National University School of Medicine, Busan, Korea
3. Department of Radiology, Pusan National University School of Medicine, Busan, Korea
4. Division of Pulmonology, Department of Internal Medicine, Dong-A University Medical Center, Busan, Korea.

Objective: Thin-section CT is essential to identify small peripheral bronchi during peripheral bronchoscopy using radial probe endobronchial ultrasound. We performed a retrospective study with a prospectively collected database to identify the optimal radiation dose for thin section CT for peripaheral bronchoscopy.

Methods: A total of 91 patients with peripheral lung lesions underwent thin-section CT (both standard-dose CT as a reference and low-dose CT). Subjects were randomly assigned to one of four groups: group 1 = 120 kVp, 25 mAs; 2 = 100 kVp, 15 mAs; 3 = 120 kVp, 5 mAs and 4 = 100 kVp, 5 mAs. Two chest radiologists evaluated effective dose, image noise, wall thickness of the peripheral airway and bronchus sign.

Results: The median effective dose of standard CT scan was 3.1 mSv (2.7–3.7) and the effective doses of low dose CT scans were significantly different among the four groups (median effective dose, 0.88, 0.34, 0.19, and 0.12 mSv for groups 1–4, respectively; $P < 0.001$). The degree of image noise in low dose CT was significantly increased from groups 1 to 4 ($P < 0.001$ for both Radiologists 1 and 2). The differences in peripheral airway wall thickness in group 4 were significantly higher than those in the other groups ($P = 0.011$) in the evaluation of Radiologist 2, whereas, there was no significant difference in those of Radiologist 1 ($P = 0.103$). In the analysis of Radiologist 1, the bronchus sign of low dose CT in groups1 and 2 completely corresponded with those of standard CT, however, the accuracy of bronchus sign of low dose CT was decreased to 83% and 73% in groups 3 and 4, respectively ($P = 0.003$). In the analysis of Radiologist 2, the accuracies of bronchus sign on low dose CT in groups 3 and 4 were lower than those of groups 1 and 2, however, there was no statistical difference (96%, 100%, 88%, and 82% for groups 1–4, respectively; $P = 0.143$).

Conclusion: Our results indicated that low-dose thin-section CT with effective dose of > 0.34 mSv (effective dose of group 2) is feasible for peripheral bronchoscopy.

PO-323

Endobronchial Valve for Airway Fistula: a Clinical Observation of 2 Cases

Liao,Huai、Guo,Yubiao、Xie,Canmao
First Affiliated Hospital of Sun Yat-sen University

Objective: To explore the efficacy and safety of endobronchial valve(EBV) in the treatment of airway fistula.

Methods: Retrospective analysis of July 2018 to June 2019 of 2 cases of airway fistula with diameter less than 5mm, treated with EBV implantation through bronchoscope, including 1 case of stump fistula after lobectomy and 1 case of bronchiolopleural fistula.

Results: A total of 3 EBV stents were implanted in 2 patients, and 2 cases (100%) were cured clinically. No serious complications occurred during and after operation, the main complications were cough and no stent displacement.

Conclusion: Bronchoscopic EBV implantation is effective and less complication in the treatment of small airway fistula with diameter less than 5mm.

PO-324

Successful treatment of a complex benign central airway stenosis through bronchoscopy intervention: a case report

Yang,Li、Gu,Ye、Wang,Hai、Yu,Dongmei、Wang,Hao
Shanghai Pulmonary Hospital, Tongji University School of Medicine

Objective: Complex benign central airway stenosis recurred frequently and required multiple treatments. We reported a case of a complex benign central airway stenosis caused by trauma and successfully treated by bronchoscopy intervention.

Methods: The case was a 36-year-old male suffered from serious chest injury after car accident. Six months later, central airway stenosis was gradually appeared, and then was treated with airway stenting. However, stenosis recurred because of severe granulation. Then surgical airway plasty was given, including median split esophageal repair, tracheostomy fistula flap placement and tracheal T-tube placement. Still, the upper trachea under the annular cartilage was narrowed, the peripheral wall was softened, and the granulation proliferated. We attempted to treat stenosis by multiple bronchoscopy intervention including dilation, cryotherapy and electrocautery. Triamcinolone was injected in the mucosa to inhibit granulation proliferation.

Results: The patient's airway stenosis was improved significantly and stablely.

Conclusion: Benign airway stenosis caused by trauma can achieve better clinical outcomes through surgery and multiple bronchoscopy intervention.

PO-325

Radial endobronchial ultrasound assisted transbronchial needle aspiration for the pulmonary peripheral lesions adjacent to the central airway

Yang,Li、Gu,Ye、Wang,Hai、Yu,Dongmei、Wang,Hao
Shanghai Pulmonary Hospital， Tongji University School of Medicine

Objective: The aim of the present study was to improve the preoperative diagnosis rate of the pulmonary peripheral lesions that located near the central airway and outside the bronchus.

Methods: Radial endobronchial ultrasound (R-EBUS) followed by transbronchial needle aspiration (TBNA) was used to acquire samples for diagnosis. Patients were enrolled prospectively when preoperative CT showed that the lesion was located at the peripheral zone of the lung, adjacent to the central airway and located in one side After bronchoscopy reached to the bronchi around the lesion, the ultrasound probe was used to determine the location of the lesion. Then ultrasound probe was withdrawn, and puncture was performed under direct vision. Specimens were used for pathological examination.

Results: Twenty patients were enrolled in our study, including 13 males and 7 females, with an average age of 50 years old. Totally 17 patients were successfully diagnosed with samples taken from TBNA, including 6 cases of lung cancer, 1 case of tuberculosis, 2 cases of pneumonia, and 1 case of cryptococcal infection. The other 3 patients were diagnosed by postoperative pathology, including 2 cases of lung cancer and 1 case of sclerosing cell tumor. The diagnosis rate was 85%.

Conclusion: With the assistance of R-EBUS, TBNA acquired sufficient samples that achieved a good diagnosis rate for peripheral lung lesions near to the central airway without intrabronchial invasion.

PO-326

Safety and efficacy of uncovered self-expandable metallic stents in tracheobronchial tuberculosis stenosis for long-term placement

Li,Fuqi1、Huang,Haidong1、Dong,Yuchao1、Zhang,Wei1、Yao,Xiaopeng1、Wang,Qin1、Li,Qiang2、Bai,Chong1
1. Changhai Hospital， Naval Medical University(Second Military Medical University)
2. Shanghai East Hosptial Affiliated to Tongji University

Objective: The long-term placement of uncovered self-expandable metallic stents (uSEMS) for benign tracheobronchial stenosis was controversial. This study was conducted to find out the characteristics of safe and effective cases of long-term uSEMS placement in tracheobronchial tuberculosis stenosis (TBTS), analyze factors leading to restenosis after uSEMS placement, establish a prediction restenosis model with the Restenosis Score and provide evidences for patient selection and choices of bronchoscopic treatment before uSEMS placement.

Methods: A retrospective cohort analysis of all patients with TBTS treated with uSEMSs which were long-term placed (>6 mon.) between 2000.01 and 2008.12 in Changhai Hospital, Shanghai, China.

Results : (1) Seventy-seven TBTS patients received long-term placement of uSEMSs. Forty-eight patients (62.34%) didn’t develop restenosis after uSEMS placement, the other 29 patients (37.66%) developed. In the non-restenosis group, uSEMS-related complications included mild granulation tissue hyperplasia (47.91%) and mild scar hyperplasia (6.25%). The average number of procedures per patient after stents placement was 2.50±3.21, including cryotherapy，needle-shaped electric knife and electrocoagulation, which were 0.58±1.65,0.52±1.29 and 0.25±0.53,

respectively. During at least 10 years of follow-up, these patients (45/48 93.75%) achieved good living conditions. Adverse events included occasional cough and mild dyspnea after activity. In the restenosis group, the main causes of restenosis were severe granulation tissue hyperplasia (89.66%) and severe scar hyperplasia (51.72%). Interventional treatments were performed on average 16.70 ± 13.04 times after stenting, including electrocoagulation、needle-shaped electric knife and cryotherapy， which were 4.30±4.60, 2.81±2.84 and 2.30±3.58, respectively. During the follow-up, 4 patients had improved symptoms and got stable conditions, 12 remained under interventional therapies, 11 had bronchial atresia and 9 of them underwent surgery. Adverse events were severe dyspnea after activity and severe cough. （2） Three factors were significantly related to the occurrence of restenosis: the type of stenosis, the number of thermal treatments received before the stent, the difference value between the length of uSEMS and the length of the stenosis segment. In the group of Restenosis Score < 0, the incidence of restenosis was 8.57% (3/35). The incidence of restenosis was 61.90% (26/42) in the group of Restenosis Score ≥ 0. The difference between the two groups was significant (p<0.001).

Conclusion: It is safety and efficacy of uSEMS for long-term placement in a significant number of patients with TBTS. The Restenosis Score may have the potential to identity individuals benefiting from long-term placement of uSEMS and help to select the appropriate bronchoscopic treatments before uSEMS placement.

PO-327

Endoscopic closure of respiratory fistulas with cardiac septal defect occluders or vascular plugs

Lao,Miaochan、Gao,Xinglin、Chen,Pingping、Li,Jing、Miaochan Lao
Guangdong Provincial People's Hospital， Guangdong Academy of Medical Sciences， Guangdong Provincial Institute of Geriatrics

Objective: Respiratory fistula is a relatively rare but refractory disease. The development of endoscopic methods of treatment may provide a choice in treating this condition. The goal of this paper was to report a series of patients with acquired respiratory fistulas treated with cardiac septal defect occluders or vascular plugs, and find out which kind of patient could get benefit from this procedure.

Methods: 13 patients with acquired respiratory fistulas (12 males and 1 female, mean age 62.6±10.4 years) were included. There were 5 bronchopleural fistulas, 2 tracheopleural fistulas, 2 tracheoesophageal fistulas, 3 bronchoesophageal fistulas, and 1 tracheogastric fistula. Fistula size was unmeasurable in 6 patients, and 6-12mm in other 7 patients. The underlying disease was post-lobectomy or post- pneumonectomy in 7 patients, esophageal diverticulum in 1 patient, esophageal squamous cell carcinoma in 1 patient, post-intubation in 1 patient, and idiopathic in 3 patients. Fistulas was diagnosed by bronchoscopy in 8 cases, by injecting methylthionine chloride into pleural cavity in 3 cases, by Injecting methylthionine chloride into esophageal diverticulum in 1 case, and by Chartis in 1 case. Cardiac septal defect occluders or vascular plugs were implanted through a flexible bronchoscope to close the fistulas. Atrial septal defect (ASD) Amplatzer occluders was implanted in 10 cases, ventricular septal defect Amplatzer occluder in 1 case, patent ductus arteriosus occluder in 1 case and vascular plugs in 1 case. The mean follow-up was 6.3±6.6 months. The longest follow-up was 18 months.

Results: Fistulas in 12 patients were successfully closed with no procedure related complication. Patients recovered soon after procedure from aspirated pneumonia, mechanical ventilation and pneumothorax. The one case of bronchopleural fistula which was not visualized from bronchoscopy, and the leaking bronchus was detected by Chartis testing, was with persistent leakage after occlusion procedure. New fistulas were found at the edge of Amplatzer occluders in 3 cases of tracheoesophageal/bronchoesophageal fistulas out of 5 cases 3-17months after the occlusion procedure. Refractory empyema occurred in 1 case of bronchopleural fistula, and the Amplatzer occluder was removed by surgery. The other 5 cases of tracheopleural/bronchopleural fistulas were uneventful in the follow-up period.

Conclusion: Endoscopic closure with cardiac septal defect occluders or vascular plugs could successfully and safely close most of tracheopleural/brochopleural fistulas soon after the procedure and in a long-term period. The occlusion could successfully close tracheoesophageal/bronchoesophageal fistulas in short-term, and may result in new fistula in longterm.

PO-328

Quantitative CT analysis of fissure integrity and emphysema heterogeneity for one-way valve treatment; Analysis in Japanese COPD patients

Mineshita,Masamichi、Nishine,Hiroki、Handa,HIroshi、Kida,HIrotaka、Furuya,Naoki、Morikawa,Kei、Inoue,Takeo、Masamichi Mineshita
St. Marianna University School of Medicine

Objective: Bronchoscopic lung volume reduction (BLVR) is a promising treatment option for carefully selected severe emphysema patients. BLVR with one-way valves has demonstrated clinical and meaningful improvements in patients with both heterogeneous and homogenous emphysema without collateral ventilation. The U.S. Food and Drug Administration approved the use of one of one-way endobronchial valves (EBV) in 2018. StratX is a quantitative CT analysis software that can evaluate fissure integrity and tissue destruction. StratX is used to identify and screen appropriate candidates for BLVR with one-way valves. Patients with fissure integrity score of <80% are not considered for EBV treatment. However, if quantitative CT analysis shows a fissure completeness between 80 and 95%, then additional measures to confirm the absence of collateral ventilation are required. If the fissure completeness is >95%, EBV treatment can be directly performed. Although BLVR with one-way vale could be introduced into Japan in the near future, there is a lack of data for the adaptability of this treatment in Japanese COPD patients.

Methods: High-resolution CT (HRCT) scans for severe COPD patients were retrospectively analyzed using StratX software retrospectively. Homogeneous emphysema was defined as less than a 15% difference in emphysema destruction score between target and ipsilateral lobes. The difference in in volume-weighted percentage was measured using the density scores of the target lobe and the ipsilateral nontarget lobe at -910 Hounsfield units. In this study, the target lobe was defined as the most affected lobe with 70% or more emphysema destruction score in each patient.

Results: HRCT scans of 27 patients with severe COPD (GOLD stage III=17, stage IV=10) were analyzed. Patient characteristics were as follows: male, 23; age; 72.9±6.3 years; %FVC, 81.0±16.8%; %FEV1, 35.3±9.8% and FEV1% was 34.5±6.2%. Of the 27 patients, 5 patients were defined as heterogeneous emphysema. Target lobes were found in 19 patients (70%), 8 patients (heterogeneous n=1; homogeneous n=7) had target lobes with fissure completeness of more than 95%, 6 patients (heterogeneous n=2; homogeneous n=4) with 80 to 95% fissure completeness, and 5 patients (heterogeneous n=2; homogeneous n=3) with less than 80% fissurecompleteness.

Conclusion: After screening HRCT scans of Japanese patients by StratX software, we found that close to half of the GOLD stage III and IV patients were considered candidates for thorough examination for BLVR treatment with one-way valve.

PO-329

Avoiding Stenting in Post intubation/trachesotomy tracheal stenosis

Chima,Kamran Khalid、Naqvi,Mazhar Ali 、Hussain,Muhammad
Services Institute of Medical Sciences

Objective: Self-expanding metallic stent1, silicon stents2 and electrocautery/APC3 have been used for post intubation/trachestomy tracheal stenosis and cause profuse granulation, stent fracture and mucostasis requiring repeated interventions. This may be due to pre-existing tendency of scar formation in these patients as response to local injury. we aim to use no cautery not cutting technique to avoid restenosis and scarring

Methods: Adult patients (age 16-60) with simple Tracheal stenosis. Tracheal stenosis due other causes or managed by electrocautry, stenting were excluded. Pre- op imaging, Spirometry and video bronchoscopy was performed. Informed consent and anesthesia fitness was obtained. All patients were managed as day care cases. Rigid bronchoscopy under GA was performed with Efer-Dumon Series-III system and largest diameter tracheal tube was inserted according to patient`s glottic size. Trachea was examined with flexible video bronchosopce Olympus -180 series; Stricture was examined by ultrathin scope Olympus. Serial dilatations were performed using the graded bronchial tubes under videoscopic/telescopic guidance. Final dilatation was performed by advancing the tracheal tube on bronchial tube with circular rotations to fully dilate the stricture. This had a tamponade effect on stricture resulting in minimal hemorrhage. Patients were discharged after 3-6 hours of observation and followed up in OPD biweekly and then monthly with symptoms inquiry, dyspnea scoring, examination and spirometry. Re-examine was planned if symptomatic or reduced FEV1. Patients were followed up to 6 months.

Results: Nine patients with simple tracheal stenosis due to tracheal intubation (7) and tracheostomy(2). Mean age was 25+5. 5 males and 4 females. 7 had severe tracheal stenosis with lumen 4mm or less and FEV1 <1L while 2 patients had moderate to severe stenosis with 6mm size and FEV1 1-1.6L. Located at 1-3rd tracheal ring. All were managed with tracheal dilatation and post procedure improvement in FEV1 3 months after the procedure was 1L.

Conclusion: Mechanical dilatation of simple tracheal stenosis using serial dilatation tubes under videoscopic/telescopic guidance is safe, effective and cheaper alternative to stenting with no recurrence of symptoms in our patients. By avoiding electrocautery/APC in these patients we did not see recurrence of granulation.

PO-330

Individualized Customized Silicone Stent for Airway Fistula: a Clinical Observation of 8 Cases

Liao,Huai、Liu,Qionghui、Xie,Bizhen、Guo,Yubiao、Xie,Canmao
First Affiliated Hospital of Sun Yat-sen University

Objective: To explore the efficacy and safety of individualized silicone stent in the treatment of airway fistula.

Methods: A retrospective analysis of 8 cases of airway fistula with diameter more than 5mm treated with individualized silicone stent implantation from Dec 15,2017 to Dec 24,2019, including 3 cases of stump fistula after lobectomy, and 5 cases of esophageal airway fistula after esophageal cancer treatment.

Results: In 8 cases, 14 fistulas were successfully sealed by customized silicone stent. 7 cases (87.5%) were cured and 1 case (12.5%) was partially improved. No serious complications occurred during and after operation. The main complications were postoperative cough, sputum retention and slight granulation hyperplasia, without stent displacement.

Conclusion: The efficacy of customized silicone stent in the treatment of airway fistula with diameter more than 5mm is definite, and the complications are few, which is worthy of further clinical study.

PO-331

Clinical Study of Vascular Intervention Combined with Bronchoscopy Intervention in Treatment of Airway Tumor

Yang,Ming、Wang ,Kailv、Li ,Wenjun、Zeng,Qiang、杨明
The third hospital of MianYang

Objective: To investigate the effect of chemotherapy and / or embolization by bronchial artery infusion in the treatment of airway tumors before tracheal intervention.

Methods: Nine patients with pulmonary tumor and airway stenosis were analyzed, including eight malignant tumors and one benign tumor. Bronchial arterial infusion chemotherapy and/or embolization were performed before tracheal intervention.

Results: Eight patients with malignant tumors had significantly reduced lesions after bronchial arterial infusion chemotherapy and embolization, and the symptoms of dyspnea were significantly improved after bronchoscopic interventional; For the patient with benign tumors，the symptoms of dyspnea immediately improved after surgery.

Conclusion: Application of bronchial artery infusion chemotherapy and/or embolization is safe and effective cause of significantly reduced risk of bleeding, and be helpful in expanding the indications for airway intervention.

PO-332

Endobronchial ultrasound as a novel approach for the management of tracheobronchopathia osteochondroplastica: a case report

Lin,Huihuang、Zeng,Yiming
The Second Affliated Hospital of Fujian Medical University

Objective: Tracheobronchopathia osteochondroplastica (TO) is not only rare but also has varied and nonspecific clinical manifestations. Therefore, the treatment and management of TO is still indefinite. The bronchoscopy is recommended as a gold standard for the diagnosis of TO. However, submucosal changes of TO is invisible through bronchoscopy, so it cannot accurately evaluate the progression and treatment response of the disease. Consequently, it’s desirable to explore a suitable approach to detect submucosal changes for satisfactory management of TO.

Methods: We performed bronchoscopy and radial probe endobronchial ultrasound (EBUS) for a 62-year-old asymptomatic man whose chest computed tomography (CT) showed multiple calcified nodules projecting from the anterolateral wall of the trachea. And the tissue sample from the nodule was also obtained through bronchoscopy.

Results: Histopathological examination of the bronchoscopic biopsy samples illustrated submucosal ossification formation. A diagnosis of TO was made. EBUS of the airway wall showed hyperechoic density of 0.5cm thickness.

Conclusion: We think EBUS is a suitable approach for the follow-up and management of TO, especially for the detection of submucosal changes.

PO-333

Tentative study on radial endobronchial ultrasonography evaluating airway wall thickness before and after bronchial thermoplasty Longitudinal ultrasonography

Shang,Yan1、Zhu,Chengjie1,2、Wang, Qin1、Huang ,Haidong1、Bai,Chong1、商艳
1. Department of Respiratory and Critical Care Medicine， Changhai Hospital， Navy Military Medical University
2. Section of Health， No.94804 Unit of The Chinese People's Liberation Army

Objective: Aim: we aimed to observe the clinical practicing value of radial endobronchial ultrasonography evaluating airway wall thickness before and after bronchial thermoplasty.

Methods: Methods: we selected two patients who received bronchial thermoplasty in our hospital. We measured the thickness of each segmental airway wall of each patient by radial endobronchial ultrasonography, and observed the difference before and after the therapy. All the treatments and measurement were performed by a designated bronchoscopist and the locations and depths of the ultrasound probe were relatively fixed, to reduce the operational error.

Results: Results: in both two patients, the mean thicknesses of all segmental airway walls was 4.9±0.7 mm before the first session of BT; the mean thickness was 4.13±0.92 mm before the second session; the mean thickness was 2.69±0.68 mm before the third session; the mean thickness was 2.7±0.5 mm in the follow-up measurement at six months after the BT treatment; all thicknesses of airway wall were significantly reduced comparing with those before treatment ($P < 0.05$); all the thicknesses of the airway walls were stable without any tendency of thickening after six months ($P > 0.05$). Although the airways in the right middle lobe of both two patients were not received BT, their thicknesses were also decreased comparing with those before the treatment; both upper lobes bronchus of both two patients were not activated in the first and second sessions, but their thicknesses were also decreased at the third measurement.

Conclusion: Conclusion: radial endobronchial ultrasonography is a simple and practical method to measure the thickness of patient’s airway wall. Bronchial thermoplasty can effectively reduce the thickness of airway wall. It can reduce airway smooth muscle by direct activation and other possible more complicated mechanism, which need further research.

PO-334

Endobronchial Treatment of Giant Emphysematous Bulla with Self-made Conical Silicon Spigots

Lin,Huihuang、Zeng,Yiming、Song,Duanhong
The Second Affliated Hospital of Fujian Medical University

Objective: Giant emphysematous bulla (GEB) can compress adjacent normal parenchyma and impair gas exchange, leading to dyspnea on exertion and, sometimes, pneumothorax. The surgical bullectomy has been recommended as the standard treatment. However, when a patient refuses surgery or is not a surgical candidate, we can choose less invasive procedure as the treatment. The aim of the study was to evaluate the clinical efficacy of the endobronchial treatment of GEB using self-made conical silicone spigots (SCSS).

Methods: Four patients with GEB were enrolled in the study. After preoperative evaluation and planning with the computed tomography (CT) and virtual bronchoscopic navigation (VBN) system, SCSS were placed in the segmental bronchi through bronchoscopy to functionally isolate the airway that supplied the bulla.

Results： After the procedure, there were increases in the mean value of forced expiratory volume in 1s (FEV1) [from 1.2±0.25L (49.75±11.35%) to 1.33±0.30L (55.50±12.77%)] and forced vital capacity (FVC) [from 2.62±0.76L (77.25±19.52%) to 2.84±0.65L (85.25±17.06%)], reductions in the mean value of total lung capacity(TLC) [from 7.08±0.82L (139.25±11.44%) to 6.30±0.21L (124.50±10.15%)] and residual volume (RV) [from 4.38±0.62L (194.50±19.67%) to 3.46±0.70L (154.25±30.90%)]. The 6-minute walk test (6MWT) distance was also improved greatly (mean change +60 m). The follow-up CT demonstrated noticeable reductions in the size of the bullae in the four patients (from 13.26±4.86 cm to 9.52±2.54 cm). The average occurrence time of the above changes was 45±38 days after the procedure. Two of the patients experienced infective exacerbations of their chronic obstructive pulmonary disease on days 1 and 2, respectively, after their procedures.Both fully resolved after 7-day courses of an appropriate antibiotic and prednisolone.

Conclusion： The endobronchial SCSS treatment can be an effective therapeutic option and warrants further investigation in surgically unfit patients with GEB.

PO-335

Rigid bronchoscopic dilatation of postintubation tracheal stenosis

Zhang,Nan、Tao,Meimei、Zhou,Yunzhi、Zou,Heng、Wang,Zhina、Wang,Hongwu
Emergency General Hospital

Objective： Rigid bronchoscopic dilatation is considered an effective technique for the treatment of postintubation tracheal stenosis (PITS). However, less analysis have been made on the target. This study aims to demonstrate the safety and long-term benefits of progressive rigid bronchoscopic dilatation.

Methods： A retrospective analysis of patients with postintubation tracheal stenosis treated with progressive rigid bronchoscopic dilatation were performed in one single session. These cases did not undergo additional concurrent endobronchial intervention.

Results： The median age was 43 years (range 18–81), and 63.3% of patients were male. The main presenting symptom was dyspnea in all 15 cases. The type of their PITS was distributed as follows: 10/15 tracheal stricture, 5/15 tracheal stricture with granulation. All 15 patients obtained immediate dyspnea relief after rigid bronchoscopy dilatation. Median tracheal lumen diameter previous and post dilation was 4 (range: 2–6) and 8 (range: 6–11). No patient experienced pneumothorax, bleeding, respiratory distress, any other procedural complication, or mortality. The median follow-up time was 23 months. The mean number of sessions was 5 (range 4–10).

Conclusion： Rigid bronchoscopic dilatation is an effective and safe modality to treat PITS. Prospective studies with more patients are necessary.

PO-336

Single application of airway stents in thoracogastric-airway fistula: comparison of silicon and fully covered self-expendable metallic bifurcated stents

Tao,Meimei、Zhang,Nan、Zhou,Yunzhi、Zou,Heng、Wang,Zhina、Wang,Hongwu
Emergency General Hospital

Objective: Silicon stents and fully covered self-expendable metallic stents (SEMS) are widely used to treat thoracogastric-airway fistula (TGAF). However, less study make a comparison between the two type of stents. This study aims to explore the effectiveness and complications between silicon stents and SEMS for TGAF.

Methods: We retrospectively included TGAF patients receiving airway bifurcated stents from March 2014 to March 2019. SEMS or silicon stents were implanted to cover orifices under interventional bronchoscopy based on imagings. TGAF healing was defined as the primary outcome, and complete sealing of TGAF as the second outcome. Granulation and mucostasis were also analyzed post stent implantation.

Results: Of the 53 patients, 29 (25 males, 86.2%) received SEMS and 25 (21 males, 84.0%) with silicon stent. Healing was achieved in 18 (34.0%) patients, and complete sealing in 42 (79.2%) patients. There were no significant differences in healing and complete sealing rates between patients receiving SEMS and silicon stents. However, the tracheal and right main bronchial diameters in the SEMS group were significantly larger than those in the silicon stent group (P=0.015). No perioperative death or massive hemorrhage occurred. The silicon stent implantation led to a reduced incidence of sputum retention (44.0%, 11/25) compared with that (75.0%, 21/29) in SEMS group (P=0.001). Hyperplasia of granulation tissue happened in 16 cases in silicon stent group (64.0%) and 23 cases in SEMS group (82.1%) (P<10-3).

Conclusion: Both silicon and covered metallic airway stenting are effective to close TGAF. Compared with SEMS, silicon stent leads to less granulation proliferation and sputum retention.

PO-337

The Mounier-Kuhn syndrome:a case report and literature review

Wei,Peng、Li,Yu、Li,Yinkang、Qin,Caicheng、Liu,Guangnan
Department of Respiratory Medicine， The Second Affiliated Hospital of Guangxi Medical University

Objective: To analyze and summarize the etiology, clinical symptoms, bronchoscopic manifestations, and current status of respiratory endoscopic interventional therapy for Mounier-Kuhn syndrome(MKS),so as to enhance the knowledge of MKS.

Methods: A case of MKS diagnosed in the Department of Respiratory Medicine of the Second Affiliated Hospital of Guangxi Medical University was reported, and the keywords with “ Tracheobronchomegaly” , “ Mounier-Kuhn syndrome” were screened through the mode of literature retrieval in CNKI, VIP,WANFANG and Pubmed databases so as to get about high-quality related reviews for recent 20 years.

Results: There were 217 cases around the world，among which there were only 16 cases in China. MKS is frequently seen in middle-aged men, and most of the patients are smokers. The ratio of men to women is 8 to 1. The disease is characterized by abnormal dilatation of the trachea and main bronchi，often accompanied by tracheobronchomalacia and tracheal diverticula. Congenital absence or atrophy of airway smooth muscle may be a potential cause. Flexible bronchoscopy can easily find the tracheobronchomalacia and tracheal diverticula, which is

very helpful for diagnosis. The clinical symptoms of this disease are various, and the treatment is mainly to prevent and control the infection. Rigid bronchoscopy with YAP laser treatment、Airway Stenting and Tracheobronchoplasty were suggested as potential therapeutic options to these patients with tracheobronchomalacia and tracheal diverticula.

Conclusion: MKS is a rare disease with unknown etiology and widely various clinical symptoms. Flexible bronchoscopy is very helpful in the diagnosis of this disease. Respiratory endoscopic interventional technology plays an important role in the treatment of MKS, especially for those patients with tracheobronchomalacia and tracheal diverticula.

PO-338

Treatment of primary tracheal glomus tumors: two case reports and a literature review

Guo,Li、Wang,Ke
West China Hospital Sichuan University

Objective: Glomus tumors (GTs) are rare soft tissue neoplasms. Several treatment options have been reported for tracheal GTs including thoracotomy, bronchoscopic electrocautery, Nd: YAG laser, and cryotherapy. However, few studies have evaluated the ideal treatment for tracheal GTs.We reported 2 rare cases of primary tracheal GT. The size, site, invasion, degree, and corresponding treatment of reported tracheal GTs were also reviewed.

Methods: One at the level of C7–T1 that was resected using bronchoscopy, and the second in the lower trachea, which was treated by thoracotomy. The literature of reported tracheal GTs were also reviewed.

Results: Both of them achieved good results and no recurrence was seen at the final follow-up.tracheal GTs has invaded the tracheal wall; tumor diameter is greater than 2 cm, and located in the middle, or distal trachea; the tumor has malignant characteristics, and rich vascularity; and the basilar part of tracheal GTs is widely, were the indications of surgical treatment. The benign tumor is strictly, confined to the airway lumen without extension into the airway wall; tumor diameter is less than 2 cm; the tumor is located in the upper trachea; and the patients are considered unacceptably high risk for anesthesia, and surgery were the indications of endoscopic intervention.

Conclusion: We recommend choosing the most appropriate approach to manage tracheal GTs based on patients' general condition, and tumor characteristics to obtain an excellent prognosis. Our 2 cases of tracheal GT were managed by different approaches, and both achieved good results.

PO-339

The application and security of painless medical thoracoscopy in the etiological diagnosis of pleural effusion

Xu,lisheng1、Ji,Xiang1、Li,Tao1、Pan,Pengfei1、Liu,Xiaoping2、Xu,Zhiyun1、Wang,Aihua1、Li,Yu1、徐立升
1. Department of Respiratory and Critical Care Medicine
2. Department of anesthesiology

Objective: The aim of this study was to investigate the clinical feasibility and security of painless Medical Thoracoscopy (PLMT) under combination with local infiltration and intravenous anesthesia, in the etiological diagnosis of pleural effusion. However, It might be profitable for patients to receive intravenous anesthesia to really reach the painless state, and this combination would even reduce the dose of intravenous anesthetics and increase the safety.

Methods: Approved by Research Ethics Committees(2019152), a prospective cohort study was performed to compare the difference between "local and intravenous anesthesia" and only local anesthesia in tradition. Totally, 60 patients who received Medical Thoracoscopy for diagnosis were enrolled to join this research, from Date July 2018 to Sept 2019. They were randomly divided into observation (PLMT) and control group by computer-generated randomization list. Patients in control group received local infiltration anesthesia. In PLMT, intravenous anesthesia was performed with 1-2mg/kg propofol (Added injection dosage of 0.5mg/kg every 15 min), 1-2mg midazolam and 5-10 μg sulfentanil to achieve moderate sedation level, besides local anesthesia with 150mg lidocaine(2%) + 75mg ropivacaine(0.75%) for incision. The primary objective of the study was to observe Visual Analogue Scale (VAS) in operation, and 1 hour(1h), 6 hours(6h) after surgery. The secondary objective was to survey the intraoperative and postoperative change of Blood pressure, Heart rate, Respiratory rate, SaO2. Consciousness and the incidences of adverse events.

Results: In operation, VAS of PLMT group was obviously decreased ($p<0.01$) (Figure 1A), which was similar as an hour and 6h after surgery($p<0.01$)(Figure 1 BC). There were increased Heart rate and Blood pressure in control group, while decreased Heart rate and Blood pressure were found in PLMT($p<0.05$, compared with pre-anesthesia). In observation on 6 hours after surgery, somnolence is the most common complication with the rate of 16% ($p<0.05$). There was no significantly increased adverse events in or after surgery(Table 3). Other data in the process of endoscopic surgery was also shown in Table 2 and 3. On expense, the total expenditure of PLMT is RMB 1900 yuan on average, which is less than twenty times lower in comparison with video-assisted thoracic surgery(RMB 40000 yuan) for pathological examination and endoscopic treatment.

Conclusion: The study suggests painless medical thoracoscopy with local and intravenous anesthesia to endure security and anesthetic effect. It benefit from improved patients' comfort, decreased operation time and lower rate of Hyoxemia and other events in high risk during the surgery.

PO-340

Cellular Fibrous Histiocytoma of pulmonary with Endoscopic Treatment

Cui,Jinhe、Guo,Lijin
Affiliated Hospital of Putian College

Objective: To study the efficacy of endoscopic treatment for benign lung tumors

Methods: a 58-year-old male, visited to our hospital because of hemoptysis, with a smoking history of 35 years。Dened allergy history and family genetic history。 We finished related inspections after admission.A mass can be seen in the right main bronchus on chest CT scan（Fig1,2）.Obvious enhancement can be seen on chest enhancement CT（Fig3,4）。For this reason,We implemented a bronchoscopy。The right intermediate bronchus mass can be seen under the bronchoscopy。We made a transbronchoscopic lung biopsy (TBLB)（Fig5,6）。Pathological results suggested spindle cell tumor（Fig7,8）。We communicated with the patient and his family,then,they made a decision to refuse to have surgery.After that ,we communicated with pathology,considered that the mass probably was a benign tumor.So，we implemented tumor resection under bronchoscopy-guided high-frequency electrosurgical snare combined with argon plasma coagulation(Fig9,10).Large specimen pathology suggested the mass was cellular fibrous histiocytoma of pulmonary(Fig 11，Fig12).One week later,We had another bronchoscopy,Hyperplasia of fresh granulation tissue can be seen in the intermediate bronchus under bronchoscope.We elimanated granulation tissue by bronchoscopic cryotherapy(Fig13,14).The patient did not have other side effect after therapy.And the symptoms of hemoptysis disappeared.

Results: Five months later,reexamination of chest CT showed no obvious signs of recurrence.There was nothing wrong with the patient(Fig15,16).Fourteen months later,chest CT examination. Similarly，showed that there was no obvious obstruction in the intermediate bronchus(Fig17,18).

Conclusion: Endoscopic treatment for benign lung tumors is a treatment worth considering.

PO-341

Diagnostic performance of endobronchial ultrasound-guided transbronchial needle aspiration for benign and malignant mediastinal/hilar lymphadenopathy

He,Yuping1、Zhou,Rui2、何玉平
1. The Third Hospital of Changsha
2. The second Xiangya hospital of Central South University

Objective: to evaluate the diagnostic performance of endobronchial ultrasound-transbronchial needle aspiration (EBUS-TBNA) for benign and malignant mediastinal/hilar lymphadenopathy.

Methods : Clinical data, imaging features and pathological diagnosis of 204 inpatients with mediastinal or hilar lymphadenopathy presented by thoracic CT who underwent EBUS-TBNA at the Second Xiangya Hospital of Central South University between January 1, 2015 and December 31, 2018 were retrospectively analyzed.

Results: 117 of 204 patients with final diagnosis of malignancy, 94 patients were verified by EBUS-TBNA (diagnostic yield 80.3%), with 91 lung cancer, 2 lymphoma and one primary mediastinal small cell neuroendocrine carcinoma. 18 cases of EBUS-TBNA negative lung cancer were further identified by other invasive methods. 87 of 204 patients with final diagnosis of benign diseases, 30 of which were confirmed by EBUS-TBNA (diagnostic yield 34.5%), with 12 tuberculosis, 13 sarcoidosis and 3 inflammations. Another 23 tuberculosis, 23 sarcoidosis and 6 inflammations which were EBUS-TBNA negative were final diagnosed. The overall diagnostic yield of EBUS-TBNA for malignancy was significantly higher than that of benign diseases. The sensitivities of EBUS-TBNA in the diagnosis of lung cancer,

tuberculosis, sarcoidosis and inflammation were 83.5%, 34.3%, 36.1% and 33.3%, respectively. The sensitivity of EBUS-TBNA for the diagnosis of lung cancer was significantly different from that of tuberculosis, sarcoidosis or inflammation($p < 0.05$). Diagnostic yield was significantly higher when the short axis of the lymph node size ≥10mm compared with less than 10mm in the malignancy group($p < 0.05$). The overall complication rate of EBUS-TBNA was 2.45%(n=5). Moderate bleeding happened in one patient, and the procedures were terminated with 2 patients suffered from tachycardia and one with intense coughing, and the last one with fever after the procedure, other patients were well tolerated and no severe complications.

Conclusion: The data demonstrate that EBUS-TBNA is superior in the diagnostic sensitivity of malignant mediastinal/hilar lymphadenopathy compared with benign diseases. The diagnostic yield is related to the lymph node size in malignancy, higher diagnostic yield could be detected when the short axis of the lymph node size ≥10mm compared with less than 10mm. EBUS-TBNA is a safe and minimally invasive procedure.

PO-342

Photodynamic Therapy for Early Lung Cancer in Bronchus: A Cases report

Hu,Anke、Zhang,Huaping、Zeng,Yiming
Department of Respiratory and Critical Care Medicine, the Second Affiliated Hospital of Fujian Medical University, Quanzhou, China.

Objective: To explore the effect of photodynamic therapy for early lung cancer in bronchus and to enhance the understanding of photodynamic therapy.

Methods: A 73-years-old male was diagnosed with COPD (chronic obstructive pulmonary disease, COPD) for 3 years with repeating cough, expectoration and dyspnea, and the condition exacerbated for 4 months, then hospitalized on 8 August, 2019. The chest CT of HuiAn county hospital shown that pneumonia disease, pneumoconiosis and secondary pulmonary tuberculosis, bilateral pleural effusion, multiple pulmonary bullae in bilateral superior lobe. And then he had bronchoscopy, revealed that there were neoplasms in the bronchus of upper lobe of the right lung. The pathology results from a bronchoscopy biopsy identified (in anterior segmental bronchus of the upper lobe of the right lung) bronchial mucosa have high-grade squamous intraepithelial lesion (squamous cell carcinoma in situ). We considered that the elderly patient with poor lung function was unable to tolerate surgery. With chest CT enhancement scan, it showed irregular density shadow in the posterior segment of the right upper lung, inflammatory probably. We found neoplasms at secondary crest in anterior-apical segment of right superior lung lobe in second bronchoscopy and the histopathology showed that squamous cell carcinoma in situ with local foci and infiltration. We provided PDT (Photodynamic treatment, PDT) at the right upper bronchus on August 29, 2019 and August 30, 2019 (total energy was 60J and 40J respectively)

Results: The bronchoscopy was reexamined in HuiAn county hospital after 8 weeks, the neoplasm disappeared at secondary crest in anterior-apical segment of right superior lung lobe.

Conclusion: PDT provides an opportunity for radical treatment of inoperable patients with early central intratracheal lung cancer.

PO-343

Analysis of the therapeutic effect of holmium laser bronchoscopy in the treatment of broncholithiasis under the support of HF (high flow)

Guo,Guohua、Xiao,Jianhong、Song,Bin
Department of repiratory medicine，mindong hosptial affiliate to fujian medical university

Objective: To evaluate the effect of holmium laser in the treatment of broncholithiasis under the support of high flow.

Methods: from January 2014 to December 2017, nine patients with broncholithiasis were treated by holmium laser, including 6 males and 3 females, aged 42-68 years, with a median age of 52 years. All 9 cases were treated for cough, shortness of breath, hemoptysis and pyroxene. The location of broncholithiasis: 4 on the left main trachea, 3 on the right middle bronchi and 2 on the main bronchi. The chest CT findings of 9 cases showed high-density shadow in the bronchi and obstruction of the lumen, which may be accompanied by distal bronchostenosis, dilation, obstructive pneumonia or calcification of mediastinal lymph nodes. 9 cases were examined by electronic bronchoscopy, 6 cases were granulation wrapped lesions, 3 cases were calculus like lesions. All the 9 patients were treated by holmium laser under the support of high flow.

Results: the operation was successful in the whole group. The operation time was 30-60 minutes, with an average of 45 minutes. During the operation, the heart rate of the patients was stable, the blood oxygen saturation was not decreased, the blood pressure was stable, the hemodynamics was stable, the patients did not complain of discomfort, there was no obvious cardiopulmonary failure and other complications. During the operation, there was no major bleeding, pneumothorax and other complications. The respiratory symptoms of all the patients were improved, and the average hospitalization time was (2.5 ± 1.4) days. 9 cases were followed up for 1 to 24 months, with an average of 6 months.

Conclusion: it is safe and feasible to use dexmedetomidine to sedate HF and to use holmium laser to treat tracheolithiasis through electronic bronchoscope, which provides a new treatment for tracheolithiasis.

PO-344

Interventional treatment of acquired subglottic stenosis in children by fiberoptic bronchoscopy.

Duan,Xiaojun、段效军
Hunan Children’s Hospital

Objective: To explore the interventional therapy and the effectiveness of fiberoptic bronchoscopy in children with acquired subglottic stenosis.

Methods: The clinical data of children who had acquired subglottic stenosis hospitalized in Hunan children's Hospital from January 2019 to November 2019 were analyzed retrospectively.. A total of 12 cases were included in this study. There were 9 boys and 3 girls with their age ranging from 26 days to 3 years and 11 month. (median age 10．8 m). According to Freitag's classification standard of central airway stenosis, the morphological classification of subglottic stenosis was carried out. Different interventional methods were chosen according to the characteristics of Freitag's morphological classification.

Results: Among the 12 cases, 11 cases were cured clinically, and the effective rate was 91.67%. Among them, 7 cases with the length of less than 1cm were treated by balloon dilation alone. Two children with subglottic stenosis more

than 1 cm in length and two children with endotracheal granulomatosis were treated by multiple interventional methods. One child with congenital heart disease and Cri-du-chat syndrome had no response to interventional therapy and could not be evacuated from the ventilator.

Conclusion: Interventional treatment of acquired subglottic stenosis in children is safe and effective. Freitag's criteria for classification of central airway stenosis can be used to guide the choice of interventional therapy and evaluate the prognosis of children with acquired subglottic stenosis.

PO-345

Successful removal of a foreign body abutting the pleural surface using hybrid bronchoscopy

Shaller,Brian、Machuzak,Michael、Gildea,Thomas
Cleveland Clinic

Objective: Background: Although most aspirated foreign bodies (FBs) are extracted via flexible bronchoscopy, bronchoscopic retrieval becomes more challenging as the FB migrates toward the lung periphery. We present a case in which a FB abutting the pleura was successfully removed using a hybrid thin bronchoscope, thereby obviating the need for operative management.

Methods: Case report – see below

Results: Case: An 80-year-old man was transferred from an outside facility after aspirating a dental drill bit. Imaging revealed a 3.5-mm-long foreign body (FB) in the left lower lobe within approximately 7 mm of the pleura (Figure 1A-B). Prior to transfer he was intubated and underwent an unsuccessful attempt at bronchoscopic retrieval. Given the FB’s location, it was determined that surgical intervention would be necessary if another such attempt were to fail. Upon arrival he underwent flexible bronchoscopy using a hybrid bronchoscope with a 4.0-mm outer diameter (BF-MP160F, Olympus, Japan) (Figure 1C), with successful localization and forceps-extraction of the FB from a distal subsegment of the left lower lobe-posterior basal segment (Figure 1D-E). The patient was extubated post-procedurally and recovered uneventfully.

Conclusion: Conclusion: The inception of bronchoscopy was predicated on our vulnerability to aspiration, with the first-ever bronchoscopy performed to extract a pork bone from the right mainstem bronchus(1). Although the majority of FB aspirations involve organic matter, inorganic aspirations in adults may occur during dental procedures(2–5). Symptoms vary depending on location and chronicity of aspiration and include respiratory distress, hemoptysis, pneumonia, pleural effusion, empyema, and pneumothorax(1, 5). Although most FBs come to rest more proximally within the tracheobronchial tree, distal migration may occur and there are case reports of FBs penetrating the pleural space(6–8). Flexible bronchoscopy is the principal means of FB-retrieval, and successful extraction using electromagnetic navigation has even been reported(9); however, rigid bronchoscopy is sometimes still utilized and, rarely, thoracotomy is required(5). Unique to our case is the depth to which the FB lodged in the bronchial tree and its proximity to the pleural surface, which placed our patient at significant risk for pleural penetration should further migration have occurred. This case highlights the ability to retrieve FBs at extreme depths within the airways using appropriate tools: the availability of a sufficiently slim hybrid bronchoscope with a working channel that could accommodate flexible forceps was essential for successful localization and extraction of this very distal FB, and helped this patient avoid surgery, which would have been the next and last course of action.

PO-346

Feasibility, Effectiveness and safety of a Novel Cryoablation of Pulmonary Tumors under Thoracoscopy (CPTT) in an Animal Model

Sun,Jiaxing、Wang,Kun、Gao,Wei、Chen,Rongzhang、Wu,Xiaodong
Shanghai East Hospital， Tongji University

Objective: Background and objective: Peripheral pulmonary nodule (PPN) is a common clinical issue nowadays and is potentially curable with early identification. Surgical resection is the major treatment at present, but it has some limitations to some extent. Percutaneous cryoablation is widely used in clinical practice, but mostly limited in late palliative treatment. In the present study, we developed a novel systematic approach called Cryoablation of Pulmonary Tumors under Thoracoscopy (CPTT) for PPN treatment and evaluated its feasibility, safety, and effectiveness in an animal model.

Methods: A preclinical study was performed on four swine under general anesthesia by tracheotomy. We designed. First, we established the PPN model by puncturing a novel modeling agent with a mixture of agarose, Omnipaque and methylene blue to the peripheral regions of lungs under the guidance of computer tomography(CT). Then, the intratracheal anchoring forceps was placed to the nodule position guided by electromagnetic navigation system under bronchoscopy. At last, the percutaneous cryoablation guided by the percutaneous electromagnetic navigation was achieved under thoracoscopy observation. We evaluated its feasibility, safety, and effectiveness with the help of CT and pathological anatomy.

Results: 1. The mean diameters of PPN by injection of 1ml and 2ml modeling agent in the lungs were 1.2cm and 1.5cm respectively; 2. Endobronchial anchoring forceps could accurately reach the focus; 3.The 3-dimensional CT reconstruction confirmed that the cryoablation locations were accurate; 4. There were no obvious complications in all 4 swine after 28 days of following-ups.

Conclusion: The novel agent can be used to establish high-quality PPN models. The cryoablation of PPN guided by electromagnetic navigation under thoracoscopy observation is safe and technically feasible.

PO-347

Application of oxygenation via nasopharyngeal tube on rigid bronchoscope intubation

Xu,Weihua、He,Haidong 、Wang,Hongwei 、 Li ,Guozheng、Lou ,Feiyan 、 Hu,Huiping

浙江省立同德医院

Objective: Rigid bronchoscope intubation needs general deep sedation and muscle relaxation. Under this condition, additional oxygen should be provided or the patient would die of apnea. Up to now, preoxygenation with 100% oxygen is usually performed to reserve oxygenation for rigid bronchoscope intubation. When preoxygenation is performed for 3 minutes, ideal oxygen saturation can be maintained for about 5 minutes. But for the patients who receive rigid bronchoscopy, this ideal oxygen saturation time is much less because most of these patients suffered from airway obstruction which weakens the effect of preoxygenation. This condition requires pulmonologists accomplish rigid bronchoscope intubation in short time or intubation should be terminated ahead of time. This research reported another experience of using nasopharyngeal tube to provide oxygenation during rigid bronchoscope intubation.

Methods: Patients who need stent implantation, stent removal, or central airway tumor ablation had been selected from March 2018 to July 2019. Patients who were severe tendency of hemorrhage, intolerance of general anesthesia, were forbidden for rigid bronchoscopy. After nasopharyngeal tube with inner diameter of 7.0 mm and length of 15.0 cm was successfully placed, ventilator was connected to the proximal terminal of nasopharyngeal tube for supplying oxygen at appropriate respiratory frequency (14 to 20 times per min) with appropriate oxygen concentration (35% to 100%) and ventilation volume (300 to 550ml). Rigid bronchoscope was then intubated. Once rigid bronchoscope intubation achieved, ventilator conduit was taken off from the nasopharyngeal tube and connected to the rigid bronchoscope. When rigid bronchoscope had not been successfully inserted into tracheal airway within 15 minutes, rigid bronchoscope intubation was terminated. Instead, tracheal intubation was performed for further operations. During the rigid bronchoscope intubation, End-tidal carbon dioxide pressure (EtCO2), oxygen saturation (SaO2), heart rate (HR), diastolic blood pressure (DBP), systolic blood pressure (SBP) were recorded every minute. Complications of nasopharyngeal tube insertion were observed.

Results: 11 patients received 12 rigid bronchoscope operations. There were three cases failed to be performed rigid bronchoscope intubation. The intubation time of other 9 cases was 3.19±1.43 minutes. The average SaO2 of 12 cases was 97.8%±1.4%. EtCO2 was 40.1±7.4 mmHg. During rigid bronchoscope intubation, HR, DBP, SBP was recorded as 80.2±10.9, 72.2±8.2 mmHg, 135.4±10.4 mmHg. Even in three failed-intubation patients, ideal oxygenation was provided in 15 min. No severe complication of nasopharyngeal tube insertion was found.

Conclusion: Oxygenation via nasopharyngeal airway was a safe and effective method for supporting oxygenation during rigid bronchoscope intubation.

PO-348

Analysis of interventional therapy for 75 cases of primary tracheal and bronchial benign tumors

Qiu,Xiaojian、Zhang,Jie、Peng,YUhan
Department of Pulmonary Diseases， Beijing Tian Tan Hospital

Objective: The aim of this article is to discuss the characteristics of primary tracheal and bronchial benign tumors in image inspection and endoscope，to summarize and analyze therapeutic effects and prognosis of interventional therapy, in order to rovide guidance for the treatment of different types of benign airway tumors.

Methods: The imaging features，endoscopic characteristics，pathologic results，interventional therapy methods，clinical interventional treatment effects and prognosis of 75 patients with tracheal and/or bronchial benign tumors were summarized and analyzed which were treated in our hospital from 2005 to 2019.

Results: The ratio of male and female patients was 2.13:1. 93.3% of imaging features showed that there were varying degrees of stenosis in trachea and/or bronchus. The major pathology type were pleomorphic adenoma(20%), also including lipoma , hamartoma , papilloma , leiomyoma , inflammatory polyps (single, in the distal bronchus), schwannomas , neurofibromas , chondroma , myoepithelioma , solitary fibroids, hemangioma , inflammatory pseudotumor. 76% lesions were located in the trachea or one main bronchus, with an average diameter of 2.18cm. Intracavitary growth accounted for 90.7%. 78.7% blocked more than 3/4 of the lumen. A total of 75 patients underwent 100 interventional therapies. During the treatment, 54% applied cyrotherapy, 42% applied high frequency electrical knife, 41% applied electric snare, and 39% applied argon knife. 94.7% of the cases reached the clinical effective standard, and 4 cases (5.3%) reached the mildly effective standard. 90% lesions were cleared by one treatment, six by two treatments, three by three treatments, one by four operations. 55 patients were followed up for long-term prognosis, among which 41 patients were followed up so far without recurrence. Four patients with papilloma had one postoperative recurrence, and one patient had five postoperative recurrences. One case of schwannoma had one postoperative recurrence. Two cases of pleomorphic adenoma recurred once, and six cases of pleomorphic adenoma presented malignant changes in long-term follow-up.

Conclusion: Imaging results can provide a certain reference for the diagnosis of benign airway tumors. Endoscopic intervention has less trauma, is easy to operate, and has less recurrence, which is the best choice for the diagnosis and treatment of most benign airway tumors. Malignant changes can be seen in some patients with pleomorphic adenoma, neurofibromas cannot be eradicated, and airway collapse is likely to occur after interventional therapy, so surgical treatment is recommended.

PO-349

Sequential unilateral bronchosopic lung volume reduction with endobronchial valves for severe emphysema: A case report in China

Liu,XinYang、Tan,Min、Liu,Yang、Song,Xiaolian、Wang,Changhui

Shanghai Tenth People's hospital

Objective: Severe emphysema comes a serious burden of disease, remains a leading cause of incidence rate and mortality. Among various therapeutic methods, bronchosopic lung volume reduction(BLVR) indicates significant clinical efficacy. It is rarely reported that after the first BLVR. The objective of this clinical case report is to explore the feasiblity, safety and benifits of sequential unilateral bronchosopic lung volume reduction.

Methods: We here report the case of 57-year old man with severe emphysema referred for bronchosopic lung volume reduction, where sequential right upper lobe BLVR and 5 years later left upper lobe BLVR.

Results: Subsequent reviews at 4 weeks post-procedure revealed the efficacy of his first lung volume reduction, approach as reflected by obvious improvement of 6MWD from 172m to 412m. The patient exhibited significant clinical improvement. The FEV1%pred increased to 30%(+15.5%), MVV%pred increased to 38.1%(+22.2%), RV decreased to 5.55L(-1.9L), RV/TLC% decreased to 69.3%(-19.2%). His chest CT scan showed atelectasis of the right upper lobe, and he had no postoperative complications. 5 years later, the patient was admitted for the same symptoms and causes again, we performed lung volume reduction on his left upper lobe after completing preoperative assessment and informed consent. At 4-week follow-up, showed the efficacy by significant improvement of mMRC score from 4 to 3, CAT score from 32 to 25, SGRQ score from 34 to 37, 6MWD from 153m to 270m. The FEV1%pred increased to 25.2%(+7.8%), MVV%pred from unmeasurable to 23.9%, RV decreased to 6.4L(-1.21L), RV/TLC% decreased to 75.1%(-9.5%). At 8 months, the lung physiological measures all reflect decreased physiological function of the lungs , but are superior to the preoperative data. His mMRC score is 2, CAT score is 22, SGRQ score is 25, 6MWD is 290m. The FEV1%pred is 21.8%, MVV%pred is 21.4%, RV is 7.71L, RV/TLC% is 71.5%. His chest CT and pulmonary perfusion scan was improved. There were no postoperative complications.

Conclusion: Bronchoscopic lung volume reduction (BLVR) has been recognized to have definite effects and acceptable safety profile. Key predictors of efficacy include the degree of heterogeneity between the targeted treated and un-treated lung segments and the degree of hyperinflation, the presence or absence of collateral ventilation. The selection of target area and patient tolerance are factors that can not be ignored. In our study, we have refined the preoperative assessment to select the right patient. Nevertheless, the first volume reduction will still lose efficacy due to exposure factors. The second volume reduction showed good results, but we do not know whether the second BLVR will affect the first BLVR. A study have shown that repeated BLVR does not change the natural development of emphysema, but fails to obtain the benefits of the first BLVR and "resets" the existing emphysema, it is consistent with this case. The patient did not develop complications, but it is still necessary to be vigilant for the occurrence of complications and to observe the long-term efficacy. In terms of the current follow-up results, Sequential unilateral bronchosopic lung volume reduction with endobronchial valves is safe, feasible and sustainable.

PO-350

A review of virtual-assisted lung mapping (VAL-MAP) in a single institution

Nishida,Tomoki、Fukai,Ryuta
Shonan Kamakura General Hospital

Objective: Recently, following popularization of video-assisted thoracic surgery, sub-lobar resections for non-palpable small lung lesions during the peri-operative period have increased. In our institution, virtual-assisted lung mapping (VAL-MAP) was introduced in 2015. VAL-MAP involves multi-spot dye-marking around the target lesion using bronchoscopy with virtual images. Herein we have reviewed this technique retrospectively.

Methods: Fifty-eight patients provided 62 lesions in this study. The patients underwent VAL-MAP between January and December 2018. The success of sub-lobar resection with VAL-MAP was defined as a resection margin greater than the diameter of the lesion if < 20 mm or > 20 mm if the diameter of the lesion was > 20 mm. We assessed several factors relative to VAL-MAP.

Results: The mean size of the lesions was 13.0±6.5 mm. All target lesions were resected completely. Thirty-three patients underwent wedge resections, 23 patients underwent segmentectomies, and 2 patients underwent lobectomies that were converted from sub-lobar resections because of inadequate resection margins. The execution rate of planned dye-marking was 97.9% and the peri-operative identification rate of marking was 91.0%. Complications caused by VAL-MAP included the formation of two new bullae and one mild pneumothorax that did not require an additional procedure. The pathologic diagnoses were 36 primary lung cancers, 20 metastatic lung cancers, and 6 inflammatory nodules. Five patients with inadequate resection margins underwent VAL-MAP during the first half of the study. The success rate of surgery was 91.4%.

Conclusion: We consider VAL-MAP to be a useful technique for resection of small lung lesions. VAL-MAP is a safe procedure compared with other marking techniques to localize lung lesions. Moreover, the results demonstrated reproducibility of VAL-MAP compared with a previous multi-center study conducted in Japan.

PO-351

Endobronchial Ultrasound and Electromagnetic Navigational Guided Cryobiopsy in Peripheral Pulmonary Nodule: A Case Report

Liao,Huai、Guo,Yubiao、Xie,Canmao
First Affiliated Hospital of Sun Yat-sen University

Objective: Bronchoscopic biopsy of peripheral pulmonary nodules of less than 10mm has proven to be difficult. Previous studies have indicated that cryobiopsy may aid in the diagnosis of peripheral pulmonary lesions.

Methods: We report here the use of endobronchial ultrasound and electromagnetic navigational guided cryobiopsy to diagnose the peripheral pulmonary nodule of less than 10mm in a 55-year-old woman.

Results: A definitive diagnosis was made in this case. There were no complications during the procures.

Conclusion: Endobronchial ultrasound and electromagnetic navigational guided cryobiopsy has successfully diagnosed the peripheral pulmonary nodule of less than 10mm in our case. We continue to expplore its use in biopsy of peripheral pulmonary nodules.

PO-352

Animal study of methylene blue fibrin composite gel as a preoperative localization agent for pulmonary nodules

Lin,Hongsheng
Quanzhou No.1 Hospital

Objective: To explore the clinical value of methylene blue fibrin complex gel as a preoperative localization agent for pulmonary micronodules, and to provide a basis for accurate location of pulmonary micronodules before operation.

Methods: 1. Fibrin gel and methylene blue fibrin gel were separately constructed, and the release of each group of gels in a 37 ° C water bath was observed. 2. Twenty healthy New Zealand rabbits were divided into groups I, II, IIIa, IIIb and IIIc, with 5 in each group. Methylene blue fibrin gel was injected into the right upper lobe, and each of Group I and Group II New Zealand rabbits were sacrificed on days 1, 2, 3, 4, and 5 of the injection of methylene blue fibrin complex gel. Five rabbits of IIIa, IIIb, and IIIc New Zealand rabbits were sacrificed at 1, 2, and 3 hours after injection of methylene blue. Pathological specimens of lungs were obtained, stained with HE, and pathological changes were observed under microscope [1].

Results: 1. In the whole preparation process of the gel, the time required for each group to form a fibrin gel is between 40-60 s, and the addition of methylene blue does not affect the gel formation time. 2. Group I and II New Zealand rabbits were dissected on each of the two groups of New Zealand rabbits on the 1st, 2nd, 3rd, 4th and 5th day after percutaneous injection of the methylene blue fibrin gel mixture. The lungs were visible to the naked eye when the lung specimens were taken. The focal blue gel freezes one section, and as time passes, the diameter gradually decreases until it disappears completely on the fifth day. In the first and second hours after the injection of methylene blue, the New Zealand rabbits in the IIIa and IIIb groups were killed, and the methylene blue was widely spread in the lung tissues. In the third hour after the injection, the New Zealand rabbits in the IIIc group were seen. The blue is completely absorbed.

Conclusion: 1. Methylene blue does not affect the release rate of fibrin gel release system; 2. The methylene blue fibrin gel mixture is a safe and stable marker for small nodules in the lungs.

PO-353

Six cases of soft bronchoscopy frozen lung biopsy under local anesthesia

Zhang,Dexin、Yang,Shuanying、Zhang,Jie、Xie,Mei、Zhang,Yonghong
Department of Respiratory Medicine, Second Affiliated Hospital of Medical College, Xi' an Jiaotong University

Objective: To observe the effectiveness and safety of soft bronchoscopy frozen lung biopsy under local anesthesia.

Methods: Six patients with diffuse lung lesions or local interstitial lesions on CT examination of the lung between January 2019 and March 2019 were selected in the Department of Respiratory and Critical Care Medicine, the Second Affiliated Hospital of Xi'an Jiaotong University The results were not satisfactory after anti-inflammatory treatment. There were 5 males and 1 female; aged 51 to 77 years. All patient selections were selected according to expert consensus criteria. After the local anesthesia was performed through the cyclomembrane puncture, the cryoprobe was inserted into the predetermined bronchus through the biopsy channel. After encountering resistance, the cryoprobe was

retracted by about 2 cm, and the cryotherapy device was activated. After 5-6 seconds, the cryoprobe and trachea remove the microscope together, and thaw the probe for a few seconds to obtain tissue. Quickly insert another bronchoscope during the thawing period, observe whether there is bleeding and give corresponding treatment. The taken specimen was fixed in 4% formalin.

Results: Cryobiopsy was successfully performed in 6 cases. The biopsy was performed on different lung lobes. There were 2 cases of right upper lobe, 1 case of right lower lobe, 2 cases of left upper lobe, and 1 case of left tongue lobe. One patient was diagnosed with lung adenocarcinoma, one with mucinous adenocarcinoma, one with invasive adenocarcinoma, one with pneumoconiosis, and two with chronic inflammation. There were 2 cases of grade 0 bleeding, 4 cases of grade 1 bleeding, and no grade 2 or more bleeding; 4 cases of pneumothorax occurred, of which 1 patient was given closed chest drainage and 1 patient was punctured with a thoracentesis. No other pneumothorax occurred. No complications such as mediastinal emphysema, subcutaneous emphysema, postoperative infection, and acute exacerbation occurred.

Conclusion: Frozen lung biopsy is a highly effective diagnostic method. Patients with diffuse lung disease or local diffuse disease are the main indications. The positive rate was significantly higher than that of other interventional methods. In terms of complications, pneumothorax and bleeding may be the most important complications, but pneumothorax may be more likely than bleeding. In order to reduce the occurrence of complications, strict control of the indications and contraindications of patients is the most important factor to reduce the occurrence of complications.

PO-354

The value of ultrasound image of radial ultrasound bronchoscope in the diagnosis of benign and malignant lung diseases

Fang,Yukun、Song,Jia、Li,Yu、Wang,Jian、Chen,Qingyong
The PLA 117 hospital

Objective: To explore the value of ultrasound image of EBUS-GS in the diagnosis of benign and malignant lung diseases.

Methods: The clinical data and examination results of 174 patients with EBUS-GS from January 2018 to June 2019 in 903 Hospital of PLA were analyzed retrospectively, and the application value of ultrasound image of radial ultrasound bronchoscope for benign and malignant lung lesions was analyzed.

Results: Among the 154 patients who underwent EBUS-GS examination in 903 Hospital of the PLA, 96 were benign lesions and 54 were malignant lesions. According to the gold standard of pathological diagnosis, the positive rate of ultrasound diagnosis of EBUS-GS was 81.33%, the consistent rate with pathological diagnosis was 80.52%, the sensitivity was 90.48%, the specificity was 29.23%, the benign predictive value was 80%, and the malignant predictive value was 85.19%. In addition, the malignant ultrasound images of EBUS-GS under bronchoscope are mostly irregular, the boundary is not clear and discontinuous, the echo is basically uniform, the interior is mostly low echo, a few gas containing echo images will appear point line and concentric circle. However, most of the benign images are regular (mainly round or oval), with clear and continuous boundary, most of the echoes are uneven, and most of the internal hyperechoic images are dotted, linear and concentric. The characteristics of radial ultrasound have a certain value in predicting lung malignant diseases, and the difference is statistically significant ($P < 0.05$).

Conclusion: The ultrasound image of EBUS-GS has a certain reference value for the diagnosis of benign and malignant lung diseases, which is helpful for the preliminary evaluation of benign and malignant lung diseases, and can provide a new basis for the early clinical diagnosis in the future.

PO-355

Report of 2 cases of allergic bronchopulmonary aspergillosis and literature review

Hu,Zhimin、Jin,Qiusheng、胡志敏
Wuhan Pulmonary Hospital

Objective: To review the clinical data of two patients with allergic bronchopulmonary aspergillosis (ABPA) and to review the literature so as to improve the understanding of the disease and reduce misdiagnosis and missed diagnosis.

Methods: Collecting and collating the medical history data, laboratory examinations, imaging examinations, bronchoscopic findings, histopathological findings of the two patients, and comparing the latest diagnostic criteria of allergic bronchial aspergillosis and reviewing the literature.

Results: The clinical symptoms of allergic bronchopulmonary aspergillosis were easily confused with asthma, tuberculosis and lung cancer. The imaging manifestations are varied, the early lung shadow is migratory, and the middle and late stages of "central bronchiectasis" have more characteristic changes. Bronchoscopic mucus embolism is common. Eosinophils in peripheral blood increased. The necessary conditions for diagnosis included two items: the increase of serum speci_ C IgE (sIgE) level (>0.35 kUA/L) or the positive rate of Aspergillus fumigatus skin test, and the increase of serum total IgE level (>1 000 U/mL). It is usually difficult to obtain positive results from etiology.

Conclusion: The diagnostic criteria of allergic bronchopulmonary aspergillosis are constantly improved and revised. Medical workers need to improve their understanding of allergic bronchopulmonary aspergillosis and reduce misdiagnosis and missed diagnosis.

PO-356

Balloon Dilatation therapy via rigid bronchoscopy in four infants with congenital tracheobronchial stenosis difficulty in weaning ventilation

Zheng,Yangming1、Ye,Leping2、Zhang,Hailin1、Guang fa,Wang3
1. The Second Affiliated Hospital and Yuying Children’s Hospital of Wenzhou Medical University
2. Peking University first Hospital Obstetrics and Obstetrics Hospital
3. Peking University first Hospital

Objective: congenital tracheobronchial stenosis(CTBS) is extremely rare but life-threatening disease. In most cases, patients were characterized by the presence of complete tracheal or bronchial cartilage rings resulting in lumen narrowing. We described four cases of CTBS with ventilatory insufficiency despite invasive mechanical ventilation. Aim of this report was to evaluate usefulness of Balloon dilatation in treatment of tracheobronchial stenosis.

Methods: Medical records of infants with CTBS in our institution between 2017 and 2020 were retrospectively analyzed.

Results: A total of 4 infants were diagnosed with CTBS in our institution including 3 males and 1 female. The median age was 3 months (range 1-4 months) and the median weight was 5.2 kg (range 3.8-7 kg) at the time of Balloon dilatation. Of the 4 patients, 1 had short segment tracheal stenosis involving the upper trachea, 1 had stenosis in the lower trachea, 1 had stenosis in the left main bronchus and concurred occlusion of the right main bronchus and lung hypoplasia, and 1 had stenosis and malacia involving the lower trachea and bilateral main bronchi. Infants with CTBS often coexists with other anomalies. Patients had various congenital cardiovascular anomalies including atrial septal defect, pulmonary artery sling, ventricular septal defect, patent ductus arteriosus. Pulmonary valve stenosis, double

outlet right ventricle. 1 had hemivertebra deformity. 1 had gastroschisis. Failure in ventilator weaning was a leading clinical feature in all patients. 1patients presented with difficulty in passing endotracheal tube. Tracheobronchography and computed tomography identified CTBS in all 4 patients. Patients remained intubated and suffered from frequent ventilatory insufficiency for 33 to 96 days. Balloon dilatation were performed by angioplasty balloon catheter passing through rigid tube. 3 patient acquired immediate ventilatory improvement with peak inspiratory pressure dropping after balloon dilatation. These patients remained intubated for 7 to 24 days and finally succeeded in weaning ventilation. 1patient had no improvement in ventilation and failed to wean off ventilator after dilatation. Her parent finally abandoned treatment.

Conclusion: CTBS often coexists with other anomalies including cardiovascular anomalies. Failure in ventilator weaning and frequent ventilatory insufficiency is a leading clinical feature in these patients. Balloon dilatation is potentially effective treatment for CTBS with unstable ventilatory status despite invasive mechanical ventilation. Balloon dilatation may be a initial option of treatment in CTBS as a less invasive procedure than surgical tracheoplasty.

PO-357

Primary tracheal papilloma disguised as asthma: a case report

Chen,Yanbin、Jiang,Junhong、Guo,Lingchuan、Huang,Jianan、Yanbin Chen
苏州大学附属第一医院

Objective: Tracheal papilloma presenting as asthma is a rare occurrence

Methods: We report a case of a 32-year-old male patient who presented with features of central airway obstruction partially. Flexible bronchoscopy demonstrated a large growth arising from the lower end of the trachea. Successful treatment using snare loop and argon plasma coagulation (APC) of the polypoidal growth was performed via flexible bronchoscope.

Results: The patient had immediate relief of airway obstruction and histopathological examination of the neoplasm demonstrated features of papilloma.

Conclusion: Primary tracheal papilloma is mimicker of asthma, CT scan should be considered in patients with persistent chronic cough, or stridor. Endoscopic papillectomy is a safe and effective treatment and should be considered as first-line therapy for tracheal papilloma.

PO-358

Bronchoscopic lung volume reduction in the treatment of pulmonary bullae: A review

Guo,Zhifeng、Zeng,Yiming
The Second Affiliated Hospital of Fujian Medical University

Objective: By reviewing the literature about bronchoscopic lung volume reduction in the treatment of pulmonary bullae, the advantages and disadvantages of different bronchoscopic lung volume reduction in the treatment of pulmonary bullae were summarized, and the selection of different types of pulmonary bullae bronchoscopic lung volume reduction were summarized.

Methods: PubMed database is used to search the literature about bronchoscopic lung volume reduction for the treatment of pulmonary bullae at home and abroad in the past 10 years, and the literature is analyzed, summarized.

Results: The wall of the pulmonary bullae is very thin and consists of flat epithelial cells of the alveoli, and it may only be a fibrous membrane. According to the pathological morphology, the pulmonary bullae were divided into three types. At present, the treatment of pulmonary bullae can be divided into two categories: internal medicine and surgery. The available surgical interventions include lung volume reduction surgery, pneumonectomy and lung transplantation. The main method for the treatment of pulmonary bullae in internal medicine is bronchoscopic lung volume reduction. At present, the commonly used methods are endobronchial one-way valve treatment and endobronchial coil treatment, bronchial plug treatment. Different methods of bronchoscopic lung volume reduction have their own advantages and disadvantages, and the therapeutic effects are not the same.

Conclusion: According to different types of patients with pulmonary bullae and the degree of tolerance, different methods of bronchoscopic lung volume reduction can be selected.

PO-359
Ring sling complex in a 53 year-old woman

HANNA,Amir、LA ROSA,Ambre、AMSALEM ,Myriam、CRUTU,Adrian 、FADEL,Elie
Marie Lannelongue Hospital

Objective: We report a rare case of ring sling complex. A 53 year old woman treated since childhood for a progressive severe asthma. CT Angiography showed left pulmonary artery arising from the right pulmonary artery, running between the trachea and the esophagus with tracheal stenosis in consequence. She had a 50% stenosis of the inferior third of the trachea with undeveloped posterior membranous part. Surgical management with reimplantation of the left pulmonary artery into the main pulmonary trunk and end-to-end tracheal anastomosis.

Methods: Surgical repair by reimplantation of the LPA into the pulmonary trunk associated with resection of the tracheal stenosis along 5 rings followed by end-to-end anastomosis (running posterior suture and interrupted anterior suture using 3-0 PDS) through a median sternotomy under cardiopulmonary bypass without aortic clamping to facilitate PA anastomosis (37 minutes).

Results: Post-operative follow up performed at three months showed marked clinical improvement, improved dyspnea NYHA class I. Follow up bronchoscopy showed satisfactory tracheal anastomosis and computed tomography angiography eliminated pulmonary artery stenosis.

Conclusion: Left pulmonary artery sling complex is a rare congenital disease, associated with long segment tracheal stenosis known as ring-sling complex, typically diagnosed in the first year of life owing to airway obstruction leading to severe neonatal respiratory distress. Symptoms are often long standing dyspnea, mimicking asthma. Surgical repair by reimplanting the left pulmonary artery into the main pulmonary artery trunk with repair of associated tracheal stenosis should be proposed whenever possible in expert centers.

PO-360

Surgical and functional outcomes following resection of benign laryngotracheal stenosis

HANNA,Amir、NAUTA,Anapa、MITILIAN,Delphine、CRUTU,Adrian、MERCIER,Olaf、FADEL,Elie
Marie Lannelongue Hospital

Objective: Laryngotracheal resection provides good to excellent technical surgical results in the management of benign subglottic laryngotracheal stenosis (BSLTS). In this study, we retrospectively reviewed our recent cohort of patients with a specific focus on surgical and functional outcomes.

Methods: We evaluated all patients operated for BSLTS, between January 2007 and November 2018. Preoperative computed tomography scanners and flexible bronchoscopy categorized the severity of narrowing. Post-operative assessment was conducted by routine flexible bronchoscopy at day 1 and 7, routine clinical and endoscopic evaluation at 1 month, and if necessary at 3 and 6 months. We analyzed 30-day mortality, overall complications and success rates. Late surgical outcomes included restenosis and mortality. Functional outcomes and quality of life were assessed by (standardized) questionnaires (Visual Analogic Scale (VAS) and modified Medical Research Council for dyspnea, VAS for swallowing, Voice Handicap index (VHI)).

Results: Of the 194 patients who underwent tracheal surgery, 43 were operated for benign laryngotracheal stenosis: 28 with a "modified Pearson technique" and 15 with "Grillo's intervention". A laryngeal release was performed in 15 cases (32%). Thirty-day death, overall complications and success rates were 0%, 44%, and 95%, respectively. Latesurgical outcome data (mean follow-up 53 months) were available for 38 patients (88%). There were 7 (18%) restenoses and 36 (95%)late surgical successes. Thirty-four patients (79%) responded to functional questionnaires. There was a significant diminution of mean postoperative dyspnea VAS scores during rest (-5.4 (±4.2)) and activity (-5.6 (±4.8)) ($p<0.001$), and a trend toward decreased mMRC grade after surgery ($p=0.057$) (65% postoperative grade 0). According to VHI scores, 30 patients (88%) had no to moderate voice impairment and 4 (12%) experienced severe impairment. There was no significative differences between pre- and post-operative dysphagia VAS scores. Finally, 85% of patients (n=29) felt an improvement in their quality of life. Improved quality of life was significantly associated with: lower post-operative dyspnea VAS score during rest ($p<0.01$) and exercise ($p<0.01$); lower mMRC grade ($p=0.012$) and lower VHI score ($p=0.01$).

Conclusion: In the management of BSLTS, laryngotracheal resection with primary end-to-end anastomosis is not only safe but provides excellent surgical and functional outcomes leading to improvement in quality of life. This procedure should be considered as the best curative treatment for BSLTS.

PO-361

Retrospective analysis of 51 cases of esophageal cancer complicated with malignant tracheoesophageal fistula

Xu,Xiaoyi1、Zhong,Zhicheng2、Li,Jing3、Huang,Pei3
1. Shantou University Medical College
2. Shenzhen University General Hospital
3. Guangdong Provincial People's Hospital

Objective: Malignant tracheoesophageal fistula (mTEF) is a complication of primary tumor growth or recurrence of esophageal or lung carcinoma, resulting in poor survival and quality of life. Esophageal cancer (EC)-associated mortality is common due to malnutrition, repeated aspiration, and severe infection, with a mean survival duration of 2 to 4 months. The aim of this study was to investigate the effects of different clinical characteristics and treatment regimens on the prognosis of mTEF secondary to esophageal cancer.

Methods: The clinical data of 51 patients with EC complicated with mTEF who received treatment in Guangdong Provincial People’s Hospital from 2007 to 2017 were analyzed. They were assigned to three groups according to the treatment regimen: a tradition medical (TM) group, an esophageal intervention (EI) treatment group and an airway intervention (AI) treatment group.

Results: Among 51 patients, 22 of them received TM treatment, 13 received AI treatment, and 16 received EI treatment. Overall, the median survival duration was 87 days (TM group, 42 days; AI group, 108 days; EI group, 104 days) and the mean survival duration was 130.1 days (TM group, 88.1 days; AI group, 153.5 days; EI group, 166.1 days). Cox regression analyses revealed that the treatment regimen was an independent risk factor predictive of increased survival within 1 month after treatment and most symptoms were relieved in the EI and TI groups.

Conclusion: Interventional treatment of the esophagus and airway is an effective approach to improve symptoms and increase short-term survival.

PO-362

A case of bronchial Dieulafoy's disease

Mai,Zhitao、Wan,Sanzhi、Di,Qingguo
cangzhou centl hospital

Objective: Review the bronchual Dieulafoy's disease through case report
Methods: case report

Results: In this case, we had a bronchoscopic biopsy that resulted in massive bleeding. The case was considered as Dieulafoy's disease. Hemostasis was treated under the microscope. Clinically, this disease often causes life-threatening bleeding. For unknown bleeding and bronchoscopic nodular lesions, biopsy should be careful.

Conclusion: The differential diagnosis of hemoptysis should always include Dieulafoy's disease. For patients with unknown causes of hemoptysis, although chest imaging is normal, this disease should be considered. It is necessary to be careful when biopsy the unknown nodules under tracheoscope, which may cause massive hemorrhage. Angiography or EBUS can be used for diagnosis. In treatment, conservative treatment is usually ineffective, requiring bronchial artery embolization, and some patients may need surgical resection of the focus.

PO-363

The diagnostic value of radial endobronchial ultrasound-guided transbronchial lung biopsy with guide sheath in 11 cases of pulmonary cryptococcosis

Guan,Shuhong、Zhang,Sujuan、Zhou,Jun、Zhang,Qiudi、Xu,Qianqian、Xu,Xiong、Yan,Tingzan
The First People's Hospital of Changzhou

Objective: To evaluate the diagnostic value of radial endobronchial ultrasound-guided transbronchial lung biopsy with guide sheath（rEBUS-GS-TBLB） for pulmonary cryptococcosis(PC).

Methods: Patients diagnosed with PC at the Third Affiliated Hospital of Soochow University from January 2015 to May 2019 were collected, among which the rEBUS-GS-TBLB cases were selected. Clinical characteristics, positive rate of rEBUS-GS-TBLB diagnosis of PC and operational complications were retrospectively analyzed.

Results: 20 cases of PC were diagnosed in our hospital from January 2015 to May 2019, 11 of which had received rEBUS-GS-TBLB examination. Among the 11 patients, 7 were male and 4 were female, aged 32-71 years, with an average age of 54.5 years. All patients had no history of HIV infection. The clinical symptoms were not specific, and chest CT showed nodule, mass and consolidation, and 9 cases had air bronchogram. All the 11 patients were detected by ultrasound and biopsied successfully, without severe complications such as massive hemoptysis and pneumothorax. Among the 11 patients, 7 cases of pulmonary cryptococcosis were pathologically diagnosed by rEBUS-GS-TBLB, with a positive rate of 63.6% (7/11),1 case was also stained with ink of alveolar lavage fluid, and cryptococcus was found. There was no evidence of PC in the pathology of the other 4 cases.

Conclusion: rEBUS–GS–TBLB has a high positive rate for PC diagnosis, with few complications, and is safe and reliable.

PO-364

Development and preliminary application of rapamycin-coated airway stents

Han,Xinwei、Li,Zongming、Zhang,Quanhui、Jiao,Dechao、Ren,Kewei、Lu,Huibin
The First Affiliated Hospital of Zhengzhou University

Objective: To investigate the effectiveness of rapamycin coated tracheal stent in inhibiting granulation tissue proliferation in tracheal stenosis animal models.

Methods: Thirty-six New Zealand white rabbits (2.5-3.0 kg) were selected and divided into control group (n=18) and experimental group (n=18), the bare nickel-titanium alloy stents and rapamycin-coated bare nickel-titanium alloy stents were implanted respectively. According to the time of execution, each group was divided into 1 month group, 2 months group and 3 months group, with 6 rabbits in each group. Tracheotomy combined with brush destroying mucosa was used to make animal model of tracheal stenosis. Thirty-six bare nickel-titanium alloy scaffolds, 18 of which were dipped with rapamycin coatings supported on PLGA. The tracheal stent was implanted under fluoroscopy. The tracheal stenosis was observed by chest CT in 1 month, 2 months and 3 months after stent implantation before execution. The specimens were taken from the upper and lower ends of stent for HE staining and pathological examination to compare the tracheal mucosal hyperplasia of the two groups.

Results: During the process of making tracheal stenosis model, one died of too deep anesthesia, two died of severe tracheal mucosal congestion and edema three days after making the model. The other 33 tracheal stenosis models were successfully made, and three more were successful, with the degree of stenosis ranging from 50% to 85%. All

tracheal stenosis models were successfully implanted with tracheal stents at one time. Chest CT scans at 1 month, 2 months and 3 months after operation showed that there were different degrees of granulation tissue proliferation in the upper and lower edges of the stent in the control group. The average stenosis degree at the upper edge of the stent was (81.6 +2.8)%, (66.4 +1.6)% and (78.2 +2.3)% respectively. In the experimental group, the proliferation of granulation tissue was significantly lighter, and the average degree of stenosis at the most narrow sites were (61.68 (+2.3)%, (45.23 (+4.5)% and (50.97 (+3.8)% respectively. Pathological examination showed that the degree of cellulose proliferation and collagen deposition in the drug-coated stent group was slightly lower than that in the control group.

Conclusion: Rapamycin coating can effectively inhibit the proliferation of granulation tissue and reduce the degree of restenosis after stent implantation.

PO-365

Therapeutic effect of Y-shaped single-plugged covered metal airway stent on right bronchopleural fistula

Han,Xinwei、Li,Zongming、Jiao,Dechao、Lu,Huibin、Ren,Kewei
The First Affiliated Hospital of Zhengzhou University

Objective: To determine the feasibility and efficacy of using Y-shaped single-plugged covered metal stents to treat right bronchopleural fistulas.

Methods: We designed the Y-shaped single-plugged covered metallic airway stent to fit the specific anatomy of the right main bronchus. The stent had a main stem and two branches, resembling an inverted "Y". One of the branches was closed (plugged) and bullet-shaped; the other was tubular and open. The entire stent was encased in a nitinol wire mesh. Stent size was individualized using spiral CT measurements of the airway. Under fluoroscopic guidance, we implanted 28 Y-shaped stents in 28 patients who had right bronchopleural fistulas.

Results: Stent insertion was successful in all patients. All fistulas were successfully closed immediately after stent placement. Follow-up was performed for 3–34 months. Positive clinical outcomes were seen in 25 of 28 patients. Three patients died of intractable pulmonary infection and multiorgan failure. The fistula completely healed and the stent could be removed in 15 patients; however, two of them were left with a small, aseptic, residual right lung cavity. The remaining 11 patients are still alive with the stent in situ.

Conclusion: The placement of Y-shaped single-plugged covered metal airway stents seems to be a feasible and safe method for the treatment of bronchopleural fistulas involving the right main bronchus. This stent is a promising therapeutic alternative for bronchopleural fistulas involving the right main bronchus.

PO-366

Ultrasound-guided percutaneous pleural lesion and marginal pulmonary mass biopsy

Zhang,Hua1、Lei,ZhiKai1,2、张骅
1. Department of Respiratory and Critical care Medicine， Heping li Hospital， Beijing
2. Ultrasound imaging department， Hangzhou First People's Hospital

Objective： Ultrasound-guided percutaneous pleural lesion and marginal pulmonary mass biopsy

Methods： Ultrasound-guided

Results： For the puncture of pleural lesions, the superficial high-frequency probe should be selected, because it can show the tissue structure of the chest wall more clearly.During the puncture, the biopsy needle should be as close as possible to the pleura in a parallel state, and the maximum oblique section should be taken as far as possible to increase the sample volume, reduce the number of needle insertion, and reduce the risk of bleeding. In terms of range, a range of 10mm should be selected for such small nodules close to the pleura (estimated diameter not exceeding 10mm) to avoid damage to lung tissue.

Conclusion： Ultrasound-guided percutaneous pleural biopsy is a simple, safe and less invasive method, which is the most widely used method in clinic. However, in the pleural puncture biopsy, the biopsy gun is also easy to go through the pleura to damage the lung and cause pneumothorax. Therefore, the probe selection should be careful, for patients with small lesions, not thick chest wall and non-obese patients. The superficial high-frequency ultrasonic probe is better than the abdominal low-frequency probe, with high resolution. It should also be cautious for the choice of the biopsy gun. For small lesions and the lack of safe distance, semi-automatic biopsy gun can be chosen. Because semi-automatic biopsy gun is supposed to arrive advanced to the farthest margin of the lesion before puncturing materials. That is to say, the tip of the needle actually reached the farthest end of the puncture when taking samples. Compared with acquiring materials via the full-automatic biopsy gun, which quickly entered the preset distance, it was safer and controllable, moreover, can avoid the occurrence of pneumothorax and other complications. Patients should hold their breath during the puncture operation of pleural lesions, to reduce the damage to the lungs caused by the tip of the needle due to the interference of lung gas.

PO-367

A case of tracheo-innominate artery Pseudodissected aneurysm successfully treated with endovascular stent of the innominate artery

Su,Nan、Chen,Cheng、Chen,Yanbin、Zhu,Yehan、Lei,Wei、Ning,Weiwei、Wang,Xiaofei、Zhang,Xiaohui、Wang,Jiajia、Liu,Chao、Huang,Jianan
The First Affiliated Hospital of Soochow University

Objective: To investigate the causes of airway hemoptysis caused by pseudodissecting aneurysms of trachea-nameless artery and the corresponding treatment methods.

Methods: A 63 years old patient in a coma after a car accident, was gave a tracheotomy. two months later, the patient was considered to remove the tracheostomy tube. While she has a massive hemoptysis about 2000 ml in the process of pulling tube. Surgical exploration found that anonymous artery and right carotid artery is rupture, so she was gave a endovascular stent of the innominate artery and right carotid artery, the postoperative recovered well, incision healing, and oral warfarin 2.5 mg/day for a long time. Two months later, the patient began to appear intermittent hemoptysis, initial quantity about 1-2 ml/day, the chest CT examination showed that both lungs only had patchy exudation. The CTA inspection on neck and chest did not see obvious vascular malformation and active bleeding, so she received a bronchoscope examination. We found a newborn granulation tissue at the tracheotomy, there were lots of visible blood and thrombus under the two lungs, we could not see active bleeding after completely clean up. After 1 week, tracheoscopy was performed again, and the granulation tissue was significantly larger than before, and the trachea was blocked locally. Therefore, the neoplasm was removed with APC, freezing and biopsy, no bleeding was observed during surgery. But she appear haemoptysis again about 100 ml 2 days later, and 200ml 4 days later. At last, she was gave a DSA (Digital Substraction Angiography) examination, we could find that the bronchial arterys were fine, there was no abnormalities and active bleeding, but the aortic arch angiography showed a phenomenon of bleeding shot at the innominate artery with a endovascular stent, just like a pseudo dissecting aneurysm, the aneurysm is just located at the tracheostomy granulation of the rear, We believed that this pseudoaneurysm was the source of bleeding, and therefore decided to give her another endovascular stent to block off the hemorrhagic spot.

Results: after a new endovascular stent was imbedded at innominate artery, there was no any bleeding.

Conclusion: tracheo-innominate artery Pseudodissected aneurysm is rare, and DSA examination is a good way to find the cause of bleeding, and interventional therapy is a good solution.

PO-368

Intratracheal triamcinolone therapy for post stent granulation

Guliani,Abhinav、Dhamija,Amit、Basu,Arup
Sir Ganga Ram Hosital

Objective: Post stent granulation tissue is a common complication especially at the ends of the stent. It is seen more with metallic stents and requires periodic debulking and dilatation. Triamcinolone acetonide is widely used by various specialities to decrease fibrosis locally. We present its potential use in the trachea.

Methods: 17 year old female initially presented to our hospital with severe progressive respiratory distress with stridor and was found to have a peritracheal mass compressing the trachea and main bronchi. She was initially managed with a Y shaped SEMS to establish airway and allay symptoms. She had mediastinal fibrosis on biopsy and was initiated on steroids with which she improved and the lesion decreased on a subsequent scan 3 months later. Y stent was removed

and underlying trachea showed excessive granulation tissue with critical stenosis of around 7mm in the proximal trachea starting just below the cords. Lower trachea and main bronchi were normal. To establish airway patency balloon dilatation was done followed by SEMS placement(size 4cmX10mm). Oral steroids were continued(Dexamethasone 2mg/day). She developed significant side effects with moon like facies, weight gain (25kg), abdominal striae. Despite this her upper tracheal granulation tissue persisted which continued to cause significant narrowing of the airway and respiratory distress. Stent removal failed after keeping stent in position for nearly 8 weeks requiring re-dilatation and re-stenting. We injected Triamcinolone acetonide(40mg/ml) 0.2ml (8mg) each into the narrowest part of the stenosed segment along four points at 12, 3, 6 & 9 ‘o clock positions using an endoscopic injector after balloon dilatation and stent removal. Video will be presented.

Results: Her dexamethasone has now been tapered off after 3 months of the procedure with no increase in symptoms/stridor. She is able to carry out daily activities with no dyspnea.

Conclusion: Metallic stent may cause airway irritation and persistent inflammation leading to non resolution of granulation tissue akin to keloid. Local Triamcinolone may be helpful as a therapy for chronic inflammation leading to tracheal stenosis.

PO-369

Diagnostic value of rigid transbronchial lung cryobiopsy in interstitial lung disease

Yu,Min、Zhao,Qi、Dai,Jing hong、Li,Rui、Li,Yan、Gao,Yu juan、Yan,Xin、Ding ,Jing jing、Meng ,Fan qing、Cai,Hou rong
The Affiliated Drum Tower Hospital of Nanjing University Medical School

Objective: To evaluate the efficacy and safety of rigid bronchoscopy lung cryobiopsy (TBCB) for the diagnosis of interstitial lung disease.

Methods: 33 patients with interstitial lung disease admitted to the Affiliated Drum Tower Hospital of Nanjing University Medical College from December 2017 to December 2018 underwent TBCB. The classifications of interstitial lung disease were identified combing with clinical characteristics, physical examination and chest high-resolution CT scan. The complications intra and post of the operation were observed.

Results: 33 patients underwent rigid transbronchial lung cryobiopsy successfully: 18 patients received the operation in the anesthesia operating room under x-ray guidance. The average operation time was 46.9±17.0 min. the average biopsy number was 4.2±1.1, the average specimen size was 9.7±3.4mm2; 15 patients received the operation in bronchoscopy room without any guidance, the average operation time was 25.7±4.6 min. the average biopsy number was 5.1±1.1, the average specimen size was 8.2±3.1mm2. The overall diagnostic yield was 81.8%(27/33). All the patients underwent balloon sealing to prevent hemorrhage, and no serious hemorrhage occurred. The incidence ratio of pneumothorax was 12.1%(4/33), and all the 4 patients were able to heal spontaneously. There is no statistics differences between the X-ray guided group and the no guiding group in the diagnosis yield and the incidence rate of complications.

Conclusion: Rigid transbronchial lung cryobiopsy is a safe and effective method for the diagnosis of interstitial lung disease.

PO-370

A case of tracheoesophageal fistula blocked by ventricular septal defect occluder via bronchoscope

Li,Sijia、Song,Xinyu
Yichang Central People's Hospital

Objective: Tracheoesophageal fistula (TEF) is a rare disease. It is an abnormal communication that connects the posterior wall of the trachea and the anterior wall of the esophagus. It mainly originates from malignant tumors and exposure after radiation. The clinical picture of TEF consists of chronic cough, bouts of cough when swallowing liquids, recurrent pulmonary infections, increased respiratory secretions, lung abscess, and hemoptysis. Above symptoms are not specific, and esophagogastric duodenoscopy, bronchoscopy, and CT could contribute to diagnose TEF. The mortality rate of TEF is so high that the median survival time is 1-6 weeks without treated. However, the postoperative mortality was still up to 40%. The ways of surgery, thoracoscopy, endoscopic injection of medical protein glue, peritoneal stent implantation, bronchial valve was used to treat TEF, but the long-term prognosis is still controversial due to various serious complications. In this case, the ventricular septal defect occluder was successfully used to block the TEF under the guide of bronchoscope. The ventricular septal defect occluder was regarded as a cross-indication application. Therefore, this case report intended to analyze the characters of ventricular septal defect occluder for TEF, and the long terms goal was to provide new insights in clinic.

Methods: none.

Results: none.

Conclusion: none.

PO-371

Therapeutic effect of double Y-shaped covered airway stents on thoracic stomach-right main bronchial fistula

Li,Zongming、Jiao,Dechao、Han,Xinwei、Lu,Huibin、Ren,Kewei
The First Affiliated Hospital of Zhengzhou University

Objective: To determine the efficacy of double Y-shaped covered airway stents to treat thoracic stomach–right main bronchus fistulas.

Methods: We retrospectively analyzed 21 patients who developed thoracic stomach–right main bronchus fistula after esophageal cancer resection and postoperative irradiation. All fistulas were close to the right upper lobe bronchus. Two Y-shaped covered airway stents were designed for each patient. Under radiographic guidance, one stent was placed in the main bronchus (main stem), right upper lobe bronchus and intermediate bronchus (branches); another stent was placed in the trachea (main stem), and right and left main bronchi (branches).

Results: All fistulas were closed immediately after stenting. All patients could eat well. The symptom of coughing while lying down resolved in all patients, and no complications such as airway bleeding and pneumothorax occurred. Two patients died of tumor recurrence. Another two patients died of pulmonary infections. In one of these patients, there was a long delay between symptom onset and stenting. In the other patient, a small rupture occurred in the silicone membrane covering the stent, which allowed the leakage of gastric contents into the lung.

Conclusion: Double Y-shaped covered airway stent placement is feasible and safe to treat thoracic stomach–right main bronchus fistulas. Improvements to the material covering the stents are required.

PO-372

Frozen section of pleural biopsy combined with routine biopsy at medical thoracoscope conduces to the diagnosis of pleural effusion

Zhang,Tongtong、Li,Yu、XU,Mingpeng、LI,Wentao、Liu,Guangnan
The second affiliated hospital of Guangxi Medical University

Objective: To review and compare the diagnostic value of medical thoracoscope by combining frozen pleural biopsies and the conventionally formaldehyde-fixed paraffin-embedded lesion sections (standard sections) for patients with undiagnosed pleural effusions

Methods: The retrospective study was conducted based on the clinical data from a cohort of 42 patients with pleural effusions who had medical thoracoscopy at the second affiliated hospital of Guangxi Medical University (Nanning China) between October 2018 and November 2019. Of the 42 patients, 27 cases were performed with routine biopsy, 15 cases were obtained combined with frozen biopsy. Biopsy specimens from parietal pleura were obtained under direct vision and were sent for histopathological examination

Results: Of the 27 patients, 23 cases of pleural effusions were confirmed by medical thoracoscopic biopsy with a diagnosis rate of 85.1%. In these 23 confirmed patients, 8 had pleura cancer metastasis (34.8%) and 15 had tuberculous pleuritis (65.2%). Of the 15 patients by medical thoracoscopic frozen pleural biopsy were confirmed with a diagnostic rate of 93.7%, 14 patients acquired pathological diagnosis, including 7 pleura cancer metastasis (50%) and 7 tuberculous pleuritis (50%). Lung cancer is the most common type of malignant tumor, responsible for 93.8% of the patients with pleural metastasis. The samples obtained by frozen pleural biopsy are much larger for better sections, and therefore improves the positive diagnostic rate of pleural diseases to some degree. No complications were observed in the 42 cases. There was significant difference of diagnostic value between conventional biopsy and frozen pleural biopsy ($P < 0.05$).

Conclusion: Medical thoracoscopy is a safe and effective procedure. Frozen pleural biopsy combined with routine pleural biopsy at medical thoracoscopy has a vital diagnostic value for undiagnostic pleural effusion in patients.

PO-373

Retrospective analysis of clinical characteristics of 475 patients with tracheobronchial foreign bodies in central southern region of China

Liu,Qingqing、Yan,Nan、Xia,Shulan、Shi,Zhihui、Xiao,Kui、Zhou,Rui
The Second Xiangya Hospital, Central South University

Objective: To investigate the clinical characteristics and diagnosis of tracheobronchial foreign bodies(TFBs) as well as the removal experience of foreign bodies through bronchoscopy in adults and children.

Methods: A retrospective analysis was carried out by retrieving 475 cases in two general hospitals and one children's hospital. Furthermore, an analysis about the clinical manifestations, radiological findings, types and locations of tracheobronchial foreign bodies and endoscopic treatments was made in different patient groups.

Results: Among the 475 patients, the most common clinical manifestations were cough, children are generally treated earlier than adults. Direct signs were more dominant in children than in the adult group. The most common type of foreign bodies in adult group was fragments of animal bone or hot pepper, while in children group was small grain foods such as nuts and beans. Successful removal of foreign bodies through flexible bronchoscopy was 94.0% in adults

which was 100% in the case of children's hospital through rigid bronchoscopy .

Conclusion: Clinical characteristics of tracheobronchial foreign bodies between adults and children were different. As to removal of them, rigid bronchoscopy under general anesthesia was preferred in children especially for those who are under 3 years old. Flexible bronchoscopy was preferred in adult patients.

PO-374

Metabolite markers identify pneumonia better in serum than sputum or broncho-alveolar lavage fluid

Xiao,Qiang1、Zheng,Xiaobin2、Liu,Xiang3、Li,Liang4、Rong,Fu1、肖强
1. Department of Respiratory, Shunde Hospital, Southern Medical University (The First People's Hospital of Shunde Foshan)
2. Department of Respiratory Medicine, the Fifth Affiliated Hospital of Sun Yat-sen University
3. Department of Haematology, Shunde Hospital, Southern Medical University (The First People's Hospital of Shunde Foshan)
4. Shenzhen Institutes of Advanced Technology, Chinese Academy of Sciences

Objective: Pneumonia biomarkers have long been considered as an improvement to current mainstream diagnostic method[1-2]. However, there is a lack of comparison between the different patient sample types to be used for diagnostic biomarker development[3]. We aimed to compare the differential metabolite biomarkers for pneumonia in serum, sputum, and broncho-alveolar lavage fluid (BALF).

Methods: 242 pneumonia patients and 50 healthy volunteers were enrolled in this study. Serum and induced sputum were collected from all the participants. BALF were collected from 70 pneumonia patients and 20 healthy volunteers. UHPLC-QE Orbitrap/MS analysis was performed on the collected samples[4].

Results: Among serum, sputum and BALF, serum samples showed the most abundant metabolite biomarkers detectable that significantly differentiate pneumonia from healthy samples. Only 3 differential metabolites were shared between serum, sputum and BALF. 15 serum metabolites were found to consistently differentiate pneumonia and healthy states from all serum samples, while 8 of them were validated using random forest model. The serum metabolite biomarkers were not significantly associated to patient background parameters such as age or gender.

Conclusion: Serum metabolite biomarkers were found more efficient than those in sputum or BALF to differentiate pneumonia from healthy samples. A biomarker panel including 8 metabolites was proposed for potential diagnosis of pneumonia.

PO-375

Perioperative nursing experience of laser treatment of benign airway stenosis under fiberoptic bronchoscopy

Luo,Liying
The second hospital affiliated to Guangxi Medical University

Objective: To explore the perioperative nursing experience of laser treatment of benign airway stenosis under fiberoptic bronchoscopy

Methods: The perioperative nursing data of 20 patients with benign airway stenosis admitted to our department from January 2018 to May 2019 were retrospectively analyzed

Results: Through preoperative evaluation, intraoperative cooperation and postoperative careful nursing, 20 patients with benign airway stenosis were treated with laser therapy under fiber bronchoscope and perioperative nursing, and all achieved good clinical efficacy without complications

Conclusion: Adequate preoperative preparation, intraoperative coordination, and postoperative nursing care are the guarantees for good clinical efficacy of laser therapy for benign airway stenosis under fiberoptic bronchoscopy

PO-376

Application of interventional care in selective bronchial arterial embolism

Cheng,Xiaofang
Nanchang University First Affiliated Hospital

Objective: The application value of interventional care in the treatment of large hemorrhagic patients by interventional arterial embolism is discussed. Methods 51 patients with bronchial arterial thrombosis were selected as study subjects, and randomly divided into experimental groups (25 cases) and control groups (26 cases), respectively, to provide interventional care and routine care, and to observe the clinical effects of two groups of patients. Results The effective rate of clinical interventional care was 96.00%, which was significantly higher than that of the control group, and the difference was statistically significant (P 0.05). Conclusion After interventional care of large hemorrhagic patients treated with bronchial arterial embolism, the clinical effect was significantly optimized and worthy of clinical promotion.

Methods: From March 2011 to April 2016, 51 cases of large-scale hemorrhage were admitted to the hospital, including 31 cases of male and 20 female, age 34 to 70 years old, average age (43.5 to 8.2 years old), disease course 3 days to 9 years, bronchial expansion 30 cases, tuberculosis 18 cases, lung cancer 2 cases, 1 case of pneumonia. In 51 cases, the patients were accompanied by clinical symptoms of hemorrhage, coughing and coughing, and some patients experienced dizziness and short chest tightness. Randomized 51 patients were divided into experimental group (25 cases) and control group (26 cases), and the clinical data of the two groups were not statistically significant and comparable

Results: The clinical validity rate of the experimental group was 96.00%, the clinical validity rate of the control group was 76.92%, and the clinical efficacy of the patients in the experimental group was higher than that of the control group, and the difference was statistically significant ($P < 0.05$)

Conclusion: Treatment of elective bronchial arterial embolism is a common treatment for large hemorrhage, which requires proper care after surgery, otherwise it may affect the effectiveness of the treatment. The use of interventional care after treatment of a selective bronchial arterial embolism can improve the patient's therapeutic

outcome, quality of life, and rate of care satisfaction. The caregiver performs psychological guidance according to the actual situation of the patient, and patiently explains the treatment of the arterial embolism of the selective bronchial tube, as well as the process of interventional care, as well as the precautions, benefits, etc. In the operation, the nursing staff need to always pay attention to the patient's vital signs, with the medical treatment, and ready to rescue the rescue at any time.

PO-377

Serum Creatinine as a Potential Biomarker for the Diagnosis of Tuberculous Pleural Effusion

Liang,Laoqi1、Rong,Fu1、Li,Liang2、梁烙琪
1. Shunde Hospital of Southern Medical University (the First People’s Hospital of Shunde)
2. Shenzhen Institutes of Advanced Technology， Chinese Academy of Sciences

Objective： Our study aimed to explore whether Cr can act as a biomarker for the diagnosis of TPE and to evaluate the correlation between Cr and TPE.

Methods：Patients at our hospital who suffered from pleural effusions (PEs) and met the inclusion criteria were enrolled in this study. By comparing the concentrations of Cr and adenosine deaminase (ADA) in patients with TPEs and non-TPEs, we determined the sensitivity, specificity, Youden index, and area under the curve (AUC) for these biomarkers. Additionally, we generated receiver operating characteristic (ROC) curves and quantifications for each biomarker to evaluate the diagnostic accuracy.

Results： In total, 86 patients (44 patients with TPE, 25 patients with malignant pleural effusion (MPE) and 17 patients with non-tuberculosis (non-TB) infectious PE (NTIPE)) were enrolled in the study. The concentrations of Cr in TPE were significantly higher than those in non-TPE (87.49±20.20, 61.94±16.20 and 63.68±14.96 (μmol/L) for TPE, NTIPE and MPE, respectively) (P1,P2<0.05). However, a similar trend was not observed for NTIPE and MPE (P3>0.05). The levels of ADA in TPE were significantly higher than those in NTIPE and MPE (59.90±24.27, 34.48±27.11 and 14.36±5.83 (μmol/L) for TPE, NTIPE and MPE, respectively) (P’1, P’2<0.05). The sensitivity, specificity, Youden index, and AUC of Cr, ADA and (ADA+Cr) in the diagnosis of TPE was 70.5%, 90.5%, 0.609, 0.837; 97.7%, 81.0%, 0.787, and 0.923; and 90.9%, 92.9%, 0.838, and 0.951, respectively.

Conclusion： Cr has the potential to aid in the diagnosis of TPE to some extent though its accuracy is not as high as that of ADA. Further studies are necessary for Cr to be applied in clinical practice for the diagnosis of TPE.

PO-378

Rapid on-site evaluation combined EGFR/ALK/ROS1 gene mutations in lung adenocarcinoma clinical application and research

Ren,Xuezhu、Cai,Zhigang
The second Hospital of Hebei Medical University

Objective: Rapid on-site evaluation (ROSE) technology is a real-time fast cytological interpretation technology with in the process of the materials.Target location based, on the premise of no loss of tissue samples, specimen will be partly based on slides, made from cytology film base, rapid dyeing and integrated clinical information immediately with a special microscope interpretation, after 2 minutes we can get qualified enough to know whether the specimen was enough, and then transferred to the parallel inspection department.ROSE has been proposed as a method to improve the yield of tissue samples.The study investigated whether on-site analysis facilitates routine diagnostic bronchoscopy in terms of sampling, yield and cost.To determine the extent to which on-site cytopathology assessment improves diagnostic yield when sampling lung nodules or lung hilar or mediastinal lymphadenopathy by fiberoptic bronchoscopy (FOB).Diagnostic accuracy, sensitivity, specificity, positive predictive value(PPV), negative predictive value (NPV) were compared.Through the evaluation of the ROSE and the pathological diagnosis of lung adenocarcinoma detection of EGFR/ALK ROS1 gene mutations, the patient who has positive mutation can use appropriate targeted drugs.

Methods: Take the people who was suspected of lung adenocarcinoma patients were divided into two groups, a group of 40 people, the first group using ROSE guidance materials then send pathology, a second group of routine pathology.Take interventional techniques(via electron microscopy bronchoscopy lung biopsy, percutaneous lung biopsy) for materials, including irrigation, brush, biopsy, TBNA, etc. A cytopathologist screened the speciment on-site for the presence of diagnostic material. The bronchoscopic sampling process was adjusted according to the results.Clinicians bronchoscope in patients with lung cancer were drawn by doing it, for the specimens for on-site evaluation to determine for adenocarcinoma patients, to take tissue by brush or gross tissue pathological slices, detection of EGFR/ALK/ROS1.

Results: Adequate tissue sampling rates showed no significant difference between the 2 groups.But in the NO-ROSE group, there are 7 cases(17.5%) because of insufficient sample size,more materials are needed to surgery the second time.This caused the patient is greatly increased risk of secondary surgery.Only in 2 patients (5%) diagnostic aspirates were not recognized on site.Every case of patients with ROSE has sufficient and accurate specimens for conventional pathology detection and immunohistochemical detection.And in ROSE group, specimen qualified rate and diagnostic yields were signicantly higher than No ROSE group (98.77% vs 91.00%, $P<0.05$), the incidence of complications in the ROSE group was signicantly lower than that in the No ROSE group (1.23% vs 11.67%, $P<0.05$). The sensitivity, specificity, positive predictive value and negative predictive value of ROSE in the diagnosis of lung cancer are 91.38%, 100.00%, 100.00% and 46.00%. ROSE can improve the specimen qualified rate and diagnostic rate, also can reduce the complications thus worthy of further promotion. In the diagnosis of adenocarcinoma of the specimen, EGFR gene mutation rate is 11%, the ALK gene mutation rate is 2%, ROS1 gene mutation rate is 1.5%.

Conclusion: ROSE is an efficient method to provide adequate samples for testing of EGFR/ALK/ROS1 mutation and arrangement of the following routine histopathology .ROSE is a highly useful, accurate and cost-effective technology.Epidermal growth factor (EGFR) gene mutations of tumor cell proliferation, has played an important role in growth, repair and survival, is a kind of drug sensitive mutations.Anaplastic lymphoma kinase (ALK) variation is mainly for the ALK gene and other genes break rearrangement.Sarcoma of carcinogenic factor - receptor tyrosine kinase. (ROS1) gene rearrangement, fusion in non-small cell lung cancer incidence is about 1% ~ 2%.By testing, the positive mutation can use appropriate targeted drugs.The advent of gene targeting drugs, significantly improve the quality of life and survival of patients with lung cancer, three kinds of joint gene mutation detection has important clinical significance.To carry out the ROSE can help provide direction for clinical diagnosis, improve the diagnosis of patients with difficult success rate, avoid experience treatment, reduce the in-hospital time, for the benefit of patients, patients relief from pain.Combining two methods of inspection, this study aims to improve the diagnostic rate of patients with lung adenocarcinoma targeted drugs for patients to seek the most accurate, reduce the pain and economic burden.

PO-379

Tobacco Heating System 2.2 in mild to moderate chronic obstructive pulmonary disease subjects: An exploratory analysis

Sergio,Francesco、Ansari,Michael、Felber,Loyse、Elamin,Ashraf、Haziza,Christelle
PMI

Objective: The Tobacco Heating System (THS) 2.2 is a novel product that electronically heats tobacco at temperatures significantly lower (<350℃) than those generated when burning cigarettes (CC), producing substantially lower levels of harmful and potentially harmful constituents, with a mean decrease of 90%. A randomized, two-arm parallel group, multicenter exposure study conducted in the US (NCT02396381) demonstrated statistically significant changes in five of eight biomarkers of effect (BoEff) at 6 months among adults switching to THS relative to those who continued smoking, meeting the primary study objective, with all BoEffs moving in the direction of smoking cessation (SC). The study was extended by an additional 6 months (NCT02649556), and these favorable changes were maintained over 12 months.

Methods: This analysis was designed to explore the effect of switching to THS (n = 17) compared with continued smoking (n = 28) in a subgroup of subjects (from the two aforementioned exposure studies) with baseline spirometry indicating mild to moderate chronic obstructive pulmonary disease (COPD) according to GOLD 2018 criteria. The results from a subset of subjects (n = 18) with mild COPD from a 1-year continuous smoking abstinence study (NCT02432729) were used as reference. The analysis was also conducted on a broadened subgroup including subjects with obstruction defined by forced expiratory volume in 1 s (FEV1)/forced vital capacity (FVC) ≤ 0.75, based on the Lung Health Study's review1 of mild to moderate COPD, which defined obstruction with the precedent American Thoracic Society guidelines. The main respiratory and cardiovascular endpoints were white blood cell count (WBC) and soluble intercellular adhesion molecule 1 (sICAM-1) and 8-epi-prostaglandin F2α (8-epi-PGF2α) levels.

Results: After 12 months of follow up, COPD subjects showed favorable shifts in the direction of changes observed in SC for most BoEffs after predominant (>=70%) THS use. The magnitude of these shifts was more pronounced than those in the general population of our exposure studies, where the majority of enrolled subjects were healthy, with a THS–CC difference of 72 mL in FEV1 among COPD subjects and a reduction of 1.95 GI/L in WBC, 6.8% in sICAM-1 levels, and 28% in 8-epi-PGF2α levels for THS relative to CC.

Conclusion: The results of this preliminary analysis are consistent with the main study findings, with marked changes observed among subjects with COPD. These results suggest reduced harm potential for THS compared with smoking in mild to moderate COPD subjects

PO-380

Early application of noninvasive ventilation to prevent and treat postoperative complications of bronchoscopy under general anesthesia

Wang,Yinfeng、Chen,Yunfeng、Zeng,Yiming
The Second Affiliated Hospital of Fujian Medical University

Objective: To investigate the changes of pulmonary ventilation function after bronchoscopy under general anesthesia and to explore the prevention and treatment methods.

Methods: A prospective self-control study was used in this study. The changes of PCO2, PO2 and oxygenation index in blood gas analysis（BGA）before, after general anesthesia bronchoscopy and after the application of noninvasive ventilation after operation for 2h, 6h, 12h and 24h were compared.

Results: In RICU of our unit, 8 patients participated in the experiment from July 2019 to December 2019. Among them, 8 patients completed the BGA before, after general anesthesia bronchoscopy, 2 hours after noninvasive ventilation and 12 hours after noninvasive ventilation. There were 5 patients who completed the BGA after 6 hours of noninvasive ventilation, and 6 patients who completed the BGA after 24 hours of noninvasive ventilation.The mean PCO2 values before and after bronchoscopy were 43.738 ± 5.0313 and 50.062 ± 4.5679 (t = -3.061, P = 0.018);The mean PCO2 values after bronchoscopy and 2 hours after noninvasive ventilation were 50.062 ± 4.5679, 41.438 ± 10.9315 (t = 2.318, P = 0.054) ;The mean PCO2 values after bronchoscopy and 6 hours after noninvasive ventilation were 50.92±5.692，40.10±4.959（t=8.667，P =0.001）；The mean PCO2 values after bronchoscopy and 12 hours after noninvasive ventilation were 50.062±4.5679，39.212±9.2718（t=4.054，P =0.005）；The mean PCO2 values after bronchoscopy and 24 hours after noninvasive ventilation were50.87±5.093，39.38±8.134（t=4.937，P =0.004）；There were significant differences in PCO2 before and after bronchoscopy under general anesthesia. And it aslo has significant difference in PCO2 between the patients who used noninvasive ventilation for 6h, 12h and 24h after operation and those after operation.

Conclusion: The PCO2 level may rise after bronchoscopy under general anesthesia and can be decreased by early application of noninvasive ventilation after operation.

PO-381

Study on the relationship between endoscopic classification and efficacy in asthma patients with bronchial thermoplasty (BT)

Long,Fa、Huang,Zhihui、Huang,Wenting、Long,Liang、Hu,Fengbo、龙发
University of Chinese Academy of Sciences Shenzhen Hospital

Objective: To study the relationship between endoscopic classification and efficacy of 126 patients with bronchial thermoplasty (BT).

Methods: 126 patients who received BT treatment in our hospital from May 2016 to November 2018 were included as the study subjects. According to different endoscopic classification，the patients were divided into mucosal edema group（n=18）,strong contraction group（n=41）,mucosal remodeling group（n=30）and mucosal structure mixed grop（n=37）. Outcomes assessed post BT included ACT score, AQLQ score, lung function, frequency of acute exacerbations, asymptomatic days and medication adjustment in the four groups at 6 and 12 months post treatment.

Results: 6th and 12th months post BT of the ACT score, AQLQ score, FEV1 and FEV1 % predicted were higher

than those of four groups before surgery. The ACT score of 12th months post BT was higher in the mucosal edema group than in the mucosal remodeling group. The AQLQ scores of the type group, 6th and 12th months post BT were higher than those of the mucosal remodeling group and the mucosal structure mixed group. The ACT score and AQLQ score of 12th months post BT in the strong contraction group were higher than those in the mucosal remodeling group and the mucosal structure mixed group，the difference was statistically significant (P<0.05). The number of acute exacerbation, asymptomatic days, and oral glucocorticoids doses in the four groups 12th months post BT were improved compared with those before surgery (P<0.05). However, the degree of reduction in acute exacerbation frequency in the mucosal edema group was greater than that in the mucosal remodeling group. The increase degree in asymptomatic days post BT in the mucosal edema group and the strong contraction group greater than that in the mucosal remodeling group. Inhaled glucocorticoids were significantly reduced post BT in the strong contraction group and mucosal remodeling group. The difference was statistically significant (all P < 0.05).

Conclusion: The clinical symptoms, quality of life, lung function in patients with severe asthma were significantly improved post BT treatment. BT in treatment of Patients with mucosal edema group and strong contraction group asthma responded better, and those of the curative effect were significantly better than mucosal remodeling group.

PO-382

A case of bronchial carcinoid diagnosed by the guiding of ROSE and literature review

Shen,Hong、Chen,Shiping、Zhu,Yina、Jin,Ning
the Second Affiliated Hospital of Nanjing Medical University

Objective: By summarizing the clinical manifestation, radiological and pathological features of the patients with bronchial carcinoid, in order to improve the diagnostic rate of bronchial carcinoid and prevent the risk of massive haemorrhage caused by extra biopsy by using rapid on-site evaluation (ROSE) technique.

Methods: The clinical data of a case with bronchial carcinoid diagnosed by the guiding of ROSE was retrospective analyzed, and relevant literature was reviewed.

Results: A female patient was admitted due to “cough and sputum for one month”, chest CT showed a small nodule in the spur of the left main bronchial lumen, biopsy was taken by bronchoscopy, the manifestation of tissue inprint for ROSE presented the cell morphology was consistent, disorderly arrangement, small cell size, nuclear enlargement, less cytoplasm, we assessed preliminarily it as carcinoid, thus guided the biopsy for three times, and evaluated the adequacy of specimen, after the assessment performed by ROSE, the procedure was stopped. Several days later with immunohistochemistry the lesion was confirmed as typical carcinoid.

Conclusion: Bronchial carcinoid is a rare and low-grade malignancy, clinical and imaging findings can’t lead to the diagnosis and the positive rate of bronchoscopic biopsy is low. The application of ROSE can improve diagnostic yield, decrease times of biopsy and reduce the risk of massive bleeding, increase the adequacy of the specimen and appropriately triage of sample for further testing. The final diagnosis of carcinoid is confirmed by pathology and immunohistochemistry.

PO-383

Cytological Testing of Novel Programmed Death Ligand-1 in Lung Cancer Patients on Bronchoscopic Needle Aspiration

Khemasuwan,Danai、Danai Khemasuwan
St. Elizabeth Medical Center

Objective: Novel genetic markers are being increasingly targeted and have shown to improve survival in patients with advanced non-small cell lung cancer (NSCLC). Programmed Death-Ligand-1 (PD-L1) testing in NSCLC is recommended by current guidelines. The goal of this study was to determine the diagnostic yield of PD-L1 testing from cytology cell block samples obtained through transbronchial needle aspiration with endobronchial ultrasound (EBUS-TBNA) and electromagnetic navigational bronchoscopy (ENB).

Methods: We identified 39 patients who underwent EBUS and ENB for the evaluation of presumed lung cancer between April 2018 and November 2019. Of these, we identified 33 patients who were diagnosed with NSCLC. We excluded 13 patients in whom PD-L1 testing was performed on histologic samples. We included 20 patients with NSCLC who underwent PD-L1 testing on needle aspiration samples.

Results: Among 20 patients, 17 patients had needle aspiration samples that were obtained from lymph nodes/hilar mass through EBUS-TBNA. All cytological samples obtained with 21-G needle were used to analyze PD-L1 expression. Seventeenth patients (100%) underwent successful PD-L1 testing. The median number of passes per lymph nodes was 5 (range 2 to10). Three patients underwent navigational biopsy of the lung nodules and had negative lymph node stations. Cytological samples obtained with 19-G needle were used to analyze PD-L1 testing. All samples (100%) were adequate for testing.

Conclusion: In our single center experience, cytological samples obtained through EBUS-TBNA and ENB-guided needle aspiration were adequate for PD-L1 testing on lymph nodes and tissue samples.

PO-384

The Role of Endobronchial Ultrasound-Guided Transbronchial Needle Aspiration Cytology in the Diagnosis of Mediastinal Lymphadenopathy

Xu,Chuancai、Ni,Chongjun、Huang,Jian'an、徐传财
The First Affiliated Hospital of Soochow University

Objective: The present study aimed to evaluate the effectiveness of the combination of EBUS-TBNA and LBC in the diagnosis of mediastinal lymphadenopathy.

Methods: A total of 602 LNs that were retrospectively analyzed were sampled in 442 patients who underwent EBUS-TBNA between January 2014 and December 2016. The Histopathological result of TBNA tissue was considered as the gold standard to evaluate diagnostic utility of LBC and conventional smears (CS) for the diagnosis of mediastinal lymphadenopathy.

Results: Of the 602 LNs, 265 were mediastinal LN metastases from lung cancer, 4 were lymphoma, and 333 were benign (Table 1-3). Among all the 602 mediastinal LNs, 521 (86.5%) were diagnosed by EBUS-TBNA combined with LBC, which was significantly higher than the number diagnosed by CS (490, 81.4%) ($P<0.001$) (Table 4). The sensitivity of LBC and CS in the diagnosis of mediastinal LN metastases from lung cancer was 72.8% and 63%, respectively, and the specificity was 98.5% and 97%, respectively. The positive predictive values for LBC and CS

were 97.5% and 94.4%, respectively, whereas the negative predictive values were 82.2% and 76.9%, respectively. The accuracy of LBC and CS was 88% and 83.7%, respectively. The diagnostic value of LBC was significantly higher than that of CS (P=0.001). The sensitivity of LBC and CS to detect LN metastases of squamous cell carcinoma was 63% and 55.6%, respectively, however, no statistically significant difference was observed by Fisher's exact test. McNemar's test showed significant difference in the sensitivity of LBC and CS for the detection of adenocarcinoma (P=0.027), particularly in small cell lung cancer (P=0.001) (Table 5) (Figure 1).

Conclusion: The combination of EBUS-TBNA and LBC is a highly reliable and feasible procedure that optimizes diagnostic utility for the diagnosis of lung cancer and mediastinal LN staging.

PO-385

The Role of Endobronchial Ultrasound-Guided Transbronchial Needle Aspiration in Mediastinal Lymphadenopathy After Positron Emission Tomography/ Computed Tomography Scans

Xu,Chuancai、Ni,Chongjun、Huang,Jian'an、徐传财
The First Affiliated Hospital of Soochow University

Objective: Endobronchial ultrasound guided transbronchial needle aspiration (EBUS-TBNA) and positron emission tomography/computed tomography (PET/CT) are the two most extensively used methods in the diagnosis, evaluation, and follow-up surveillance of patients with lung cancer.

Methods: Eighty-five patients with mediastinal lymphadenopathy who underwent EBUS-TBNA and PET/CT between January 2014 and December 2017 were retrospectively analyzed in this study. Of the 85 patients, 55 patients had malignant tumors, and 30 had benign diseases (Table 1-2). The accuracy of EBUS-TBNA histopathology and cytopathology was evaluated and compared with PET scan findings. McNemar's method and Unpaired Student's t-test were used.

Results: A total of 151 lymph nodes (LNs) were sampled in 85 patients. The average SUVmax value of LNs was 6.6 (range, 0.9 to 25.6). Among the 46 PET/CTpositive benign LNs, 29 were reactive and diagnosed by EBUSTBNA. A representative case was shown in Figure 1. Eleven of 13 (84.6%) granulomas and 3 of 4 (75%) TB cases were diagnosed by EBUSTBNA. Among the 9 PET/CTnegative malignant LNs, 2 of 5 (40%) metastatic LNs of adenocarcinoma, 1 metastatic LN of small cell lung cancer and 1 non-Hondgkin lymphoma LN were detected by EBUSTBNA (Table 3). The diagnostic accuracy of EBUS-TBNA histopathology (84.8%) and cytopathology (78.8%) was significantly higher than that of PET/CT (63.6%) (P<0.001 and P=0.012, respectively). The diagnostic sensitivity, specificity, positive predictive values, and negative predictive value of EBUSTBNA combined with PET/CT were 95.2%, 100%, 100%, and 94.4%, respectively. The diagnostic accuracy (97.4%) of EBUSTBNA combined with PET/CT was significantly higher than that of the single diagnostic method (P < 0.001).

Conclusion: EBUS-TBNA could effectively reduce PET/CT false positive and PET/CT false negative rates in the diagnosis of mediastinal lymphadenopathy, provide accurate staging and determine optimum therapeutic strategy, which might improve survival in patients with lung cancer.

PO-386

Role Of Bronchoscopy In Centrally-Located Lung Tumor

Candrawati,Ni Wayan、Andikayasa,Pande Made、Rai,Ida Bagus Ngurah、Kusumawardani,Ida Ayu Jasminarti Dwi
RSUP Sanglah

Objective: Lung cancer is the most common cause of cancer death in the world also in Indonesia. The majority of lung cancer patients are diagnosed at an advanced stage.Selection between transthoracic and bronchoscopic approaches should be based on the location and distribution of the tumor. Central endobronchial lesions yield the highest diagnostic return (>90%), whilst small peripheral lesions often prove more elusive unless more demanding and time-consuming techniques are used. The aim of this study is to assess the role of bronchoscopy in centrally-located lung tumor. Lung cancer is the most common cause of cancer death in the world also in Indonesia. The majority of lung cancer patients are diagnosed at an advanced stage.Selection between transthoracic and bronchoscopic approaches should be based on the location and distribution of the tumor. Central endobronchial lesions yield the highest diagnostic return (>90%), whilst small peripheral lesions often prove more elusive unless more demanding and time-consuming techniques are used. The aim of this study is to assess the role of bronchoscopy in centrally-located lung tumor.

Methods: This was a retrospective study involving 115 patients with a confirmed diagnosis of lung cancer in Sanglah Hospital from January 2017 until December 2017. The diagnostic techniques that included in this study were bronchoscopy, pleural fluid cytology, transthoracal biopsy, fine needle aspiration biopsy of external lymph node and open biopsy. Data were analyzed using chi square and kolmogorov-smirnov test.

Results: Of the 115 study patients, 54.8% were male. The mean age was 58.93 years (range 29-84 years). The diagnosis was made using transthoracal biopsy (48.7%), bronchoscopy (23.5%), pleural fluid cytology (11.3%), fine needle aspiration biopsy of external lymph node (9.6%) and open biopsy (7%). The mass was identified to be centrally located in 29 cases (25.2 %) and peripherally in 86 cases (74.8%). Tumor histological type were squamous cell carcinoma, in 20 cases (17.4%); adenocarcinoma, in 80 cases (69.6%); small cell carcinoma, in 3 cases (2.6%); non small cell lung carcinoma in 8 cases (7%) and others, in 4 (3.5%). Analysis was performed to examine the association between the location of lung tumor and diagnostic techniques, and the result was statistically significant. Bronchoscopy was significantly associated with positive histologic result in centrally located tumor (chi-square; P = 0.000). No significant association between bronchoscopy and histological type of tumor (Kolmogorov-Smirnov, P = 0.331).

Conclusion: Bronchoscopy played a pivotal role in lung cancer diagnosis especially in centrally located lung tumor.

PO-387

Primary Tracheobronchial Papilloma: Case Report and Literature review

Yang,Huizhen、Ma,Yun、Zhang,Quncheng、Zhang,Xiaoju
Henan Provincial People's Hospital

Objective: To investigate the clinical and pathological features of the tracheal/bronchial papilloma so as to achieve a comprehensive understanding of this disease and improve the diagnosis and treatment.

Methods: The clinical data of five cases of tracheaobronchial squamous cell papilloma were retrospectively analysed. The related literatures were extensively reviewed to accurately describe the clinical manifestations, diagnosis, treatment, and prognosis of this disease. Pubmed(1995-2020.5), Chinese biomedicine literature database (1978-2020.5), Chinese technological periodical full-text database (1989-2020.5), and Chinese periodical full-text database (1964-2020.5) were searched for tracheobronchial papilloma.

Results: The five cases were diagnosed as tracheobronchial papilloma by the bronchoscopy and pathological detection, interventional therapy under electron-bronchoscope was effective for treatment of the disease. The clinical presentations of this disease were various and typically nonspecific, which ranged from mild symptoms like cough to life-threatening conditions like upper airway obstruction. Treatment plan is usually made on an individual basis, which depended on the extent of the papillomas, lesion characteristics, potential malignancy, treatment outcome, and patient status.

Conclusion: Tracheobronchial papilloma is a relatively rare benign tumor of respiratory system, it is easy to misdiagnose due to lacking of specificity of clinical manifestations. Bronchoscopic biopsy contributes to the diagnosis. The treament is mainly bronchoscopic interventional therapy, and thoractomy was performed when malignant transformation was considered.

PO-388
A case report - Endobronchial chondromas

Tao,Hongyan、Ma,Tiantian、Wan,Yixin、陶红艳
The second hospital of Lanzhou university

Objective: Endobronchial chondromas are rare benign mesenchymal tumors. We report the case of a patient with an endobronchial chondroma.

Methods: We report the case of a 47-year -old man with one-year history of discontinuous chest tightness and shortness of breath, and the symptoms aggravated for 1 month. The patient presented with complaints of occasional cough, sometimes with white phlegm. Computed tomography of the chest and bronchoscopy showed an tumor about 1.7cm×1.3cm occluding the trachea. The bronchoscope examination showed that the cauliflower-like neoplasm obstructed the three-fourths of the trachea. The bronchoscope was barely able to pass. Histologically, the biopsy specimens were composed of fiber capsule and hyaline cartilage. In this case, we set up an electric trap and high frequency electric、cryosurgery to remove the chondroma in the middle of the trachea to avoid thoracotomy. The operation process was successful and effective. After 1 years of follow-up, the recovery was perfect, no recurrence and sequelae.

Results: The treatment of bronchoscopic resection consists of complete resection to avoid risks of recurrence or transformation.

Conclusion: Endoscopic resection seems be the first choice to Endobronchial chondromas.

PO-389

Acute and long-term survival results of lung RF ablation in healthy porcine model

Yoneda,Ken1、Spangler,Taylor2、Raina,Shashank3、Panescu,Dorin3
1. University of California， Davis
2. VDx Preclinical Research Services
3. Zidan Medical

Objective: Lung cancer is the most common cancer in the world. Surgical resection is considered the best treatment for patients with non-small cell lung cancer (NSCLC). However, patients with comorbidities may not be suitable candidates for resection. Radiofrequency Ablation (RFA) is a therapy that is associated with lower morbidity and can be done on outpatient basis. RFA therapy has the potential to be comparable with stereotactic body radiation therapy (SBRT) in treating early-stage NSCLC. The goal of this paper is to introduce a novel technology for treating early-stage NSCLC using an endobronchial approach via a flexible RFA catheter. A discussion of findings from a 12-week survival healthy-swine study is provided.

Methods: The RFA system consisted of a catheter, generator, irrigation pump (IP) and a laptop. The catheter was equipped with a balloon and two electrodes: a 5 mm long RF electrode with holes for irrigation with hypertonic saline (HS) and a 1-mm long impedance electrode used for bipolar impedance measurement. The catheter has a 1.4 mm outer diameter for compatibility with current bronchoscopes, and radial EBUS. Nine swine were treated in this study with survival times of 1, 4 and 12 weeks (N=3 at each time point). In all animals the treatment sites consisted of one bronchus in the lower right lung and one bronchus in the upper right lung. CTs were taken pre, post and at every 2 weeks post treatment. Ablation times ranged from 6 to 8 min and average applied power was 68 W (range 63 – 72 W).

Results: At 1 week, large zones of necrotic tissue were observed in all ablations. The average ablation volume was between 3.2 cm to 3.8 cm in diameter. The necrotic tissue was gradually replaced with fibrotic tissue. After 4 weeks survival, the replacement was almost complete in all animals. The average volume of the treatment effect decreased to 2.3 to 1.3 cm in diameter. At 12 weeks the histopathology showed little evidence of residual necrotic tissue, ablation zones had been resorbed and contracted by fibrous scar tissue (Figure 1). The average volume of the treatment effect decreased to 1.6 to 1.1 cm in diameter. There were no complications in any of the nine animals.

Conclusion: RFA created with an endobronchial catheter has been shown to be an effective and safe therapy in healthy porcine lungs. This device and therapy may be considered for further evaluation in minimally invasive treatment of tumorous lung nodules.

PO-390

The diagnosis and treatment of Endobronchial Papilloma by bronchoscopy:A Case Report and Literature Review

Su,Xiaoshan1,2、Zhang,Huaping1,2、Weng,Meili1,2、Chen,Xiaoyang1,2、Zeng,Yiming1,2
1. The Second Affiliated Hospital of Fujian Medical University
2. Respiratory Medicine Center of Fujian

Objective: To strengthen the understanding of the clinical characteristics of Endobronchial Papilloma and observe the clinical efficacy of electronic bronchoscopy in the diagnosis and treatment in order to improve the diagnosis and treatment of this disease.

Methods: The clinical data of one rare case of a 14-year-old woman with Endobronchial Papilloma were analyzed retrospectively, and the related literature was reviewed.

Results: A 14-year-old female was referred to our institution for investigation of recent recurrent cough. She had suffered from progressive cough over the previous four months. Upon preliminary assessment, the patient's vital signs, physical examinations and serum laboratory data were normal, including tumour markers. While contrast-enhanced thoracic computed tomography (CT) demonstrated an inhomogeneously enhanced nodule measuring 1.61 cm×1.53 cm in the middle segment of the trachea. No mediastinal, hilar lymphadenopathies or other lesions in the lung parenchyma were noted. Bronchoscopy and bronchial biopsy revealed an endobronchial mass in the middle segment of trachea, nearly occluded the lumen. The endobronchial mass was biopsied and treated successfully by high-frequency snare ligation via an A 14-year-old female was referred to our institution for investigation of recent cough. She had suffered from progressive cough over the previous four months. Upon preliminary assessment, the patient’s vital signs, physical examinations and serum laboratory data were normal, including tumour markers. While contrast-enhanced thoracic computed tomography (CT) demonstrated an inhomogeneously enhanced nodule measuring 1.61 cm×1.53 cm in the middle segment of the trachea. No mediastinal, hilar lymphadenopathies or other lesions in the lung parenchyma were noted. Bronchoscopy and bronchial biopsy revealed an endobronchial mass in the middle segment of trachea, nearly occluded the lumen. The endobronchial mass was biopsied and treated successfully by high-frequency snare ligation via an electronic bronchoscopy . Histopathological examination revealed that papillary structures were composed of glandular epithelial cell, no evidence of malignant transformation was recognized. She was diagnosed with glandular papilloma of the bronchus and had immediate relief of airway obstruction. . Histopathological examination revealed that papillary structures were composed of glandular epithelial cell, no evidence of malignant transformation was recognized. She was diagnosed with glandular papilloma of the bronchus and had immediate relief of airway obstruction afterA 14-year-old female was referred to our institution for investigation of recent cough. She had suffered from progressive cough over the previous four months. Upon preliminary assessment, the patient’s vital signs, physical examinations and serum laboratory data were normal, including tumour markers. While contrast-enhanced thoracic computed tomography (CT) demonstrated an inhomogeneously enhanced nodule measuring 1.61 cm×1.53 cm in the middle segment of the trachea. No mediastinal, hilar lymphadenopathies or other lesions in the lung parenchyma were noted. Bronchoscopy and bronchial biopsy revealed an endobronchial mass in the middle segment of trachea, nearly occluded the lumen. The endobronchial mass was biopsied and treated successfully by high-frequency snare ligation via an electronic bronchoscopy . Histopathological examination revealed that papillary structures were composed of glandular epithelial cell, no evidence of malignant transformation was recognized. She was diagnosed with glandular papilloma of the bronchus and had immediate relief of airway obstruction after bronchoscopy and endoscopic intervention .

Conclusion: Endobronchial papilloma is a relatively uncommon diseases, accounting for only 0.38% of all lung tumours and approximately 7% of all benign epithelial and mesenchymal lung tumours. The present case was one of juvenile-onset type endobronchial papilloma. Endobronchial papillary is easy to be misdiagnosed in the early stage, electronic bronchoscopy can be used to diagnose the disease. Moreover, the effect of high-frequency snare ligation by

electronic bronchoscope is remarkable. Bronchoscopy and endoscopic intervention play a huge role in the diagnosis and treatment of the Endobronchial Papilloma and should be considered as first-line therapy.

PO-391

Interventional Bronchoscopy of Primary Tracheal spindle cell sarcomatoid carcinoma

Lin,Xiaoping、Zeng,Yiming
Department of Pulmonary and Critical Care Medicine， the Second Affiliated Hospital of Fujian Medical University；
Pulmonary Medicine Center of Fujian Province

Objective： Spindle cell carcinoma cases are reported in many sites, such as head and neck region, larynx, digestive tract, breast, kidney, genital tract, skin and lung, but to our knowledge, few in trachea.

Methods： We report a case of primary tracheal spindle cell sarcomatoid carcinoma which was diagnosed and resected by bronchoscopic techniques. A 40-year-old man presented with dyspnea and intermittent cough. Chest computed tomography scan revealed an endoluminal mass and a tumoral mass arising from the left posterior wall of the trachea was observed bronchoscopically. Endoscopic Nd:YAG laser and electric snare were performed to take biopsies and to regain the airway passage. Microscopically, the tumor was composed of fascicular pattern of spindle cells with atypical mitotic figures and nuclear pleomorphism, positively reactive to epithelial membrane antigen supporting a diagnosis of tumour with epithelial differentiation.

Results： These findings supported the diagnosis of a spindle cell sarcomatoid carcinoma of trachea.

Conclusion： Primary malignant tracheal tumours consist mainly of squamous cell carcinoma and adenoid cystic carcinoma and generally have an aggressive course with poor prognosis. Spindle cell sarcomatoid carcinoma of the trachea is rare, there are only a few reported cases in the literature. We report a case which was diagnosed and resected by interventional bronchoscopic techniques

PO-392

Clinical Features and Management of Endobronchial Hamartoma

Bian,Shuang、Tang,Xiaomiao、Wang,Jiajia、Zhang,Xiaohui、Chen,Yanbin、Yang,Xinjing、Lei,Wei、边爽
The First Affiliated Hospital of Soochow University

Objective： Endobronchial hamartoma(EH) is a benign endobronchial tumor with low incidence. The objective of this study was to explore the clinical features and management of patients with endobronchial hamartoma, improve the diagnosis and treatment.

Methods： Retrospective study on the clinical data of 13 cases of endobronchial hamartoma confirmed by pathology in The First Affiliated Hospital of Soochow University from July 2000 to October 2019.

Results： The 13 patients, 11 males and 2 females, aged 48-74 years, mean(63±9)years, were diagnosed with EH. Three of the 13 patients with EH are asymptomatic, others had atypical symptoms. CT showed obstructive pneumonia in 10 of the 13 patients. Among the 13 patients, visible endobronchial tumor were present in 7 patients on CT, and only 3 cases were diagnosed with endobronchial tumor by radiologists. All cases received bronchoscopy. Seven patients were treated via flexible bronchoscopy, using electrocautery, argon plasma coagulation(APC) and cryotherapy. Six patients received pulmonary lobectomy via thoracotomy. Follow-up CT scan was performed in 7 of 13 patients(mean 47 months, range 17-69 months), which revealed no recurrence in all 7 patients.

Conclusion: In clinical work, EH sometimes may be neglected in CT images. Bronchoscopy plays an important role in diagnosis. Pathological study is required to confirm the diagnosis. The management of endobronchial hamartoma should be individualized, bronchoscopic treatment is the first choice for EH. But in some instances, surgery should be considered.

PO-393

Determinants of false-negative results in endobronchial ultrasound-guided transbronchial needle aspiration

Liu,Yangli、Liao,Huai、刘杨丽
First Affiliated Hospital of Sun Yat-sen University

Objective: To reduce the false-negative diagnosis of Endobronchial ultrasound-guided transbronchial needle aspiration (EBUS-TBNA) is a good way to improve its diagnostic efficiency. We present our experience with EBUS-TBNA in an evaluation of the cases with a negative diagnosis in the procedure and analyze the factors that may limit the diagnostic yield.

Methods: EBUS-TBNA procedures performed at our institution between September 1, 2012 and May 30, 2016 for enlarged mediastinal or hilar lymphadenopathy were retrospectively analyzed. Negative EBUS-TBNA results were recorded. Determinants of false-negative results including subject age, gender, disease species, sampling site distribution, short axis of largest Lymph node and number of needle passes per subject were collected were determined by multivariate logistic regression.

Results: A total of 328 subjects underwent EBUS-TBNA during the study period, 64 subjects got a negative result and the failure rate was 19.5%. False-negative results were related to subject age (P=0.013), disease species (P<0.01), lymph node location (P=0.098), and largest lymph node size(P=0.005). In the multivariate analysis, disease species (P<0.01) and lymph node size (P=0.004) were statistically significant risk factors for false-negative results. Subjects with benign lymphadenopathy and small lymph node(≤2cm) exhibited a significantly higher false negative result [OR 3.86 (2.06-7.24) and OR 2.36 (1.32-4.21), respectively].

Conclusion: To decrease the false-negative rate of EBUS-TBNA, the indication for disease categories, site and size of the sampling lymph node should be better chosen.

PO-394

Effect of Bilevel positive airway pressure ventilation on procedural success of talc poudrage in patients with malignant pleural effusion

Ekpumimas,Kulachat、Wattanatham,Anan
Phramongkutklao hospital

Objective: To evaluate the benefits of post-pleurodesis Bilevel positive airway pressure ventilation (BiPAP) administration in patients with symptomatic malignant pleural effusion after talc poudrage.

Methods: In this open-label, single-centered, randomized control trial, we randomly assigned (1:1) 24 patients with symptomatic malignant pleural effusion who are eligible for talc poudrage to receive post-pleurodesis Bilevel positive airway pressure ventilation(BiPAP) for at least 2 hours or routine post-pleurodesis care. The primary endpoint was pleurodesis success rate which was assessed by chest x-ray at 4th week after pleurodesis. The secondary endpoints were post-pleurodesis intercostal drainage duration, and other predicting factors for pleurodesis failure.

Results: Between June 2016 – June 2018, we enrolled 24 patients: 12 allocated to Post-pleurodesis BiPAP administration and 12 allocated to Routine Post-pleurodesis care. In total population, the pleurodesis success rate at 4th week was 62.5%. The 4th week- pleurodesis success rate of Post-pleurodesis BiPAP administration group was 66.7% compared with 58.3% of routine Post-pleurodesis care group without statistical significance (p = 1.0). There was no difference in intercostal drainage duration between two group (5 days versus 4.92 days in control group and Post-pleurodesis BiPAP group, respectively, p = 0.926). We found that Low pleural glucose and low pleural pH were reliable predictors for pleurodesis failure. Pleural glucose < 100 mg/dL had sensitivity and specitivity to predict pleurodesis failure of 100% and 70.6% respectively (AUC = 0.861; 95%CI, 0.712 to1.000; p =0.002). All of the patients could tolerate the BiPAP through 2 hours of administration without any major complications.

Conclusion: In patients with symptomatic malignant pleural effusion, Post-pleurodesis BiPAP administration did not improve pleurodesis success rate and had no benefit on shortening intercostal drainage duration. Low pleural glucose (<100mg/dL) and low pH (<7.45) may be reliable predictors for pleurodesis failure.

PO-395

3-CASES ANALYSIS OF MEDIASTINAL INFECTION AFTER ENDOBRONCHIAL ULTRASOUND-GUIDED TRANSBRONCHIAL NEEDLE ASPIRATION

Zhang,Yingwei1、Zhao,Qi1、Wang,Yang2、Wang,Ping3、Yu,Min1、张英为
1. Department of Pulmonary and Critical Medicine， Nanjing Drum Tower Hospital， The Affiliated Hospital of Nanjing University Medical School
2. Department of Radiology， Nanjing Drum Tower Hospital， The Affiliated Hospital of Nanjing University Medical School
3. Department of Pulmonary and Critical Medicine， Xi’an Aerospace General Hospital

Objective: In recent years, transbronchial needle aspiration guided by real-time ultrasound bronchoscopy (EBUS-TBNA) has been widely used in clinical work. The reason for its popularity lies in its mini trauma, high diagnosis rate and few complications. However, few complications don’t mean no complication. Here, we reported three-case mediastinal infection after EBUS-TBNA, in order to enhance the recognition of the complications after EBUS-TBNA.

Methods: We retrospectively analyzed the clinical data of three cases with mediastinal infection after EBUS-

TBNA in our hospital since 2015.One case was mediastinitis and the other two cases were pericarditis. Also literature was reviewed.

Results: Case 1 A 59-year-old man with enlarged lymph nodes and low-density mass in the mediastinum underwent endobronchial ultrasound-guided transbronchial needle aspiration (EBUS-TBNA) in the clinic. He got a middle-grade fever right after EBUS-TBNA was performed and was admitted 3 days later. CT scan showed pneumomediastinum. Later, CT scan showed pericardial and pleural effusions. During hospital stay, he accepted pericardiotomy because of circulatory unsteadiness. Eventually, he recovered and discharged. Case 2 A 54-year-old woman with enlarged lymph nodes in the mediastinum and some cloudy opacity in right lower lobe underwent endobronchial ultrasound-guided transbronchial needle aspiration (EBUS-TBNA). Her diagnosis was sarcoidosis (stage II) and was treated with oral prednisone. She got a fever and out of breath 50 days after EBUS-TBNA was performed. CT scan showed pericardial effusions. During hospital stay, she accepted pericardiotomy because of uncontrolled pericardial effusion. Eventually, she recovered and discharged. Case 3 A 64-year-old man with enlarged lymph nodes and low-density mass in the mediastinum underwent endobronchial ultrasound-guided transbronchial needle aspiration (EBUS-TBNA) in the hospital. One day before EBUS-TBNA, He got a middle-grade fever. After treatment, his temperature was normal on the day of EBUS-TBNA. However, he got a high fever right after EBUS-TBNA was performed. CT scan denoted newly-appeared low-density zone in the mediastinum. He was treated with broad-spectrum antibiotics immediately. Eventually, he recovered and discharged.

Conclusion: Although the incidence of complications of EBUS-TBNA is low, some scholars still paid attention to and reported the adverse reactions related to this technique. At the same time, some scholars believed that the low rate of complications may be related to the underreporting . It is very important to improve the diagnostic consciousness of the postoperative complications of EBUS-TBNA, to observe the patients after EBUS-TBNA closely, to discover the possible complications in time, and to deal with them properly and timely!

PO-396

A case report of malignant myopericytoma of the trachea

Wu,Weijing、Hong,Lingling、Zhang,Huaping、Wu,Chunlin
Department of Respiratory and Critical Medicine， the Second Affiliated Hospital of Fujian Medical University.

Objective: Myopericytoma is a rare, usually benign soft tissue tumor that occurs mostly in the dermis and subcutaneous soft tissues of the lower extremities.We report a case of a low-grade malignant MPC located in the trachea.

Methods: A 64-year-old male who presented with recurrent asthmatic attacks for more than a month was admitted to our hospital on October 20, 2014.During the hospitalization, interventional therapy under bronchoscopy was mainly performed. After using a snare device to remove part of the tumor tissue, and argon gas knife cauterized the residual tumor tissue to stop bleeding, the patient's cough and asthma symptoms improved significantly,

Results: The pathology report (upper segment of the trachea) was low-grade malignant myopericytoma.The patient's cough and asthma symptoms improved significantly.

Conclusion: Most myoblastomas are benign tumors, and surgical resection is the main treatment.This case also suggests that bronchoscopic interventional therapy can also be used as an option for the treatment of tracheal myoblastoma.

PO-397

CLINICAL OUTCOMES WITH 3D PATIENT SPECIFIC AIRWAY STENTS COMPARED TO COMMERCIALLY AVAILABLE AIRWAY STENTS

Aravena Leon,Carlos1、Inaty,Hanine2、Urbas,Adrianna3、Grafmeyer,Keith3、Machuzak,Michael2、Sethi,Sonali2、Gildea,Thomas2

1. Universidad Cat ó lica de Chile
2. Cleveland Clinic Foundation
3. Custom Orthopaedic Solutions

Objective: Due to limited shapes and sizes, commercially available airway stents (CAS) poorly fit in patients with complex airways. They can cause a variety of complications. However, an experienced bronchoscopist can customize a CAS to make them suitable for a difficult airway. A patient-specific silicone stent (PSS) may minimize complications, improve quality of life, and reduce the need for repeated procedures. We describe clinical outcomes with both the placement of PSS and previously placed CAS in the same patient to assess if the PSS is as safe and effective as CAS

Methods: Medical records and bronchoscopy reports of all patients who received PSS at Cleveland Clinic under FDA expanded access were reviewed from one year back the PSS was placed to the finish of the study period. Interventional Pulmonologists involved in the procedures were asked to complete a survey related to stent loading, deployment, removal, and general patient improvement. Two physicians graded Stent-related adverse events (AE's) based on the Common Terminology Criteria for Adverse Events (CTCAE) scoring system

Results : 13 PSS were placed in 4 patients. No difference was described to load, place, or remove the PSS ($p > 0.05$). The bronchoscopists noted that there was a significant clinical improvement after the PSS was placed ($p = 0.03$). The average lifespan of the PSS was significantly higher than the CAS (300.2 days vs. 124.0 days, $p < .001$). The average duration between bronchoscopies was significantly longer with PSS than with CAS (65.6 days vs. 36.6 days, $p = 0.004$). Furthermore, PSS also experienced a lower severity of migration ($p = 0.0225$). All other AEs were not statistically different between the two groups

Conclusion: While AE's are a good measure of safety, stent lifespan has a direct correlation with the effectiveness of the stent that was implanted. The reasons to change a stent are severe AEs or lack of clinical improvement. Since AE's severity and rate showed to be minimally different, it is likely that PSS improved patient quality of life and breathing symptoms in the form of a higher PSS lifespan and time between procedures. Patient-specific stents may have a role in patients decreasing symptoms and improving quality of life

PO-398

Application of EB-OCT in the formation of benign airway stenosis in rabbits

Liu,Yuehong、Jiang,Junhong、Yuehong Liu
The First Affiliated Hospital of Soochow University

Objective: We found that the main cause of post-traumatic stenosis was cartilage destruction, and the types of stenosis were divided into mucosa destruction and cartilage destruction. At present, the main diagnostic methods for benign airway stenosis are CT and bronchoscopy. However, the judgment of stenosis type depends on histopathological judgment. Optical coherence tomography (OCT) is a new technique. Using interference imaging technology, it can provide a cross-sectional view of the microstructure under the surface of biological tissue. We used the method of tracheal mucosal injury combined with cartilage injury to establish a rabbit model of tracheal stenosis, and used EB-OCT to dynamically observe the formation of benign airway stenosis, providing a new diagnostic means for further study of the mechanism and treatment of benign airway stenosis.

Methods: Tracheal mucosal injury combined with cartilage destruction (incision of tracheal wall, injury of tracheal mucosa with a brush, and injury of cartilage with a vascular clamp) was used to injure the tracheal wall of 12 rabbits. The rabbits were observed under bronchoscope at 2, 4, 6 and 8 weeks after operation, and scanned by EB-OCT. Three rabbits were sacrificed and pathological specimens were obtained at each time. Compare OCT image and pathological image for consistency.

Results: (1) EB-OCT images were consistent with the follow-up findings under bronchoscope; (2) The changes of EB-OCT images during the postoperative follow-up of rabbit airway stenosis were consistent with the pathological histology, and the two images were completely matched. Cicatricial contracture and granulation hyperplasia were observed around the operation. Six weeks after the operation, the scar contracture was obvious and the stenosis was relieved. Scar contracture was found 8 weeks after the operation, and the stenosis of the lumen was further relieved.

Conclusion: (1) Injury of tracheal mucosa and cartilage is the key factor of benign airway stenosis in rabbits. The main types of stenosis are granulation and scar contracture. (2) EB-OCT images matched with histopathological images completely. (3)EB-OCT can dynamically observe the formation process of benign airway stenosis, and its image appearance is consistent with the pathological histology, which can well distinguish the destruction of mucosa and cartilage and the degree of both destruction.

PO-399

Cell-free DNA from bronchoalveolar lavage fluid (BALF) for the identification of lung cancer: A new medium of liquid biopsy

Wang,Changguo、Jiang,Junhong
The First Affiliated Hospital of Soochow University

Objective: Differentiating malignant lung tumors from solidary pulmonary nodules is still a great challenge. cfDNA-based plasma testing has been developed for the purpose of screening and diagnosis. However, due to the limited amount of ctDNA present in early stage lung cancer patients, the sensitivity of such tests is limited. Bronchoalveolar lavage (BAL) is a technique for sampling the epithelial lining fluid of the respiratory track. Limited evidences support the use of BAL fluid (BALF) for lung cancer diagnosis. This study interrogates the potential of using BALF for lung cancer diagnosis.

Methods: 52 patients with solid pulmonary nodules (≤2cm in diameter) at department of respiratory medicine of the first affiliated hospital of soochow university were enrolled, including 45 patients with solitary pulmonary nodule at initial diagnosis and 7 patients with small pulmonary nodule at advanced stage. Among the 45 patients, 30 patients underwent curative surgery, 3 patients had confirmed benign nodules by TTNA or follow-up , 12 with uncertain nodules for the present . tissue and BALF samples were obtained for mutation profiling using a panel consisting of 168 lung cancer related genes. At the same time, some BALF samples were subjected to DNA methylation profiling.

Results: Of the 30 patients underwent surgery, 24 malignant nodules and 6 benign nodules. First, we performed consistency analysis between matched tissue and BALF samples from patients with malignant tumors (N=31, including patients with metastatic or relapsed disease). 93.5% (29/31) and 64.5% (20/31) patients had mutations detected from their tissue and BALF samples, respectively, resulting in a concordance of 71%. 83 and 59 mutations were detected from tissue and BALF samples, respectively. Using tissue samples as references, BALF samples revealed 20 new mutations and missed 44 mutations. Next, we evaluated the performance of BALF cfDNA mutation profiling in differentiating malignant or benign pulmonary nodules(≤2cm in diameter). 24 patients with malignant nodules and 9 patients with confirmed benign nodules were included for this analysis. BALF cfDNA mutation profiling resulted in a sensitivity of 63%, specificity of 100%, positive predictive value (PPV) of 100% and negative predictive value (NPV) of 50%. In addition, we also found that the total volume of BALF were significantly correlated with the amount of cfDNA extracted from patients.

Conclusion : BALF cfDNA profiling demonstrates good performance in distinguish small malignant tumors (≤2cm in diameter) from benign pulmonary nodules, thus having the potential to serve as a diagnostic tool.

PO-400

Interventional bronchoscopy for the treatment of surgery related complications

Tonn,Hermann、Beck,Klaus、Freundt,Tobias、Schneider,Klaus-Dieter、Schoenhofer,Bernd
KRH Siloah Hannover

Objective: Surgical intrathoracic interventions can lead to severe complications like tracheo-bronchial stenosis and/or tracheal-bronchial malacia and diverse types of fistulas. If surgical re- intervention is not feasable, bronchoscopy offers several options of treatment. We reviewed patients from July 1993 till May 2019 who were referred from various surgical departments to our department.

Methods: Interventional bronchoscopies of 24 patients (5 women, 19 men, mean age 51,9 years, range 18 – 80 years, July 1993 till May 2019, follow-up till November 2019) were restrospectively analyzed. The surgery related complications consisted of stenosis/malacia (6 patients) and various kinds of fistula in different locations (18 patients). Bronchoscopic interventions used stents of different types (Dumon™ silicone stent, Freitag dynamic™ stent) for stenosis and malacia. For the closure of fistulas stents (silicone, covered metallic stents, Ultraflex™, aerstent®) EWS® spigots and Amplatzer® vascular plugs were inserted depending on the localisation and type of the fistula. There were early stenosis and fistulas (within 4 weeks after the first operation) and chronic lesions.

Results: Out of 24 patients 14 could be treated successfully. 3 out of 11 patients could be weaned from the ventilator. In the subgroups all 6 patients with a stenosis could be treated successfully. Whereas only 7 (39 %) out of 18 patients with fistulas could be treated successfully, meaning significant reduction of symptoms. Especially in the early fistula group of the main bronchi after pneumonectomy not a single patient out of 5 could be successfully treated. All patients were in a critical respiratory status due to constant aspiration, and secondly the sealing was complete only in one patient. All three patients with chronic fistulas after right pneumonectomy could be sealed with vascular plugs. Concerning stenosis/malacia technically stent implantation was always technically possible. The closure of fistulas was more crucial and not always successful, because the closure was sometimes incomplete. Some patients in whom

bronchoscopic intervention failed, died from respiratory and/or multiorgan failure. For the long term survivors change of devices was necessary in the course of time.

Conclusion: If a surgical re-intervention is no further option for the treatment of surgical related complications interventional bronchoscopy can offer a possible alternative. Stents, spigots and vascular plugs can be chosen depending on the type of lesion and location. Anatomical changes due the surgical procedure are challenging

PO-401

The bronchodilator responses in asthma accessed by endobronchial optical coherence tomography

Zhou,Zi-Qing
Guangzhou institute of respiratory health

Objective: Explicating of bronchodilator responses in asthmatic patients with endobronchial optical coherence tomography.

Methods: We performed EB-OCT measurements and spirometry in 32 asthmatic patients before and after salbutamol inhalation. EB-OCT scanning was conducted immediately (within 1 min) after inhaling 400 μg salbutamol (denoted as baseline EB-OCT measurement). Thereafter, EB-OCT imaging was performed at 5-min intervals (up to 15 min) to directly determine the dynamic airway morphological changes. The continuously accessed airway inner area corrected for the body surface area (Ai/BSA) and airway wall area percentag (Aw%) were analyzed. Spirometry was performed at 60 min after salbutamol inhalation (post-bronchodilation test).

Results: Sixteen patients with moderate asthma and 16 with severe asthma were recruited. Salbutamol inhalation led to a significant improvement not only in FEV1, FVC and FEV1/FVC, but also the small-airway spirometric parameters including MMEF, MEF25 and MEF75. The clear airway images shows that bronchodilation indeed occurred both in the Ai/BSA in medium-sized (Ai/BSA3-6, from 2.62±1.06 to 3.38±1.10 mm2/m2) and small airways (Ai/BSA7-9, from 1.00±0.37 to 1.40±0.38 mm2/m2) after salbutamol inhalation (All $P<0.05$). Aw% of medium-sized and small airways did not change significantly at 15 min after bronchodilation . The magnitude of increase in Ai/BSA3-6, but not Ai/BSA7-9, Aw%3-6 or Aw%7-9, correlated positively with the improvement in FEV1 ($r=0.636$, $P<0.01$) and FVC ($r=0.506$, $P<0.01$) at 15 min after salbutamol inhalation.

Conclusion: Salbutamol inhalation results in a bronchodilation in both medium-sized and small airways. But medium-sized airways contributed to the critical target locations that responded most prominently to bronchodilators in asthma.

PO-402

Effect of bedside fiberoptic bronchoscopy on the prognosis of ICU patients with severe pneumonia

Guo,Ying、Zhang,Jian
Affiliated Hospital of Hangzhou Normal University

Objective: To evaluate the prognostic value of bedside fiberoptic bronchoscopy in ICU patients with severe pneumonia.

Methods: 60 patients with severe pneumonia admitted to the ICU of our hospital from August 2017 to October 2019 were randomly divided into control group (30 cases) and experimental group (30 cases). The control group was treated with conventional anti infection, fluid resuscitation, mechanical ventilation, nutritional support and other symptomatic treatment. The experimental group was treated with alveolar lavage by bedside fiberbronchoscope on the basis of the control group, and the patients in the two groups were recorded .The results showed that: leukocyte, procalcitonin, interleukin-6, hypersensitive C-reactive protein, arterial oxygen partial pressure, arterial carbon dioxide partial pressure, arterial oxygen saturation, mechanical ventilation time, ICU hospitalization days, antibiotic use time. The difference of each index among the groups was compared. The classified variable was expressed as a percentage of the total sample, and the continuous variable was expressed as mean ± standard deviation. Chi square test was used for the comparison between groups of classified variables.Statistical method was selected for the comparison between groups of continuous variables according to the distribution.Normal distribution use t test, non normal distribution select non parameter test. When $p < 0.05$, the difference was statistically significant.All data were analyzed by spss26.0.

Results: The levels of leukocyte (8.23 ± 4.10), procalcitonin (26.5 ± 9.21), interleukin-6 (35 ± 6.37), hypersensitive C-reactive protein (154 ± 10.8), ICU hospitalization days (10.4 ± 3.7), mechanical ventilation time (7.54 ± 3.21) in the experimental group were lower than those in the control group ($P < 0.05$). The arterial oxygen partial pressure (85.9 ± 4.30) and arterial oxygen saturation (84.5 ± 3.71) in the experimental group were higher than those in the control group and the partial pressure of arterial carbon dioxide (38.7 ± 6.28) was lower than that of the control group .There was statistical significance in all $P < 0.05$ .There was no significant difference in antibiotic use time and arterial pH between the two groups ($P > 0.05$).

Conclusion: Bedside fiberoptic bronchoscopy has a significant effect on the prognosis of ICU patients with severe pneumonia, which can shorten the time of mechanical ventilation and ICU hospitalization, reduce the time of antibiotic use, and improve the prognosis of patients.

PO-403

Explore the role of airway wall injury in the formation of benign airway stenosis in rabbits

Zhang,Jie、Jiang,Junhong
The First Affiliated Hospital of Soochow University

Objective: To explore the role of tracheal wall injury in the formation of benign airway stenosis in rabbits.

Methods: We used four different methods to damage the tracheal wall of 28 New Zealand white rabbits in order to develop benign airway stenosis. Experimental groups comprised: Group 1 (n=7,the tracheal mucosa was damaged slightly), the 7 subjects' tracheal mucosa was damaged mildly by ordinary brush under bronchoscope; Group 2 (n=7,the tracheal mucosa was damaged severely),the 7 subjects' tracheal mucosa was damaged severely by nylon brush after tracheotomy; Group 3 (n=7,the tracheal cartilage was damaged after incise the tracheal), the 7 subjects' tracheal cartilage was injured with vascular clamp after tracheotomy; Group 4 (n=7,the tracheal mucosa and cartilage were

damaged after tracheotomy) ,the 7 subjects' tracheal mucosa was injured with a nylon brush and tracheal cartilage was damaged by vascular clamp. Tracheal endoscopy was performed on each experimental rabbits at the 1st, 2nd, 3rd and 4th weeks after operation. In the fourth week, we executed the experiment rabbits after Multi-slice spiral computed tomography scan. The formation rate and type of tracheal stenosis were compared among four groups.

Results: No animals in Group 1 developed stenosis. In Group 2, 28.57% of subjects developed tracheal stenosis. Two rabbits with tracheal stenosis in Group 2 developed granulation tissue at 1st, 2nd, and 3rd week after operation and one of the rabbits with granulation tissue formed scar contracture at 4th week postoperative. Fourteen rabbits in group 3 and 4 developed tracheal stenosis due to granulation tissue proliferation at 1st, 2nd, and 3rd weeks. However, 71.4% of rabbits with tracheal stenosis formed scar contracture at 4th week after operation,7.1% of rabbits with tracheal stenosis had granulation tissue proliferation and scar contracture.

Conclusion: Granulation tissue proliferation and scar contracture are the two types of benign airway stenosis after tracheal trauma in rabbits. Injury of cartilage and perichondrium are the key factor of benign airway stenosis. The possibility of forming airway stenosis by injuring tracheal mucosa is small, chronic persistent injury of tracheal mucosa may aggravate the degree of airway stenosis on the basis of cartilage destruction.

PO-404

A Case of Total Resection of Typical Endobronchial Carcinoid Tumor with Rigid Bronchoscopy A Mimic of Asthma

Rizk,Ayman、Ayman Rizk
alex police hospital

Objective: According to the 2015 World Health Organization Classification of Lung Tumors; carcinoid tumors are neuroendocrine tumors. Neuroendocrine tumors (NTs) are classified into the well differentiated [pulmonary carcinoids], (low-grade typical carcinoid, and intermediate-grade atypical carcinoid) and the poorly differentiated (high-grade large cell neuroendocrine carcinoma and small cell carcinoma).(1) Most common site of carcinoid tumors is GI tract (64%), next is respiratory tract (28%).(2)

Methods: A 25-year old lady complained of dyspnea with wheezes for about one year that started during her 2nd trimester and attributed to her pregnancy. Her dyspnea persisted after delivery. Wheezes had no relation to physical exertion. She was treated as bronchial asthma with bronchodilators and steroids, both oral and inhaled but without any improvement.

Results: A Case of Total Resection of Typical Endobronchial Carcinoid Tumor with Rigid Bronchoscopy A Mimic of Asthma

Conclusion: A Case of Total Resection of Typical Endobronchial Carcinoid Tumor with Rigid Bronchoscopy A Mimic of Asthma

PO-405

The novel airway stent delivery system versus standard airway stent delivery system in treatment of patients with malignant central airway stenosis, a multi-center, randomized, parallel-group, superiority trial

Jiang,Junhong1、Lv,Xuedong2、Cheng,Zhaozhong3、Chen,Chengshui4、Wang,Jiwang5、Robert,Browning6、Wang,Kopen7、Ke,Mingyao8、Huang,Jianan1

1. The First Affiliated Hoapita of Soochow Universty
2. Nantong First People 's Hospital
3. Affiliated Hospital of Qingdao University
4. The First Affiliated Hospital of Wenzhou Medical University
5. Jiangsu Province Hospital
6. Walter Reed National Military Medical Center
7. Johns Hopkins University
8. Xiamen Second People 's Hospital

Objective: Self-expandable metallic (SEM) airway stents are an important approach to treat malignant central airway obstruction (CAO). We designed a novel delivery system of the through-the-scope (TTS) SEM airway stent, which can be directly implanted into the airways through the working channel of the flexible bronchoscope. Clinical superiority of the TTS delivery system stent versus standard delivery system (Nanjing Micro-Tech company) with respect to the operation way is unknown.

Methods: In this multi-center randomized, parallel-group, superiority study, we enrolled patients with malignant central airway obstruction from 6 sites in China where pulmonologists skilled in deploying standard SEM stent. The main inclusion criteria of this trial was that the airway stenosis grade was more than 50% with dyspnea and age range from 18-75 years .The study was expected to enroll 144 patients who were randomly assigned (2:1) to place TTS stent (experimental group) or standard stent (Nanjing Micro-Tech company) (control group) by the simple randomization. The whole operation procedure was videotaped. The primary endpoint was operation time of airway stent implantation. Secondary endpoint was the successful rate of the release stent and the effectiveness and safety of the stent. This study is registered with the Chinese Clinical Trial Registry, number ChiCTR-IOR-17011431.

Results: From May 15, 2017 to December 30, 2018, 146 patients were enrolled, we analyzed 146 patients data from six sites, 87 patients were randomized to the TTS-group and 42 to OTW-group. The operation time in experimental group 1.74±1.13（min）vs in control group 4.21±1.85（min）(95%CI -2.48[-2.98, -1.97],p=0.000) There was no significant difference in the age, gender ,stent placement, stent size between the experimental group and the control group.

Conclusion: The TTS SEM stent is as effective and safe in the treatment of malignant central airway obstruction as compared with the standard SEM stent. The TTS delivery system SEM airway stent is superior to the standard delivery system in operation time. TTS stent deployment and placement is clinically easier to deploy by most bronchoscopists.

PO-406

Application of respiratory training in ultrasonic bronchoscopy-guided downstream bronchial needle suction biopsy

Zou,Meihong
Department of Respiratory Medicine, First Affiliated Hospital, Nanchang University

Objective: To explore the application effect of respiratory training in ultrasonic bronchoscopy-guided downstream bronchial needle suction biopsy

Methods: The patients who were randomly assigned 120 routine ultrasound bronchoscopy to guide the downstream bronchoscopy were randomly divided into observation group and control group, each group of 60 cases, the control group was given routine care, the observation group gave preoperative breathing training on the basis of the control group, and compared the number of coughs, puncture times, pain score, and biopsy success rate of 2 groups.

Results: Preoperative breathing training can significantly reduce the number of patients coughing, shorten the operation time of the bronchoscopy needle siphone, improve the success rate of biopsy, reduce the patient's pain.

Conclusion: Nurse's surgery in the "suction" - "call" guided language can make patients follow the instructions for rhythmic mouth breathing, on the one hand can give the patient emotional support and encouragement, so that the patient's psychological relaxation, through self-regulation, active participation in the surgical process, can be well coordinated with the adverse reactions of cough, nausea, argon and other adverse reactions in the operation, reduce the operation Stress response, reduce pain, on the other hand can reduce the performance of the respiratory muscle, chest sphincter remains stable, reduce the pressure of blood vessels in the lungs, in order to facilitate the lesions back and forth puncture, needle-absorbing tissue, increase the tacit understanding between the doctor, care, patients, improve the success rate of puncture ($P < 0.05$).

PO-407

Diagnostic value and safety evaluation of ultrasound-guided bronchoscopy needle biopsy in elderly patients with lung shadow

Zhou,Jianping、Ni,Lei、Shen ,Jimin、Dai,Ranran、Bao,Zhiyao、Sun,Xianwen、Tang,Wei、Chen,Wei、Xiang,Yi、Ding,Yongjie、Zhou,Min、Li,Qingyun
Department of Respiratory and Critical Care Medicine, Ruijin Hospital, Shanghai Jiao Tong University School of Medicine, China.

Objective: To evaluate the diagnostic value and safety of endobronchial ultrasound-guided transbronchial needle aspiration (EBUS-TBNA) in elderly patients with unexplained lung shadows.

Methods: A retrospective analysis of 1206 elderly patients aged 65 years or older who underwent EBUS-TBNA from December 2009 to November 2019 in the Thoracic Interventional Center of Ruijin Hospital was performed. All patients underwent chest CT or PET-CT, which revealed a shadow of the lungs with or without a hilar or mediastinal lymphadenopathy, and/or a paratracheal or parabronchial mass.

Results: Among all 1206 patients, the mean age was 69.8±4.0 years old. By EBUS-TBNA, 883 cases (73.3%) were diagnosed as malignant diseases and 322 cases (26.7%) were benign diseases. The total number of puncture lesions was 286, of which 538 were lymph node punctures, and the average number of punctures per lymph node was 2.4; the total number of punctures in the lungs was 1790, and the average number of punctures per lesion was 2.9. The

sensitivity, specificity, positive predictive value, and negative predictive value of EBUS diagnosis were 86.3%, 100%, 100%, and 48.7%, respectively.The overall tolerability of all elderly patients was comparable. Only 12 patients had early termination due to poor tolerability, and 105 (8.7%) patients had minor complications after surgery.

Conclusion: EBUS-TBNA has a certain diagnostic value for both benign and malignant lesions in elderly patients with lung shadow, and it also has high safety.

PO-408

Mycobacterial tuberculosis culture positive from Endobronchial Ultrasound-Guided Transbronchial Needle Aspiration in HIV/AIDS Patients

Zhou,Jianping、Hu,Yun、Yan,Tianli、Chen,Wei、Xiang,Yi、Li,Qingyun
Department of Respiratory and Critical Care Medicine, Ruijin Hospital, Shanghai Jiao Tong University School of Medicine, China.

Objective: Intrathoracic lymphadenopathy (LAD) occurs frequently in patients with Human Immunodeficiency Virus (HIV) infection. It has been demonstrated that 35% of patients with HIV infection have intrathoracic LAD on routine computed tomography (CT) scan, with mycobacterial infections being a relatively common cause along with malignancies (lymphoma, primary lung cancer). According to previous reports, the incidence of mediastinal tuberculous lymphadenitis in HIV positive patients ranges from 17% to 60%, while in HIV negative it is only 3%-23%. To my knowledge, there is only one published article exploring the utility of Endobronchial Ultrasound-Guided Transbronchial Needle Aspiration (EBUS-TBNA) in diagnosis of intrathoracic LAD in patients with HIV up to now.

Methods: We, herein, report several cases of mediastinal tuberculous lymphadenitis in two newly diagnosed HIV patients.

Results: Tuberculosis is one of the most common opportunistic infection in patients with AIDS and the incidence in this group is 500 times greater than the general population. Co-infection with Mycobacterium tuberculosis impairs HIV-specific T cell function, and favors disease progression. So early diagnosis is of great concern. HIV-associated tuberculosis has atypical radiological presentation, mediastinal adenopathy is more likely to appear in significant immunocompromised patients. Chest CT is a sensitive tool to reveal LAD but does not provide pathogenic evidence. CT scan shows that 2R, 4R and 10R lymph node groups are usually invaded in mediastinal tuberculosis. Central necrosis is usually present in lymph nodes with a diameter greater than 2cm, more especially in Station 4R. Ultrasound imaging of mediastinal tuberculous nodes often reveal the absence of the clustered formation and the presence of necrosis sign. The positive rate of tuberculin test is low because of inhibition of cellular immunity and allergic reactions; only 20%-40% of the patients report positive tuberculin skin tests [9], while sputum-positivity is only 50%-60%. Therefore, lymph node biopsy and transbronchial needle aspiration are needed to enhance the diagnosis rate.

Conclusion: This is crucial for immunocompromised person because minimally invasive surgery may reduce the risk of further infection. Complications are rare, but it should be noticed that smear-positive bloody sputum may develop after EBUS-TBNA, so temporary isolation following EBUS-TBNA should be considered.

PO-409

Endobronchial treatment of upper tracheal squamous cell carcinoma – a case report

Zhou,Jianping、Du,Wei、Li,Ning、Xiang,Yi、Li,Qingyun
Department of Respiratory and Critical Care Medicine, Ruijin Hospital, Shanghai Jiao Tong University School of Medicine, China.

Objective: Primary tracheal tumour is rare. The most common malignant primary tracheal tumours are squamous cell carcinomas and adenoid cystic carcinomas. Primary squamous cell carcinomas of the trachea are more common in smokers. Patients usually remain asymptomatic until haemoptysis, cough, hoarseness, stridor occur as a result of local progression of the disease. Thus tracheal tumours are usually diagnosed at an advanced stage. Interventional pulmonology now allows for endobronchial resection of tracheal tumours.

Methods: We herein describe a patient with tracheal squamous cell carcinoma with lymph node metastasis.

Results: A 70-year-old female patient, non-smoker, was admitted to our department with a two-month history of cough with intermittent hemoptysis and worsening hoarseness of voice. She reported increasing dyspnea during the previous two weeks. Physical examination revealed a 1.8×1.0 cm firm and mobile right supraclavicular lymph node. An ultrasound-guided fine needle aspiration of the node was done. A CT scan thorax done on admission showed irregular thickening of the proximal tracheal wall with paratracheal soft-tissue mass extending to the oesphagus. Flexible fiberoptic bronchoscopy was performed in the bronchoscopy suite under conscious sedation. No paralysis of the vocal cords was noted. A diffuse nodular lesion mass was seen originating from the left lateral wall of the upper trachea and encompassing approximately ¾ of the tracheal circumference, causing about 75% narrowing of the lumen. The lesion was approximately 3cm in length and was located 5 cm above the carina (Figure 2). The rest of the trachea, the carina and bronchial segments were normal. A cryoprobe (Kooland BB-1.8K) was used for sampling the lesion and initial debulking. Flexible bronchoscopy was repeated under conscious sedation a week later for further ablation and debulking of the lesion using an Olympus coagulation electrode and an electrocautery knife.

Conclusion: To our knowledge, this is the second case report of a patient with primary tracheal squamous cell carcinoma with a metastatic lymph node. Cryotherapy, electrocoagulation, electrocautery or other endotracheal debridement methods like laser, photodynamic therapy or argon-beam coagulation can be used for recanalization followed by chemotherapy and radiotherapy as required.

PO-410

The Role of Bronchoscopy In Smoke Inhalation Injury: Where Are We Now?

Zhou,Jianping、Chen,Wei、Xiang,Yi、Li,Qingyun
Department of Respiratory and Critical Care Medicine, Ruijin Hospital, Shanghai Jiao Tong University School of Medicine, China.

Objective: We chose to review case sheets of patients referred to the Department of Interventional Pulmonology during the past five year for flexible bronchoscopy to evaluate the use of this procedure in patients with smoke inhalation injury.

Methods: We performed a retrospective review of all patients referred to the Department of Interventional Pulmonology from the Burns Unit during a five-year period from November 2014 to November 2019.

Results: The 120 patients included in the study consisted of 20 female patients and 100 male patients. The mean age was 45 (31-63) years. The mean % TBSA was 31.5% (0-93). 102 of the 120 patients presented with soot in the oropharynx; 113 had upper airway mucosal hyperemia and 100 had upper airway edema. ENT examination revealed

bullous mucosa in 114 patients. Out of the 120 patients, rales could be heard in 64 patients, wheezing in 51 and the rest had clear chest auscultation. Initial chest radiography was reported as bilateral increased lung markings in 116 patients, bilateral ground glass opacities in 61, bronchial thickening in 42 and pulmonary edema in 13. Emergency tracheostomy on presentation was performed in 64 patients and the other patients were observed and decision of tracheostomy was taken according to the evolution of clinical signs and symptoms. The mean number of days of hospital stay before bronchoscopy was performed was 9 ± 4.9 days. Repeat flexible bronchoscopy was performed on 4 occasions in 32 patients with Grade 4 injury for bronchial toileting and airway sampling and in 16 with Grade 1 injury who developed pneumonia and required aspiration of secretions.

Conclusion: Since there is no consensus existing up to now pertaining to the diagnosis, grading and prognosis of inhalation injury, clinicians tend to forego bronchoscopy and choose non-invasive techniques like signs and symptoms, chest radiographs for initial diagnosis. It is clear that further prospective studies are required to evaluate the use of bronchoscopy in the diagnosis and management of inhalation injury and to determine whether non-invasive techniques can be used in cases where bronchoscopy is not available or its use is limited for economic reasons.

PO-411

Efficacy and Safety of fibrous bronchoscope alveolar lavage in the treatment of severe pneumonia in adults: A Meta-analysis

Guo,Lianghua、肖建宏 ,XIAO Jian-hong、曾林淼 ,ZENG Lin-miao、宋彬 ,SONG Bin、彭锦芸 ,PENG Jin-yun
Mindong Hospital Affiliated to Fujian Medical University

Objective: To systematically review the efficacy and safety of fibrous bronchoscope alveolar lavage in the intermeddle of severe pneumonia in adults.

Methods: Databases including PubMed, The Cochrane Library (Issue 5,2019),EMbase, CNKI, VIP and WanFang Data were searched to collect randomized controlled trials (RCTs) about iBronchoalveolar lavage in the intermeddle of severe pneumonia in adults from inception to May 2019. Two reviewers independently screened literature, extracted data and assessed the risk of bias of included studies. Then meta-analysis was performed by using RevMan 5.3 software.

Results: total of 26 RCTs involving 2097 patients were finally included. The results of metaanalysis showed that: The overall response rate in fiberoptic bronchoscopy group were higher than that of the control group (OR=5.66, P<0.000 01). Length of stay in the fiberoptic bronchoscopy group were shorter than that of the control group(MD=-7.2, P<0.000 01). Cough relief time in the fiberoptic bronchoscopy group were shorter (MD=-4.02, P<0.000 01). The disappearance time of pulmonary rales in the fiberoptic bronchoscopy group were shorter than that of the control group(MD=-5.70, P<0.000 01). The antipyretic time in the fiberoptic bronchoscopy group were shorter than that of the control group(MD=-2.93, P<0.000 01). All the differences were statistically significant. Side effects show that: Sinus tachycardia incidence rate(OR=32.04, P<0.000 01) and decreased rate of oxygen(OR=27.02, P<0.000 01)the fiberoptic bronchoscopy group were higher than that of the control group.the differences were statistically significant.

Conclusion: Fiberoptic bronchoscopy alveolar lavage combined routine comprehensive treatment of severe pneumonia in adults compared with the conventional comprehensive treatment of severe pneumonia, the total effective rate of the former can improve the patients, shorten the defervescence time, cough reduce time, lung then disappear time and length of hospital stay, Meanwhile, temporary sinus tachycardia and the decrease in the incidence of hypoxic decrease were also brought. The above conclusions need to be verified by more high quality research in the quantity and quality of the research.

PO-412

An unusual case report of TBLB-induced pulmonary cavity and Takotsubo Syndrome

Li,Wentao、Xu,Lina、Li,Yu、Xu,Mingpeng、Ke,Lan、Luo,Liying、Liu,Guangnan、李文涛
The Second Affiliated Hospital of Guangxi Medical University

Objective: As the growing number of therapeutic and diagnostic bronchoscopy procecedures are applied worldwide, a variety of complications is mounting up, but the Takotsubo Syndrome is rarely reported. Now we present one case report about the transbronchial lung biopsy(TBLB)-induced pulmonary cavity and Taktsubo Syndrome, in order to help us to increasingly recognize and identify this condition.

Methods: A 62-year-old woman entered our department on Aug.25.2019 because of a solid mass in her lung. 18F-fludeoxyglucose(18F-FDG) positron emission tomography/computed tomography(PET/CT) showed a 25*28*32mm high-density mass in the left upper pulmonary lobe, with irregular border and contained calcification(SUVmax6.7). She had no any symptoms and any positive signs while physical examination, as well as no smoking, post-menopusal women who had a painful stress since her husband died 3 months ago. Laboratory tests such as Blood Routine Test, Myocardial Enzyme(CK, CK-MB), Troponin I, BNP, PCR, ESR, PCT, ECG etc were normal. The radial probe-endobronchial ultrasound discovered a hypoechoic nodule was at posterior segment of left upper lobe. After successfully obtaining specimens, unfortunately, bleeding and pneumothorax occurred. under directly view, instillating of 20 mL of 1:10 000 adrenaline and using of vasoconstrictors and procoagulants, the haemorrhage was controlled. Further, the pneumothorax was treated via the thoracocentesis. Later, the hemodynamics was not stable, fluctuating between 60-84/35-56mmHg. Chest computed tomography(CT) found a thick wall cavity and a solid mass in the apicoposterior segment of the left lung and some patchy and maculas in both lung, There are no randomized clinical trials to support specific treatment recommendations in TTS. The major objective of in-hospital therapy is supportive care to sustain life and to minimize complications during recovery, and follow-up assessment at 6 months.

Results: According to the diagnostic Criteria for TTS of Mayo clinc and European Society of Cardiology(ESC) and The Inter TAK, the patient has some clinical presentation and characteristics of TTS as following. ja post-menopusal female who had a painful emotional and physical stress （her husband die; complicated with bleeding and pneumothorax and infection after TBLB）ka series of ECG changes (ST-segment depression and T-wave inversion) lan unusual appearance of the left ventricle(LV) with a narrow neck and LV regional wall motion abnormality mcardiac biomarkers elevated(CK, CK-MB, troponin, BNP) nnormal coronary arteries.

Conclusion: This is an unusual case report of TBLB-induced pulmonary cavity and Takotsubo Syndrome, We should learn more ahout TTS in the our daily interventional pulmonology.

PO-413

A life-threatening bleeding successfully controlled with one mainframe and double bronchoscopies:one case report

Li,Wentao、LI,Yu、Xu,Mingpeng、Ke,Lan、Luo,Liying、Liu,Guangnan、李文涛
The Second Affiliated Hospital of Guangxi Medical University

Objective: In the case of an acute masive haemoptysis after biopsy or intervention, losing more than 100ml of blood in few minutes, nothing but suctioning. How should we save successfully a life-threatening bleeding patient undergoing therapeutic procedures and How should we do that can help us save more times to further other practices. Now, the techique is presented here.

Methods: As the increasing number of therapeutic and diagnostic bronchoscopy procecedures are applied worldwide, Unfortunately, in the case of an acute masive haemoptysis after biopsy or intervention, losing more than 100ml of blood in few minutes, nothing but suctioning. The blcoking cather can’t be inserted as well as vasoactive drug can’t be instilled through the working channel of a bronchoscope, let alone withdrawing the bronchoscope to further other practices. Above these limitations displayed, we developed recently one mainframe and double bronchoscopies to overcome these problems and save successfully a life-threatening bleeding patient undergoing therapeutic procedures that can help us save more times to further other practices.

Results: we save successfully a life-threatening bleeding patient undergoing therapeutic procedures.

Conclusion: The technique of one mainframe and double bronchoscopies is more suitable, feasible, economic and effective to control pulmonary haemorrhage in clinical practice, especially some health care facilities where are absent of bronchial arterial embolisation or weak link in surgey or have an one mainframe only.

PO-414

Percutaneous tracheostomy by Ciaglia technique modified by endoscopic guide

Carboni Bisso,Indalecio、Las Heras,Marcos、Huespe,Iv á n、Schverdfinger ,Sofia、Videla,Carlos、Montagne,Juan、Dietrich,Agust í n、Smith,David、Beveraggi,Enrique、San Rom á n,Eduardo
Hospital Italiano de Buenos Aires

Objective: Measurement of the efficiency and survey of the complications associated to percutaneous tracheostomy (PT) guided by videobroncoscopy performed in an Universitary Hospital of High Complexity.

Methods: Retrospective observatory study of period between may 2017 and november 2019 of patients more than 18 years old to whom PT elective guided by videobroncoscopy was performed. Demographic variables were registered, APACHE II and days of mechanic ventilation previous to PT. Efficiency of technique was evaluated based on rate of success in execution, necessity to conversion to an open technique, and complications observed.

Results: 266 procedures were evaluated (167 male and 99 female) in patients with average age of 61 years with a standard deviation (SD) of 18 and APACHE 18 ± 7 SD. Criterion for indication of PT was long weaning in all cases. There were complications in 4,13% (11) of the cases. Minor bleeding was the most frequent complication observed in 5 cases (1,89%), hypotension in 4 cases (1.50%) associated to sedation, transitory hypoxemia and ventricular arrhythmia not sustained in 1 case (0,37%).

Conclusion: PT realization by unique dilator guided by videobroncoscopy was observed as a safe and effective procedure to be performed in intensive care units with low rate of complications.

PO-415

Analysis of occupational exposure to PM2.5 during bronchoscopic thermal ablation

Chen,Kai、Bai,Chong
Changhai Hospital, Second Military Medical University

Objective: To measure the concentration of PM2.5 in the smoke generated by thermal ablation such as laser and high-frequency electric in real time during bronchoscopic procedure, leading to investigate the occupational exposure of PM2.5 from thermal ablation and discuss the effects of different thermal ablation techniques, operating methods and human factors on the PM2.5 exposure to medical staff.

The indoor air samples before and during the operation of bronchoscopy were collected from endoscopy rooms. The real-time relationship curve of PM2.5 mass concentration was recorded. The bronchoscopic laser and high frequency electric therapy were the mainly monitoring objects. The trend and difference of PM2.5 exposure concentration with time under different thermal ablation was studied, while the effect of negative pressure suction on PM2.5 concentration and the influence of human factors under thermal ablation were analyzed.

Results: 1.The concentration of PM2.5 within 60 seconds in the environment after a short time of laser, electrocision or electrocoagulation treatment increased temporarily after a certain delay, and eventually remained the same as the background concentration. The PM2.5 produced by laser ablation was averagely higher than that by electrocoagulation and electrocoagulation. 2.One 45 minutes' bronchoscopic laser therapy was studied, in which the average exposure concentration of PM2.5 was 46.7 ug/m3, which was statistically higher than the background concentration 36.0 ug/m3. Another 38 minutes' bronchoscopic procedure with electrocautery snare and electrocoagulation was monitored, in which the average exposure concentration of PM2.5 was 79.2 ug/m3, which was statistically higher than the background concentration 60.2 ug/m3. 3.The time-dependent curves of PM2.5 concentration within 60 seconds after single laser irradiation were recorded with negative pressure suction on and off respectively. Negative pressure suction could reduce PM2.5 exposure by 70-80%. 4.When two different operators performed laser therapy under the same external conditions, the results showed that there was no significant difference in the average duration between the two groups statistically.

Conclusion: Thermal ablation operation could cause transient elevation of PM2.5 concentration in the environment and increase the overall PM2.5 concentration during bronchoscope operation. The PM2.5 exposure of medical staff operation could exceed the lower limit of mild PM2.5 pollution stipulated by the state. The exposure produced by laser therapy is higher than high frequency electricity. The apply of negative pressure suction device during operation is the key to reduce PM2.5 exposure in thermal ablation, while human factors have little influence on it. Relevant guidelines of occupational protection should be developed.

PO-416

Long-time follow up of a low-grade left pulmonary mucoepidermoid carcinoma by therapeutic bronchoscopy and a literature review

Li,Xiaoxiao、Jiang,Junhong
The First Affiliated Hospital of Soochow University

Objective: Pulmonary Mucoepidermoid Carcinoma (PMEC) is a low-grade malignant neoplasm in child and relatively rare among all lung cancers, The long-time effectiveness of therapeutic bronchoscopy in the treatment of PMEC was investigated.

Methods: Data of one case of PMEC treated by bronchoscope in the first affiliated hospital of Soochow University were retrospectively analyzed. A review of the relevant literature was also performed, data of relevant 20 patients were analyzed.

Results: A 10-year-old female was hospitalized with prolonged fever. Computed tomography of the chest showed a tumor in the left upper lung with associated pneumonia. Biopsies were performed through bronchoscopy, and the diagnosis of a low-grade PMEC was obtained. The tumor was resected by therapeutic bronchoscopy. The next-generation sequencing of neoplasm tissue was performed and only NF2 gene missense mutation was detected. The left main bronchial mucosa was smooth with no neoplasm observed by bronchoscopy after 17 months follow-up .The 13 of 20 patients with low-grade malignant PMEC treated by bronchoscope ,the mean follow-up time was 27 months and the disease did not recur.

Conclusion: Therapeutic bronchoscopy can be used as an alternative treatment for patients with low-grade PMEC who cannot be surgically removed.

PO-417

To study the complications of the TTS stent in the tracheal stenosis of rabbits

Liu,Ziyi、Jiang,Junhong
The First Affiliated Hospital of Soochow University

Objective: We designed a novel delivery system of the through-the-scope (TTS) SEM airway stent and changed end structure of TTS stent showed acute angle, in order to study the incidence of complication about TTS stent.

Methods: 30 New Zealand white rabbits of mature months old weighing 2.5-3.5Kg were randomly divided into group A and group B. Group A was implanted with 6*30mm TTS stent via bronchoscope and group B was implanted with 6*30mm OTW stent . In 2nd week, three experimental rabbits were randomly selected from each of the two groups for bronchoscopy to obtain images and the tracheal specimens were dissected after the experimental rabbits were sacrificed. In 8th week, all the surviving experimental rabbits in group A and group B were examined by bronchoscopy to obtain images and then tracheal specimens were dissected after the experimental rabbits were sacrificed. The difference of granulation hyperplasia after implantation of two stents was studied by observing the morphology of anatomical specimens and pathological examination. Analysis and comparison of granulation tissue hyperplasia in experimental rabbits after implantation of two kinds of tracheal stents have statistical significance ($P<0.05$).

Results: After 8 weeks of experimental observation, a total of 16 TTS stents and 12 OTW stents were included in the analysis. Tracheal morphology of experimental rabbits in group A and group B did not change significantly, and sputum retention was not serious. In group A, granulation hyperplasia mainly occurred at the end of the stent along

the mesh of the stent, without causing obvious lumen stenosis. In group B, large granulation tissue was formed due to granulation hyperplasia, resulting in stenosis of lumen. After 8 weeks of follow-up observation, experimental rabbit granulation tissue hyperplasia resulted in lumen stenosis of more than 30% 6.25%(1/16) in group a and 50%(6/12) in group b, P=0.023(<0.05) which has statistical difference.

Conclusion: TTS stent and OTW stent with the same diameter cause more than 30% stenosis in benign airway stenosis in experimental rabbits. TTS stent is superior to OTW stent.

PO-418

Application of medical thoracoscopy in unexplained pleural effusion

Xia,Shulan、Zhou,Rui
The Second Xiangya Hospital, Central South University

Objective: To evaluate the clinical application of medical thoracoscopy for the diagnosis of unknown origin pleural effusion.

Methods: A retrospective review of 976 patients undergoing a thoracoscopic operation was performed in our Respiratory endoscopy clinic by semirigid thoracoscopy or flexible thoracoscope.

Results: 470 of these 976 patients, were diagnosed to have malignant disease, which include 312 adenocarcinoma cases, 24 squamous carcinoma cases, 8 small cell lung cancer cases, 38 pleural endotheliomas cases, 12 Mammary carcinoma cases, 3 gastrointestinal carcinoma cases, 4 lymphoma cases,7 sarcoma cases,1 renal-cell carcinoma case,1 prostatic carcinoma case,1Cartilaginous tumor case,1Reticulated hemangioendothelioma case,and 58 unclassification mesothelial cell clumps cases. There are 269 tuberculous pleurisy cases, 2 fungi infection cases, 12 non caseating granuloma cases, 32 fibrinous inflammation cases, f1oreign body cases ,18 atresia of pleural cavityand Atresia of pleural cavity and 128 cases non-confirmed.Diagnosis rate was 86.6％ .

Conclusion: Medical thoracoscopy possesses higher positive diagnostic rate and safty. And it has preferable value in clinical application for those unclear causes of pleural effusion.

PO-419

Correlation: analysis of the bronchoscopic signs and pathological results and clinical features of 292 patients with bronchial pigmentation

Xia,Shulan1、Long,Chengfeng2、Zhou,Rui1
1. The Second Xiangya Hospital, Central South University
2. Nanxishan Hospital of Guangxi Zhuang Autonomous Region

Objective: To investigate the pathogenesis,site of lesions,pathological results and clinical significance of Bronchial anthracosis(BAC)/Bronchial anthracofibrosis(BAF)

Methods: A retrospective analysis of the gender,age,patholagical results, clinical features, endoscopic signs and correlation of 292 patients with BAC/BAF.

Results: There was no characteristic clinical manifestation in BAC/BAF patients.The occurrence of BAC/BAF was not related to gender (P >0.05),but related to age,and more seen in people over 60 years old (P<0.05).The predilection sites were right upper lobe, left upper lobe and right middle lobe (P<0.05).There are mainly three types of endoscopic signs: bronchial anthracosis(BAC), pigmentation infiltration type and bronchial anthracofibrosis(BAF). The distribution of the three types of expression under bronchoscopy was related to age (P<0.05).The most common pathological results of biopsy in the lesion site were chronic mucosal inflammation, followed by tuberculosis and lung cancer, and the endoscopic manifestations were correlated with the pathological results (P<0.05).

Conclusion: The specific pathogenesis of BAC/BAF is not clear yet, and its occurrence is positively correlated with age, and the pathogenesis is more extensive with age.No association with sex, tuberculosis infection, or occupational dust exposure history, different types of microscopic manifestations predicted different pathological results.Bronchoscopy is the most important method to discover BAC/BAF.

PO-420

Differences in complications between covered tracheal stents and uncovered tracheal stents in the treatment of airway stenosis of rabbits

Yang,Zhenyu、Jiang,Junhong
The First Affiliated Hospital of Soochow University

Objective: The study of complications of the same diameter covered-metal tracheal stents and round head bare-metal tracheal stents in benign airway stenosis in rabbits.

Methods: The 6*30mm covered-metal tracheal stents and the 6*30mm round head bare-metal tracheal stents were respectively guided by electronic fiber bronchoscope into 18 and 15 of New Zealand white rabbits weighing 2.5-3.5kg,and the upper end of the stents were 2 cm below the glottis.

Results: In the covered-metal tracheal stent group (group A), 18 rabbits were included in the experiment, and in the round head bare-metal stent group (group B) ,there were 15 rabbits included in the experiment. The accumulation of secretion of the rabbits in group A were greater than 90% of the stents cavity,and 14 rabbits survived less than 2 weeks or about 2 weeks. In group B, 4 of the rabbits showed the accumulation of secretion greater than 90% of the stents cavity, and the survival period was less than 1 week or about 1 week.However,the accumulation of secretion of the remaining rabbits were less than 50% of the stents cavity.In group A, 13 rabbits were found to have tracheal deformation, and mainly concentrated at the two ends of the stents. In the experimental group B, no tracheal deformation

was observed (P=0.000029<0.05, Fisher's exact test).In group A, scar contracture can be found in 9 rabbits,but only 2 rabbits in group B,which were also mainly concentrated at both ends of the stents (P=0.034<0.05, Fisher's exact test).

Conclusion: Compared with the round head bare-metal tracheal stents , the covered-metal tracheal stents of the same diameter have a more accumulation of secretion, and the severe accumulation of secretion is one of the main reasons for the short survival of experimental rabbits.Meanwhile, the rabbits implanted with the covered-metal tracheal stents were more susceptible to have deformation and scar contracture, and were mainly concentrated at both ends of the stents.

PO-421

Pilot study of the difference value of C-TBNA and EBUS-TBNA in mediastinal bronchial-derived cysts

Liu,Ziyi、Jiang,Junhong
The First Affiliated Hospital of Soochow University

Objective: To investigate the difference value of Convention-transbronchial needle aspiration (C-TBNA) and Endobronchial ultrasound-guided transbronchial needle (EBUS-TBNA) in mediastinal bronchial-derived cysts.

Methods: A retrospective analysis of clinical data and follow-up data of 27 patients using conventional TBNA techniques and EBUS-TBNA techniques diagnosed as mediastinal bronchogenic cysts from May 2008 to December 2016 in the First Affiliated Hospital of Soochow University.

Results: During 8 years , there are 13 cases of C-TBNA examination and 14 cases of EBUS-TBNA diagnosed mediastinal bronchogenic cysts . C-TBNA extracted clear liquid and the volume of it was 8.9 ± 1.5 ml, 14 patients examined by EBUS had a homogenous anechoic signal, Clear liquid was extracted and the volume of it was 29.1 ± 7.5 ml. The cyst liquid with EBUS-TBNA extraction was significantly more than that with C-TBNA (P < 0.05).During the follow-up, 1 patient had cyst rupture after being punctured by C-TBNA , secondary pulmonary infection and right pleural effusion, followed by surgical treatment. The recurrence rate of C-TBNA was 100.00% (13/13), and that of EBUS-TBNA was 71.43% (10/14) (P >0.05).

Conclusion: C-TBNA and EBUS-TBNA technology have high diagnostic value for the mediastinal bronchogenic cysts. Both C-TBNA and EBUS-TBNA technology have the risk of secondary infection and recurrence of cysts.

PO-422

Experience of medical thoracoscopy at a single institution

Lin,Ching-Kai1,2、Luo,Wei-Cheng2、Wen,Yueh-Feng2、Yu,Kai-Lun2、Ho,Chao-Chi1
1. National Taiwan University Hospital
2. National Taiwan University Hospital， Hsin-Chu Branch

Objective: Medical thoracoscopy (MT) is a minimally invasive procedure for inspection and biopsy of the pleural space. The treatment of pleural disease by MT has also gradually applied in some circumstances. We summarize the experience of MT at National Taiwan University Hospital, Hsin-Chu Branch.

Methods: A retrospective chart review was performed on patients who underwent MT procedures for diagnostic or therapeutic purposes in patients with various pleural diseases or undiagnostic pleural effusion from December 2015 to August 2018. Those without definite diagnosis were excluded. For diagnostic purpose, a 1.9 mm cryoprobe was used for specimen collection. An alligator jaw grasping forceps or Kelly clamp was attempted for adhesionlysis/fibrolysis or

other therapeutic procedures.

Results: Thirty-eight patients who underwent 40 MT procedures were enrolled in the present study (Figure 1). Twenty-one procedures were performed for diagnostic MT, 5 for therapeutic MT, and 14 performed both diagnostic and therapeutic MT during the same procedure. For the 35 diagnostic procedures, the overall diagnostic yield was 100%. For the 19 MT for therapeutic purpose, 18 were performed adhesionlysis/fibrolysis or decortication, and only 4 patients in this population needed for further surgical thoracoscopy. The remaining 1 patient was performed diaphragm repair due to hepatic hydrathorax with defect on diaphragm.

Conclusion: MT had a high accuracy for diagnosis of various pleural diseases. For therapeutic purposes, MT procedures also had high efficacy. The utility of surgical thoracoscopy could be minimized if MT procedure was performed initially.

PO-423

Clinical Utility of Endobronchial-Ultrasound Guided Miniforceps Biopsy (EBUS-MFB) for Lung Cancer Patients: A Novel Diagnostic Technology for Hilar and Mediastinal Lymph Nodes

Kirita,Keisuke、Tamiya,Yutaro、Itotani,Ryo、Udagawa,Hibiki、Nosaki,Kaname、Zenke,Yoshitaka、Ikeda,Takaya、Matsumoto,Shingo、Yoh,Kiyotaka、Niho,Seiji、Goto,Koichi
National Cancer Center Hospital East

Objective: EBUS - miniforceps biopsy (MFB) is a new diagnostic tool of lymph nodes under continuous EBUS guidance. Previous pilot study suggested that technique may increase the diagnostic yield for granuloma and lymphoproliferative disease, but little is known about lung cancer.

Methods : EBUS-TBNA was performed first in all patients by convex probe EBUS bronchoscope (UC260/290FW, Olympus) and TBNA needle (Vizishot2 21G, Olympus). After withdrawing TBNA needle, EBUS bronchoscope was positioned, 1.0mm miniforceps (coreDx, Boston Scientific) was inserted to target lesions under EBUS and performed forceps biopsy.

Results: A total of 38 attempt number of puncture were performed in 5 patients who were suspicious with primary lung cancer. Median short axis of target lymph node was 17mm (range: 10-23mm), and target lesions were located in #4R, #4L, #7 and hilar (#11s). Median total number of puncture (TBNA) / biopsy (MFB) in each patient was 3 and 7 times, respectively. Insertion success rate of MFB into the target lesion was 82% and overall diagnostic yield of malignancy was 87%. Median tumor concentration was 60% and area was 1.21mm2. Procedure time of each MFB was significantly shorter than that of TBNA puncture (median 41 seconds vs. 106 seconds, $p<0.01$). Total procedure time was 28.8 (range: 19.3-32.4) minutes and no severe complication (ex; bleeding, pneumothorax, respiratory failure and infection) was identified.

Conclusion: EBUS-MFB is safe and feasible technique for hilar and mediastinal lymph nodes suspicious with primary lung cancer.

PO-424

Pneumopericardium following surgery of thymic cancer

Yamamoto,Kozo、Kuwahara,Motohisa、Yamamoto,Satoshi
Medical Kouhoukai Takagi Hospital， International University of Health and Welfare

Objective: ＜BACKGROUND> Pneumopericardium is a rare condition, defined as the presence of gas in the pericardial sac. It can be caused by local infection, trauma, inflammation, malignancy and idiopathic event. Pericardial tamponade caused by pneumopericardium is life-threating, so acute diagnosis and treatment are needed. We report a case of pneumopericardium after thymic cancer operation.

Methods: <CASE> A 67-year-old man underwent thymectomy with partial resection of the left upper lung lobe, pericardium and left phrenic nerve for thymic cancer. Pericardium was reconstructed using Gore-Tex sheet. Postoperative radiotherapy (50Gy) was conducted. Four years later, he visited our hospital due to chest pain. Chest computed tomography revealed pneumopericardium communicating with the bulla of the left upper lobe. We attempted pericardial drainage, but the pneumopericardium showed no change due to continuous air leakage . He showed no pericardial tamponade symptom or signs of infection; hence, he was kept under careful observation.

Results: Nine months later, he suffered from a left pneumothorax; so we decided to perform operation.The approach was 3rd intercostal antero-lateral thoracotomy. In the intrapleural space, adhesions were found around the apex and upper anterior mediastinum. After division of the adhesions, an air leak was found around the area of the incarceration of the bulla. We detached the bulla from the pericardial sac and sutured the bulla. We didn’t reconstruct pericardium due to loss of the margin to suture. Thirty months observation after the operation, there is no recurrence of the pneumopericardium.

Conclusion: ＜CONCLUSION> We experienced a rare case of pneumopericardium following surgery of thymic cancer.

PO-425

Thoracoscope under local anesthesia for advanced non-small cell carcinoma with pleuritis carcinomatosa to attempt genetic examination

Yamamoto,Kozo、Kuwahara,Motohisa、Yamamoto,Satoshi
Medical Kouhoukai Takagi Hospital， International University of Health and Welfare

Objective: <BACKGROUND> EGFR-TKI can recover patients suffering from severe subjective symptoms caused by advanced non-small cell lung cancer（NSCLC）.We report a case of carcinomatous effusion and pleurisy with respiratory discomfort and leg edema. The histopathological diagnosis was pulmonary adenocarcinoma/EGFR mutation positive (exon18) and quality of life was improved remarkably under EGFR-TKI administration.

Methods: <CASE> A 67-year-old female patient with cough, leg edema and respiratory discomfort went to the previous hospital. Chest X-ray showed left massive pleural effusion. She was admitted to our hospital for further examination and treatment. Chest computed tomography revealed left massive pleural effusion, complete collapse of left lung and shift to the right of mediastinum. As for serum tumor marker, CEA level was very high at 106.9 ng/ml. Thoracostomy drained about 2400ml of dark bloody fluid and shift of mediastinum improved. In the thoracoscopy under local anesthesia, multiple white nodules were found all around pleural cavity. which were thought to be dissemination. We performed biopsy of them and histopathological diagnosis was adenocarcinoma. Following Genetic test of EGFR was mutation positive (exon19), and osimertinib was started immediately. In addition, PET showed accumulation (SUVmax 4.5) of about 15mm nodule of left upper lobe, which was supposed to primary lesion.

Results: After starting osimertinib , CEA lebel was decreasing gradually (30.0 ng/ml) and pleural effusion was under control. Eleven months later, she has discharged to her home with no severe subjective symptoms now.

Conclusion: <CONCLUSION> We realized again that EGFR-TKI can recover patients suffering from severe subjective symptoms caused by NSCLC dramatically. The thoracoscope under local anesthesia can be useful for patients with severe condition such as pleuritis carcinomatosa.

PO-426

Application of rapid on-site evaluation in CT guided percutaneous lung biopsy of peripheral pulmonary nodules

Li,Yanyan
People's Hospital of Binzhou City

Objective: To evaluate the value of rapid on-site evaluation in CT-guided percutaneous lung biopsy of peripheral pulmonary nodules (< 2 cm)

Methods: A retrospective analysis was made of 108 patients with pulmonary nodules who underwent CT-guided percutaneous lung biopsy from January 2017 to October 2017 in our hospital. The nodules were less than 2 cm in diameter. According to the presence or absence of ROSE, they were divided into ROSE group (58 cases) and conventional group (50 cases). Adequacy of sampling,diagnostic accuracy, complications, secondary biopsy rate，and statistical consistency between rapid on-site cytological evaluation and histopathology

Results: In ROSE group and routine group, the adequacy of sampling was 93.10%,78.00%,P value was 0.024,the diagnostic accuracy was 89.66%,74.00%, P value was 0.033, the second biopsy rate was 6.90%,22.00% (11/50),P value was 0.024, which had statistical difference. The incidence of pneumothorax in ROSE group and routine group was 13.79%,18.00%,P value was 0.549,the incidence of bleeding was 39.66%,40.00%, P value was 0.971, there was no statistical difference.The consistency between ROSE and histopathology in benign and malignant lesions was 100%,93.33%

Conclusion: ROSE can guide puncture sampling without prolonging the operation time and increasing complications, so as to ensure the adequacy of sampling, improve the diagnostic accuracy and reduce the rate of secondary puncture biopsy. Moreover, ROSE has good consistency with histopathology, and can make the lesion get immediate diagnosis

PO-427

Combining bronchoscopy mucosal biopsy and transmission electron microscopy technology in Primary ciliary dyskinesia research and diagnosis

Guo,Ting1,2、Luo,Hong1,2、Zhou,Rui1,2
1. Department of Respiratory Medicine, The Second Xiangya Hospital, Central South University, Changsha, China
2. Research Unit of Respiratory Disease, Central South University, Changsha, Hunan, China

Objective: Primary ciliary dyskinesia (PCD; MIM: 244400) is a rare and clinically heterogeneous disorder due to impairment of ciliary function.Ciliary ultrastructure analysis by bronchoscopy mucosal biopsy combining with tran smission electron microscopy(TEM) is really important for the diagnosis of PCD. The identifcation of ultrastructural defects through TEM has been previously considered a "gold standard" diagnostic test for PCD. However, it was challenged by recent fndings. In order to test the effectiveness of TEM in PCD,we recruited 11 rare PCD patients in this study.

Methods: We recruited all the patients with a definitive diagnosis of PCD based on typical clinical phenotype and genetic diagnosis. In all cases,bronchoscopy mucosal biopsies were performed.Samples were fixed in 2.5% glutaraldehyde in 0.1 M sodium cacodylate buffer, and postfixed in 1% osmium tetroxide. After dehydration, the samples were embedded in epoxy resin. Then, several sections were picked out onto copper grids. The sections were stained with aqueous 1% uranyl acetate and Reynold's lead citrate. Ciliary ultrastructural analysis was carried out using the TEM.

Results: Of the 11 patients,3 patients(27%) were identified the loss of both outer dynein arm(ODA) and Inner dynein arm(IDA) by TEM analysis.3 patients(27%) were identified the loss of isolated ODA. 1 patient (9%) was identified central pair defect.1 patient(9%) was ambiguous ciliary ultrastructure and 4 paitents(37%) were lack of whole cilia structure due to recurrent lung infections.

Conclusion: (1) Bronchoscopy mucosal biopsy combined with transmission electron microscopy technology is still an effective test for PCD.(2) To avoid the absence of cilia, the recommended time for bronchoscopy mucosal biopsy must be non-infectious period.(3)If the ciliary ultrastructure is equivocal, other approaches(including repeated biopsy or ciliated cell culture techniques)may be considered.

PO-428

Comparison of neostigmine and sugammadex on effect-site concentration of remifentanil for preventing emergence cough at extubation in male patients

Kim,Ji Eun
Ajou University School of Medicine

Objective: During general anesthesia, emergence cough at extubation is common, but related with serious complications. Remifentanil infusion during emergence lowers the cough. Effect-site concentration (Ce) of remifentanil using target-controlled infusion (TCI) has been evaluated in previous studies. Sugammadex, as a reversal agents for muscle relaxant, induces the emergence cough more frequently and earlier compared to neostigmine. We investigated the optimal Ce of remifentanil for preventing emergence cough following extubation during general anesthesia in male patients who are reversed with sugammadex or neostigmine.

Methods: Forty two male patients undergoing laparoscopic cholecystectomy were enrolled. Anesthesia was implemented with remifentanil using TCI and sevoflurane. The remifentanil Ce for suppressing emergence cough was estimated for each group using Dixon's up-and-down method and isotonic regression method with a bootstrapping approach.

Results: By Dixon's up-and-down method, the EC50 of remifentanil was significantly lower in sugammadex group (2.17 ± 0.59 ng/mL) than neostigmine group (3.04 ± 0.49 ng/mL) (P=0.014). The EC50 (83% confidence intervals) and EC95 (95% confidence intervals) by isotonic regression also were lower in sugammadex group [3.00 (2.65–3.21) and 3.45 (3.44–3.47) ng/mL, respectively] than neostigmine group [3.50 (3.22–3.68) and 3.95 (3.93–3.97) ng/mL, respectively]. Finally, anesthesia time in sugammadex group was shorter than that in neostigmine group (P=0.028), although operation time was similar.

Conclusion: The remifentanil requirement for preventing emergence cough at extubation was lower in sugammadex group than in neostigmine group among male patients. Sugammadex use is suggested during remifentanil TCI at extubation when considering the adverse effect of opioid.

PO-429

EBUS--Guided 125I Brachytherapy for Metastatic Mediastinal Lymphadenopathy

Li,Changyi、肖东京,Dongjing
Department of respiratory and critical care medicine， the second affiliated hospital of Chongqing medical university

Objective: To retrospectively evaluate the therapeutic effect and safety of EBUS-guided brachytherapy for metastatic mediastinal lymphadenopathy due to lung cancer refractory to conventional radiation and chemotherapy

Methods: EBUS-guided 125Iodine seed placement was performed in 21 patients with known metastatic mediastinal lymphadenopathy. A pre-operative treatment planning session (TPS) evaluated the lymph node to be treated. Following bronchoscopic placement, the dose distribution radiographic improvement and complications were assessed. Repeat CT scans were performed and KPS scores evaluated at 2, 4 and 6 months.

Results: 125I catheter placement was successful in 19/21 patients. In these, TPS criteria was met with a median dose of 94 Gy and median volume of 97.1%.The local control rate (CR+PR) was 76.2%，85.7%，and 81.0% at months 2, 4 and 6 after implantation, respectively. The average postoperative KPS scores at 6 months was significantly higher than pre-operatively（Z=-3.066, P=0.002）. Complications include local hematoma in one patient and low-grade fever in

two patients. No severe complications, including massive hemorrhage or pneumothorax, occurred.

Conclusion: EBUS-guided 125I brachytherapy is a safe and effective palliative therapeutic option for metastatic mediastinal lymphadenopathy due to lung cancer

PO-430

Interventional treatment of pulmonary sequestration in which the donor artery originated from the celiac trunk: a rare case report

Qin,Wei、Li,Fa-jiu、Zhu,Zi-yang、Wang,Xiao-jiang、Li,Cheng-hong
Affiliated hospital of jianghan university

Objective: Pulmonary sequestration is one kind of congenital lung malformations, which is usually classified into two types, intralobar and extralobar. The main treatment of these diseases is surgical excision. Nowadays, with the development of endovascular treatment, more and more cases treated with Interventional techniques has been reported. so we report one case of pulmonary sequestration treated with coil intervention.

Methods: we report the case of a 50-year-old female with recurrent hemoptysis after the transcatheter septal closure. She has been diagnosed with intralobar pulmonary sequestration by chest enhanced CT.We embolized the isolated lung with spring coils.

Results: The patient stopped hemoptysis immediately after interventional embolization, and the lesion was completely absorbed after three months.

Conclusion: Vascular interventional therapy can be used in patients with pulmonary sequestration

PO-431

Subglottic Occlusion Recanalization by Montgomery T-tube

Zhang,Quncheng、Ma,Yun、Qi,Yong、Zhang,Xiaoju
Henan Provincial People hospital

Objective: A 36-year-old man presented to subglottic airway occlusion for 2 months after tracheotomy due to cerebral infarction.

Methods: Computed tomography of the chest showed occlusion (about 30mm) in the subglottic trachea (Panel A, CT sagittal position setting). Flexible bronchoscopy revealed granulation proliferation that was completely obstructing the trachea (Panel B). Flex-needle(18G) was used to puncture the occlusion in the direction of trachea (Panel C), then placed the guide wire through the needle (Panel D). After balloon expansion with rigid tube, the Montgomery T tube was placed in a proper position (Panel E F G).

Results: After the operation, the patient could speak and CT showed that T tube was in the right position (Panel H I). Subglottic trachea occlusion is one of the serious complications caused by intubation or tracheotomy. The patient was treated with Montgomery T-tube to therapy trachea occlusion, and his symptoms resolved.

Conclusion :

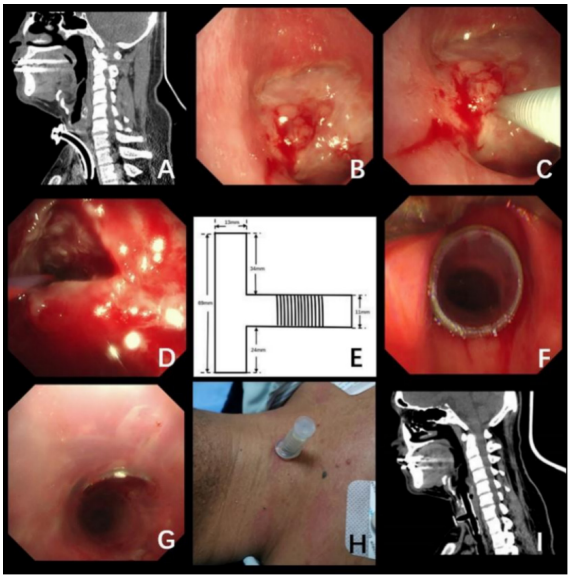

PO-432

Peripheral pulmonary nodule was diagnosed as mycobacterium tortoise by electromagnetic navigation bronchoscope combined with next generation sequencing: a case report

Liu,Wei、Yanyan,Li、Yu,Zang、Yan,Wang、Liyan,Bo、Faguang,Jin
Department of Respiratory, the Second Affiliated Hospital, the Fourth Military Medical University

Objective: We report the case of a 29-year-old female with a 1.1 cm × 1.1 cm solitary nodule adjacent to the pleura in the upper lobe of the right lung that was diagnosed as mycobacterium tortoise by electromagnetic navigation bronchoscope combined with next generation sequencing.

Methods: The ENB in this case reported was performed by a bronchoscopist in our institute, superDimension Bronchus System Version 7.0 (SDBS, Herzliya, Israel) was used for navigation, and biopsy was performed using a 16-mm biopsy forceps. The NGS results show that mycobacterium tortoise was detected in both bronchoalveolar lavage fluid and biopsy tissue

Results: Through ENB combined with NGS, the patient acquired an accurate diagnosis and a prompt medical treatment, meanwhile avoided the cost of surgery.

Conclusion: This case is the first to use ENB in combination with NGS to diagnose peripheral pulmonary nodules caused by mycobacterium tortoise infection. Through this pattern diagnostics technology, the peripheral pulmonary nodules of the patient were clearly diagnosed, while avoiding the pain of surgery, reducing the length and the cost of hospitalization, providing a new way for accurate diagnosis of peripheral pulmonary nodules.

PO-433

Multiple bronchoscopic interventional methods combined in the treatment of extensive airway stenosis: A case report

Guo,Zhifeng、Zhang,Huaping、Zeng,Yiming
The Second Affiliated Hospital of Fujian Medical University

Objective: To share a case of multiple bronchoscopic intervention combined in the treatment of extensive airway stenosis, and to improve the understanding and management of extensive airway stenosis.

Methods: The patient, a 37-year-old female, was admitted to our hospital in 2019 -11-05 because of "progressive asthma for more than 10 years and aggravation for 2 weeks". Computer tomography showed:cervical and thoracic tracheal stenosis, local narrowing of the left main bronchus and thickening of the corresponding tube wall. Bronchoscopy was performed on 11-08 after admission. Scar hyperplasia was found in the upper segment of the trachea 3mm from the glottic. The lumen was narrow and the diameter was about 3mm.The posterior wall, left and right wall of upper tracheal stenosis were ablated with the sapphire laser. The length of the upper tracheal stenosis is about 2cm and the diameter after ablation is about 6mm.The middle part of the trachea is about 5cm from the glottis, and scar stenosis and mild hyperplasia can be seen. No further treatment was carried out because the patient could not tolerate it. That night, the patient developed chest tightness and obvious shortness of breath. Physical examination: shortness of breath appearance, visible inspiratory three concave sign, sitting breathing. Considering edema and necrotic obstruction after bronchoscopic treatment, tracheal necrotic tissue removal and balloon dilatation were performed under electronic bronchoscopic. After operation, a high-frequency ventilator was used to assist ventilation. The patient's shortness of breath was obviously relieved. Since then, biopsy forceps and frozen cutting were given to remove necrotic substances

in 11-11, 11-14 and 11-18 successively, meanwhile,cryoablation, high-frequency electric knife and JHQ0840 balloon dilatation were performed. Submucosal injection of prednisone and betamethasone was given to the lesions of the upper trachea, right middle lobe bronchus and left upper lobe bronchus. After the treatment, the diameter of the bronchial lumen of the right middle lobe was about 5.5mm, the opening lumen of the left upper lobe was enlarged to about 5.5mm.

Results: After the combined treatment of various interventional methods under bronchoscopic, the tracheal lumen of each segment was enlarged, and the asthma symptoms of the patients were significantly improved.

Conclusion: Multiple interventional methods under bronchoscopic are effective in the treatment of extensive airway stenosis, but at the same time, special attention should be paid to the possible complications. It is necessary to closely observe the situation of patients in clinical work and find out the occurrence of complications in time.

PO-434

Cross-sectional investigation on the distribution of medical resources for interventional bronchoscopy

Bai,Yang、Li,Yishi、Guo,Shuliang、白阳
First Affiliated Hospital of Chongqing Medical University

Objective: To investigate the distribution of medical resources for interventional bronchoscopy across the country. 划词翻译 详细解释

Methods: A multi-center, cross-sectional study using an electronic questionnaire was conducted in hospitals performing diagnostic and/or interventional bronchoscopy from April to June 2019. The survey questionnaire included information about general hospital features, hardware equipments, technical capabilities, talent teams. 划词翻译 详细解释

Results: A total of 96 electronic questionnaires were collected in this survey. The proportion of tertiary hospitals participating in this questionnaire was higher in the eastern region than that in the western region (89.2% vs 54.1%, adjusted P<0.01). 49.0% hospitals had independent subspecialty of interventional pulmonology, 38.5% had independent ward, 21.8% had pathogen isolation operating room, and 59.4% had equipment storage area, 63.5% had patient preparation area, 58.3% had patient recovery area, and there were no significant differences between the four regions (all P>0.05). The proportion of hospital with cryotherapy device in the eastern region was higher than that in the western region (81.1% vs 43.2%, adapted P<0.01), and there were no significant differences in other hardware equipments between the four regions (all P>0.05). The proportions of hospitals in the eastern region with bronchoscopy cryotherapy (80.1% vs 43.2%, adapted P<0.01), transbronchial needle aspiration biopsy (64.9% vs 29.7%, adapted P<0.01), transbronchial balloon dilatation (73.0% vs 37.8%, adapted P<0.01) were higher than those in the western region respectively, and there were no significant differences in other technical capabilities between the four regions (all P>0.05). 57.3% hospitals had full-time interventional physician teams, there were no significant differences in talent teams between the four regions (all P>0.05). 划词翻译 详细解释

Conclusion: There were differences in some aspects of medical resources for interventional bronchoscopy regarding general hospital features, hardware equipments, technical capabilities in different economic regions of China. Although there were no significant differences in the talent teams, the number of interventional pulmonology physicians was small and so was the number of research projects. It is necessary to strengthen the training of bronchoscopy physicians and promote multi-center clinical researches and research projects. 划词翻译 详细解释

PO-435

Analysis of the effect of percutaneous thrombectomy in the treatment of acute pulmonary embolism

Ma,Xuan、Zhou,Wei
General hospital of ningxia medical university

Objective: To investigate the clinical efficacy and safety of percutaneous thrombectomy in the treatment of acute pulmonary embolism.

Methods: The clinical data of 26 patients with acute pulmonary embolism who were admitted to our hospital from January 2017 to January 2019 and treated by percutaneous catheter thrombectomy were retrospectively analyzed. All patients were treated with percutaneous catheter thrombectomy combined with local thrombolytic therapy to observe the improvement of clinical symptoms, pulmonary function and pulmonary artery before and after treatment.

Results: 26 cases were successfully broken pin bolt and local thrombolysis treatment, 15 cases of patients cured, 10 cases of patients were markedly effective, improvement in 1 case, and the treatment of patients after heart rate, breathing rate, D - dimer, MPAP index significantly lower than before treatment ($P < 0.05$), and after treatment in patients with arterial blood gas analysis results was obviously improved, the $P < 0.05$, with statistical significance.

Conclusion: The treatment of acute pulmonary embolism by percutaneous catheter thrombolysis combined with local thrombolytic therapy is reliable and safe, and has the advantages of quick onset, low iatrogenic trauma, high cure rate and less complications, which has the value of clinical application and promotion.

PO-436

The effects of different activators on the release curve of human platelet-rich plasma

zhuang,yawen、Zeng,Yiming
The Second affiliated Hospital of Fujian medical university

Objective: To compare and analyze the effects of different activators on the release curve release curves of TGF-β1、PDGF-AB in platelet rich plasma.

Methods: A total of 36 ml peripheral venous blood was extracted from the 10 healthy adult volunteers, and the PRP was made by secondary centrifugation.The platelet activator was made up of bovine thrombin 1000 U and 10% 1 ml calcium chloride solution.The Thrombin-PRP group was made by PRP and the activator in a ratio of 10:1. The Calcium chloride-PRP group was thus in a ratio of 10:1 by PRP and 10% calcium chloride solution instead. The fresh whole blood(whole blood group) and inactived PRP(PRP group) as control group, and incubated the four groups in warm water of 37 ℃ for 0、1、8、2、72and 168 h.A quantitative sandwich enzyme-linked immunosorbent assays(ELISA) was used to examine the amount of TGF-β1 and PDGF-AB in different time points of each group. The release curves of TGF-β1、PDGF-AB were based on afore-mentioned data, then a comparation of the release curves of TGF-β1、PDGF-AB in different groups by repeated measurement variance analysis.

Results: (1)The levels of TGF-β1 and PDGF-AB in the Whole blood group and the PRP group continued to increase within 168 h. PRP immediately formed into a gel after mixed with thrombin combined and calcium chloride, and the concentration of TGF-β1, PDGF - AB reached the peak in 1 h after activation, respectively increased from (42±21)ng/ml、(77±18)ng/ml to (84±21)ng/ml、(124±35)ng/ml, then decreased gradually.The release curve was direct and rapid.The PRP came into a gel state in approximate 1 h after mixed with calcium chloride, the concentration of TGF-β1 and PDGF-AB were slowly rising and remained high at 168 h.(2)The AUC0-168h of TGF-β1 and

PDGF-AB in the PRP group were higher than that in the whole blood group（Z=-3.78 ，Z=-3.78，P ＜ 0.05）, and the AUC0-168h of TGF-β1 in the Calcium chloride-PRP group was higher than that in the Thrombin-PRP group(Z=-2.26，P ＜ 0.05).However, there was no significant difference in the AUC0-168h of PDGF-AB between the Calcium chloride-PRP group and the Thrombin-PRP group(Z=-1.512，P=0.131).

Conclusion： Using calcium chloride as activator can get a higher release concentration of TGF-β1、PDGF-AB and a longer release time,with the largest area under the curve.

PO-437

Palliative value of self-expandable metal stent insertion in malignant tracheobronchial stenosis by bronchoscopy

K.Jahangir、Zhang,Jingxi、Huang,Haidong、Bai,Chong、Jahangir kabir
Department of Respiratory and Critial Care Medicine， Changhai Hospital， Second Military Medical University

Objective： The purpose of this study was to identify and evaluate the post metallic stent palliative value in the form of dyspnoea (MRC grade) and quality of life (ZPS score) for the patients with malignant tracheobronchial stenosis.

Methods： Medical data were retrospectively reviewed for all patients who underwent SEMS insertion due to malignant airway diseases from January 2015 to December 2016 at Interventional Pulmonology Centre, Changhai Hospital, Shanghai, China. Dyspnoea (MRC grade) and Quality of life (ZPS score) were collected and compared before SEMS insertion and 3 months after SEMS insertion.

Results： A data analysis of 103 patients who had underwent total 110 SEMS including uncovered stent (83.4%) and covered stent (16.6%) were inserted successfully by flexible or rigid bronchoscopy suffering from malignant tracheobronchial stenosis. Among them male were (n = 69; 67%) and female were (n = 34; 33%) with mean age (61.01 ± 10.65 years). The major respiratory symptoms before implantation included dyspnea / respiratory distress in all patients in different grade, cough with sputum (n = 32; 31.1%), haemoptysis (n = 15; 14.6%) and stridor (n = 9; 8.7%). Etiology of stenosis included lung cancer (n = 56; 54.4%), esophageal cancer (n = 33; 32%), and other malignancies (n = 14; 13.6%). The stents were placed in trachea (n = 62; 56.4%), followed by right main bronchus (RMB) (n = 23; 20.9%) and left main bronchus (LMB) (n = 17; 15.5%). There were significant improvement in dyspnoea (n = 54/65; 83.1%, 3.76 ± 0.95 vs 2.17 ± 0.84 P < 0.0001) and quality of life (n = 37/65; 56.9%, 2.47 ± 1.05 vs 1.15 ± 0.97, P < 0.0001) had been observed between before implantation and 3 months after implantation. The most frequent stent related complication was restenosis due to either tumour ingrowth (n = 08; 9.8%) or granulation tissue formation (n = 05; 6.1%). Other complications were bronchoesophageal fistula (n = 05; 6.1%), haemoptysis and stent migration (n = 02 in each cause; 2.4%) respectively.

Conclusion： SEMS placement in airway by bronchoscopy is a safe and effective method for relieving dyspnoea and contributed to improve quality of life for patients with malignant tracheobronchial stenosis for an extended period.

PO-438

Centrally located masses and the role of EBUS-TBNA and EUS – B – FNA

Tashi,Eritjan1、Teferici,Alma1、Kokici,Fahri1、Kapisyzi FCCP,Prof. Dr. Perlat2
1. University Hospital Shefqet Ndroqi
2. University of Medicine. Faculty of Medicine. Tirana / Albania

Objective: The diagnosis of centrally located masses without endobronchial abnormalities pose a diagnostic challenge. Different modalities are applicable for tissue diagnosis 1. To asses the feasibility and diagnostic yield of EBUS-TBNA and EUS-B FNA in centrally located tumors adjacent to the trachea and oesophagus in patients without general anaesthesia.

Methods: Retrospective study of patients suspected of lung cancer with CT scan of chest revealing a intrapulmonary mass near or adjacent to oesophagus and trachea from January 2018 to December 2019. Patients after non diagnostic flexible bronchoscopy were proceeded to EBUS - TBNA and EUS-B - FNA for histologic diagnosis in one session by a single pulmonologist. The yield and sensitivity of EBUS-TBNA and EUS-B-FNA with also the added value of EUS-B- FNA to bronchoscopy and EBUS was assessed

Results: 12 patients were enrolled in the study in whom there was a centrally located tumor near the oesophagus or trachea on chest CT and histologic diagnosis was made through EBUS - TBNA or EUS - B FNA without general anaesthesia. 11 patients were identified with the following diagnosis of NSCLC. The diagnostic yield and sensitivity of EBUS and EUS – B FNA for detecting lung cancer was 91.7%. In 5 patients (41.6 %) the intrapulmonary tumor was exclusively detected by EUS- B FNA after non diagnostic bronchoscopy and EBUS -TBNA. In 6 patients (50 %) were diagnosed with trans tracheal EBUS. No EUS - B FNA complication were observed. 5 patients 41.6% after non diagnostic EBUS due to difficulty in passing the bronchoscope through the vocal cords, respiratory insufficiency, compression of the trachea due to mass and also not possible to pass the needle through the trachea were switched in during the procedure to EUS - B - FNA. EUS- B-FNA increased the yield of diagnosis from 41.6% to 91.7%. Samples were adequate for diagnosis in 91.7% of cases

Conclusion: EUS-B- FNA is a feasible and safe technique for diagnosis of centrally located intrapulmonary masses. EUS – B should be considered in the same endoscopy session following a non diagnostic bronchoscopy and EBUS - TBNA. They might present the first diagnostic step in intrapulmonary masses. Awake EBUS- TBNA and EUS-B are a safe well tolerated procedure and can be done without general anaesthesia. When there is EBUS failure EUS-B should be considered as a alternative.

PO-439

Association between different components of blood pressure and the risk of endobronchial biopsy-induced hemorrhage in patients with lung cancer

Wang,Saibin
Jinhua Municipal Central Hospital, Jinhua Hospital of Zhejiang University

Objective: Hemorrhage is the most common complication during endobronchial biopsy (EBB). The aim of the present study was to explore associations between different components of blood pressure and the risk of endobronchial biopsy-induced hemorrhage in patients with lung cancer.

Methods: We conducted a retrospective cohort study of 643 consecutive adults with lung cancer over an approximately 4-year period (from 2014 to 2018) at a large tertiary care hospital in China. Patients were divided into the hemorrhage group and the non-hemorrhage group. The association between systolic pressure (SP), diastolic pressure (DP), mean arterial pressure (MAP), pulse pressure (PP), PP to DP (PP/DP) ratio and the risk of EBB-induced hemorrhage was evaluated using multivariate regression analysis and smooth curve fitting adjusted for demographics, tumor characteristics, and laboratory factors.

Results: EBB-induced bleeding incidence was 37.8%. An independent association was found between PP/PD and EBB-induced hemorrhage risk (per SD, adjusted odds ratio, 0.788; 95% confidence interval, 0.653-0.951). The multivariate regression analysis performed using quartiles of PP/DP revealed that higher level of PP/DP ratio was related to a lower risk of EBB-induced hemorrhage (P for trend < 0.05) after adjustment for potential confounders. However, no association was observed between SP, DP, MAP and EBB-induced hemorrhage.

Conclusion: Lower PP/DP was the independent risk factor for hemorrhage in patients with lung cancer who underwent EBB.

PO-440

Discussion on Management Mode of Endoscope Center

Xu,Min
Beijing Tian Tan Hospital, Capital Medical University

Objective: With the development of endoscopic technology, the scope of diagnosis and treatment is continuously expanding, and the endoscopic diagnosis and treatment technology is gradually developing in a direction of diversification, refinement, comfort and standardization. The existing management modes of endoscopy centers are mostly a summary of experience gathered through continuous trial, which are often lack of the foresight and flexibility of scientific management. However, the management realm represented by the management concept and management level will indirectly affect the professional level that the industry can reach. Managers should continuously improve the scientific management level to improve efficiency, release potential, and improve the level of hospital fine management.

Methods: In this study, by introducing the development and changes of the management mode of the endoscopy center, the past management behaviors and thinking modes are discussed, the management elements and methods of the endoscope center are summarized. At the same time, multiple management modes and their influence on the development of the discipline were compared to explore a new endoscopic center management mode which adapt to modern medical development.

Results: Different endoscopic center management modes have different management methods in terms of medical quality, nursing quality, sensory management, and benefit management. No matter which management mode,

reducing costs, improving efficiency, and maximizing value are the direction of all endoscopic center management. Platform management is more systematic and scientific in terms of integrating resources and reducing costs, and is more executing in terms of improving efficiency and effectiveness. The management of the endoscope center needs to be constructed and operated scientifically and rationally in order to romote the development of specialized technology.

Conclusion: With the development of endoscopic technology and the expansion of the scope of minimally invasive medicine, multi-disciplinary collaborative diagnosis and treatment has changed the relationship between departments and the management model of the endoscopic center. The core of management has changed from previous management, supervision, and control to assistance, empowerment and achievement, the responsibility of the manager has changed to provide a good development space for endoscopic technology, and stimulate the individual innovative ability of endoscopic practitioners. The modern era is the era of the sharing economy. Shared space, shared resources, shared channels, shared benefits, and platform-based management have gradually deepened into the management mode of the endoscope center. Channels and resource sharing have been opened up, and smooth connections and close cooperation with relevant departments have been achieved to shared build and share win.

PO-441

Threshold effect between platelet count and refractory bleeding following endobronchial biopsy in patients with lung cancer

Wang,Saibin
Jinhua Municipal Central Hospital, Jinhua Hospital of Zhejiang University

Objective: Decreased blood platelet count has been proposed to be a risk factor associated with bleeding following bronchoscopic biopsy; however, the specific association between the two remains elusive. The aim of the present study was to explore the association of blood platelet count with endobronchial biopsy (EBB)-induced refractory bleeding in patients with lung cancer.

Methods: A total of 659 patients with lung cancer who had undergone EBB were consecutively collected at a tertiary hospital between January 2014 and April 2018. The association between platelet count and EBB-induced refractory bleeding was examined by using piecewise linear regression and multiple regression analysis after adjusting for potential confounders.

Results: A significant proportion (13.8%, 91/659) of the patients experienced refractory bleeding following EBB. A non-linear relationship with a threshold effect was observed between platelet count and EBB-induced refractory bleeding in a piecewise linear regression analysis. In multiple regression analysis, the risk of EBB-induced refractory bleeding significantly decreased in patients with the platelet count above the inflection point (platelet count = 125×109/L) than those with the platelets below the inflection point (adjusted odds ratio, 0.44; 95% confidence interval, 0.22-0.91, P = 0.026).

Conclusion: There was a threshold effect between platelet count and the risk of EBB-induced refractory bleeding. The platelet count of less than 125×109/L was the independent risk factor for refractory bleeding following EBB in patients with lung cancer.

PO-442

Development of a predictive model for hemoptysis following CT-guided transthoracic lung biopsy

Wang,Saibin
Jinhua Municipal Central Hospital, Jinhua Hospital of Zhejiang University

Objective: The aim of this study was to establish and validate a predictive model for hemoptysis following computed tomography-guided transthoracic lung biopsy (CT-TNB).

Methods: A total of 436 consecutive patients who underwent CT-TNB between June 2016 and December 2017 at a tertiary hospital were divided into derivation (n=307) and validation (n=129) cohorts. We used LASSO regression to reduce the data dimension, select variables and determine which predictors were entered into the model. We used multivariate logistic regression analysis to develop the predictive model and presented it by means of a nomogram. The discrimination capacity of the model was evaluated by the area under the receiver operating characteristic curve (AUROC), the calibration curve was used to test the goodness-of-fit of the model, and decision curve analysis was used to evaluate its clinical utility.

Results: Five predictive factors (diagnosis of the lesion, lesion characteristics, lesion diameter, procedure duration and puncture distance) were selected by LASSO regression analysis to develop the predictive model. The AUC in the derivation and validation cohorts was 0.849 (95% confidence interval [CI], 0.806-0.891) and 0.765 (95% CI, 0.684-0.847), respectively. The predictive model was well-calibrated ($P > 0.05$), and decision curve analysis showed that the model was clinically useful.

Conclusion: We established a predictive model that incorporates lesion features and puncture parameters, which may be of great value for the individualized preoperative prediction of hemoptysis following CT-TNB.

PO-443

Nebulized application of tranexamic acid: A promising method to prevent hemorrhage induced by the endobronchial biopsy in patients with lung cancer

Wang,Saibin
Jinhua Municipal Central Hospital, Jinhua Hospital of Zhejiang University

Objective: To establish a feasible and effective pathway to prevent endobronchial biopsy-induced bleeding in patients with lung cancer by using preoperative inhalation of nebulized tranexamic acid (TXA).

Methods: In an endobronchial biopsy setting of patients with lung cancer, a randomized, controlled trial comparing a lidocaine group with TXA combined with lidocaine group was performed, and evaluation of the duration and volume of bleeding, as well as the incidence of bleeding induced by EBB after these drugs use via the nebulizer system was done. The potential adverse effects of TXA such as thromboembolic events and seizures were also monitored.

Results: Among the 114 lung cancer patients in the TXA group, the incidence of EBB-induced bleeding was 24.6% (28/114, 95% confidence interval [CI]: 16.7%-32.5%) and it was 42.1% (24/57, 95% CI: 29.3%-54.9%) in the control gourp. The relative risk (RR) of TXA group in the incidence of EBB-induced bleeding was 0.584 (95% CI: 0.435-0.733). Moreover, there were statistically significant in the volume of the EBB-induced bleeding between the TXA group and the control group ($P < 0.05$). When compared to the control gourp, the proportion of cases with more bleeding (≥ 20 ml) in the TXA group was significantly reduced, while the proportion of cases without bleeding or micro-

bleeding (< 5 ml) increased significantly. In addition, the bleeding time was less in the TXA group than in the control group ($P < 0.05$), even after adjusting for the affecting factor of hemostasis. No TXA-related adverse drug reactions were observed during the study.

Conclusion: Nebulized application of TXA combined with lidocaine contributed to lower the incidence of EBB-induced bleeding, and reduced the bleeding volume and the bleeding time follwong EBB.

PO-444

Fungi and bacteria isolated from pulmonary samples in Niger

Abdoulaye Mamoudou,Oubayyou1,3,4、Zongo,Cheickna3、Mounkaila,Soumaila2、Gagara,Assiata4、Traor é ,Alfred3、Mounmouni,Hassane1
1. Universit é Abdou Moumouni de Niamey
2. Universit é d'Agadez, Niger
3. CRSBAN, Universit é de Ouaga1, Burkina
4. Hôpital national Lamord é , Niger

Objective: To determine association of medical fungal and bacterial profile in pulmonary samples from patients

Methods: It's prospective study, carried out in health centers in Niamey from October 2013 to september 2016. Mycological and bacteriological examination was done on lung washing fluid, pleural fluid and sputum. The strains identification was based on phenotypic carracter

Results: Several assocoations have been confirmed. It concerned species of the same genus or from a group of germs to another. The association between bacteria species were 7 types. Three types of fungi association were reported. The mixte association, between fungi and bacteria was observed in 23 times.

Conclusion: These baseline data will be used to better assess the situarion and guarantee a better chance of successful diagnosis, prevention and probabilistic treatment in Niger.

PO-445

Fire in the hole！ A case of foreign body removal from airway

Wang,Xiaoming、Zeng,Qianglin、Zhou,Hui、王晓明
Affiliated Hospital of Chengdu University

Objective: The removal of airway foreign body is a common bronchoscopy operation. This case report is an accident of airway fire during the removal of foreign body. For the purpose of warning, we hereby report it to you.

Methods: This case is a 23-year-old female. 10 + years ago, she swallowed a toy whistle (cylindrical) and then coughed into the bronchus. In the past year, she had pneumonia twice. Three days before admission, she had cold again and then coughed yellow sputum. Chest CT showed that there were foreign bodies in the right lower lung and obstructive pneumonia in the right lower lung. The foreign body is located between the right intermediate bronchus and the base segment of the right lower lobe. The opening of the right middle bronchus is annular stenosis. It is difficult to take out the foreign body through the bronchoscope in the first attempt, and it is difficult to take out the foreign body through the bronchoscope in the second attempt. It is proposed to take out the foreign body through laser incision of the narrow ring, after balloon expansion of the narrow ring, freezing or forceps, However, in the process of laser incision of the narrow ring, there was a fire in the airway. The tracheoscope was seriously burned and damaged. Immediately

pull out the tracheoscope, cut off the oxygen supply to the airway, and replace another tracheoscope to enter the airway again. It can be seen that the glottis to the trachea and the right main bronchus were generally pale and burned. There were many black substances on the airway wall, which were washed by local ice and physiological saline. The foreign bodies were frozen by the freezing probe.

Results: In order to prevent the obstruction of upper airway, endotracheal intubation was performed. After that, bronchoscopy was performed for many times. The necrotic substances in the inner wall of trachea and bronchus gradually fell off. Local injection of acetylcysteine atomized solution was made, and the dead objects were frozen out. After 2 weeks, the epiglottis and vocal cord recovered gradually, and the patients could make normal voice without dyspnea.

Conclusion: When operating medical equipment such as laser or electric knife, the standard operation procedures must be strictly followed to ensure the safety.

PO-446

Prospective randomized controlled study of radial endobronchial ultrasound-guided transbronchial lung biopsy with distance and guide sheath in the thin Bronchoscope for peripheral pulmonary lesions with diameter ⩾ 3 cm

Guan,Shuhong、Zhou,Jun、Zhang,Qiudi、Xu,Qianqian、Xu,Xiong、Zhang,Sujuan
The First People's Hospital of Changzhou

Objective: The purpose of prospective randomized controlled study was to compare the diagnostic yields, operation time and safety of radial endobronchial ultrasound-guided transbronchial lung biopsy with distance(rEBUS-D-TBLB) and guide sheath（rEBUS-GS-TBLB）in the thin bronchoscope for peripheral pulmonary lesions with diameter ≥ 3 cm.

Methods: 603 Patients with peripheral pulmonary lesions(diameter ≥ 3 cm) were included in this study and divided into two groups: with distance group (D group) and with guide sheath group (G group) by the random number table method. They were assigned to undergo rEBUS-D-TBLB or rEBUS-GS-TBLB. The operation time, adverse events, histopathology, final diagnosis were observed.

Results: 569 cases were included finally, 282 in group D and 287 in group G. The diagnostic yield of rEBUS–D–TBLB was noninferior to that of rEBUS–GS–TBLB in malignant diseases. The distribution of lung bands did not affect it. In right lung lesions, the diagnostic yield of rEBUS–D–TBLB was noninferior to that of rEBUS–GS–TBLB, which required to be further confirmed by sample accumulation in right middle lung lesions. In the general group, the positive group and the negative group, the operation time of group D was longer than that of group G. There were 14 cases of bleeding > 50m, 1 case of postoperative chest pain in group D and 3 cases of bleeding > 50ml in group G. There was no pneumothorax or infection in both groups.

Conclusion: rEBUS–D–TBLB in the thin bronchoscope had a high diagnostic yield . In the diagnosis of malignant diseases and right lung lesions, the diagnostic yield was noninferior to that of rEBUS–GS–TBLB, which was not affected by the distribution of lung bands. The operation time with rEBUS–D–TBLB is a little longer and there were more bleeding adverse events, but its cost is low.

PO-447

Intralesional triamcinolone acetonide injection combined with Radial incision approach for benign cicatricial airway stenosis

Ma,Yun、Huang,Taibo、Li,Xiao
the People's Hospital of Henan Province

Objective: Background Benign central airway stenosis (BAS) means ststenosis caused by benign lesions in central airways. Its etiology is complex, with benign hyperplastic scar stenosis is the most common type. The most common etiologies for benign airway stenosis are tuberculosis(TB). High-frequency Electrotomy, balloon dilatation, transbronchial cryobiopsy, local injection are frequently-used treaments for BAS. Triamcinolone Acetonide (TA) is a synthetic glucocorticoid with strong and long-lasting anti-inflammation effect. Local injection of TA in the target site can restrains fibroblasts hyperplasia, reduces collagen synthesis, thus inhibits scar tissue growth.

Methods: Case report A 42-year-old man presented with a chief complaint of cough, sputum for 1 month, dyspnea for more than 10 days. He reported a history of tracheobronchial tuberculosis for 1year, and accepted standard antituberculotic treatment. Based on the Clinical manifestation, chest CT and bronchoscopy, a clinical diagnosis of tuberculous bronchial cicatricial stenosis was made. Stenosis sites were located in infraglottic cavity and right main bronchus. To manage complicated airway stenosis, the patient received local injection of triamcinolone acetonide combined with needle-shaped high-frequency electrotome with radial incision approach and balloon dilatation by bronchoscopy.

Results: Among 4 months, the patient underwent three interventional treatments. After treatments, the airway diameter and dyspnea score were significantly improved. The subglottic diameter was increased from 3mm before operation to 6-7mm after operation. The diameter of right main bronchi was increased from 2mm to 5mm (figure 1). A 6 months follow-up, the patient remained stable after treatments. No related serious complications were observed.

Conclusion: Local injections of TA therapy combined with needle-shaped high-frequency electrotome with radial incision approach for benign cicatricial airway stenosis has good curative effect. Mucosal damage was less by needle-shaped high-frequency electrotome with radial incision approach. Local injections of TA prolonged restenosis time significantly. The treatment was safe and effective. It may be a good treatment option in patients with severe benign cicatricial airway stenosis.

PO-448

The diagnosis of severe pneumocystis pneumonia by bronchoalveolar lavage combined with metagenomic Next Generation Sequencing: a case report

Chen,Hui、Wang,Sheng-Yu、Zhou,Jing、Cai,Kai-Xia、Hui Chen
Department of pulmonary and critical care medicine, the First affiliated Hospital of Xi'an Medical University

Objective: We report a 48-year old woman with severe pneumocystis pneumonia was diagnosed by bronchoalveolar lavage combined with metagenomic Next Generation Sequencing to illustrate bronchoalveolar lavage combined with NGS has an important clinical value for pulmonary infectious diseases.

Methods: A previously healthy, fully immunized 48-year old woman with severe pneumonia was admitted to the Department of pulmonary and critical care medicine, the First affiliated Hospital of Xi'an Medical University. The patient received invasive ventilation and V-V ECOM treatment.On the second day after admission, we performed a bronchoscopy on the patient. During operation, we found congestion and edema of bilateral bronchial mucosa, no obvious secretion, and bronchoalveolar lavage was performed in the lower lobe of the right lung, and the BALF was examined by metagenomic Next Generation Sequencing (NGS). After 3 days, the results of NGS revealed: pneumocystis jiroveci, subsequently, the antibiotics were adjusted to cefoperazone sulbactam, caspofungin and sulfanilamide. The patient's symptoms gradually improved and finally recovered.

Results: In this case report, the condition of patient is very critical and prompt diagnosis and targeted treatment are key to success. For pulmonary infectious diseases, it is very important to obtain respiratory secretions, and bronchoalveolar lavage can obtain deep airway secretions, avoiding the interference of contaminating bacteria to a large extent, meanwhile, the rapid and accurate acquisition of pathogenic data by NGS laid a foundation for successful rescue of the patient.

Conclusion: Bronchoalveolar lavage combined with NGS has an important clinical value for pulmonary infectious diseases, especially for those patients who can not be effectively diagnosed by routine methods in a short period of time.

PO-449

Comparison PD-L1 expression between transbronchial biopsy with endobronchial ultrasonography-guide sheath for lung cancer

Ding,Hui、Jingzhu,Zhou 、Guanghui ,Zhou 、Zhiwei,Tang、Ruhua,Chen 、Yan,Fen
Department of Respiratory Medicine， Yixing people hospital， affiliated Jiangsu University

Objective: The previous reports said that endobronchial ultrasonography-guide sheath (EBUS-GS) for peripheral pulmonary lesions (PPLs) provided larger tissues than transbronchial biopsy (TBB) for gene analysis by next generation sequenceng. The aim of this study is to assess the average number of tumor cells and PD-L1 expression (≥ 50% and ≥ 1%) for EBUS-GS for PPLs and TBB in patients with lung cancer.

Methods: We enrolled 13 patients from July to December 2018 at Yixing people’s hospital in this prospective study. The number of average tumor cells and PD-L1 expression were compared between EBUS-GS and TBB. e average number of tumor cells and PD-L1 expression (≥ 50% and ≥ 1%) for EBUS-GS for PPLs and TBB in patients with lung cancer.

Results: The average numbers of tumor cells obtained by EBUS-GS were significantly larger than those got by TBB (1506± 208.3 vs., 526 ± 88.13, $P < 0.01$). PD-L1 ≥ 50% and ≥ 1% patients for EBUS-GS were 26.38% and 62.61%, respectively, whereas those for TBB were 13.25% and 43.92%, respectively. PPLs and TBB in patients with lung cancer.

Conclusion: EBUS-GS may be a more suitable approach for lung tissue with gene analysis and whole exon sequencing. Particularly, it could also provide ample tissue for PD-L1 expression analysis in addition to accurate diagnosis.

PO-450

An improved method for establishment of benign acquired tracheoesophagus fistula model in experimental dogs

Wang,Yuchao、Li,Jing、王钰超
Guangdong Provincial People`s Hospital

Objective: To study the simplified effect of Medtronic aortic perforator on the establishment of benign acquired TEFs model in the experimental dogs[1,2], and the adjuvant therapy effect of nasal feeding on the prevention of postoperative pulmonary infection.

Methods: 1.Experimental materials and animals Two beagle dogs, weight of 10kg and one Medtronic aortic perforator 2. Operative procedure All dogs were deprived water for 12 hours before surgery and their hair was removed before surgery. The experoimental dogs were anesthetized with ketamine. After the animals lost consciousness, they were fixed on the operating table. The dog`s head neck were extended and fixed to fully expose the neck. Mechanical ventilation with tracheal intubation and low oxygen flow were performed. The ECG monitoring was connected, the blood oxygen saturation was detected, and venous access was establish through small saphenous vein puncture of lateral hindlimb at the same time. Using iodine volts disinifect the chest area and on the both side of anterior portion. On the left neck biceps inside edge to make a longitudinal incision, 5 cm long. Cutting the subcutaneous tissue and thoracic muscle, free fascia and other connective tissue, expose the trachea and esophagus, selected the neutral position of cervical trachea esophagus as the fistula position, turn the right 90° of tracheal and esophagus, free the surrounding tissues of esophagus wall, exposed the esophagus left side wall and front side wall. Then used the electrotome cut the esophagus front wall 2cm longitudinally, at the same time use the electrotome burning the trachea membrane at the

corresponding place, and punch the trachea membrane department by using the Medtronic aortic perforator, using the 3-0 stitch interrupted suture the esophagus anterior wall and the matching trachea membrane incision edges, layered suture neck incision after using saline flushing. After the operate, the experimental group 1 was intubated with nasal feeding. When the animals were awake. It is taken to the breeding room.

Results: After one week observation, the result showed that there were a significant tracheoesophageal fistula formation in both animals. The animal which use nasal feeding survived after one week without any lung infection. The animal without nasal feeding died in the 5 day after operate because of the lung infection and malnutrition.

Conclusion: The use of Medtronic aortic perforator can simplify the whole process of TEFs model establishment. The nasal feeding can prevent postoperative contamination and respiratory tract infection because of the oral feeding.

PO-451

CT-guided Percutaneous lung Biopsy Resulted In Aggravation Of Lung Infection In 2 Patients

Li,Mengjie
Qingxian people's Hospital

Objective: CT-guided percutaneous lung biopsy is a common clinical procedure. Pulmonary infection complications are rare and no specific report has been found. In actual medical treatment, the author encountered 2 cases of puncture lesions that were infectious lesions. After percutaneous lung biopsy, respiratory symptoms appeared. Through re-examination of the puncture site of chest CT, pulmonary infection at the original site spread, and the shape was disseminated along the puncture needle.

Methods: The aggravation of pulmonary infection after operation in 2 cases of percutaneous lung biopsy was analyzed.

Results: The pathological reasons may be as follows: pulmonary lesions of the patient are inflammatory lesions, and infection is easy to spread after puncture; After puncture, lung injury and structural damage are caused, and pathogen infection is easy to be caused. If the puncture process is not strict disinfection or intraoperative pollution may also be the cause of infection. During clinical percutaneous lung biopsy, strict aseptic operation and disinfection of the operation site should be conducted.

Conclusion: Chest CT should be timely reviewed for patients who are clinically considered as infectious lung lesions or whose puncture result is returned as inflammation, or whose cough is aggravated after puncture, and anti-infection treatment should be given in time if the infection is aggravated.

PO-452

The value of prolonging BALF culture time in the diagnosis of pulmonary cryptococcosis

Mu,Deguang、Li,Xi、Li,Xiaomeng
Zhejiang Provincial People's Hospital

Objective: Pulmonary cryptococcosis is an acute, sub-acute or chronic respiratory mycosis caused by the infection of cryptococcus. The top five pathogens of pulmonary mycosis in China are aspergillus, candida, cryptococcus, sporidium and mucormycosis. Etiological diagnosis is very important in infectious diseases. The diagnosis standard of cryptococcus is the pathological detection of cryptococcus in the lung tissue. But this examination is an invasive operation. So, the healthy condition of the patient must be taken into account. Some patients have poor tolerance and are undurable to complete lung biopsy, which brings difficulties to the pathogen detection of cryptococcus.The culture of bronchial alveolar lavage fluid is an important clinical diagnostic method. In the clinical practice, the culture time of cryptococcus in BALF is generally 2-5 days, and if no fungal colony is formed after 1 week of culture, it is often judged to be negative result. No prolonging the culture time study was reported. Objective: Explore the value of prolonging the fungal culture time of bronchial alveolar lavage fluid in the diagnosis of pulmonary cryptococcosis

Methods: Methods: Retrospective analysis the data of 12 patients suspected of pulmonary cryptococosis who had positive fungal results from BALF culture from January 1, 2019 to August 31, 2019. As to these patients, alveolar lavage was performed at corresponding segments according to the chest CT findings under bronchoscopy. The alveolar lavage fluid was given fungal culture until cryptococcus colony formation or until 3 weeks.

Results: Results: Among the above 12 patients, 4 cases formed cryptococcus colony after more than 1 week of culture time and obtain the pathogenic evidence. These 4 patients were administrated fluconazole treatment and got a good therapeutic effect.

Conclusion: Conclusion: Prolonging the time of the fungal culture of BALF of patients suspected pulmonary cryptococcosis has clinical application value for getting pathogenic evidence and is worthy of clinical recommendation.

PO-453

The predictors of liberation from mechanical ventilation in patients with acute respiratory failure due to malignant central airway obstruction after metallic airway stenting using flexible bronchoscopy

Tu,Chih-Yen、Chen,Chia-Hung、Liao,Wei-Chih、Wu,Biing-Ru、Cheng,Wen-Chien、Chen, Chih-Yu、Chen,Wei-Chun、Hsia,Te-Chun、Hsu,Wu-Huei
China Medical University Hospital

Objective: Patients with malignant central airway obstruction (CAO) can be life-threatening and often require emergency intubation and mechanical ventilation. The insertion of self-expandable metallic stents with bronchoscopy can facilitate rapid extubation or weaning from mechanical ventilation (MV). The purpose of this study was to determine the factors predicting weaning from MV in patients with acute respiratory failure due to malignant CAO.

Methods: We conducted a retrospective study at a university hospital from January 2008 to December 2017. A total of 87 patients in the intensive care unit had acute respiratory failure due to malignant CAO during this period and required intubation and MV. These patients underwent flexible bronchoscopy with electrosurgery or stent implantation under bronchoscopic visualization and local anesthesia in the intensive care unit without fluoroscopic guidance throughout the procedure.

Results: Of the 87 patients, 40 had lung cancer, 39 had esophageal cancer, and 8 had other types of malignancy. The patients were divided into two groups based on liberation from MV: successful group and failed group. There were significant differences in baseline characteristics including fraction of inspired oxygen (FiO2), presence of pneumonia, size of the tumor around the airway, acute lobar or total lung collapse, and C-reactive protein between the two groups. After univariate and multivariate analyses, FiO2 > 40%, presence of pneumonia, and size of the tumor around the airway > 3.8 cm were negative predictors of liberation from MV. However, acute lobar or total lung collapse was a positive predictor of weaning from MV.

Conclusion: The insertion of self-expandable metallic stents with flexible bronchoscopy facilitated liberation from MV in the patients with acute respiratory failure due to malignant CAO. It may be difficult to wean patients from MV if they have pneumonia, FiO2 > 40%, and a tumor > 3.8 cm around the airway before the procedure. In contrast, acute lobar or total lung collapse was a positive predictor of weaning from MV.

PO-454

The time needs endobronchial ultrasound-guided transbronchial needle aspiration after positron emission tomography for mediastinal staging in patients with lung cancer

Chen,Chia-Hung、Tu,Chih-Yen、Liao,Wei-Chih、Wu,Biing-Ru、Cheng,Wen-Chien、Chen,Chih-Yu、Chen,Wei-Chun、Hsia,Te-Chun、Hsu,Wu-Huei
China Medical University Hospital

Objective: Endobronchial ultrasound-guided transbronchial needle aspiration (EBUS-TBNA) has a high diagnostic value for mediastinal staging in patients with lung cancer. This retrospective study is comparison between EBUS-TBNA and positron emission tomography (PET) utility for lung cancer stage and determined the characteristics of false negatives and false positives in PET scan

Methods: 147 Patients who received both EBUS-TBNA and FDG-PET for the diagnosis of preoperative lymph node were retrospectively investigated from 2008-01 to 2018-12 at China medical university hospital. We compared the diagnostic performance of these two modalities. In addition, pathological findings of the biopsied sample were evaluated precisely and compared with the results of PET.

Results: The sensitivity, specificity, positive predictive value (PPV), and negative predictive value (NPV) of EBUS in detecting nodal metastasis were 95.2%, 100%, 100% and 9.3% whereas those of PET were 75.4%, 53.7%, 56.3%, 73.3% respectively. The multivariate analysis indicated age > 65 years old (p=0.009), non-adenocarcinoma (p<0.008), and history of tuberculosis infection as risk factors for false positive uptake in PET scan and diabetes (p=0.002), non-adenocarcinoma (p=0.048), and SUVmax of lymph node < 4.0 (p=0.041) as risk factors for false negative uptake in PET scan.

Conclusion: The diagnostic yield of EBUS-TBNA is higher than that of PET for mediastinal staging in patients with lung cancer. EBUS-TBNA should be performed if patient was age > 65 years old, non-adenocarcinoma, and history of tuberculosis infection due to high risk factors for false positive uptake in PET scan and also need to perform if patient with diabetes, non-adenocarcinoma, and SUVmax of lymph node < 4.0 due to high risk factors for false negative uptake in PET scan.

PO-455

Clinical characteristics of five cases of Tracheobronchopathia osteochondroplastica

Guo,Rong、Wei,Xiaohui、Niu,Ling
People's Hospital of Xinjiang Autonomous Region

Objective： Objective: To investigate the clinical characteristics of tracheobronchopathia osteochondroplastica (TO).

Methods： Methods: The clinical data of 5 patients with TO from November 2016 to November 2018 were retrospectively analyzed. The etiology, clinical manifestations, diagnosis and treatment of TO were summarized.

Results：Result: All 5 patients with TO were middle-aged males, confirmed by histopathological examination. The main clinical symptoms were cough, sputum, hemoptysis, chest pain and repeated pulmonary infection. Some patients could make a preliminary diagnosis by chest CT, and definite diagnosis could be made by bronchoscopy combined with histopathological examination. The main treatment includes anti-infection, phlegm-resolving and other symptomatic treatment.

Conclusion： Conclusion: TO is a benign disease predisposing to adults. Its clinical manifestations are lack of specificity and easy to be misdiagnosed or missed. Chest CT examination contributes to the diagnosis of TO, and Bronchoscopy combined with histopathological examination is the main method for the diagnosis of TO. There is no well-recognized treatment standard for TO, and the judgment of therapeutic effect is inconsistent. It is necessary to improve the understanding of this disease from clinical perspective.

PO-456

The intermediate bronchial stenosis after right upper lobectomy

Yamamoto,Satoshi、Kuwahara,Motohisa、Yamamoto,Kozo
International University of Health and Welfare

Objective： <Background> It is common the left bronchial bend and stenosis after upper lung lobectomy rather than the right bronchus. We experienced a patient of the right intermediate bronchial band and stenosis after right upper lobectomy for lung cancer with complicated of Diabetes mellitus. We would like to report the present illness and some references.

Methods： <Case report> 78 year-old male, admitted our hospital with abnormal shadow of the right upper lung field, and he had been Diabetes mellitus (Type 2) with insulin administration. He had thoracoscopic right upper lobectomy under usual manner, and had no major complication, and discharged hospital on 14 day after operation. Pathological examination revealed invasive adenocarcinoma (lipidic 60%, acinar 40%) T1bN0M0 Stgae IB2.

Results： After 7 months, he admitted our hospital with low grade fever and some stridor. White blood count was 4820/ul, serum CRP level was 1.25 mg/dl, chest CT scan showed the bend and stenotic the right intermediate bronchus, and some infiltration shadow in the right middle lobe. The symptom was improved by administration of antibiotics and inhalation of bronchodilator. The findings of bronchoscope showed soft stenosis of the right intermediate bronchus, so the fiber scope easily passed through the stenotic portion. There was not any abnormal findings of bronchial mucosa. Chest CT scan at one month and three months after the event revealed that the stenosis of intermediate bronchus has been gradually improved.

Conclusion： Steroid therapy was considered for this case, however, we did not select the therapy on account of diabetes mellitus. We guess this bronchial stenosis has some possibility of relation to infection (especially viral infection) due to diabetes mellitus.

PO-457

Case Report: Endobronchial Kaposi Sarcoma in a patient with Myelodysplastic Syndrome

Tang,Fei、Lv,Liping、Xu,Jianping、Ye,Wei、Wang,Lina、Wang,Yueming
An Hui Chest Hospital

Objective: To improve the understanding and management of airway diseases in patients with low immunity by reporting a case of myelodysplastic syndrome (MDS) with endotracheal kaposi sarcoma (KS).

Methods: A case of MDS-KS diagnosed in our hospital was reported, and the clinical characteristics, bronchoscopic characteristics and treatment of endobronchial kaposi sarcoma were summarized and analyzed.

Results: We report the case of a 40 year-old-male patient, who presented with a intermittent cough for 5 months. His past medical history was myelodysplastic syndrome.Laboratory examination on this patient showed decreased white blood cells and red blood cells, low albumin content, no significant abnormalities in other indicators, and negative results of immune combination examination.CT scan of chest showed numerous nodular opacities and small plaques in both lungs,Small nodules are seen at the trachea carina. According to bronchoscopy, the trachea carina, the left main trunk, the left upper bronchus and the opening of the right main bronchus were found to have four round granulomatous protrusions with narrow pedicles, among which the species in the left upper bronchus and the trachea carina showed local mucosal vascular dysplasia in Narrow Band Imaging（NBI） mode. The species were safely removed by high frequency electrical traps in four times and was sent for examination. The pathological results combined with immunohistochemical markers indicated kaposi sarcoma.

Conclusion: Kaposi sarcoma (KS) is an angioproliferative tumor associated with human herper virus (HHV-8). Kaposi sarcoma and MDS are rarely complicated, and the manifestations of bronchial lesions are more rare. Meanwhile, to prevent bleeding, thermal ablation techniques should be used whenever possible. As such ,this case should requires further attention and recognition in clinical practice, especially in Pulmonology，Hematology and Critical Care.

PO-458

To analyze the clinical value of bronchoalveolar lavage plus Piperacillin Sodium and Tazobactam Sodium in bronchiectasia patients with concurrent infection

Dong,Yiming
Weifang People's Hospital

Objective: To analyze the clinical value of bronchoalveolar lavage plus Piperacillin Sodium and Tazobactam Sodium in bronchiectasia patients with concurrent infection.

Methods: 45 bronchiectasia patients with concurrent infection(2018.12-2019.12) in our hospital from December 2018 to December 2019 were selected and assigned to group one (N=20,odd number) and group two (n=20,even number) according to medical record number.Group one was treated with Piperacillin Sodium and Tazobactam Sodium;on the basis of the former,group two was treated with bronchoalveolar lavage. The curative effect, FEV1/FVC,PaO2,SaO2,CRP and PCT were evaluated.

Results: The total effective rate of study group 2(97%) was better than that of study group 1(85%)($P<0.05$);there was no significant difference in FEV1/FVC,PaO2,SaO2,CRP and PCT between the two groups before treatment ($P>0.05$);after treatment ,FIV1/FVC,PaO2and SaO2 of study group 2 were singnificantly higher than those of study group 1,CRP and PCT were significantly lower than those of study group 1($P<0.05$).

Conclusion: The combination of bronchoalveolar lavage, Piperacillin Sodium and Tazobactam Sodium is of great importance for bronchiectasia patints with concurrent infection.

PO-459

The value of electronic bronchoscopy in the diagnosis of bronchial tuberculosis

Chen,Hui、Wang,Sheng-yu、ZHOU,Jing、 Li,Ya-ming、Liu,Song、陈晖
Department of pulmonary and critical care medicine， the First affiliated Hospital of Xi'an Medical University

Objective: To explore the value of electronic bronchoscopy in the diagnosis of bronchial tuberculosis.

Methods: From June 2016 to March 2019, 69 patients with bronchial tuberculosis admitted to the Department of respiratory and critical care medicine, the First affiliated Hospital of Xi'an Medical University completed the preoperative examination, and carefully read the chest CT of the patients to determine the lobes and segments of the lungs that required to be electronic bronchoscopy. The operation was performed by Olympus 1T260 electronic bronchoscope. During the operation, carefully observe each segmental bronchus, especially the lobes and segmental bronchus of the diseased part: (1) for the mucosa with hyperemia and edema, saline was injected 37℃ at the lesion site, 20ml each time, and lavage was performed for a total of 3 times; (2)for the mucosa covered with the necrosis, brush two pieces ; (3)for the mucosa with thickening, ulceration, roughness and other lesions, brush two pieces and biopsy. The clinical data of the above patients were analyzed retrospectively, including the clinical manifestations, mucosal characteristics, acid fast staining of bronchoalveolar lavage fluid, brush examination and biopsy.

Results: The main clinical manifestations of 69 patients in this study were cough, expectoration and hemoptysis. Among the above patients, 30 cases revealed no tuberculous changes of pulmonary parenchyma or mediastinal lymph node on chest CT. The main characteristics of bronchial mucosa included hyperemia and edema, massive carbon deposition, mucosal ulcer, covered with caseous necrosis, and airway stenosis may occur in patients with a longer course of disease. According to the above mucosa changes, lavage, brush examination and biopsy were used respectively. The positive rates were: lavage 38.9%, brush 62.3%, biopsy 75.9%, and brush combined with biopsy 85.4%.

Conclusion: For the patients who are suspected of bronchial tuberculosis, the electronic bronchoscopy as soon as possible, pay attention to the characteristics of the bronchial mucosa, and choose the appropriate examination method according to the characteristics of the bronchial mucosa. Combined with a variety of bronchoscope examination methods, it can improve the the diagnostic rate.

PO-460

Selective arteriography and embolization in the treatment of pulmonary tuberculosis with massive hemoptysis

Zhong,Jinnan
The Sixth Hospital of Wuhan， Affiliated Hospital of Jianghan University，

Objective: To investigate the long-term efficacy, safety and complications of bronchial artery embolization in the treatment of massive hemoptysis

Methods: 136 cases of patients with bronchial artery embolization from January 2015 to January 2018 in the sixth hospital of wuhan were analyzed retrospectively, including 84 male and 52 female, the patient’s age ranged from 16 and 82 years, with a mean age of 54.9 years. The patients were observed and followed up 24 hours after operation. The patients were reexamined by X-ray chest radiography or chest CT, and returned by telephone or questionnaire for a minimum of 2 months and a maximum of 9 years.

Results: A total of 776 vessels were embolized in 136 patients, 104 cases were cured clinically, 12 cases were markedly effective, 8 cases were effective, 12 cases were ineffective (2 cases died), the total effective rate was 91.2%,

the cure rate was 76.5%.Follow-up for 1 to 2 years ,96 cases were cured clinically, 16 cases were markedly effective, 4 case was effective and 20 cases were ineffective (6 cases died, of 2 died after operation), the total effective rate was 85%, the cure rate was 71%. 2 cases died of uncontrollable massive hemoptysis after short-term follow-up.2 cases died of massive hemoptysis due to recurrence of pulmonary tuberculosis and family members refused to intervene again.2 cases died because hemoptysis increased than before, accompanied by uncontrollable lung infection There were no deaths, no serious complications and no long - term adverse events.

Conclusion: Bronchial artery embolization is safe and effective in the treatment of hemoptysis, and the efficacy rate of hemostasis is high. There are few serious complications and long-term adverse events.

PO-461

The therapeutic effect of percutaneous vascular intervention on the massive hemoptisis caused by pulmonary arterial pseudoaneurysm

Li,Fajiu、Zhu,Ziyang
Department of Respiratory Medicine, Wuhan No. 6 Hospital, Affiliated Hospital to Jianghan University

Objective: Hemoptysis is a common acute and critical illness in respiratory system, and the mortality rate of massive hemoptysis is very high. Because more than 90% of massive hemoptysis is ruptured and bleeding of body artery dominated by bronchial artery, the treatment of massive hemoptysis with body artery embolization has been widely used in clinic at present, which greatly reduces the fatality rate of massive hemoptysis. However, a small number of massive hemoptysis is caused by pulmonary artery (PA) origin, mainly in the form of pulmonary arterial pseudoaneurysm (PAPA) ,then the body artery embolization is ineffective. The purpose of this study is to find a more effective treatment for massive hemoptysis caused by pulmonary arteriogenic (pulmonary arterial pseudoaneurysm).

Methods: From October 2016 to October 2018,44 patients who were diagnosed with pulmonary arterial pseudoaneurysm were treated with body artery and pulmonary artery embolization and followed up for 6 months to 2 years.

Results: Of the 44 patients, 40 were successfully treated with body artery and pulmonary artery embolization, 2 patients had recurrent hemoptysis of 20 ml 8 months after operation, and improved by internal medicine treatment ,the other 4 patients could not find the pulmonary artery supplied by PAPA, so only body artery embolization was performed,of 1 patient had recurrent massive hemoptysis of 500ml 6 months later.

Conclusion: Percutaneous vascular intervention (body artery and pulmonary artery embolization) is an effective means to treat PAPA, and it is worth a wide range of clinical popularization.

PO-462

The study of how pulmonary artery pseudoaneurysm is involved in the massive hemoptysis of tuberculosis and the embolization in the treatment of hemoptysis

Hu,Bingzhu
The Sixth Hospital of Wuhan , Affiliated Hospital of Jianghan University,

Objective: To investigate the diagnosis and treatment of pulmonary artery pseudoaneurysm involved in hemoptysis of pulmonary tuberculosis.

Methods: 200 cases of pulmonary tuberculosis complicated with massive hemoptysis in our hospital from May 2013 to February 2018 were selected to analyze the CTA and angiographic features and therapeutic effect of pulmonary artery pseudoaneurysm.

Results: There were 40 cases of pulmonary artery pseudoaneurysm in 200 cases, of which 8 cases found pulmonary artery pseudoaneurysm on CTA examination, but were not found on angiography, all of them achieved immediate hemostasis. 8 patients had recurrent hemoptysis due to infection 6 months after discharge and the another 32 patients without hemoptysis.

Conclusion: For pulmonary tuberculosis, especially fibrous cavitation pulmonary tuberculosis, we should be on guard against pulmonary artery pseudoaneurysm. For patients with massive hemoptysis, CTA examination is recommended to make a definite diagnosis, and embolization through pulmonary artery with coils to treat PAP has a good hemostatic effect.

PO-463

The application of continuous management of doctor-nurse cooperation for patients with bronchiectasis and massive hemoptysis after pulmonary vascular interventional therapy

Feng,Qiong
The Sixth Hospital of Wuhan , Affiliated Hospital of Jianghan University

Objective: To explore the effect of continuous management of doctor-nurse cooperation on pulmonary vascular interventional therapy for patients with bronchiectasis and massive hemoptysis.

Methods: From January 2016 to December 2017, 136 patients with bronchiectasis and massive hemoptysis after interventional therapy were randomly divided into the observation group (70 cases) and the control group (66 cases). The control group received routine nursing, while the observation group received continuous management of doctor-nurse cooperation. The life quality score, postoperative readmission rate and recurrence rate of hemoptysis in two groups were compared.

Results: After the implementation of the continuous management of doctor-nurse cooperation, The score of CAT (COPD Assessment Test) in the patients with bronchiectasis and massive hemoptysis after treatment of pulmonary vascular intervention was significantly reduced.($P < 0.01$), the readmission rate and recurrence of hemoptysis were significantly decreased ($P < 0.05$), The satisfaction of the patients to the doctor-nurse staff was obviously improved ($P < 0.05$).

Conclusion: The doctor-nurse cooperation continuous management model not only improves the quality of life of patients with bronchiectasis and hemoptysis after pulmonary vascular intervention, but also reduces readmission rate, effectively reduces the recurrence of hemoptysis, improves patient satisfaction to doctor-nurse staff, it is worthy of reference and promotion.

PO-464

Observation on the effect of double intervention in the treatment of bronchiectasis complicated with massive hemoptysis

Li,Fajiu、Li,Chenghong
Department of Respiratory Medicine, Wuhan No. 6 Hospital, Affiliated Hospital to Jianghan University

Objective: To investigate the advantages of vascular intervention (bronchial artery embolization) combined with endoscopic intervention (endoscopic lavage) in the treatment of bronchiectasis complicated with massive

Methods: 332 patients who had bronchiectasis complicated with massive hemoptysis in Department of Respiratory Medicine, six Hospitals of Wuhan, affiliated Hospital of Jianghan University from January 2014 to December 2017 were selected and were treated with bronchial artery embolization . Among them, 160 patients were treated with routine treatment as control group. 172 cases were in the double intervention group,in addition to routine treatment, bronchoscopy lavage was performed on the third day after operation, followed by bronchoscopy lavage on a regular basis (every 3 months).The patients in the two groups began postoperative observation and regular follow-up immediately after bronchial artery embolization. The changes of blood leukocyte count and procalcitonin biochemical indexes were recorded before and seven days after treatment, and returned by telephone or questionnaire (every 3 months). The follow-up time was 24 months.The changes of pulmonary function, the life quality score, the times of admission (year) and the recurrence time of hemoptysis were observed.

Results: The symptoms of hemoptysis were well controlled in both groups, but the white blood cell count and procalcitonin level in the double intervention group were better than those in the control group after seven days treatment,differences were all statistically significant ($P < 0.05$). The short-term and long-term improvement of pulmonary function, the life quality score, the times of admission, and the recurrence time of hemoptysis were better than that in the control group.

Conclusion: Vascular intervention therapy combined with endoscopic intervention therapy can better control the infection , improve the quality of life and reduce the time of hospitalization.

PO-465

Bronchoscopic Interventional Therapy of Tracheobronchial Neurofibroma:Report of 2 Cases and Review of the Literatures

Jiang,Lixue、Mia,Weiwei、Wu,Xue、Ma,Liang
Department of respiratory medicine, Harbin First Hospital

Objective: To summarize the clinical features,diagnosis and treatment of patients with tracheobronchial neurofibroma,to lmprove the clinician,s understanding of the disease and to reduce misdiagnosis and missd diagnossis.

Methods: We analyzed the general condition,the clinical manifestations, histopathology, microscopic and imagin findings, treatment and prognosis of 2 patients with tracheobronchial neurofibroma our hospital and reviewed relevant literatures .

Results: The two patients were male, including one case of patient whose pulmonary CT showed a round soft tissue density shadow on the right main bronchus (Figure 1a) and bronchoscopy showed that the tumor grew upward the carina and blocked the left main bronchial lumen of 60%(Figure 1b). This patient was resected the mass by bronchoscopic interventional therapy.Pathological return were tracheal neurofibroma(Figure 1c). During a fllow-

up period of 5 years,the patients was in good condition and the intraluminal lessions showed no progress(Figure 1d). Another patient had multiple systemic involvement ,including the tongue(Figure 2a)、skin(surgical resection has been performed,and pathologically supported neurofibrom(Figure 2b)、cerevical vertebrae MRI showed space occupancy(Figure 2c)、lumbar vertebrae showed space occupancy(Figure 2d) and the trachea showed a visible tumors. Pulmonary CT showed round soft tissue density shadow in the upper middle section of the right side wall of trachea(Figure 2e) and bronchoscope showed broad basal mass in the upper middle section of the right side wall of trachea(Figure 2f). Intratracheal tumors was resected the mass by bronchoscopic interventional therapy(Figure 2g) and Pathological return were tracheal neurofibroma(Figure 2h). During a fllow-up period of 7 month,the patients was in good condition and lived and worked normally.

Conclusion: Tracheal neurofibroma is a clinically rare benign tracheal tumor. Its clinical manifestations are lack of specificity,wich is easy to be miss diagnosis and misdiagnosed. The diagnosis relies on histopathology. Radiotherapy and drug therapy have no obvious curative effect.Surgical operation is an effective treatment, but the traditional operation is more traumatic.With the development of pulmonology interventional techniques, we can use the bronchoscopic interventional therapy which have good effect on tracheobronchial Neuiofibroma

PO-466
lung fibromatosis

Elhag,Omer
Alneelain university

Objective: to present rare case
Methods: case study

Results: We presented a 32 years old lady referred to our hospital complain of epigastric pain, dry cough for six month. No past history or family history of note, on clinical examination absent breath sound on the right side. Routine laboratory investigations were within normal limits. Chest imaging showed Left lung tissue is normal. There is a huge mass in the rightt side.Abdominal ultrasound reported: urinary system left kidney is higher than the right which is poorly detected. There is a mass (cyst) in the right side above the liver, exploratory posterolateral thoracotomy was undertaken, parietal pleura not thick. huge mass with stamped ribs impression, the tumor was found to extend vertically from diaphragm up to apex of the thoracic cavity and from lateral chest wall to pericardium horizontally, In trial of aspiration there is no fluid. Make pierce string and make hall we discover it's a solid mass, We made a deep incision by incision there was no capsule but we made it. by possibility of mobilization the base of the tumor posteriorly near the thoracic vertebrae it's not attached above the diaphragm but it was involved deep to the abdomen without attachment, the tumor successfully removed. Weight 5 kg. The lung's 3 lobes fully inflated in anatomical and physiological position. Chest tube size 32 Fr attach with underwaterseal was inserted functioning, Histopathological examination of the specimen revealed fibromatosis. Immunological stains were performed and the cells were positive for Vimentin, the blood vessels were positive for CD34.

Conclusion: Conclusion: Fibromatosis are usually solitary , Fibromatosis should always be considered as a possibility while dealing with an intrathoracic/ mediastinal tumor. The disease is potentially curable if diagnosed early. Long term follow-up is strongly recommended for early detection of recurence , Recommendation: fibromatosis should be included in the preoperative differential diagnosis of a lung mass

PO-467

Carinea fistula with endobronchial tuberculosis

Tashi,Eritjan1、Teferici,Alma 1、Kapisyzi FCCP,Prof. Dr. Perlat2
1. University Hospital Shefqet Ndroqi
2. University of Medicine. Faculty of Medicine. Tirana / Albania

Objective: Lymph node TB is the most common form of extrapulmonary TB . In the chest, Mycobacterium tuberculosis can enter the lymphatic system from parenchymal lesions and cause mediastinal and hilar lymphadenopathy due to caseation necrosis and granulation tissue formation. Bronchonodal fistula can occur as a complication of active pulmonary TB with TB lymphadenitis in adult patients, especially in the elderly 1. Tuberculosis lymph nodes in the mediastinum can erode adjacent structures, including esophagus, heart, aorta, and airways through inflammation and necrosis, causing fatal consequences sometimes . Carinal fistula has been reported rarely in association with endobronchial tuberculosis. We report a case of a subcarinal lymphnode fistula in the carina of trachea

Methods: Case report of carinea fistula complicated with endobronchial tuberculosis

Results: A 69 year old woman presented to hospital with a two months history consistent of fever , dyspnoea, malaise and respiratory insufficiency. She has taken several course of antibiotics but without improvement. She had no previous history of lung disease and other diseases Her chest x ray demonstrate diffuse consolidation of the left lung. On chest CT there was massive consolidation with aeric bronchograme of the left lung with subcarinal lymph node with maximal diameter of 5 cm. Fiber optic bronchoscopy revealed cheese-like necrotic materials in the carinea and left main bronchus. A fistulae was noted on the carinea (figure 1). Acid-fast bacilli were detected on a microscopic examination of bronchial-washing fluid and Mycobacterium tuberculosis was isolated in the same specimen. The patient’s cough and sputum were improved after 4 weeks of treatment with an antituberculosis chemotherapy and prednisolone 0.5mg / kg

Conclusion: Lymph node tuberculosis has the ability to erode in the adjacent structures giving rise to endogenous spread and related complication. Carineal fistulae present a rare complication of tuberculosis. Standard treatment with antituberculus present the base of treatment and careful follow up need to be done for late post fibrotic TB complications.

PO-468

Feasibility, Effectiveness, and Safety of a Novel Cryo-Balloon Targeted Lung Denervation Technique in an Animal Model

Wang,Kun1、Sun,Jiaxing1、Gao,Wei1、Chen,Rongzhang1、Wu,Xiaodong1、He,Yanan1、Guo,Qian1、Zhang,Xin2、Li,Qiang1、王琨
1. Shanghai East Hospital， Shanghai Tongji University
2. People’s Liberation Army Joint Logistic Support Force 920th Hospital

Objective: Targeted lung denervation (TLD) is a pulmonary interventional procedure for COPD that aims to disrupt parasympathetic pulmonary nerve input to the lung to reduce the clinical consequences of cholinergic hyperactivity. TLD has been proven to be a safe procedure and can effectively alleviate symptoms and reduce the onset of exacerbation. In the present study, we developed a novel cryo-balloon TLD system and evaluated its feasibility, safety, and effectiveness.

Methods: A preclinical study was performed on twelve sheep, four were tested for airway resistance alterations before and after TLD; two were tested for the Hering-Breuer reflex (HBR) before, immediately after, and 7 days after the surgery; and the remaining six sheep were evaluated for 28 days to assess the safety and effectiveness of the

procedure.

Results: After an observation period of 28 days, significant disruption of vagal innervation to the lung could be validated by both histological and physiological assessments. The operation time was shorter than that in the traditional procedure, with minimal adjacent tissue injury and no device-related adverse events.

Conclusion: The novel cryo-Balloon TLD procedure was feasible, safe, and effective. Further investigations are warranted to improve the industrial design of the balloon and refine the treatment time.

PO-469

Application value of Traditional Laryngoscope combined with Fiberoptic Bronchoscope for Orotracheal Intubation

Yu,Mi、Sun,Jian
The First Affiliated Hospital of Chengdu Medical College

Objective: Objective: To analyze the application value of traditional laryngoscope combined with fiberoptic bronchoscope for orotracheal intubation.

Methods: Method: Sixty-eight patients with orotracheal intubation were selected as the study subjects from November 1, 2018 to November 1, 2019 in Department of Respiratory and Critical care medicine，First Affiliated Hospital of Chengdu Medical College. According to the different methods of endotracheal intubation, the patients were divided into the traditional laryngoscope combined with fiberoptic bronchoscopy group (group A, n=36) and the simple traditional laryngoscope group (group B, n=32). The exposure time of glottis, the time required for successful tracheal intubation, successful cases of one-time intubation, the average number of intubations as well as whether arrhythmia, decreased blood pressure, decreased oxygen saturation, respiratory depression and other reactions occurred during intubation between two groups were compared, and the teeth injury, throat pain and other complications were also observed.

Results: The time required for successful intubation and glottis exposure in group A were shorter than those in group B, and the average number of intubations in group A was less than that in group B, the difference were statistically significant ($P<0.05$). The successful cases of one-time intubation in group A was significantly higher than that in group B, with statistically significant differences ($P<0.05$). The occurrence rate of adverse reactions during intubation was significantly lower in the traditional laryngoscope combined with fiberoptic bronchoscope group than in the simple traditional laryngoscope group ($P<0.05$). The incidence of complications in group A was significantly lower than that in group B, and the difference was statistically significant ($P<0.05$).

Conclusion: Conclusion: Traditional laryngoscope combined with fiberoptic bronchoscope can improve the success rate of one-time intubation, shorten the duration of intubation and glottis exposure time, reduce the number of intubations, and greatly decrease the incidence of adverse reactions and complications during the operation. It is safe and worthy of clinical promotion.

PO-470

Montgomery T-tube placement with Extra-Corporeal Membrane Oxygenation for Cotton-Myer grade IV subglottic stenosis with severe lower tracheal collapse

jin,beibei
Department of Pulmonary Diseases, Beijing Tian Tan Hospital, Capital Medical University

Objective: To report a treatment for a complex airway disease.

Methods: We report Montgomery T-tube placement to treat a case of Cotton-Myer grade IV subglottic stenosis with severe lower tracheal collapse.

Results: A young woman was admitted to hospital due to respiratory distress. Bronchoscopy revealed complete occlusion of the trachea in the subglottic region and the trachea below the tracheostomy stoma had collapsed. We used reverse puncture and balloon dilation to open the occluded upper trachea and finally placed the Montgomery T-tube successfully. During the operation, we used extracorporeal membrane oxygenation therapy to maintain the patient' s blood oxygen and carbon dioxide at a relatively normal level. The T-tube was not cut, and the upper end was 0.5 cm below the glottis. The lower end was at the level of the carina. The recovery of the patient's postoperative vocal function was satisfactory, as was the quality of life.

Conclusion: Montgomery T-tube placement is an effective method for the treatment of the whole tracheal stenosis. Extra-Corporeal Membrane Oxygenation can ensure oxygenation and blood supply during surgically interrupted ventilation.

PO-471

Interventional Bronchoscopic Therapy in Adult Patients with Tracheobronchial Schwannoma

jin,beibei
Department of Pulmonary Diseases, Beijing Tian Tan Hospital, Capital Medical University

Objective: To evaluate the safety and efficacy of interventional bronchoscopic therapy in adult patients with tracheobronchial schwannomas.

Methods: The clinical manifestations, bronchoscopic interventions, complications, and follow-up results of 7 adult patients with tracheobronchial schwannomas were retrospectively analysed. The paired t-test was used to analyse the parameters of the American Thoracic Society Dyspnea Index before and after interventional bronchoscopic therapy.

Results: Tumours occurred in the trachea or main bronchus, and all were easily visualized using bronchoscopy. The symptoms of all patients significantly improved after interventional bronchoscopic therapy. The mean American Thoracic Society Dyspnea Index decreased from 2.29±0.76 to 0.29±0.49 (t=6.481; P=0.001). Bronchoscopic intervention did not result in serious complications or mortality. During the follow-up period (between 1 and 123 months after the last therapy), the following results were noted. Of the two patients with intraluminal type tracheobronchial schwannoma, one was completely cured, and the other was advised to undergo surgery 1 month after treatment. Among the five patients with combined type tracheobronchial schwannomas, three had relapsed and required repeat bronchoscopic interventions, one exhibited worse symptoms, which probably meant relapse, and one was advised surgical treatment.

Conclusion: As an alternative treatment, interventional bronchoscopic therapy demonstrated superiority in some adult patients with intraluminal type tracheobronchial schwannomas. Close follow-up is necessary due to the possibility of tumour recurrence. However, for patients with combined type tracheobronchial schwannomas, surgical treatment remains strongly recommended while interventional bronchoscopic therapy is recommended as a type of palliative treatment.

PO-472

Retrospective analysis of the implementation of painless bronchoscopy in our hospital

zhang,yijie、Zhang,Jie、Jin,Beibei、Wang,Juan、Pei,Yinghua、Qiu,Xiaojian、Wang,Yuling、Yuan,Yuan、张奕杰
Beijing Tiantan Hospital， Capital Medical University

Objective: This study aimed to compare the implementation of painless bronchoscopy under the guidance of optimized work flow before and after the overall relocation of our hospital, so as to provide basis for further optimizing the work flow of painless bronchoscopy.

Methods: Before the hospital relocation from February 8 to May 4, 2018 and after the hospital relocation from April 9, 2019 to May 31, 2019, 129 patients accepted painless bronchoscopy, 79 in group A and 50 in group B respectively. The changes of systolic blood pressure, diastolic blood pressure, heart rate and pulse oxygen saturation (SpO2) were recorded. Vital signs and adverse events between the two groups were compared. Moreover，postoperative visual analogue scale (VAS) was used to observe patients' tolerance and satisfaction to painless bronchoscopy.

Results: The intraoperative systolic and diastolic blood pressure in group B was significantly lower than that in group A [the intraoperative systolic blood pressure in group B was (126.64±16.43)mmHg; the intraoperative systolic blood pressure in group A was (139.42±24.80)mmHg; the intraoperative diastolic blood pressure in group B was (75.29±10.88)mmHg; the intraoperative diastolic blood pressure in group A was (76.53±11.15)mmHg], the difference was statistically significant (P<0.05), and the incidence of intraoperative and postoperative hypotension in group B was not statistically different from that in group A (P>0.05). The intraoperative and postoperative SpO2 in group B was significantly higher than that in group A [the intraoperative SpO2 was 98.60±2.23% in group B, the intraoperative SpO2 was 96.80±2.94% in group A, the postoperative SpO2 was 99.22±0.73% in group B, the postoperative SpO2 was 97.44±2.57% in group A], and the difference was statistically significant (P<0.05). The intraoperative and postoperative heart rate of group B was significantly lower than that of group A [the intraoperative heart rate of group B was (77.45±8.94)%; the intraoperative heart rate of group A was (83.27±15.24)%; the postoperative heart rate of group B was (80.11±9.84)%; the postoperative heart rate of group A was (84.86±17.61)%], the difference was statistically significant (P<0.05), and the incidence of bradycardia between group B and group A was not statistically different (P>0.05).The incidence of tachycardia or bradycardia in group B was significantly lower than that in group A, the difference was statistically significant (P<0.05), while the other adverse events such as hypoxemia, hypertension, hypotension and airway spasm were not statistically significant (P>0.05). Compared with group A, most of the patients in group B had no memory during the operation (P<0.05). Patients in group B were more willing to accept bronchoscopy again and had higher overall satisfaction (P<0.05). There was no significant difference in the degree of discomfort, cough and pain between the two groups (P>0.05). Compared with group A, the satisfaction of interventional respiratory doctors was higher in group B (P<0.05), but there was no significant difference in the degree of cooperation between the two groups (including cough during operation, limb activity, difficulty in passing through glottis) (P>0.05).

Conclusion: After the optimization of painless bronchoscopy work flow, compared with group A, the vital signs of group B were more stable during and after the operation, and the incidence of adverse events was reduced. In group B, the patients' overall satisfaction was improved, and the willingness to re-examination was significantly higher.

PO-473

A multi-center randomized controlled trial to assess the efficacy and safety of superimposed high-frequency jet ventilation interventional bronchoscopy

Pei,Yinghua、Zhang,Jie、Wang,Juan、Qiu,Xioajian、Wang,Ting
Beijing Tiantan Hospital, Capital Medical University

Objective: Superimposed high-frequency jet ventilation (SHFJV) is a new kind of jet ventilation, which uses a combination of high frequency jet ventilation (HFJV) and low frequency jet ventilation (LFJV) simultaneously. We sought to investigate whether SHFJV would provide safe and effective ventilation compared with single-frequency JV techniques in interventional bronchoscopy.

Methods: A multi-center prospective random single-blind clinical trial was conducted by 3 interventional bronchoscopy centers. All the patients, who would accept the diagnostic or therapeutic bronchoscopy procedures, were under general anesthesia. The patients in control group were ventilated by mono-frequency jet ventilation, the patients in trial group were ventilated by SHFJV. The PaO2 and PaCO2 were recorded before the anesthesia, during and after the procedure respectively. The SaO2 and etCO2 were recorded every 10 minutes from the beginning to the end of procedure. Patients would be under observation till 24 hours after bronchoscopy, adverse events would be recorded.

Results: 66 patients were eligible to the trial, 60 patients were included in efficiency analysis. 31 patients were in the control group, and 29 patients were in the trial group. No significant difference in demographic data between two groups. All the procedures performed successfully. In control group, 2 adverse events were recoded (1 transient atrial flutter, 1 tooth loss). In trial group, none adverse event was observed. There was no significant difference about adverse events between two groups. In control group, the PaO2 measured in the operation was 270.42±148.22mmHg, which was higher than that in the trial group (177.10±105.50mmHg, p = 0.023). The PaO2, measured before and after the operation, had no significant difference between two groups. The other indicators (PaCO2, SpO2, etCO2) at each time point had no significant differences between two groups. However, the values of etCO2 in the control group were more disperse than trial group (35.68±13.08mmHg vs 34.88±8.36mmHg, coefficient of variation 0.367 vs 0.240). In control group, when the procedure time was over 90 minutes the etCO2 trended to increase (34.62mmHg vs 45.05mmHg, p = 0.01), while the etCO2 in trial group remained stable (34.98mmHg vs 34.21mmHg, p = 0.594). Moreover, The proportion of cases which PaCO2≥50mmHg during the procedure was higher in control than that in trial group (58.1% vs 31%, p=0.042).

Conclusion: Superimposed high-frequency jet ventilation is effective and safe in interventional bronchoscopy, and it may have some potential advantages in providing more effective and stabilized ventilation than mono-frequency jet ventilation, especially in the cases with long procedure time.

PO-474

Extraction of airway foreign bodies with bronchoscopy under general anesthesia in adults: an analysis of 38 cases

wang,yuling、Zhang,Jie、Wang,Juan、Xu,Min、王玉玲
Department of Respiratory Medicine, Beijing Tiantan Hospital, Capital Medical University

Objective: To explore the efficacy and safety of extracting airway foreign bodies with bronchoscopy under general anesthesia in adults.

Methods: Altogether, 38 adult patients who underwent airway foreign body extraction with bronchoscopy under general anesthesia in the Pneumology Department of Beijing Tiantan Hospital, Capital Medical University, from January 2005 to December 2014 were included in the study and retrospectively analyzed with respect to the extraction methods and complications. The indications and experience, and lessons were summarized.

Results: Of 38 foreign body extractions, 37 were successful, except one case of extraction failure because of massive hemorrhage during the operation. The success rate was 97.4%.

Conclusion: Extraction of airway foreign bodies with bronchoscopy under general anesthesia in adults is safe and effective and can avoid surgical treatment in some patients.

PO-475

Improvement of left ventricular function in a COPD patient after endoscopic lung volume reduction by endobronchial valves. (Case Report)

Porzio,Michele、Yucel,Hasibe、Kessler,Romain、Ohana,Mickael
Nouvel Hôpital Civil

Objective: The degree of hyperinflation with airway obstruction is inversely related to left ventricular filling, stroke volume, and cardiac output. Several studies show that medical lung deflation improves left ventricular function in COPD (1,2). The effects of endoscopic lung volume reduction (ELVR) by endobronchial valves on left cardiac function are still unknown.

Methods: A 57 years old patient has been selected for ELVR according to expert panel recommendations (3). We performed fully pulmonary function test (plethysmography and 6 minutes walking test), chest X-ray and cardiac MRI 1 month before and 6 months after ELVR.

Results: In March 2019, patient underwent left upper lobe ELVR by Zéphyr* valves for severe emphysema atUniversity hospital of Strasbourg. He had a complete atelectasis of the left upper lobe with significant clinical and functional improvement 6 months after ELVR. Cardiac MRI 6 month after treatmentshowed a significant improvement of left ventricular ejection fraction (LVEF), 63% compared to baseline value (49%) and of the cardiac output at 4.41 l/min vs 3.88.

Conclusion: EBV lung deflation seems to improve left ventricular ejection fraction in COPD patients.

PO-476

Complex subglottic tracheal stenosis—silicone stent or T tube?

Wang,Ting、Jie,Zhang、Xiaojian,Qiu、Juan,Wang、Yinghua,Pei、Yuling,Wang
Beijing Tian Tan Hospital, Capital Medical University

Objective: Subglottic tracheal stenosis is a specifically challenging for the treatment, owing to its proximity to the vocal cords. Simple web-like subglottic tracheal stenosis can be managed by endoscopic interventions such as balloon dilatation or laser application, while complex subglottic tracheal stenosis (stenosis≥1cm with cartilage damaged) require silicone or T tube implantation. However, the selection is difficult for physicians. In this study, the efficacy and complications of the silicone stent and T tube for the treatment of subglottic tracheal stenosis were compared.

Methods: Herein, 17 patients with complex subglottic tracheal stenosis, who received silicone stent or T tube implantation, were analyzed retrospectively. Demographic data and findings on various aspects of therapeutic procedures were recorded, and the efficacy of both treatment methods compared.

Results: 6/17 patients received silicone stent implanted, and 11/17 received T tube implantation. The two groups did not differ significantly in terms of stenosis distance to glottis, stenosis length, and stenosis grade. The mean adjacent normal tracheal diameter in the T tube and silicone stent groups did not differ significantly (p=0.350); however, the diameter of T tube was smaller than that of the silicone stent (p=0.048). The stent-to-airway diameter ratios in T tube and silicone stent groups were 0.78 and 0.99, respectively. Compared to the silicone stent group, the T tube group had a higher clinical success rate (p=0.028), a lower rate of granulation tissue formation (p=0.028), and a lower rate of migration (p=0.029). Retention of secretions and mucosal necrosis, observed in both groups, did not differ significantly (p=0.600, p=1.000, respectively).

Conclusion: The unique design of the T tube allows its use in the case of the diameter smaller than that of the trachea and preventing migration. Thus, the friction between the T tube and airway is avoided, preventing granulation tissue formation. Thus, the tracheal T tube is a viable alternative to long-term management of the unreconstructable trachea, allowing support to the airway and adequate phonatory and respiratory function in patients.

PO-477

Paclitaxel-loaded PLGA Coating Stents in the Treatment of Benign Cicatricial Airway Stenosis-A Prospective, One-arm, Multi-center Clinical Study

Qiu,Xiaojian、Zhang,Jie
Department of Pulmonary Diseases, Beijing Tian Tan Hospital

Objective: Airway stent implantation used in the treatment of benign airway stenosis (BAS) can lead to local granulation and scar formation, resulting in restenosis and treatment failure. We systematically investigated a paclitaxel-loaded PLGA-coating stent (PLPCS), which we have developed and tested in vitro and in animals. We analyzed the safety and efficacy of the PLPCS in patients with benign cicatrical airway stenosis (BCAS).

Methods: Patients with BCAS were enrolled from four hospitals in China; control group was excluded for ethical reasons. Patients were observed for six months after implantation, by bronchoscopy performed weekly in the first month and monthly thereafter. To ensure patients' safety, the stent was removed immediately on detection of granulation tissue proliferation, leading to immobility of the stent.

Results: Of the 10 enrolled patients, 6 had tuberculosis and 4 had tracheal intubation. One week after

implantation, all patients had granulation formation, mostly on the upper edge of the stent and the narrowest airway in the stent. All stents were removed in three months (mean: 6.51+4.67 weeks), with curative outcome in one case and ineffective results in two. The remaining seven patients developed complications within three months, necessitating early stent removal. The main complication was granulation formation, resulting in difficulty in stent removal with biopsy forceps. Due to the failure of 90% of cases, the experiment was terminated in advance.

Conclusion: Although PLPCS showed beneficial effects in basic research and animal experiments, it cannot prevent airway restenosis after stent implantation in actual practice, mainly due to granulation formation.

PO-478

Nonstent Intervention Treatment of Airway Stenosis after Tuberculosis

Qiu,Xiaojian、Zhang,Jie
Department of Pulmonary Diseases, Beijing Tian Tan Hospital

Objective: With the increase of floating population and AIDS patients, tuberculosis patients are gradually increasing. 6.4%-40% active tuberculosis patients will appear bronchial tuberculosis, and more than 90% of endobronchial tuberculosis patients will appear different degree of airway stenosis. There are advantages and disadvantages of the previous treatment methods of surgery and stent implantation, which is not suitable for all patients. We used the nonstent intervention treatment method (balloon dilation + cryotherapy + needle electric knife + local drug) for the treatment of airway stenosis after tuberculosis, and have obtained satisfactory curative effects. The efficacy and safety of nonstent intervention treatment method in the treatment of airway stenosis after tuberculosis were studied in this paper

Methods: This study included 24 patients with airway stenosis after tuberculosis, in the Department of respiration, Beijing Tiantan Hospital, Capital Medical University, from January 2015 to April 2017. According to the type of the lesion, the patients were divided into 2 groups, 3 people in the web-like stenosis group, 21 in the complex stenosis. After balloon dilatation, cryotherapy and / or high frequency electric knife, we locally used Mitomycin (MMC) or Paclitaxel by self-made catheter in the lesion. The main evaluation indexes were the curative effect, the improvement rate of airway stenosis and dyspnea index, and the incidence of complications were also observed.

Results: According to our clinical curative effect criteria, 16 cases were cured, 6 cases were effective, 0 cases were ineffective, 2 cases were failure, the cure rate was 66.7%, the effective rate was 91.7%. There were no statistically significant differences in the therapeutic efficacy of different types of airway stenosis (p=0.833), and no serious complications were observed.

Conclusion: In the treatment of airway stenosis after tuberculosis, nonstent intervention therapy can achieve good therapeutic effects and safety, and is worth popularizing in clinical medicine.

PO-479

Electromagnetic Navigational Bronchoscopy-Directed Dye Marking for Localization and Resection of Peripheral Pulmonary Nodules

Wang,Longlong、Li,Jing、Gao,Xing-lin、Chen,Ping-ping、Liao,Ri-qiang、Zhong,Wen-zhao
Guangdong Provincial People's Hospital

Objective: To evaluate the accuracy and feasibility of Electromagnetic Navigational Bronchoscopy (ENB) with pleural dye marking to localize small peripheral pulmonary nodules before Video-associated thoracic surgery (VATS).

Methods: The ENB-localization procedure was performed under general anesthesia in the operating room. Once the locatable guide wire, covered with a sheath, reached the ideal location，it was withdrawn, and 0.2-1.0ml of methylene blue/indocyanine green was injected through the guide sheath. Thereafter, 20-60 ml of air was instilled, in order to disperse the dye to the pleura near the lesions. VATS was then immediately performed.

Results: Study subjects included 25 patients with 28 lesions. The mean greatest diameter of localized pulmonary nodules was 11.8mm (range, 6.0 to 24.0 mm), and mean distance from the nearest pleural surface was 13.4mm (range, 2.5 to 34.9mm). After the ENB-guided localization procedure was completed, the dye was visualized in 23 lesions (82.1%) during VATS. The average duration of ENB-guided pleural dye marking procedure was 12.6 minutes (range, 4 to 30 minutes). The resection margins were negative in all malignant lesions. No complications directly related to ENB-guided localization procedures were observed.

Conclusion: ENB can be used to safely and accurately locate small peripheral pulmonary nodules, to guide their surgical resection.

PO-480

The application of bronchial arteriography embolization combined with fiberoptic bronchoscopy in the treatment of massive hemoptysis

Gao,Xiaoyan、Li,Chenghong
Dept.of Respiratory Medicine , Affiliated Hospital, Jianghan University

Objective: To investigate the clinical value of bronchial arteriography embolization combined with fiberoptic bronchoscopy in the treatment of massive hemoptysis.

Methods: 164 cases of massive hemoptysis were treated by bronchial arteriography and embolization to occlude the bleeding or diseased blood vessels. Fiberoptic bronchoscopy was used to remove the blood or clots in the airway to release the airway obstruction to make the airway smooth, and to identify the cause of the bleeding and the bleeding site, and to use drug to stop bleeding under bronchoscope .

Results: Among the 164 cases, 122cases were cured, 40 cases improved, 2 cases died and no complication occurred.

Conclusion: Bronchial artery embolization combined with fiberoptic bronchoscope is a safe and effective method to rescue patients with massive hemoptysis, minimally invasive surgery, in the clinical treatment of patients with massive hemoptysis is worth popularizing.

PO-481

Slow-pull Capillary Technique versus Suction Technique in Endobronchial Ultrasound-guided Transbronchial Needle Aspiration for Diagnosing Diseases Involving Hilar and/or Mediastinal Lymph Node Enlargement

He,Xin、Wu,Yanjun、Wang,Haoyan、Yu,Ganggang、Xu,Bo、Jia,Nan、Yao,Zhigang
Beijing Friendship Hospital, Capital Medical University

Objective: Endobronchial ultrasound-guided transbronchial needle aspiration (EBUS-TBNA) is a widely used, safe, and accurate technique for obtaining pathological specimens to be used in the diagnosis of diseases involving lung hilar and/or mediastinal lymph node (LN) enlargement. However, the application of the suction technique during EBUS-TBNA remains controversial. In addition, the effectiveness of the slow-pull capillary technique for the diagnosis of pancreatic masses was recently reported. The aim of this study was to compare the diagnostic accuracy of EBUS-TBNA using these two techniques.

Methods: Consecutive patients with hilar and/or mediastinal LN enlargement who underwent EBUS-TBNA between January 2016 and November 2018 at the Beijing Friendship Hospital, Capital Medical University (Beijing, China) were retrospectively studied. The accuracy, sensitivity, specificity, negative predictive value(NPV), positive predictive value(PPV), and availability of tissue cores of the suction and slow-pull capillary techniques were retrospectively studied in patients who underwent EBUS-TBNA for the diagnosis of diseases involving lung hilar and/or mediastinal LN enlargement. Univariate and multivariate analyses were used to evaluate the factors related to the diagnostic accuracy.

Results: A total of 97 patients with hilar and/or mediastinal LN enlargement underwent EBUS-TBNA; 30 patients underwent the suction technique, 56 patients underwent the slow-pull capillary technique, five patients underwent both techniques, and six patients had failed operations. The accuracy, sensitivity, specificity, NPV, PPV, and the number of tissue cores obtained with the suction and slow-pull capillary techniques were 66.67% versus 85.71% ($p=0.039$), 43.75% versus 85.42% ($p<0.001$), 92.86% versus 87.5% ($p>0.05$), 59.09% versus 50% ($p>0.05$), 87.5% versus 97.62% ($p>0.05$), and 19 versus 50 ($p=0.004$), respectively. Assessed the associations with the long-axis diameter of the LN or mass (<30 mm vs. ≥30 mm), short-axis diameter of the LN or mass (<15 mm vs. ≥15 mm), EBUS-TBNA technique (suction vs. slow-pull), acquisition of tissue core, and the final pathology. In both univariate and multivariate analyses, the acquisition of tissue core was significantly associated with the diagnostic accuracy of EBUS-TBNA(odds ratio(OR): 5.244,$p=0.005$; OR: 6.673, $p=0.008$; respectively). Moreover, In both univariate and multivariate analyses, the slow-pull capillary technique was significantly associated with the acquisition of tissue core in EBUS-TBNA(OR: 4.825, $p=0.006$; OR: 4.638, $p=0.023$; respectively). There were no significant differences between the two groups in the blood contamination of samples.

Conclusion: Use of the slow-pull capillary technique in EBUS-TBNA can significantly increase the accuracy related to the diagnosis of diseases involving hilar and/or mediastinal LN enlargement by improving the acquisition of tissue core.

PO-482

Trachea stenosis with Huge Thyroid Goiter

Yamamoto,Satoshi、Kuwahara,Motohisa、Yamamoto,Kozo
Medical Kouhoukai Takagi Hospital, International University of Health and Welfare

Objective: <Background> The tracheal stenosis due to thyroid is almost caused by malignant disease. This tracheal stenosis case is of interest in causing by benign huge thyroid tumor for a long time

Methods: <Case report> 85 year-old female, she has been pointed out 10 cm in diameter upper mediastinal mass with some calcifications and some stridor, however, she rejected any therapy for the disease. Two years later, she admitted our institute for respiratory distress with enlargement of the mass to 15 cm in diameter continued to right thyroid lobe. However, degree of oxygen saturation was well with oxygen mask administration without endtracheal intubation. She agree to operation for reduce the tracheal stenosis.

Results: We underwent general anesthesia with the PCPS standby. The 5 Fr spiral tube was endtracheal intubated, we approached through the third intercostal space. The tumor was soft and located behind of the IVC. We performed puncture the tumor with needle, and aspirated 87ml of dark red internal liquid. We resected partial wall of the tumor and sucked remnant of the internal liquid. By means of this, the tracheal stenosis was reduced. The operation time was 1 hour 54 minutes, bleeding volume was 180ml.

Conclusion: The tracheal stenosis due to benign thyroid huge tumor could reduce by partial resection of tumor wall. This is one of option for huge benign tumor patient with high age and high risk condition.

PO-483

The efficacy of rapid on-site cytological evaluation (ROSE) in determining specimen adequacy and diagnostic accuracy in interventional diagnosis of lung lesions

Yuan,Mingli、Hu,Yi、Yang,Xun、Yin,Wen、Xiao,Yang、Hu,Manman、袁明丽
Department of Respiratory Medicine, Central Hospital of Wuhan, Tongji Medical College, Huazhong University of Science and Technology

Objective: When minimally invasive techniques were used to sample lung lesions, rapid on-site cytological evaluation (ROSE) was recommended in the process to improve diagnostic accuracy, reduce the risk of complications, and enable appropriate specimen triage. We herein focused on the comparison between ROSE and histopathology to evaluate the efficacy of ROSE in determining specimen adequacy and diagnostic accuracy.

Methods: The retrospective study included 127 consecutive cases of lung lesions sampled by bronchoscopy or transthoracic fine needle aspiration (FNA) and diagnosed on ROSE followed by histopathology. ROSE was done by a trained pulmonologist, and the diagnosis of ROSE was compared with final diagnosis.

Results: ROSE successfully confirmed adequacy in 118 cases of the 127 cases. The sensitivity of ROSE in determining adequacy was 97.5%, and specificity in determining inadequacy was 100%. Positive predictive value was 100%, and negative predictive value was 66.7%. The diagnostic efficacy of ROSE for assessing malignancy (sensitivity 94.5% and specificity 100%) and non-malignancy (sensitivity 97.8% and specificity 100%) was excellent. The sensitivity of ROSE for diagnosing small cell carcinoma (100%) was highest, followed by adenocarcinoma (86.5%) and squamous cell carcinoma (75%). ROSE also determined tuberculosis with a high diagnostic sensitivity (83.3%) and specificity (100%).

Conclusion: A trained pulmonologist can reliably carry out ROSE to ensure the adequacy of sample, distinguish between malignancy and non-malignancy, and sub-classify the morphological type of lung lesions in a majority of cases.

PO-484

Consideration of a case of bronchial submucosal vascular malformation

Zhang,Quncheng、Ma,Yun、Chen,Xianliang、Zhang,Xiaoju
Henan Provincial People hospital

Objective: An elderly male farmer presented with a more than 2-month history of hemoptysis. The episodes occurred intermittently, approximately 20 ml blood for each time. There was no medical history in this patient. Computed tomography scan of the chest revealed scattered nodules in both lungs are recommended for dynamic observation. Tracheoscopy showed that the mucosa of the orifice in the dorsal segment of the left lower lobe was raised, and no abnormality was found in the remaining bronchi. Figure 1 shows the diagnosis and trea

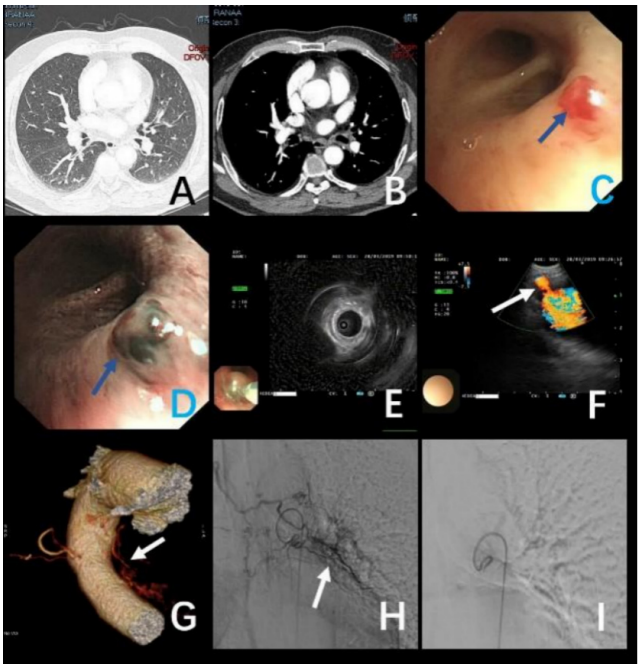

Methods: Figure 1 A、B: No obvious abnormalities were found in normal chest CT and enhanced scanning of chest.C: Tracheoscopy showed that bronchial submucosal blood vessels in the dorsal segment of the left lower lobe were dilated；D： Narrow-band imaging (NBI) showed that the vessels are tortuous and dilatational ；E：A radial ultrasound (20MHz) probe showed fuzzy hypoechoic shadows; F: Convex ultrasound bronchoscopy showed abnormal blood vessel parting from the descending aorta。G：CT reconstruction showed that the bronchial artery was tortuous , and the blood vessels diverged from the aorta；H：Bronchial arteriography shows a network of tortuous vessels；I：The vascular network disappeared after embolization.

Results: In this case, no obvious abnormalities were found in normal chest CT and enhanced scanning of the chest, What should be distinguished from Dieulafoy's disease of the bronchial mucosa is that the lesion was found to be tortuous blood vessels under tracheoscope. The causes of Dieulafoy disease are not clear and it is characterized by the presence of bronchial submucosal arterial dilatation or abnormal artery rupture hemorrhage. When the blood supply arteries enter the bronchial mucosa, the diameter of the diseased arteries remains unchanged and form a small uplifted mucosal lesion with a smooth surface or a small nodule of about 8~10 mm in diameter covered by the normal mucosa, which are susceptible to lethal bleeding that caused by rupture or spontaneous rupture due to external factors. [1] This patient's bronchial artery CTA revealed that the bronchial arteries are tortuous traveling, although it did not meet the diagnostic criteria of Dieulafoy's disease, lesions emanating from the aorta can lead to fatal bleeding during the bronchoscopic biopsy. The abnormal bronchial arteries were successfully embolized after diagnosed by bronchial arteriography with complete resolution of hemoptysis.

Conclusion: Bronchial submucosal vascular malformations are extremely common and the clinical manifestations are mainly hemoptysis. Only plain chest scan or enhanced CT scan may lead to missed diagnosis, while direct bronchoscopy biopsy may lead to fatal hemorrhage. Once encountered a small uplifted mucosal lesion with a smooth surface while performing bronchoscopy, It should be warned that it is the malformation of bronchial arteries or bronchial Dieulafoy's disease. The bronchoscopic biopsy must pay extra attention in case of fatal bleeding when Dieulafoy's lesion is suspected. Endobronchial ultrasound may be conducive to assist diagnosis when conditions permit. [2] Bronchial artery CTA may be the first choice for the diagnosis of suspected vascular malformations and can reveal bronchial artery lumen widened, tortuous traveling. When necessary, bronchial arteriography was performed to confirm the diagnosis and bronchial artery embolization may be successful for treatment.at the same time.

[1] Sweerts M, Nicholson AG, Goldstraw P, et al. Diulafoy disease of the bronchus[J]. Thorax, 1995, 50（6）:697-698. [2] 潘峰 , 王芳 , 刘卓 , 袁飞 , 孙昆昆 , 高占成 , 孙烨 . 支气管 Dieulafoy 病的支气管动脉 CT 造影特点 [J]. 中华结核和呼吸杂志 ,2018,41(12):949-953.

PO-485

TRANSBRONCHIAL BIOPSY RESULTS ACCORDING TO DIFFUSE INTERSTITIAL LUNG DISEASE CLASSIFICATION: CRYOBIOPSY versus FORCEPS. MULTICRIO STUDY.

Pajares,Virginia1、N ú ñez-Delgado,Manuel1,2、Bonet,Gloria1,3、P é rez-Pallar é s,Javier1,4、Mart í nez,Raquel 1,5、Cubero,Noelia1,6、Zabala,Txomin 1,7、Cordovilla,Rosa1,8、Flandes,Javier1,9、Disdier,Carlos 1,10、Torrego,Alfons1

1. Hospital Santa Creu i Sant Pau.Barcelona
2. Hospital Universitario Álvaro Cunqueiro. Vigo.
3. Hospital Universitario de Germans Trias i Pujol. Barcelona.
4. Hospital Universitario de Santa Luc í a. Cartagena， Murcia.
5. Hospital Universitario La F é . Valencia.
6. Hospital Universitario de Bellvitge. Barcelona.
7. Hospital Galdakao-Usansolo. Vizcaya.
8. Hospital Universitario de Salamanca.
9. Fundaci ó n Jim é nez D í az. Madrid.
10. Hospital Universitario de Valladolid. Valladolid.

Objective: In recent years, transbronchial cryobiopsy (TBCB) has come to be increasingly used in interventional pulmonology units as it obtains larger and better-quality samples than conventional transbronchial lung biopsy (TBLB) with forceps. However, there are important methodological differences in the mainly retrospective single-centre studies of TBCB to date, in terms of both technical and experimental design1. To date, only one randomized clinical trial (conducted in a single centre) has compared TBCB and TBLB and analysed the complications associated with each2. No multicentre studies have been performed, however, that analyse and compare TBCB and TBLB safety and yield according to the interstitial lung disease (ILD) classification. We compared the diagnostic yield and safety of TBCB with cryoprobe sampling versus conventional TBLB forceps sampling in the same patient.

Methods: Prospective multicentre clinical study of patients with ILD indicated for lung biopsy. Airway management with orotracheal tube, laryngeal mask and rigid bronchoscope was according to the protocol of each centre. All procedures were performed using fluoroscopy and an occlusion balloon. TBLB was followed by TBCB. Complications were recorded after both TBLB and TBCB.

Results: Included were 124 patients from 10 hospitals. Airway management was orotracheal intubation in 74% of cases. Diagnostic yield was higher for TBCB compared to TBLB for two groups: idiopathic interstitial pneumonias (IIPs) and ILD of known cause or association (OR 2.5; 95% CI: 1.4-4.2 and OR 5.8; 95% CI: 2.3-14.3, respectively). Grade 3 (moderate) bleeding after TBCB occurred in 6.5% of patients compared to 0.8% after conventional TBLB.

Conclusion: Diagnostic yield for TBCB was higher than for TBLB, especially for two disease groups: IIPs and ILD of known cause or association. The increased risk of bleeding associated with TBCB confirms the need for safe airway management and the prophylactic use of an occlusion balloon.

PO-486

Diagnostic Value of Non-Real-Time Radial Probe Endobronchial Ultrasound (RP-EBUS) Guided Positioning Method for Peripheral Pulmonary Lesions

li,ning、Ruan,Ting、李宁
The Affiliated Suzhou Hospital of Nanjing Medical University， Suzhou Municipal Hospital

Objective: The aim of this study was to analyze the diagnostic value of thin bronchoscopy lung biopsy for peripheral pul_x0002_monary lesions under non-real-time guidance of radial ultrasound (RP-EBUS),

Methods: We used a retrospective analysis of ultrasound images of 165 patients with peripheral pulmonary disease ad_x0002_mitted to Suzhou Municipal Hospital Affiliated to Nanjing Medical University from February 2016 to December 2018 who were given RP-EBUS examination. Ultrasound images were obtained for all patients. There were 76 patients treated using traditional positioning method as the control group; 89 patients were treated by probe combined with bronchoscopy positioning method as the research group where the biopsy of the lesion along the path of the ultrasound probe was taken. The positive rate of the 2 methods was observed, and the factors affecting the quality of ultra-thin bronchoscopy under RP-EBUS non-real-time guidance were analyzed.,

Results: The detection rate of the study group was 77.64%, which was significantly higher than that in control group, which was 63.16% (c2 =5.238, P<0.05). The number of biopsies in the study group was 6±1.25, which was sig_x0002_nificantly lower than that of the control group which was 9±1.87 (t=4.116, P<0.05). The diagnostic positive rate of the RP-EBUS probe was significantly higher than that of the RP-EBUS probe (c2 =5.081, P<0.05),

Conclusion: The diagnostic positive rate of RP-EBUS non-real-time guided subtotal bronchoscopy lung biopsy for peripher_x0002_al lung disease using probe combined with bronchoscopy positioning method was higher than the tradition_x0002_al positioning method, and the number of biopsies in the study group was significantly lower than that in the control group, which was related to the size, location, whether the probe was wrapped, or the characteristics of the ultrasound image,

PO-487

A new rabbit model of benign tracheal stenosis and a handy endoscope for observation

Zhang,Guoying、Zheng,Yiming
Second Affiliated Hospital of Fujian Medical University， Respiratory Medicine Center of Fujian Province

Objective: Benign tracheal stenosis is a common disease in interventional pulmonology. Establishing a simple and accessible animal model with less trauma and higher-efficiency and utilizing a convenient and handy endoscopy for observation is of great significance for widely and in-depth study of its pathogenesis and treatment.

Methods: 1.Anesthetized 4kg New Zealand rabbit was intubated with a 4.5 # endotracheal tube (length 14cm,OD 6 mm) by wire-guide technique under direct vision. A stiff nylon brush (length 15cm,OD 6 mm) was inserted through the tube and then the tracheal mucosa was circumferentially scraped by pushing, pulling and rotating the brush 10 times. At the same time, pay attention to the suction of bleeding and postural drainage to prevent airway suffocation.If necessary, 8% norepinephrine should be sprayed in the airway to stop the bleeding.Finally ,the rabbit was returned to the cage for observation after confirmation of hemostasis and resuscitated. 2. A outer-diameter of 3.9mm soft endoscope for industrial use, which cost only a few hundred RMB, was inserted into the trachea through the endotracheal catheter to observe the granulation evolution at the airway injury site and to assess the stenosis severity. 3. Under the guidance of the endoscopy light transilluminated on the skin of the neck, a 30G super fine needle percutaneous puncture of trachea ring clearance was wiggled and adjusted under endoscopic monitoring for local injection of drugs into intracavitary tissue. 4.The hyperplasia and stenosis of granulation in trachea were observed under endoscope at each week after brush injury, and sampling and sacrifice were performed. Gross specimen observation, HE pathological examination and masson staining were performed.

Results: 1. This modeling method could result in 50~80% stenosis in rabbit tracheal, and the healing time curve and pathological evolution of each stage of airway tissue repair were consistent with the tracheotomy modeling method reported in literature.Moreover, this method has low equipment requirements, significantly reduced complications and mortality, and more importantly, it has high stenosis rate, high success rate, and more compliance with animal experiment ethics.2.Acceptable images can be obtained by observing the endotracheal lesion under simple endoscope, and the assessment is accurate.3. It is feasible to intracavitary administration of durg after percutaneous puncture under simple endoscope monitoring.

Conclusion: This animal experiment system has a high success rate of modeling, simple and convenient methods, low requirements for technical equipment, controllable quality and homogeneous, which has the value of being a standard mature model and popularizing.

PO-488

The therapeutic prospect of Integrin-linked kinase in benign tracheal stenosis

Zhang,Guoying、Zheng,Yiming
Second Affiliated Hospital of Fujian Medical University， Respiratory Medicine Center of Fujian Province

Objective: How to regulate the repair process after the injury of airway tissue and inhibit the excessive hyperplasia of granulation tissue and scar contracture are the key links in the treatment of benign central airway hypertrophy and scar stenosis. Integrin-linked kinase(ILK) is a serine/threonine protein kinase, as a central component locating in Focal adhension, participating in the cell-extracellular matrix interactions and multiple signal cross-talk, such as integrin, growth factor, Wnt and TGF- beta/Smad signaling pathways. It play an important role in the regulation of cell adhesion, apoptosis, metastasis, growth, cell cycle, Mesenchymal stem cells differentiation, tumor formation and so on. ILK is widely involved in various stages of tissue injury repair and has become a promising therapeutic target to improve the healing process and reduce scar hyperplasia and contracture. In this paper,we reviews the treatment prospects of ILK in benign hyperplastic and cicatricial airway stenosis.

Methods: 1. Biological characteristics and functions of ILK 1.1 Gene characteristics and protein functions of ILK 1.2 Regulation of ILK activity 2. The role of ILK in tissue damage and repair 2.1 ILK and granulation tissue hyperplasia 2.1.1 ILK and fibroblasts 2.1.2 ILK and vascular endothelial cells 3. ILK and scar contraction 3.1 Myofibroblast transition and contraction 3.2 ECM deposition, remodeling and contraction in wound 4. ILK and mesenchymal stem cells differentiation 5. Underlying mechanism and potential therapeutic prospect of ILK in benign airway stenosis

Results: The small amount of available evidence for ILK is mostly limited to in vitro experiments and a few mouse models.ILK functions have complex environmental dependencies and specific requirements for tissue developmental stages.It is widely involved in tissue homeostasis, development and regeneration, and series connection of various signaling pathways.

Conclusion: There are still many bottlenecks to be overcome for fully understanding and utilizing ILK to improve the outcome of tissue repair after tissue injury.But there is no doubt that ILK's unique kinase domain and bidirectional signal transduction with ECM provide us with beneficial inspirations to understand complex biological processes and new signal transduction mechanisms, which show broad application prospects.

PO-489

Diagnosis and Interventional Bronchoscopy of Primary Tracheal Tumors

Lin,Xiaoping、Zeng,Yiming、Su,Xiaoshan、Lin,Hai
Department of Pulmonary and Critical Care Medicine， the Second Affiliated Hospital of Fujian Medical University；
Pulmonary Medicine Center of Fujian Province

Objective： To explore the clinical characteristics，diagnosis and therapeutic methods，especially interventional bronchoscopy，in order to improve the diagnosis and treatment of primary tracheal tumors.

Methods： A retrospective analysis of the clinical data of 21 patients with primary tracheal tumors admitted to our department during the period of 2006 to 2018 were performed.

Results： Most patients presented with progressing inspiratory dyspnea，misdiagnosed as asthma or chronic bronchitis. All cases accepted chest CT and bronchoscopy，16 cases were confirmed the diagnosis of tracheal tumor by bronchoscopy examination，5 cases were confirmed by surgery.The majority malignant tumors included squamous cell carcinomas and adenoid cystic carcinomas，and the rest were spindle cell sarcomatoid carcinoma，carcinoid，and myopericytoma. benign tracheal cases received surgery and interventional bronchoscopic therapy at the same time. And the main therapy of another cases were interventional bronchoscopy，which consisted of electrocautery，argon-beam coagulation and stenting.

Conclusion： Primary tracheal tumors are rare and early clinical symptoms are unspecific. Early diagnosis can be made by neck-chest CT, and interventional bronchoscopic techniques have important roles in the diagnosis，treatment of benign tracheal tumors，as a way to keep the airway open before subsequent definitive resection and as palliative therapy of advanced malignant tumors. Interventional bronchoscopy to unresectable tumors can lead to symptom remission and life quality improvement .

PO-490

Endobronchial Embolization for Massive Hemorrhage with a New Occlusive Endobronchial Stent

Chen,Yunfeng
The Second Affiliated Hospital of Fujian Medical University

Objective： To explore the effect of endobronchial embolization for massive hemorrhage with a new occlusive endobronchial stent.

Methods： A 67-years-old male who presented with massive hemorrhage was treated by a new occlusive endobronchial stent.

Results： An covered self-expanding occlusive Endobronchial Stent (10*10mm) was deployed under direct visualization and effectively blocking the bleeding site. The stent was removed during the second bronchoscopy procedure with no evidence of re-bleeding and had no recurrence of hemoptysis for 3 months. It is the advantage of the new occlusive endobronchial stent that the thin and flexible stent placement device can pass through the work channel in the bronchoscope, so the stent can be easily inserted any bronchus.

Conclusion： The new occlusive endobronchial stent can be used to treatment the massive hemorrhage.

PO-491

Efficacy analysis of bronchoscopic interventional therapy for benign tracheal stenosis by combination of intelligent imaging analysis system and immunohistochemistry

DuDu,Ying1、Chen,Yunfeng2
1. Quanzhou Medical College
2. The Second Affiliated Hospital of Fujian Medical University

Objective: To assess the efficacy of bronchoscopic interventional therapy for benign tracheal stenosis by combination of intelligent imaging analysis system and immunohistochemistry.

Methods: The therapeutic effect was evaluated by Computed Tomography (CT) image changes, and the effects of thermofrequency and glucocorticoids were analyzed by animal experiments. Eighteen patients with benign tracheal stenosis who were enrolled in 2017.06-2019.06 were enrolled, and the thickness, diameter and lumen area of the most narrow tracheal tube before and after bronchoscopy and 1 month after bronchoscopy were measured using intelligent image analysis software. Thirty male SD rats were randomly divided into three groups (Radiofrequency group, Glucocorticoids+Radiofrequency group and control group). At the 5th, and 28th day the comparisons were made on the pathological changes of rats skin，the average optical density value of TGF-β1 and the collagen density after the damage by Radiofrequency, Glucocorticoids+Radiofrequency.

Results: The thickness, diameter and lumen area of the wall before and after bronchoscopy are: 3.17±1.01mm vs 1.60±0.23mm; 3.61±1.23mm VS 9.04±1.00mm; 11.19±5.32 VS 67.34±13.80 mm2. The scar healing was observed in Radiofrequency group, but in the Glucocorticoids+Radiofrequency group the rats' skin were healed incompletely. The results showed significant statistical differences among three groups on TGF-β1 comparisons: 988.41±111.91，730.19±109.52 and 437.37±60.48 ($P < 0.05$). The same results of comparisons on the collagen density showed: 96540.58±29909.51,43768.16±6264.72 and 34521.15±4636.19 ($P < 0.05$).

Conclusion: After bronchoscopy intervention, the wall thickness of benign tracheal stenosis can be reduced, and the lumen diameter and area can be increased. The results can be analyzed using CT. Locally injected Betamethasone can alleviate the cicatricial tissue hyperblastosis induced by radiofrequency.

PO-492

Analysis of Occlusive Endobronchial Stent for Prohibiting Life-threatening Hemorrhage

Chen,Yunfeng
The Second Affiliated Hospital of Fujian Medical University

Objective: To investigate the efficacy and side effects of a new type of bronchial occlusion stent for life-threatening hemoptysis caused by peripheral lesions.

Methods: The patients with moderate or severe hemoptysis caused by peripheral lesions which were ineffective by routine medical treatment were treated with bronchial occlusion stent. All medical information was recorded retrospectively. Medical imaging is utilized to check the deployment of stents.

Results: In our experiment, 10 bronchial stents were implanted in 10 patients. The immediate hemostasis rate was 100%. The recurrence rate of hemoptysis within one week after stent removal was 20%(2/10), 30%(3/10) had atelectasis and 20%(2/10) had obstructive pneumonia. The stent is a I-shaped structure. The length of the diameter reduction delay is shorter than that of the straight tube stent. The tension of the head and tail is higher than that of the

body. It can be embedded in the soft tissue between the bronchial cartilage to avoid stent displacement. This can be examined using medical imaging and analysis.

Conclusion: The new type of bronchial occlusion stent has the advantages of simple placement, tight packing, no displacement, long hemostasis time and less influence on lung tissue. It can be used for temporary hemostasis in patients with life-threatening hemoptysis. Imaging can be used to observe the stent placement.

PO-493

Local betamethasone injection stabilized the opened-airway diameter in benign central airway stenosis.

Chen,Yunfeng、Zeng,Yiming
The Second Affiliated Hospital of Fujian Medical University

Objective: We assessed the stabilization of an open-airway diameter and locally injected betamethasone for benign central airway stenosis using a prospective study to compare two treatment modalities: Conventional Interventional (CI) and CI combined Local Betamethasone Injected (LBI).

Methods: The average optical density value for tumor necrosis factor β1 (TGF-β1) was compared in local airway tissues before and 7 d after CI and LBI treatments. Patient prognosis was recorded after one year of treatment.

Results: Eight patients were recruited from May 2013 to May 2016 and data show a significant statistical difference in TGF-β1 (94.57 ± 35.77 vs. 155.64 ± 47.38 (t=-7.591, P=0.000) before and after the CI treatment and before and after CI +LBI treatment (145.17 ± 39.38 vs. 84.65 ± 44.34 (t=8.536, P=0.000)). TGF-β1 was measured using ANOVA to compare treatments and there was a statistical difference between the two (F=128.568, P=0.000). Prognoses were effective (6/8, 75%), moderate (1/8, 12.5%), ineffective (1/8, 12.5%) and cured (7/8, 87.5%).

Conclusion: Benign central airway therapy should include opening an obstructed airway and stabilizing the airway diameter as well as a local steroid injection to reduce TGF-β1 and minimize the negative effect of CI.

PO-494

A study on reducing the absorption of lidocaine from the airway in cats

Chen,Yunfeng、Zeng,Yiming
The Second Affiliated Hospital of Fujian Medical University

Objective: To determine if the combination of lidocaine with epinephrine or gamma globulin would decrease the rate or reduce the amount of local absorption of lidocaine through the airway.

Methods: Twenty adult male cats were randomly and evenly distributed into four groups: 1) Group LG: lidocaine administered with gamma globulin; 2) Group LS: lidocaine administered with physiological saline); 3) Group LE: lidocaine administered with epinephrine; 4) Group C: control group. Invasive blood pressure, heart rate, and concentration of lidocaine were recorded before and after administration.

Results: The peak of plasma concentrations appeared difference (Group LG: 1.39 ± 0.23 mg/L; Group LS: 1.47 ± 0.29 mg/L and Group LE: 0.99 ± 0.08 mg/L). Compared to Group C, there were significant differences in the average heart rate of Groups LG, LS, and LE ($P < 0.05$). The average systolic blood pressures were significantly different when each group was compared to Group C ($P < 0.05$). The biological half-life, AUC0-120, peak time, and half-life of absorption among the three groups have not presented statistically significant differences ($P > 0.05$).

Conclusion: Administering lidocaine in combination with gamma globulin through airway causes significant decrease the rate and reduce the amount of local absorption of lidocaine in cats.

PO-495

EBUS-TBNA for the treatment of severe suppurative mediastinal lymph node tuberculosis

Gu,Ye、Sha,Wei、Gui,Xu Wei、Yang,Li
Shanghai Pulmonary Hospital

Objective: Mediastinum and hilum lymph node tuberculosis has a slow onset and long curative effect through conventional drug treatment. We have been exploring an interventional respiratory method to intervene mediastinum and hilum lymph node tuberculosis. This case is a brand new method we have tried.

Methods: The 47-year-old male patient was admitted to the hospital due to cough and fatigue 1 month. Chest CT showed significant enlargement of mediastinal lymph nodes in 4R and 7 groups, which compressed the trachea. He was admitted to the hospital in April 2016.Two weeks later, the patient developed high fever and dyspnea. The lymph nodes in the chest CT review were significantly enlarged within a short period of time, resulting in airway compression and external compression stenosis in the middle and lower trachea. EBUS-TBNA technique was used to puncture the lymph nodes, and a total of 60ml pus was extracted from the lymph nodes in four times. At the same time, 0.3ml Isoniazid was injected each time, and the anti-tuberculosis program was adjusted according to the changes of the disease.

Results: Dyspnea was alleviated 1 week later and the lymph nodes were reduced by 80% 1 year later. No obvious complications occurred during the treatment.

Conclusion: For patients with mediastinal and hilar tuberculosis, EBUS-TBNA was used to extract pus and inject anti-tuberculosis drugs for intervention, which was an effective, safe and feasible method. This minimally invasive intervention allows patients to avoid surgical or stent injuries and complications.

PO-496

A case report of low dosage of apatinib in the treatment of advanced non-small cell lung cancer with positive RET fusion gene

Mu,Chuanyong、Yang,Zhenyu、Wang,Changguo、Jiang,Junhong
The First Affiliated Hospital， Soochow University

Objective: To investigate the therapeutic process of RET fusion gene-positive non-small cell lung cancer and provide guidance for clinical treatment.

Methods: One case of non-small cell lung cancer with positive RET fusion gene confirmed in our hospital was reported. The status and prognosis of the treatment were summarized. In this case, the patient was treated with after the diagnosis. The effect was not good. Since the onset, pemetrexed，cisplatin, docetaxel, apatinib and cabozantinib have been used successively.

Results: After the patient was diagnosed with pemetrexed plus cisplatin for four cycles, the lesions increased earlier; Then the adjustment regimen was docetaxel monotherapy with low dosage of apatinib (250 mg/day) anti-angiogenesis, the lesions were smaller than before, and the remission period was nearly two months. After the disease

progressed again, the cabozantinib (60 mg/day) alone did not work, but combined with low dosage of apatinib significantly increased pleural effusion and improved performance scores.

Conclusion: The RET mutant NSCLC responded poorly to chemotherapy and did not respond well to cabozantinib alone, but patients experienced remission for nearly two months when docetaxel and low dosage of apatinib（250 mg/day） apatinib were combined.And the combination of low dosage of apafitinib and cabozantinib was equally effective.

PO-497
Application of eye mask in fiberoptic

Liu,Huan
West China Hospital, Sichuan University

Objective: Fiberoptic bronchoscopy is an important means in the diagnosis and treatment of pulmonary diseases. However, patients often experience anxiety due to fear of pain, fear of test results, etc. Anxiety not only affects patients' satisfaction, comfort level and willingness to receive repeated examinations, but also affects the procedure, and even increase the risk of complications. Therefore, it is very important to reduce patients' anxiety. This study was to explore whether eye mask can improve patients' anxiety.

Methods: From February 2018 to June 2018, 286 patients from West China Hospital and Sichuan Provincial People's Hospital were randomly assigned to the blindfolded group and no blindfolded group. The patients of blindfolded group were given the eye mask to cover eyes during the fiberoptic bronchoscopy procedure, while the patients of no blindfolded group were given the routine nursing without other intervention measures. Basic information, vital signs, preoperative anxiety score, postoperative anxiety score and comfort score of the two groups were recorded. The differences of anxiety score and comfort score between the two groups were compared.

Results: There was no significant difference in age, gender, education level, preoperative diagnosis, duration of examination and preoperative anxiety score between the two groups. The main reason for anxiety was “worry about examination results”, and the main adverse reaction after fiberoptic bronchoscopy operation was cough. The comfort scores of blindfolded group were higher and anxiety scores were lower than no blindfolded group after the implementation of eye mask ($P < 0.05$). Postoperative diastolic blood pressure was also more stable than that of the no blindfolded group ($P < 0.05$).

Conclusion: Covering eyes during bronchoscope procedure reduced anxiety and improved comfort in patients. As eye mask is a simple and inexpensive way to use, it can be widely used in fiberoptic bronchoscopy, and even other endoscopic examination in the future.

PO-498

A CASE OF ISOLATED UNILATERAL HEMORRHAGIC PLEURAL EFFUSION:A RARE PRESENTATION OF OVARIAN HYPERSTIMULATION SYNDROME(OHSS)

kambhampati,sailaja1、MCV,Sreekar2
1. Medicover institute of medical sciences
2. Mediciti institute of medical sciences

Objective: The number of patients who undergo infertility treatment at IVF centers has been increasing. Therefore, it should be kept in mind that there may be unilateral pleural effusion without peritoneal fluid in OHSS which can be life threatening and needs to be evaluated as soon as possible.Physicians should consider this potentially life-threatening diagnosis in all patients who undergo ovarian hyperstimulation. Here, we present a case with ISOLATED UNILATERAL HEMORRHAGIC PLEURAL EFFUSION due to OHSS.

Methods: observational study

Results: A 30-year old nulliparous woman who has been married for 4 years with no significant medical history enrolled in an IVF center. On the second day of the menstrual cycle there were 9 antral follicles on each ovary and the levels of follicle stimulating hormone (FSH), luteinizing hormone and estradiol (E2) were 6.26 mIU/ml, 2.14 mIU/ml and 18 pg/ml respectively. The spermiogram parameters are normal {sperm count-200million/ml,percentage of motile cells-79%,percentage of abnormal cells-34%}. Ovarian stimulation was initiated with 200 IU of recombinant FSH (rFSH) for 5 days. This dose was increased to 250 IU on the fifth day because of low levels of E2 and low ovarian response. On the 10th day of induction there were two follicles that reached the size of 20 mm and 18 mm as seen on ultrasonography. Her peak E2 level was 1934 pg/ml. Next 10,000 IU urinary human chorionic gonadotropin (hCG) was injected and oocyte pickup (OPU) was performed at the 36th hour. A total of 10 oocytes were retrieved. One embryo transfer (ET) was performed on the third day of OPU. On the 12th day of ET the β-hCG level was 378 IU/ml. On the seventh day after she was β-hCG positive she presented with complaints of dyspnea,cough and chest pain. She had tachypnea(respiratory rate-26/min) and tachycardia(pulse rate-123/min). She had a weight gain of 2 kg and she was afebrile. Her Oxygen saturation on room air was 90% as measured on pulse oximetry. There were no complaints pertaining to the abdomen(nausea,vomiting,abdominal distention). Lab investigations revealed hematocrit of 42% and normal electrolytes,liver and renal functions.Chest x ray was not performed in view of her pregnancy and ultrasound of the abdomen revealed a moderate right pleural effusion . Her echocardiography and electrocardiography (ECG) did not revealed any abnormality.The patient was subjected to an abdominal ultrasound also and the ovaries were enlarged bilaterally (right: 86×63mm; left: 87×59 mm) with no evidence of intraperitoneal fluid. Thoracentesis was performed on the affected side and nearly 1500 cc hemorrhagic coloured fluid was recovered. The fluid analysis showed protein-4.65g/l ,LDH of 101(IU/l) thus fitting into an exudative fluid as per lights criteria. Fluid was lymphocyte and rbc predominant(hemorrhagic) Malignancy , pulmonary embolism were considered in the differential diagnosis and pleural fluid was screened for malignant cells and bilateral lower limb venous Doppler was done which did not revealed any deep vein thrombosis. . She was followed closely as an outpatient and she recovered fully without any sequele

Conclusion: The number of cases resorting to the treatment of infertility and the number of centers where it is employed have been increasing . Although OHSS is considered as if it is a syndrome that belongs to gynecology and obstetrics clinics or IVF units, the chances of clinicians who work in the emergency service and thoracic diseases and thoracic surgery centers encountering these patients have increased. Therefore, it should be kept in mind that there may be unilateral pleural effusion without peritoneal fluid in OHSS.

PO-499

Safety evaluation of modern rigid bronchoscopy and therapeutic procedures

Zhou,Yunchun1、Huang,Haidong2、Yunchun Zhou
1. People's Hosptial of YuXi City
2. Changhai Hospital of The Second Military University

Objective: To evaluate the safety of modern rigid bronchoscopy related therapeutic procedures.

Methods: We retrospectively analyzed the clinical data of a cohort of 100 patients with benign or malignant lesions who underwent the modren rigid bronchoscopy operation from April 2014 to April 2016 at the Interventional Pulmonology Center of Respiratory and Critical Care Medicine of Changhai Hospital of Naval Medical University (Second Military Medical University). A total of received 124 operations of rigid bronchoscopy were involved in. The intraoperative complications of the rigid bronchoscopy were analyzed.

Results : The intraoperative complications of the rigid bronchoscopy were as follows: transient hypoxemia (4.03%, 5/124), injury of vocal cord and around mucosa (4.83%, 6/124), exposure keratitis (1.61%, 2/124), airway structural failure (2.42%, 3/124), damage of electronic bronchoscope (2.42%, 3/124), insertion failure of the rigid bronchoscopy (0.81%, 1/124). There was no intraoperative death.

Conclusion: The modern rigid bronchoscopy is a technique with high safety and low complication worthy of clinical promotion and application. Moreover, we should focus on carrying out the standardized training of the rigid bronchoscopy and related techniques which can improve the safety and reduce the complications.

PO-500

Indwelling Pleural Catheter Tract Metastasis from Renal Cell Carcinoma: A Case Report

Low,See-Wei、Azadeh,Natalya、Sakata,Kenneth
Mayo Clinic Arizona

Objective: Malignant pleural effusion (MPE) contributes significantly to dyspnea, discomfort, and a decreased quality of life. In recent years, utilization of indwelling pleural catheters (IPC) as part of MPE management has increased as they improve patient’s symptoms and quality of life, reduces need for additional pleural procedures, and reduces hospital length of stay. Common complications include: catheter-related pain, pericatheter leakage, catheter displacement, catheter malfunction, and catheter-related infection. A rare complication of IPC is catheter tract metastasis (CTM). CTM typically presents with a new and often painful subcutaneous nodule/mass overlying the IPC insertion site or its tunneled subcutaneous tract. Duration of IPC placement is the most significant predictor for development of CTM. The diagnosis of CTM is made on clinical and radiologic grounds with use of histologic confirmation if there is diagnostic uncertainty. CTM often occurs late, at a median of 280 days post-IPC placement. We describe the first case of CTM resulting from renal cell carcinoma (RCC) and the second case of CTM post-IPC removal.

Methods: This is a case report.

Results: A 54-year-old female had a left IPC placed in March 2017 for a recurrent pleural effusion from RCC. She achieved spontaneous pleurodesis within 2 months and her IPC was removed. Her pleural effusion recurred 4 months later and a second IPC was placed at a separate site, posterior to her initial IPC placement. In January 2018, 10 months after her first IPC placement (8 months after her first IPC was removed), despite targeted treatment with lenvatinib and everolimus, she noticed an area of skin discoloration associated with pain along the previously tunneled tract of her first IPC (Figure A). A computed tomography of the chest was performed and showed presence of a left

lateral chest wall mass (Figure B). An ultrasound-guided biopsy of the chest wall mass revealed metastatic RCC (Figure C), confirming CTM.

Conclusion: This case highlights the importance of recognizing any new soft tissue abnormalities in cancer patients with an IPC or who has had an IPC. This report also describes the first case of CTM due to RCC and the second case of CTM post-IPC removal.

PO-501

Interventional pulmonology and thoracic surgery for the treatment of non-tumor tracheal stenosis

Rusakov,Mikhail、Parshin,Vladimir、Simonova,Maria
Sechenov university

Objective: Non-tumor (cicatricial) tracheal stenosis (NTTS) is a rare but extremely serious disease that significantly impairs the patient's quality of life and can even be fatal.

Methods: The earliest treatments for NTTS were developed through a collaboration between thoracic surgeon M.Perelman and bronchoscopist R.Sarkisian at the Petrovsky National Research Center of Surgery in 1965. Surgery is the main treatment for NTTS. In most cases, interventional pulmonology is used to prepare the patient for surgery. Some patients cannot immediately undergo surgery due to the severity of their condition. If the NTTS is severe, patients should be treated bronchoscopically. Some of these patients may subsequently undergo surgery. We usually perform rigid dilation of NTTS using total intravenous anesthesia and controlled ventilation or balloon dilation with local anesthesia and spontaneous ventilation. Dumon stents and self-made endotracheal tube stents are useful for long-term NTTS expansion. Tracheal resection is the gold standard for surgery. T-tube tracheal reconstruction is used in patients with a proximal tracheal lesion. If a patient has a long NTTS, T-tube tracheal reconstruction of the upper part of the lesion is performed initially, followed by stenting of the lower portion, and tracheal resection several months later.

Results: Surgical treatment for NTTS was first performed in 1963. The first endoscopic dilation was performed in 1965. The first stenting was performed in 1989. From 1963 to 2000, 297 patients were treated and 1112 patients were treated from 2001 to 2019. During these early years, the mortality rate was 50%. By the end of the 20th century, the mortality rate had it decreased to 1%. This happened due to improvements in endoscopic and surgical technique, as well as improvements in anesthesiologic technique. We studied the results for patients seen over the last 19 years: 1112 patients underwent 2799 procedures. We performed 1059 endoscopic procedures (stenosis dilatation, 433; stenting, 346; stent removal, 227; granulation resection, 49; scar dissection, 4) and 1740 surgical procedures (tracheal resection, 451; T-tube tracheal reconstruction, 1289). Overall mortality was 0.7%.

Conclusion: Combined treatment with surgery as well as endoscopy for NTTS significantly reduces mortality. This combined approach to treatment is effective for patients with long stenoses as well as patients with severe illness (e.g., craniocerebral trauma, cerebrovascular accident). The combination of endoscopy and surgery is extremely important in the treatment of extended NTTS and NTTS combined with a large tracheoesophageal fistula.

PO-502

Repositioning of migrated self-expanding metallic tracheobronchial stent: predictors of a successful maneuver and its impact on survival.

Biswas,Abhishek1、Jantz,Michael2、Fernandez-Bussy,Sebastian3、Flanagan,Mindy1、Mehta,Hiren2
1. Parkview Regional Medical Center
2. University of Florida
3. Mayo Clinic， Jacksonville

Objective: We retrospectively reviewed our experience with self-expanding metallic stents and attempted to determine -1) factors related to successful stent repositioning; 2) determine its impact on survival.

Methods: Demographic, medical history, and stent-related procedure factors were extracted from the electronic health record. Primary outcomes were bronchial stent repositioning success and survival (days until death). As validation of successful repositioning, the durations of successful and failed repositioning procedures were compared using an independent t-test.

Results: 76 patients underwent stent repositioning, of which, 55.3% (n=42) were successfully repositioned. The probability of success in repositioning procedures was accounted for by patient sex, stent location, and stent diameter. Females were more likely to have a successful repositioning compared to males. Stent repositioning in the LMS was more likely to be successful and stents larger in diameter tended to increase the likelihood of successful repositioning. Long-term survival was higher for those who had a successful procedure. Stent location and disease subgroups predicted average length of survival.

Conclusion: Repositioning of migrated stents can be successfully performed regardless of the reasons for initial placement, duration of stenting and degree of original obstruction. Larger stents are easier to reposition and so were stents in the left main stem airway. A successful stent repositioning maneuver improved long-term survival although did not have any impact survival in the immediate postprocedural period.

PO-503

Endoscopic guided percutaneous dilation tracheostomy: single center 15-year clinical experience

Peksa,Andra、Zarins,Ainars、Suba,Olegs
Riga East University hospital

Objective: Percutaneous dilation tracheostomy is now routinely performed in ICU setting for patients in need of prolonged ventilation, replacing conventional surgical tracheostomy except for selected cases. Bronchoscopy during the procedure has been applied to shorten the duration of the manipulation and decrease the complication rates1;2. The objective of this study is to asses the indication, timing, length of the procedure and early complications of endoscopic guided percutaneuous dilation tracheostomy.

Methods: A retrospective study at Riga East University hospital was performed and involved patients for whom the data of PDT during the time period of 2004 – 2019 was available. The procedure was performed in ICU setting at the bedside. All the PDT were performed using Griggs technique and commercial Portex kit, all procedures were done under bronchoscopic guidance. Patients received 100% oxygen and the sedation consisted of fentanyl, midazolam and/or propofol as required; individualized for each patient at the discretion of the attending anesthesiologist.

Results: 400 patients' cases were available for analysis, 62% of them were male (247) and 38% (153) were

female. The mean age of the patients was 53,9 ± 18,1 years. The most common reason for the PDT were neurological deficit (52%) and prolonged mechanical lung ventilation (23%). The diagnosis of patients for need of ICU were variable – most commonly due to sepsis (21%), polytrauma (13%) and oncology (8%). The decision to perform PDT was made within 6,5 ± 4,2 days on average of endotracheal intubation. The mean duration of the procedure (from skin incision to insertion of tracheostomy) was 5,5 ± 2,8 minutes (ranging from 2 to 20 minutes). The duration time was influenced by the operators experience and anatomy of the patient. The early complications rate was low (8%) and consistent mainly of minor bleeding in 4,5% of the cases, moderate bleeding was seen only in 1% cases mainly due to coagulation problems, in 1,5% - minor desaturation, 1,5% hypotension during anesthesia, in 0,25% cases – tracheal ring fracture and pneumothorax.

Conclusion: Endoscopic guided percutaneous tracheostomy is safe and relatively quick procedure with low complication rate, that shows it can be safely performed in ICU at bedside. In our center in ICU setting in patients who have no contraindications for the procedure PDT with endoscopic guidance is the method of choice.

PO-504

Combination of cryo and electrocautery approach in diagnosis and treatment of endo bronchial benign lesions

Kapisyzi,Perlat1、Teferici,Alma 2、Taci,Eritjan 2、Peposh,Ilir2、Nuredini,Ornela 2、Kokic,Fahri2、Cami,Alma2
1. Faculty of medicine Tirana Albania
2. University Hospital Sh Ndroqi

Objective: To diagnose and treat benign endobonchial tumors by combination of cryo procedure with electrocautery approach To discover the efficacy of this combination in diagnosis and treatment of typic carcinoid , endobronchial hamartoma and papilomatosis.

Methods: We have made the diagnosis of all cases with endobronchial tumors by cryobiopsy taking big speciments. After confirmation of benign origine of tumor we removed the tumor by combination of cryo approach with electrocauter under general anestesia . We used bronchoflex as tube for intubation through which we put the baloon for hemostasis ans fibrobronchoscop.

Results: We have diagnosed and treated by cryo and electrocauter 7 cases with typic carcinoids three cases with endobronchial hamartoma and one case with tracheal papilomotosis. By devitalisations, debulging and cuting with cryo and electrocautery all patient have been succesfuly treated . The patients have been followed up for more than two years without the recidives up to now.

Conclusion: According these results and orhers authors it is time to replace the surgery with less invasive and safer procedure like combinations of cryo approach with electrocautery in treatment approach of typic carcinoid without lymph adenopathy Diagnosis by cryobiopsy is very safe due to big specimens.

PO-505

Multiple stents for tracheobronchomalacia caused by hydrochloric acid inhalation: a case report

Wang,Jiwang、Sun,Weikui
Department of Respiratory Medicine， The First Affiliated Hospital of Nanjing Medical University

Objective: Tracheobronchomalacia (TBM) is a rare disease characterized by excessive collapsibility of the central airways during expiration. Potential consequences and treatment courses of the aspiration of chemical substances, particularly erosive agents such as dilute hydrochloric acid, are seldom reported.

Methods: Herein, we reported a case of 45-year old female patient with severe TBM caused by the inhalation of dilute hydrochloric acid. The patient was successfully treated with Montgomery T-tube and silicone Y-stent insertion. The use of multiple stents is an effective and minimally invasive intervention for diffuse TBM or tracheobronchial stenosis developed from the inhalation of corrosive substances.

Results: A 45-year-old female presented with dyspnea for 7 weeks and aggravating for 4 days. Seven weeks beforehand, the patient experienced dyspnea after falling into a hydrochloric acid pool. The concentration of hydrochloric acid was 20.0%. The arterial blood gas (ABG) analysis revealed respiratory failure type I. Tracheotomy and MV were promoted subsequently in local hospital. Seven weeks later, she was transferred to our hospital. Bronchoscopic view evidenced obvious subtotal stenosis (about 80%) in the middle and upper parts of trachea. Therapeutic measures contained laryngeal mask ventilation, balloon dilatation and provisional Ultraflex covered stent placement (Figure 1). Figure 1. Bronchoscopic picture during endoscopic therapy. A-C. Balloon dilatation at the level of tracheal stenosis; D. Provisional Ultraflex covered stent. On the 11th day of admission, bronchoscopic examination revealed that the covered Ultraflex stent was in position but obviously narrowed during expiration, with obviously collapsed subglottic primary bronchi. The functional Ultraflex stent should not be removed. And a Montgomery T-tube was inserted urgently (Figure 2). Figure 2. Bronchoscopic view before and after Montgomery T-tube insertion 15 days after the placement of covered Ultraflex stent. A. Obvious subglottic malacia and narrow; B. Montgomery T-tube insertion; C. T-tube; D. Obviously narrowed lower margin of Ultraflex stent. On the 37th day of admission, a silicone Y-stent was implanted under rigid bronchoscopy. The symptoms remitted obviously. A repeat chest CT revealed significant improvement in tracheal stenosis (Figure 3). Figure 3. Silicone Y-Stent insertion under rigid bronchoscopy. A. Ultraflex stent was in place; B. Obvious collapse and malacia of carina during expiration; C-D. Silicone Y-stent insertion; E-F. Postoperative chest CT and three-dimensional reconstruction of trachea. She was discharged 44 days after the hospitalization.In 4 months after discharge, she presented with hoarseness. The symptom disappeared 1week later after pruning the upper branch of t tube. In a 15-month follow-up granulation was the main complication observed.

Conclusion: Chemical inhalation injury related to extensive TBM in adults has been rarely reported. In this report, the patient developed TBM because of the inhalation of hydrochloric acid and successfully treated with multiple airway stents insertion.The close follow-up is required because of the problems associated with the airway stents, such as granulation formation, airway restenosis and recurrent respiratory infections . And the supporting function of airway cartilage was need to be evaluated, which relating to the removal of airway stents.

PO-506

Aetiologic diagnosis and the efficacy of interventional treatment of 39 cases of intraluminal central airway spheroid masses.

Wang,Jiwang、Song,Wei
Department of Respiratory Medicine， The First Affiliated Hospital of Nanjing Medical University

Objective: To explore the aetiologic diagnosis of, clinical characteristics of and effects of interventional therapy for intraluminal central airway spheroid masses.

Methods: Thirty-nine patients with intraluminal central airway spheroid masses were summarized retrospectively, and the clinical characteristics were analysed.

Results: Among 39 patients, cough and shortness of breath were the predominant symptoms, followed by haemoptysis, fever and chest pain; only 1 patient was diagnosed by physical examination. The aetiologic diagnoses were 12 cases of inflammatory granulomas, 5 cases of foreign matter, 4 cases of squamous carcinoma, 3 cases of leiomyoma, 2 cases each of lipomyoma and inflammatory myofibroblastic tumor, and one case each of glomus tumor, adenocarcinoma, mucoepidermoid carcinoma, malignant melanoma metastasis, carcinoid, adenoid cystic carcinoma, chondrosarcoma, mixed tumor, neurilemmoma, acidophilic adenoma and salivary gland tumor. The numbers of masses located in the trachea, left main bronchus, right main bronchus and right middle bronchus were 20, 12, 5, and 2, respectively. High-frequency electrocautery was the most commonly used interventional therapy method, followed by argon plasma coagulation and cryotherapy; stent implantation was used in 1 case. Thirty-one cases achieved a complete response or partial response after treatment, 7 cases achieved a mild response, and 1 had no response

Conclusion: The symptoms of intraluminal central airway spheroid masses were atypical and easily misdiagnosed or missed; benign lesions were the leading cause, and the first pathological type was inflammatory granuloma. Endoscopic intervention was an effective, safe technique.

PO-507

Study of the variations in tracheobronchial anatomy through bronchoscopy

Kumar,Abhisheka1、Rai,Deependre2
1. Netaji Subhas Medical College and Hospital
2. All India Institute of Medical Sciences， Patna

Objective: Tracheobronchial variations (TBV) can be found during routine bronchoscopy or computed tomography. Bronchoscopy is widely used diagnostic tools in pulmonary medicine. Although tracheobronchial variation are easily appreciated during bronchoscopy they are often neglected. Most of the cases don’t present with any symptoms and are detected incidentally.However, symptomatic patients may present with similar symptoms including: cough, hemoptysis, and recurrent episodes of respiratory infections(1). Moreover, clinicians should consider the possibility of tracheobronchial malformations, to avoid complications prior to certain procedures such as therapeutic bronchoscopy, lung resection, and tracheal intubation(2). Objective 1. To evaluate the presence of trachea-bronchial variation among patient who underwent bronchoscpoy. 2. To determine common Trachio-bronchial Variation in our region.

Methods: We investigated 600 consecutive reports and videos of flexible bronchoscopy retrospectively irrespective of indication and outcome. Out of 600, 52 reports were excluded because of partial visualization of tracheobronchial tree due to poor patient cooperation, stenosis, mass lesion etc. All the relevant data is collected along with pictures and analyzed.

Results: Variations of the tracheobronchial tree were found in 152(27%) of the patients examined by bronchoscopy with 65.4% in men and 39.4% in women. In our study,81.5% of the TBV were observed on the right bronchial system, 28.2% on the left, and 0.7% in the trachea. The most frequent finding was a bifurcate pattern (Fig.1c)in the right upper lobe (7.2%) followed by four segmental bronchi(Fig. 1a & Fig.1b) in 4.3%.Four cases (0.7%) had tracheal bronchus (Fig.-3). The most frequently observed TBV were right lower lobe basal orifice with two openings(Fig.5a), left upper lobe with three openings(Fig.2), accessory opening in basal segments of right lower lobe(Fig.5b &5c). In the same lung, single variation and two different TBV were seen in 86.8% and 23.6% of patients, respectively. In three cases, hypoplasia right middle lobe bronchus was found (2.6%) and in another 2.6% cases trifurcated opening (Fig.4) seen.

Conclusion: The present study display variation of Tracheobronchial tree in Indian Population. Right upper lobe presents the highest frequency of bronchial anatomical variations in the subjects undergoing bronchoscopy. Understanding of tracheobronchial variation have important implications for diagnosis of symptomatic patients and performing certain procedures including but not limited to bronchoscopy, endotracheal intubation and lung resection. The explanation of the difference between the reported variations may be due to genetic and racial factors, and there is also the possibility of sub-registers in the bronchial variations reported in the available literature.

PO-508

Preoperative Injection of Biological Glue Can Prevent Pneumothorax Cause by Pneumornocentesis in Rabbits

Chen,Xiaoyang、Shi,Liyong、Zeng,Yiming
The 2nd Affiliated Hospital of Fujian Medical University

Objective: Pneumothorax is a common complication of pneumornocentesis. This study is aim to explore a method to reduce the incidence rate of pneumothorax in pneumornocentesis.

Methods: A total of 8 male New Zealand rabbits were subjected to CT guided pneumornocentesis with one lung as the experimental side and the other side as the control side. After anesthed with 1% amobarbital , lung puncture point was marked. In the experimental side, under monitoring of CT, medical biological glue (n-butyl cyanoacrylate) 0.5ml was injected with 22G syringe into the junction of the pleura and the lung. After the biological glue was solidified for one minute, under the monitoring of CT, 12G needle biopsy needle was inserted into the lung along the original puncture point. In the Control side, under the monitoring of CT, 22G syringe was used to simulate injection, then 12G needle biopsy needle was inserted into the lung along the original puncture point. CT was used to observe the occurrence of pneumothorax. Rabbits were killed after lung puncture, and the puncture local adhesion was observed in both gross specimen and pathological specimen.

Results: Pneumothorax was not seen in the lungs of all rabbits of experimental groups injected with biological glue before lung puncture, while pneumothorax was found in all the lungs of all rabbits of control group without injection of biological glue. In gross specimen, local pleural adhesion was observed at the point where biological glue was injected. In pathological specimen, deposition of amorphous substance was observed at the point where biological glue was injected.

Conclusion: Before lung puncture, local injection of adhesions can significantly reduce or even prevent the occurrence of pneumothorax. For some patients with poor lung function, who underwent lung biopsy or other lung puncture related interventional therapy, this operation has important clinical value.

PO-509

Nebulized Ipratropium Bromide Protects against Tracheal and Bronchial Secretion during Bronchoscopy: A Randomized Controlled Trial

WANG,FAPING、Zheng,He、Zhang,Yanlin、Zhu,Hui、Shi,Jingyu、Luo,Yunxiao、Zhang,Xiang、Mao,Hui、Luo,Fengming
West China Hospital, Sichuan University

Objective: Mucous hypersecretion during brochoscopy is a big issue for bronchoscopist, which makes the procedure is hard to perform and increases the procedure time. Anticholinergic premedication has been investigated prior flexible bronchoscopy, but studies have yield no consistent results. The protective ability of ipratropium against airway secretions during bronchoscopy had not been evaluated previously. Therefore, we performed a double-blind randomized trial to investigate whether ipratropium bromide premedication influences airway secretions, patient discomfort, and procedure time.

Methods: This was a single randomized, double-blind, placebo-controlled trial ((Trial Registration: chictr.org.cn: ChiCTR1800016881) conducted in west china hospital, Sichuan University (Chengdu, China). Totally, 250 patients undergoing fiberoptic bronchoscopy participated in this randomized, placebo-controlled, double-blind study from June 2018 to December 2018. Patients were randomized 1:1 to receive nebulized 4ml ipratropium bromide (1mg, n=125) or placebo (n=125) for 15 minutes as premedication 20 to 40 minutes before bronchoscopy. Airway secretions, bleeding,

patient discomfort, procedure time, and procedure-related adverse events were compared between the groups.

Results: Nebulized ipratropium bromide prior bronchoscopy could reduce airway secretions and patient discomfort (P= 0.02, P= 0.00, respectively), but not tracheobronchial bleeding or procedure time (P= 0.51, P= 0.36, respectively). Chest nodule or mass was the most common indication for performing bronchoscopy. The adverse events were similar, and hypertension is the most common complication.

Conclusion: Nebulized ipratropium bromide prior bronchoscopy is a more satisfied regimen that shows a practical benefit on the airway secretions and patient comfort, while these effects may not translate into any marked reduction in bleeding or procedure time under general anesthesia. We suggest that routine nebulized ipratropium bromide premedication for bronchoscopy can be useful and beneficial.

PO-510
A novel and convenient pleural biopsy

Shi,Liyong、Chen,Xiaoyang、Zeng,Yiming
The 2nd affiliated hospital of Fujian Medical University

Objective: This study aims to achieve reverse direction of pleural biopsy and find an effective way to diagnose pleural diseases.

Methods: ① One male New Zealand rabbit was subjected to X-ray guided pneumornocentesis with one lung as the experimental side introduced the needle and pillow core of the device into the chest cavity to get a sense of breakthrough after the routine location of the puncture point and the disinfection of the cloth, withdrew from the pillow core, and established an artificial pneumothorax model. ② Under the guidance of X-ray, make the puncture needle enter the range of 0.5-1.0cm in the chest cavity, fix the device, avoid the puncture needle entering the chest cavity too deep, after exiting the pillow core, insert the biopsy forceps of the device along the outer sleeve needle, continue to enter the biopsy forceps while operating the steering handle, so that the biopsy forceps gradually turn to realize the opposite direction alignment with the parietal pleura. ③ Under the control of the operating handle, when the wire on one side is extended, the wire on the other side is shortened to realize the turning of the biopsy clamp. When the end of the biopsy clamp touches the parietal pleura, the biopsy handle is operated for biopsy. ④ After biopsy, exit the biopsy forceps, and when re-entering the biopsy forceps, change the direction of the biopsy forceps entering the chest cavity, so as to achieve different parts of the second biopsy and the last biopsy, and achieve multi-directional and multi-site biopsy.

Results: The method overcomes the limitation of pleural biopsy and solves the different problems of current methods of pleural biopsy.

Conclusion: In this experiment, the innovative and reverse puncture direction pleural biopsy made multi-directional and multi-site biopsy, which can be applied to the X-ray operation and blind examination that improving the accuracy rate of diagnosis, save costs, avoiding surgical trauma, and also suitable for use in primary level hospitals.

PO-511

A case of Airway Stenosis Caused by Proton Treated by Sapphire Contact Laser via Bronchoscope

Shi,Liyong、Chen,Xiaoyang、Yiming,Zeng
The 2nd affiliated hospital of Fujian Medical University

Objective: To observe effect of Sapphire Contact Laser via Bronchoscope

Methods: We present a case of a 67yr man，CT showed nodule in right middle lobe in 2012. He didn’t make diagnosis and treatment until 2013, clarified diagnosis of lymph epithelioma-like carcinoma by TBNA, then had lobectomia pulmonalis and chemotherapy. The patient suffered recurrent tumor in 2016 and lymthnode pathology suggests squamous-cell carcinoma. Then he treated with chemotherapy combined Proton radiotherapy. The man began to cough with dyspnea in 2017 and diagonosed with tracheostenosis by CT and bronchoscope showed the 7cm away from glottis appears a narrow (4.5mm). The pathology of TBLB suggested inflamtion, we thought tracheostenosis was caused by Proton. The patient was treated with sapphire contact laser via bronchoscope.

Results: Radiotherapy for lung cancer often leads to pneumonitis or lung fibrosis.Proton reduce these toxicities and have fewer side effects due to physical characteristics of proton beams which called Bragg peak. Few studies reported radiation pneumonitis caused by proton but the patient appeared. After the treatment of sapphire contact laser, the diameter of narrow increased to 6.5mm and breathless alleviated.

Conclusion: Proton also cause radiation damage like tracheostenosis and sapphire contact laser via bronchoscope has good curative effect.

PO-512

Occlusion of postoperative refractory bronchial stump fistula with a ovale foramen occluder under a bronchoscope after assessment with virtual bronchoscopy navigation: report of one case

Yu,Haoda1,2、Huang,Haidong2、郁昊达
1. Department of Respiratory and Critical Care Medicine， Wuxi People’s Hosptial Affiliated to Nanjing Medical University
2. Department of Respiratory and Critical Care Medicine， Changhai Hospital Affiliated to Naval Military Medical University

Objective: To explore a new method for the treatment of refractory fistula after transcatheter closure of

Methods: The paper retrospectively analyzed the clinical data of one case diagnosed as stump bronchopleural fistula and right upper lung empyema after right upper pneumonectomy. After the failure of various plugging methods including silicone plugs and Y-silicon stents, the researchers tentatively applied the rigid bronchoscope combined with the flexible bronchoscope under general anesthesia. Subsequently, the oval foramen occluder was built into the fistula to seal the fistula under virtual bronchoscopic navigation (VBN). Finally, the relevant experience and lessons were analyzed and summarized.

Results: The oval foramen occluder successfully blocked the right side of the upper lobe operation stump fistula mouth. One week later, the chest computed tomography fluoroscopy (CT) was re-examined and it was found that the right purulent cavity was significantly reduced.The patient without discomfort after the removal of thoracic tube was discharged smoothly.

Conclusion: The paper adopts the method of sealing postoperative bronchial stump fistula with oval foramen occluder under VBN, which provides a new strategy for the interventional treatment of refractory bronchopleural fistulas. Different types of occluders are chosen as the atrial septum occluder, the ventricular septal occluder, and the oval foramen occluder. According to the results of VBN assessment, the bronchial pleural fistula in the patient is characterized by a large fistula diameter and a thin wall. Moreover, oval foramen occluder better matches the fistula mouth of the patient due to the small left and right disc spacing and large volume of right disc, which is the reason for the successful closure. Such type of occluder needs to be further improved in the insertion method and the sealing effect. It is expected that the occlusion device dedicated to bronchial stumps will be available.

PO-513

Impact of lung volume reduction by valves (LVRV) on dynamic hyperinflation (DHI): Preliminary results from the PIERCE study

Fumat,Romane、Dupuis,Marion、Favard,Florent、Plat,Gavin、Mhanna,Laurent 、Hermant,Christophe、Didier,Alain、Egenod,Thomas、Guibert,Nicolas
Toulouse University Hospital

Objective: After 5 positive randomized controlled trials; LVRV has entered the treatment landscape of severe emphysema. This procedure significantly improves exercise capacity but changes in FEV1 are sometimes limited. A better understanding of the pathophysiological mechanisms underlying its effectiveness is needed to improve patient selection. We hypothesized that the improvement at exercise could be linked to a decrease of dynamic hyperinflation (DHI, defined as a decrease ≥ 500 ml in maximal inspiratory capacity at exercise), a phenomenon known to be responsible with dyspnea in these patients.

Methods: Patients with severe emphysema (FEV1 15-45%) and hyperinflation (RV > 175%) with little to no collateral ventilation (defined with StratX and if necessary Chartis) are being included in this bicentric prospective study (Toulouse and Limoges University Hospitals, France). Dyspnea (mMRC), quality of life (QoL, VQ11 questionnaire), exercise capacity (6MWT), lung function (FEV1, RV, FVC), gas exchanges, and DHI are assessed before and 3 months after LVRV and will be assessed at 12 months.

Results: 15 patients have been included in the study (8 Toulouse, 7 Limoges). Median mMRC, FEV1 and FVC change was 100 ml (+13%), 320 ml (+13%), and +1, respectively. Median distance at 6MWT was improved by 42 m. At the time of analysis, 3 months DHI are only available for 5 patients, showing an improvement in 4/5 (median decrease 800 ml). These very preliminary results are summarized in the table. Interestingly, in 1 patient (#2) where dyspnea was dramatically improved (mMRC 3 to 1) without change in FEV1 or CVL, DHI showed clear improvement (960 ml variation), explaining the improvement in tolerance at exercise and highlighting the limitations of static measurements to investigate LVRV outcomes. Complete DHI data for 15 to 20 patients will be available for presentation at the meeting.

Conclusion: These very preliminary results suggest that bronchoscopic lung volume reduction improves dynamic hyperinflation and that this dynamic evaluation can a better assessment of exercise capacity than static measurements, potentially explaining the discrepancy often observed between improvements in symptom and exercise capacity and stability of FEV1.

PO-514

Clinical application of photodynamic therapy for respiratory tumors in China

Jin,Faguang1、Wang,Hongwu 2、Li,Qiang3、Bai,Chong 4、Zeng,Yiming 5、Lai,Guoxiang 6、Guo,Shuliang 7、Gu,Xing 1、Li,Wangping 1、Zhang,Haitao1
1. Department of Respiratory and Critical Care Medicine, Tangdu Hospital, Air Force Military Medical University
2. Department of Respiration, China Emergency General hospital
3. Department of Respiratory and Critical Care Medicine, Shanghai East Hospital of Tongji University
4. Department of Respiratory and Critical Care Medicine, Changhai Hospital, Naval Military Medical University
5. Department of Respiratory Pulmonary and Critical Care Medicine, The Second Affiliated Hospital of Fujian Medical University
6. Department of Respiration, The 900th Hospital of Joint Service Support Force
7. Department of Respiratory Pulmonary and Critical Care Medicine, The First Affiliated Hospital of Chongqing Medical University

Objective: With the development of interventional pulmonology, Photodynamic Therapy (PDT) is gradually used in the treatment of respiratory malignant tumors because of its small trauma, high specificity, and compatibility with traditional or common therapies. However, at present, the data of clinical evidence-based medicine for PDT applied in central airway tumors is very limited, mainly from case reports or series of case studies, lacking consensus on clinical diagnosis and treatment.

Methods: In order to further disseminate China's experience, Tumor Photodynamic Therapy Committee of China Anti-Cancer Association and the World Endoscopy Association-Respiratory Endoscopy Association invited experts from relevant fields to form an expert committee, and the expert consensus is developed based on international research progress, Chinese clinical experience and research status by searching PubMed, Embase, Cochrane Library, and Chinese Journal Full-text Database (CJFD), China Science and Technology Journal Database and WanFang database, etc.

Results: After several rounds of discussion and revision by the expert committee, the consensus is formulated after the vote, for reference by the physicians in respiratory department, oncology and other related disciplines refer to the practice of tumor photodynamic therapy.

Conclusion: Photodynamic therapy of pulmonary airway tumors is effective and safe, but it still needs to be strictly implemented in accordance with the regulations.

PO-515

Necrotizing tracheobronchitis by invasive aspergillosis

Carboni Bisso,Indalecio、Las Heras,Marcos、Videla,Carlos、Villarroel,Sonia、San Rom á n,Eduardo
Hospital Italiano de Buenos Aires

Objective: BACKGROUND

Invasive aspergillosis is a fungal disease that usually affects the airways or lungs, and may present extrapulmonary dissemination. However, tissue invasion is rare and occurs more frequently in the context of immunosuppression. Immunocompetent people, despite being regularly exposed to aspergillus, only develop invasive disease exceptionally. A functional ciliary clearance and alveolar macrophages action provides great resistance to aspergillus species. Aspergillus tracheobronchitis is a rare but serious form of invasive aspergillosis that almost exclusively affects lung transplant patients.

We present the case of an immunocompetent patient who developed necrotizing tracheobronchitis due to invasive aspergillosis.

Methods: CASE REPORT

A 28-year-old female patient on admission presented fever, abdominal pain and jaundice of 48 hour evolution that rapidly worsen into hemodynamic decompensation and multiorgan failure.

She required mechanical ventilation, hemodynamic support with high doses of vasopressors and emergency renal replacement therapy.

On 9th day of hospitalization, a bronchoscopy was performed as endoscopic guide for percutaneous tracheostomy.

During bronchoscopy, pseudomembranes of necrotic tissue were visualized in the lower third of the trachea, carina, right main bronchus and left main bronchus. A bronchial mucosa biopsy performed by cryoprobe evidenced positive growth for Aspergillus fumigatus and pathological anatomy with accumulation of hyphae. Antifungal systemic treatment with liposomal amphotericin B and weekly topical instillation of voriconazole was initiated, leading to notorious improvement of tracheobronchial lesions.

No immunosuppression was diagnosed during hospitalization.

Results: -

Conclusion: CONCLUSION Necrotizing tracheobronchitis due to invasive aspergillosis is a rare but potentially lethal disease, exceptionally reported in immunocompetent patients. Antifungal systemic treatment is the first-line therapy, however this case reports a successful topical instillation with voriconazole in lung lesions.

PO-516

Tracheobronchial Rhinosporidiosis – A Rare Cause of Endobronchial Obstruction

Sarkar,Nirmal Kanti、Mia,Mofizur Rahaman、Hasan,Rejaul 、Islam,Md. Sayedul
National Institute of Diseases of the Chest and Hospital

Objective: Rhinosporidiosis is a chronic granulomatous infectious disease caused by mesomycetozoea Rhinosporidium seeberi. This highly recurrent polypoid lesion commonly affects nose and nasopharynx. Though it may involve different body parts, involvement of tracheobronchial tree is very rare, and poses challenge for diagnosis and management. We are presenting a case of tracheobronchial rhinosporidiosis, who presented with bronchial obstruction, developed acute respiratory distress and prompt intervention salvaged life.

Methods: A 30-year-old male of rural background presented to primary care physician with dry cough for 6 months and was treated as a case of asthma. Four months later, he developed hemoptysis and breathlessness. He was seen by a pulmonologist and fiberoptic bronchoscopy (FOB) was done. Histopathology revealed rhinosporidiosis. He was referred to our institute. He is a farmer and had habit of dipping in pond water to catch fish. He gave history of surgery of nasal mass two times eight and five years back respectively. On admission, he was dyspnoeic with absence of breath sound in right lung and poor air entry in left lung. Next day he developed sudden respiratory distress with fall of SpO2 below 35%. Emergency rigid bronchoscopy was done under G/A. A mulberry like mass was seen completely occluding the lower trachea with bleeding. Mass was removed as much as possible by forceps and gentle suction. Bleeding was secured. Post-operative period was uneventful.

Results: Follow-up FOB one week later showed complete clearence of tracheal mass and some residual lesion in proximal right principal bronchus and left supraglottic region. Dapsone was started 100 mg/day. Electrocautery was done via rigid scope to remove the residual lesion. Second follow-up FOB was done 1 month later, showed clearance of bronchial lesion and reduced size of nasopharyngeal mass. He continued dapsone for 1 year then stopped by himself. Follow-up FOB 1 year thereafter showed no recurrence of disease.

Conclusion: Rhinosporidiosis in tracheobronchial tree may be secondary to implantation of spores from previous surgery for nasal/nasopharyngeal rhinosporidiosis. Delay in the diagnosis may lead to life threatening airway obstruction as occurred in our case. Prompt bronchoscopic intervention can save life.

PO-517

A case of a man with TB history proven to be non small cell lung cancer

Xu,Xiaoyi1、Li,Jing2
1. Shantou University Medical College
2. Department of Pulmonary and Critical Care Medicine, Guangdong Provincial People's Hospital, Guangdong, China

Objective: Non small cell lung cancer (NSCLC) presents in various forms on imaging study. In order to raise physicians' awareness of this, we present a case of a man with NSCLC misdiagnosed as tuberculosis.

Methods: A 55-year-old man presented with cough was admitted on 2019-08-20. His serial X-Ray checkup in 2017 showed tuberculosis lesion, concerning which he was diagnosed to have tuberculosis and received a full course treatment for 1 year after which the chest X-ray showed recovery and a residual cavity. 2 days prior to admission, the patient's routine chest X-ray checkup showed increased size of the cavity. On admission, a PPD skin test was done and bronchoalveolar lavage fluid (BALF) was gained for microorganism examination. Percutaneous lung biopsy focus on the lesion in the cavitation was performed.

Results: PPD showed no redness, nodules, blisters or ulceration at 48 hour and 72 hour respectively. The BALF cultured no bacteria, fungi or mycobacterium TB. However, percutaneous lung biopsy found dysplastic tumor cells and finally through histochemistry, NSCLC was diagnosed.

Conclusion: Patients with only imaging evidences suggesting tuberculosis (TB) but without other clues should not be simply treated as TB, especially for those elderly who had a negative PPD test. Bronchoscopy and biopsy should be performed to look for evidence of TB and exclude the possibility of cancer. NSCLC occurs in various forms and extra attention show be paid for not missing the diagnosis.

PO-518

Primary ectopic meningiomas of upper airway : a case report

Li,Xiao、Ma,Yun、Qian,Haoyu、Pan,Jinbing
Henan Provincial People's Hospital

Objective: Background Ectopic meningiomas are a rare finding with a wide range of clinical feature. They have been described in a variety of locations, most commonly (90%) in the head and neck region. Occasionally, they are found in the lungs, mediastinum and retroperitoneum. So far, no case on ectopic meningioma of airway were reported. Here, we report a case of ectopic meningioma of upper airway.

Methods: Case report A 21-year-old male patient presented at our department complaining of chest tightness for more than a month. The patient had a history of tonsillectomy. There was no history of smoking, tuberculosis, malignant tumor, or cancer in the family. Thoracic computed tomography (CT) examination imaging showed a 1.8 × 1.6 cm mass with clear boundaries in upper trachea. Neoplasm from upper trachea (approx. 18× 16 × 10 mm) which almost obstruct the lumen was seen during bronchoscopy. The texture of the neoplasm was tough and the basilar part was on

direction of 12 o'clock in trachea. The patient received high-frequency electrocautery snare, transbronchial cryobiopsy and argon plasma coagulation (APC) treatment via bronchoscope. The symptoms of the patient disappeared after bronchoscopy.

Results: Pathology revealed that the lesions were composed of spindle cells covered with ciliated columnar epithelium and squamous epithelium. Necrosis, cholesterol crystallization, foam cell aggregation, keratin cyst formation are present. The immunohistochemistry results were: progesterone receptor (+), epithelial membrane antigen (EMA) (+), SSTR2 (+),vimentin (+), Ki67 (+) 1%, CD34 (+), CK (-), CD5/6 (-), Desmin (-), GFAP (-) , P63 (-) , S-100 (scattered +), SAM(focal+), and SOX-10 (-) (Fig 1). A 2 months follow-up, airway mucosa of the patient recovered fully after treatment by tracheoscopy. No mucosal abnormalities were detected on magnetic resonance imaging (MRI).

Conclusion: Conclusions We report a case of ectopic meningioma of upper airway and the treatment through bronchoscopy for the first time. Ectopic meningioma usually have a good prognosis after the tumor removal, but long-term follow-up was required.

PO-519

Flexible endoscopic combined diathermy-laser resections in malignant tumors of larynx, trachea and bronchi.

Gurau,Petru、Petru Gurau
Rebublican Clinical Hospital "Timofei Mosneaga"

Objective: Minimally invasive interventions in malignant airway tumors present clinical interest in view of improvement of patients life quality and obtaining radical curative outcome. Effectiveness of combined diathermy-laser resections, using flexible endoscopic approach, in malignant laryngotracheobronchial tumors is presented.

Methods: Combined diathermy-laser resections were performed on 60 patients with malignant tumors of larynx (46) and tracheobronchial tree (14). Larynx pathology was represented by scuamous cell carcinoma (23), spindle cell carcinoma (2), verrucous carcinoma (18) carcinosarcoma (2) and metastatic melanoma (1). In 23 cases primary tumor was diagnosed at T1 stage, in 22 cases – at T2 stage. In 35 patients treatment was limited by endoscopic intervention, in 11 cases postoperative radiotherapy was done. In 27 cases endoscopic operations were performed under local anesthesia with premedication, in 19 cases – under general anesthesia with high frequency jet ventilation (HFJV). Tracheobronchial pathology was represented by typical carcinoid tumor (6), atypical carcinoid tumor (1), adenoid cystic carcinoma (3), scuamous cell carcinoma (2), metastatic melanoma (1) and metastatic breast cancer (1). In 2 cases (adenoid cystic carcinoma and atypical carcinoid tumor) endoscopic intervention was supplemented by postoperative radiotherapy. In 11 cases HFJV was used, in 3 cases interventions were performed under local anesthesia. After snare diathermy excision of the exophytic component of the tumor, Nd:YAG laser vaporization of the residual tumor was performed, flexible laser guide being introduced through the working channel of "Olympus" therapeutic fiberbronchoscope.

Results: In larynx tumors, positive effect (local control with organ preservation) was obtained in 42 from 46 patients (91 %). Average follow-up period constituted 57 months. Treatment failure (recurrence or tumor progression) was registered in 4 cases in time interval from 1 month up to 7 months after intervention. In tracheobronchial tumors local control without recurrence or tumor progression was registered in 9 from 10 patients (90%), treated with radical curative intention (follow-up period varied from 7 months up to 12 years , average - 39 months). In 5 cases a good palliative effect was obtained (in none of the cases deaths was caused by respiratory insufficiency due to tumor obstruction).

Conclusion: Obtained results permit us to state, that using of combined diathermy-laser resection is an effective minimally invasive approach for the treatment of malignant tumors of the larynx, trachea and large bronchi in the presence of a prominent exophytic component, allowing obtaining a radical curative effect for limited tumors in

selected patients and a good palliative effect for inoperable tumors. Snare diathermy excision permits shortening of intervention time, at the same time laser ablation favours radicalism of the operation.

PO-520

Bronchoscopic Cryotherapy as a Bridging Therapy in the management of Endobronchial Mucoepdermoid Carcinoma

Pantas,Jim Paulo、Rago,May Crystel、Teo,Dennis 、Panugayan,Krislyn 、Lejos-Sabado,Marilyn
Manila Doctors Hospital

Objective: One of the complications of a mucoepidermoid carcinoma (MEC) that have obstructed a bronchus is recurrent cough and pneumonia, mimicking symptoms of asthma, COPD or lung infection. Chest radiograph and chest CT scan can reveal a mass or nodule. Routine bronchoscopic biopsy is the preferred procedure for diagnosis; however, its yield is quite low due to only a small amount of tissue gathered. Cryotherapy is a new and evolving tool that could enhance the diagnostic yield of such tumor.

Methods: We report a case of a low-grade mucoepidermoid carcinoma (MEC) at the left main bronchus in a 23-year woman who came in for non-resolving pneumonia presenting as cough. Chest Xray and Chest CT scan revealed atelectasis of the left lung with a soft tissue density at the left main bronchus hence bronchoscopy was done. Initial bronchoalveolar lavage (BAL) and tissue biopsy only showed acute on chronic inflammatory pattern. Hence, patient underwent follow up bronchoscopy with cryotherapy.

Results: The left main bronchus was recanalized by tumor debulking with the use of cryotherapy. Post operatively, patient's symptoms improved. The histopathology of the mass revealed a low grade mucoepidermoid carcinoma. Immunohistochemical studies noted that the mass was positive to mucocarmine and p63 and was negative on TTF1. The patient was later re-admitted after 6 months for surgical intervention Patient underwent explorative thoracotomy with pneumonectomy of the left lung and adhesiolysis. She was able to tolerate the procedure well and was discharged stable. Final histopathology report of the resected left lung showed no residual tumor left. Lymph nodes and superior margin of the tumor were negative for malignancy.

Conclusion: Endobronchial mucoepidermoid carcinoma (MEC) of the lung is a rare pulmonary neoplasm comprising only <1% of all lung tumors. The obstructed airway caused by the neoplasm can be worsened by mucous secretions and development of mucous plugs, hence patients with such carcinoma can have dyspnea and recurrent pneumonia. Routine bronchoscopic forceps biopsy can be used to diagnosed such condition; however, the diagnostic yield is very low. A new evolving diagnostic and therapeutic tool called the bronchoscopic cryotherapy can increase diagnostic yield up to 95%, improved patient symptoms, and can serve as bridging therapy prior to actual surgical intervention.

PO-521

Case report of bronchoscopy in the treatment of adult tracheal mucoepidermoid carcinoma

Zhang,Quncheng1、Ouyang ,Wenjuan2、Zhang,Xiaoju1
1. Henan Provincial People hospital
2. First Affiliated Hospital of Henan University

Objective: Research the bronchoscopy intervention of BMEC .

Methods: A 69- year- old woman was admitted to the hospital because of "chest tightness and cough for 2 years". The patient had no obvious cause of chest tightness and cough in the past 2 years, and it can be aggravated during severe activities. He was diagnosed as “ asthma” and “pneumonia” in the hospital, and the symptoms of anti-infective and anti-asthmatic treatment were not improved.Neoplasm was visible in the upper part of the trachea by bronchoscopy. The wide base was about 4cm long and blocked the airway by about 90%(Fig.A). The high-frequency electric coiler and laser were used to treat neoplasm (Fig. B). The tracheal cavity was enlarged significantly and the lens body passed smoothly (Fig. C). The pathological report of tissue biopsy: (new biopsy in the trachea) parotid tumor, combined with immunohistochemistry results, consistent with mucoepidermoid carcinoma .After a week, bronchoscopy showed necrosis in the middle of the trachea, and the trachea was smooth, repeated freezing and thawing at the base, argon knife burning to reduce local recurrence(Fig. D). There was no obvious discomfort after operation, and the symptoms of chest tightness and cough were obviously improved and discharged.

Results: The patient's chest tightness and cough symptoms improved significantly after surgery,and have no adverse reactions.

Conclusion: Fiberoptic bronchoscopy, the use of an electric ring, argon plasma coagulation, laser, cryotherapy and other interventions to remove the tumor, avoid thoracotomy to reduce trauma, preserve lung tissue, relieve the tumor obstruction of the airway to improve lung function, And the incidence of adverse reactions is low.

PO-522

Large emphysematous bulla with iatrogenic fistula from chest tube placement treated with endobronchial valves insertion

Gabrilovich,Michael
Kettering Health Network Fort Hamilton Hospital

Objective: Background: Endobronchial valve placement is an accepted modality to treat selected patients with emphysema. Bullas occupying 30% or more of the hemithorax are considered contraindication to the procedure although several cases of successful use were reported.

Methods: Case report

Results: 65 yo male with an extensive smoking history and minimal healthcare exposure presented with hypercapnic and hypoxic respiratory failure. CXR demonstrated right sided lucency suspicious for pneumothorax (Fig 1a) and 14 Fr chest drain was inserted by the ER physician, patient was intubated and admitted to ICU. CT chest demonstrated residual pneumothorax and chest drain inside the dominant bulla (Fig 1b). Patient’s condition remained tenuous, thoracic surgery evaluation deemed patient not a surgical candidate, air leak persisted and, eventually, decision was made to place endobronchial valves to collapse bulla and allow for removal of the chest drain and to safely place chest tube into the pleural space. Three 7mm Spiration valves were inserted into segmental bronchi of the right upper lobe. Follow up imaging demonstrated significantly decreased size of the dominant right sided bulla with chest drain

out of it. As bulla continued decreasing in size, several pneumothoraxes occurred treated with chest drain and talc pleurodesis. Eventually, percutaneous tracheostomy was placed, air leak decreased, patient was weaned to tracheostomy collar during the day and transferred to long term acute care hospital for further weaning and treatment.

Conclusion: To our knowledge this is the first case describing endobronchial valves use to collapse large bulla with accidental placement of chest drain into it. Notably an option of last reserve, it is, however can be an effective tool when significant decrease in size of large bulla is needed and surgery is not feasible.

PO-523

Diagnosis and treatment of adult airway foreign bodies

Wu,Yanjun、He,Xin、Yu,Ganggang、Jia,Nan、Xu,Bo、Wang,Haoyan、Yao,Zhigang、吴艳军
Beijing Friendship Hospital, Capital Medical University

Objective: To collect clinical data of adult patients with airway foreign bodies and summarize the experience of diagnosis and treatment of the disease.

Methods: The clinical data of adult patients with airway foreign bodies admitted to the department of respiratory medicine of Beijing Friendship Hospital in the past 5 years were retrospectively analyzed.

Results: A total of 8 patients were included, all male, the age range is 55 to 87 years old. The main clinical symptoms were cough, sputum, labored breathing and hemoptysis. The foreign bodies of the 7 patients were located in the right airway, and the remaining 1 patient was located on the left side. Foreign bodies are beans, peppers, bones, glass fragments and dentures. Flexible bronchoscope operating instruments included foreign body clamps, freezers, baskets, and lasers. The lung CT data of 2 patients were missing. The lung CT of the remaining 6 patients showed that the glass and pepper showed high density and the beans showed low density. Under the bronchoscope, the foreign bodies obstructed the corresponding airway, and the airway mucosal lesions caused by different foreign bodies have different characteristics.

Conclusion: The clinical manifestations of adult airway foreign bodies patients are different, and the severity of the disease is also different. Different operating instruments should be taken according to the characteristics, the location and the degree of adhesion to the surrounding airway of the foreign body.

PO-524

An unusual foreign body hidden in bronchial tree: case report

Ibrahim,Ashraf、Said,Ahmed、Nafae,Ramadan
Zagazig University

Objective: Intrabronchial foreign bodies are occasionally encountered in adults. We report the case of a 24-year-old male, non-smoker with history of surgery for mitral valve replacement 14 years prior to the onset of chronic cough, expectoration, fever and hemoptysis. The patient condition started one year ago managed as recurrent right sided pneumonia at the same side.

Methods: Chest x-ray revealed wedge shaped consolidation in lateral aspect of right mid and lower lung zones. Computed tomography showed Peripherally located right middle lobe Soft tissue lesion of homogeneous opacity Size about 4x6 cm with soft will demarcated margins with surrounding area of bronchiectasis. Upon exploring the tracheobronchial tree using the fiberoptic bronchoscope, surgical gauze was found. The foreign body aspirated 14 years ago during postoperative intensive care period from the oropharyngeal cavity into the trachea and impacted in the lateral

segment of middle lobe.

Results: The foreign body was successfully removed and managed by fiberoptic bronchoscopy; argon plasma coagulation (APC) as an interventional modality used, the patient symptoms disappeared rapidly with marked radiological improvement. This occurrence has not been previously reported in the literature. As previously reported cases of surgical gauzes migrate to tracheobronchial tree from mediastinum

Conclusion: Our case of Neglected Large pieces of surgical gauze 14 years, successfully managed with 2 sessions of FOB plus APC under conscious sedation. Bronchoscopists planning to use the fiberoptic bronchoscopy in foreign body removal should be aware of the problems and hazards which may ensue if improperly managed and preparing the proper interventional modality for it.

PO-525

The application of HybridKnife in the treatment of airway stenosis caused by refractory tuberculosis: A case report

Li,Chunmei、LI,Wangping
the Second Affiliated Hospital of Air Force Medical University， Air Force Medical University

Objective: The objective of this report was to investigate the treatment of airway scarring and stenosis caused by refractory tuberculosis. The stenosis was located in the distal portion of the left main bronchus and was severe, as the diameter of the bronchus in the affected region was less than 2 mm. Because long-term treatment with several conventional methods, including cryotherapy, thermal ablation, local injections, and balloon dilation—which were used either alone or in combination with other methods—was ineffective, HybridKnife was used to widen the region in the which the scarring and stenosis were located and was then combined with the above conventional therapies to further treat the stenosis. These interventions prevented permanent loss of lung function and enabled the patient to avoid surgery. Future studies should further explore the feasibility and advantages of using HybridKnife in the treatment of airway stenosis caused by refractory tuberculosis.

Methods: The patient was a 17-year-old female who, on March 13, 2017, presented to our outpatient clinic with left main bronchial stenosis. Chest CT indicated that there was significant narrowing in the distal left main bronchus and atelectasis in the left lower lobe. Bronchoscopy was subsequently performed every 1-2 weeks to relieve the stenosis. After a needle electrotome was used to loosen the scarred tissue, a balloon was used to dilate the bronchus. One cycle of cryotherapy was administered 1 week later, and then balloon therapy and a reexamination were completed 2 weeks later. One week thereafter, an additional cycle of balloon therapy was completed, and the area of scarring was sequentially frozen and thawed. The following week, the area of scarring was again treated with a needle electrotome. However, none of these treatments were effective. The patient was reluctant to undergo either endotracheal stent implantation or surgery; her family expressed similar concerns. Thus, she underwent further interventional therapy via tracheal microscopy. A balloon was used to enlarge the left main bronchus after the area of scarring and stenosis was treated with HybridKnife. The patient subsequently underwent 1 cycle of balloon therapy combined with cryotherapy, 1 cycle of acupuncture combined with balloon therapy and cryotherapy, 9 cycles of cryotherapy, and 8 cycles of localized infusions of 5 mg of dexamethasone. These treatments resulted in significant enlargement of the left main bronchus; reexamination showed that the diameter of the bronchial lumen was approximately 8 mm. No restenosis was observed at the patient’s subsequent follow-up visits, which took place 2 and 4 weeks thereafter. Results: The patient was initially reevaluated twice per month, and then she was reevaluated once every 3 months and once annually. She was last examined on January 23, 2019, at which time she was found to have mild stenosis of the distal left main bronchus, a finding indicating that her outcome was satisfactory.

Results: The patient was initially reevaluated twice per month, and then she was reevaluated once every 3 months and once annually. She was last examined on January 23, 2019, at which time she was found to have mild

stenosis of the distal left main bronchus, a finding indicating that her outcome was satisfactory.

Conclusion: Benign airway stenosis is difficult to treat. This patient's condition was refractory to conventional and long-term treatments. We used HybridKnife to relieve the stenosis, which minimized the adverse effects of the natural repair process triggered by therapeutic injury. The patient was treated with a combination of HybridKnife and conventional therapy, which resulted in a satisfactory outcome. Thus far, there are no other reports on the application of HybridKnife in the treatment of tuberculous-induced scarring and stenosis. Therefore, the value of HybridKnife in the treatment of tuberculous-induced airway stenosis requires further study.

PO-526

Safety and efficacy of manual aspiration (MA) in facilitating the outpatient management of transbronchial biopsy-related iatrogenic pneumothorax (TBBX-IP).

Matus,Ismael1、Wilton,Shannon2、Mertens,Avalon2、Raja,Haroon1
1. Helen F. Graham Cancer and Research Institute, Christiana Care Health System
2. Department of Medicine, Christiana Care Health System

Objective: Evaluate manual aspiration's safety and efficacy as a first line intervention in facilitating safe outpatient management of transbronchial biopsy-related iatrogenic pneumothorax (TBBX-IP).

Methods: IRB-approved prospective observational study performed between 5/2017 to present date. Inclusion criteria includes patients with large TBBX-IP ("large" as per BTS or ACCP criteria, defined by either >2cm between the lung margin and the chest wall at the level of the hilum or >3cm from the apex to the cupula) or symptomatic pneumothorax.Exclusion criteria include: unstable patients - defined as any patient with cardiopulmonary instability that would require hospitalization. A management algorithm was implemented (figure 1.)

Results: At a 29 month interim analysis, 475 transbronchial biopsy procedures had been performed by interventional pulmonologists. Our incidence of iatrogenic pneumothorax was 2.5%(12/475). Manual aspiration was attempted and successful with discharge to home without SBCT in 8 of the 11 (66.6%) without readmissions or reinterventions required. One patient had unsuccessful MA, but discharged with SBCT in place and office follow up with SBCT removal within 48h (8.3%). Three patients (25%) that failed MA required SBCT and admission under observation status in hospital until SBCT could be removed. The leading MA-related procedural complications were patient-reported symptoms including chest pain, pleurisy, dyspnea and chest pressure.

Conclusion: Our treatment algorithm incorporating MA demonstrates safety, efficacy and potential cost-savings for the management of TBBX-IP. Our institution's admission rate for iatrogenic pneumothoraces reduced from 100% to 25% via the implementation of this algorithmic management approach. A 75% discharge rate with close outpatient follow up and minimal MA-related patient reported symptoms is highly encouraging for further studying this treatment approach in the management of TBBX-IP.

PO-527

Effects of tracheal intubation on respiratory function.

terniche,mourad、Mahioud,Madjid、Kermi,Khaled、Aitouarab,Farah、Ousoulah,Arezki
service pneumologie Algiers

Objective: Postoperative respiratory complications are common. Morbidity related to respiratory dysfunction remains significant

Methods: 200 patients , 02 years (January 2011-July 2012). The evaluation was carried out by studying epidemiological data, etiological risk factors, factors related to patient terrain, surgery and anesthesia. She later became interested in the respiratory complications that occurred after surgery.

Results: 33 patients experienced complications, representing an incidence of 16.5%. The average age of patients was 42.4 years [15-84 years] with male predominance. COPD and smoking are the most common respiratory risk factors found in patient histories with 46.5% and 43.5% respectively. Acute respiratory insufficiency, infection and atelectasia were the most common complications encountered 5.5%, 4.5% and 4%, with an average duration of 3 days. Postoperative analgesia was provided by non-steroidal anti-inflammatory drugs and paracetamol in general. The trend was favourable in 83.5% of cases and 6% died of septic shock (42%), postoperative hemorrhage (17%) and respiratory failure on atelectasis (17%).

Conclusion: pulmonary complications include acute respiratory failure, acute respiratory distress syndrome (ARDS), atelectasis, bronchial congestion, acute upper airway obstruction, inhalation pulmonary disease, bronchial fistula, pulmonary edema, pulmonary embolism, and pleural effusion (hemothorax, pyothorax). In our series, acute postoperative respiratory failure was the second complication with an incidence of 4.5%. COPD was the primary risk factor for post-operative complications ,46.5% of patients were COPD , 28% of whom were complicated.75% of deceased patients were COPD .the use of bronchial endoscopy for intubation must be previlegic

PO-528

Electromagnetic Navigation Bronchoscopy (ENB) and Thoracic Surgery live in perfect harmony.

Martucci,Nicola、De Luca,Giuseppe、La Rocca,Antonello、La Manna,Carmine
Division of Thoracic Surgery. Istituto Nazionale Tumori – IRCCS – "Fondazione G. Pascale". Naples (Italy)

Objective: Electromagnetic Navigation Bronchoscopy (ENB) is bronchoscopic technique promises accurate navigation to peripheral pulmonary target lesions and to mediastinal lymphadenopathy, using a virtual three-dimensional (3D) bronchial map from a preoperative chest Computed Tomography (CT) scan. In this way the ENB facilitates the thoracic surgeon in the diagnosis and surgical interventions of pulmonary and mediastinal lesions

Methods: Thirty five patients with pulmonary and mediastinal lesions were evaluated by a multidisciplinary team (thoracic surgeon, endoscopist, oncologist and radiologist) in order to assess the feasibility of the ENB for diagnosis and surgical resection. Patients with mediastinal lymphadenopathy and peripheral pulmonary nodules were enrolled and the procedure was carried out under general anesthesia, using the "superDimensionTM Navigation System"

Results: Eighteen lesions were located in the lung while 17 patients had mediastinal lymphadenophaty. According to the cases, during EBN peripheral lung nodules underwent FNAB and mediastinal nodules were sampled by means of transbronchial or transtracheal FNAB. Correct diagnosis was obtained for 16 out of 18 (88.9%) patients with mediastinal lymphadenopathy and for 13 out of 15 (86.7%) patients with peripheral pulmonary nodules. In two cases, lung nodules were marked with ENB and indigo carmine dye in order to identify and remove them in VATS. No complications were recorded and all patients recovered uneventfully.

Conclusion: ENB is one of the essential tools for thoracic surgeons. It is extremely useful for the diagnosis of pulmonary nodules especially in patients unfit for invasive diagnostic techniques. The use of ENB-guided dye marking for the localization of peripheral pulmonary nodules, followed by minimally invasive resection is a feasible and safe procedure with outstanding success rates.

PO-529

Case Report: Use of heparin solution in fibrinolysis of pleural catheter

Omaña,James
Perpetual Help Medical Center Las Piñas

Objective: BACKGROUND Tissue-plasminogen activator, urokinase, and streptokinase are the usual fibrinolytics used in pleural catheters.

Methods: CASE REPORT In a 54-year-old female diagnosed with breast cancer with recurrent pleural effusion, an intrapleural catheter was inserted initially, but had problems with drainage days after the catheter was inserted, leading to sequentially decreasing pleural fluid output. She then started to have dyspnea and shortness of breath. Flushing of the pleural catheter was attempted, but was unable to drain the infused saline solution. Due to the distress of the patient, and the unavailability of the fibrinolytics, heparin solution was instilled in the catheter.

Results: The next day, there was improvement in the drainage output of the pleural catheter with subsequent relief of the dyspnea of the patient.

Conclusion: CONCLUSION This case exemplifies that although known fibrinolytics are the best option to use, infusion of a heparin solution can be an alternative.

PO-530

Successful Palliative Cryoablation and Recanalization of Invasive Follicular Thyroid Carcinoma Encroaching into the Trachea

Tanyag,Portia Maria、Gonong,Joven Roque
Lung Center of the Philippines

Objective: The aim of this case report is to present a rare case of advanced invasive follicular thyroid carcinoma in a 24 year old female presenting as a tracheal tumor and is successfully treated with palliative cryoablation and recanalization.

Methods: A 24 year old female was referred to the Lung Center of the Philippines due to a tracheal mass noted on CT scan of the chest and neck which presented as hoarseness of voice and episodes of massive hemoptysis that started 8 months prior. Patient had poor recollection of a thyroid surgery she had in a surgical mission for her enlarging neck mass 2 years preceding the referral. Patient also claimed of progressive exertional dyspnea and noticeable weight loss, yet denies fever and dysphagia. On physical examination, there was a clean incisional scar on the base of the neck. There were no cervical lymph nodes palpated.

Results: A repeat CT scan of the neck and chest showed a lobulated enhancing mass of about 2.3 x 2.6 cm at the right thyroidectomy bed encroaching into the trachea with 70% luminal narrowing. There were multiple non-calcified pulmonary nodules on both lungs. Patient underwent rigid bronchoscopic cryotherapy biopsy, ablation and

recanalization of the tracheal mass by general anesthesia, total intravenous anesthesia via jet ventilation. On rigid bronchoscopy, there was noted a wide-base smooth mass attached to the anterior surface of the second and third tracheal ring, obstructing 70% the tracheal lumen. Frozen section of the mass revealed atypical follicular cells favors thyroid carcinoma. Tracheal mass was signed out as invasive follicular thyroid carcinoma. Thyroid function test showed significant elevation of TSH at 31.927 IU/L (NV. 0.55-4.78 IU/L), FT3 and T4 were within normal limits. Reevaluation of the upper airway was done after 7 days, and completion cryoablation was performed. Patient was discharged stable, comfortable and non-oxygen requiring after 10 days of confinement. Patient underwent radioactive iodine treatment as outpatient. As of this writing, 6 months post cryotherapy, patient is still alive, up and about, no report of recurrence of hemoptysis, and non-dyspneic.

Conclusion: A 24 year old female with advanced invasive follicular thyroid carcinoma enchroaching to the tracheal lumen successfully underwent a palliative coring out and ablation of the tracheal mass using cryotherapy.

PO-531

Cryotherapy Recanalization of Primary Tracheal Squamous Cell Carcinoma

Tanyag,Portia Maria、Gonong,Joven roque
Lung Center of the Philippines

Objective: This case aimed to discuss a successful less invasive diagnostic and therapeutic management of a rare case of primary tracheal malignancy by bronchoscopic cryotherapy excision, ablation and recanalization.

Methods: A 50 year old male from Capiz, Philippines, with a 20 pack year smoking history consulted due to 3 months history of stridor and progressive dyspnea on exertion. He denied cough, hemoptysis, dysphagia, weight loss, and hoarseness of voice. Upon consult, CT scan of neck and chest was requested and showed proximal tracheal mass. Patient was referred to Lung Center of the Philippines for further evaluation and management. With multidisciplinary team, patient underwent rigid bronchoscopic, cryotherapy excision and ablation of the tracheal mass by general anesthesia, total intravenous anesthesia via jet ventilation.

Results: On rigid bronchoscopy, there was noted fungating tracheal mass obstructing 90-95% of tracheal lumen. Its base was located 1cm distal from the vocal cord, broad-based extending 2.5-3cm infiltrating the posterior column of tracheal mucosa at level of C1 to C3. Frozen section of the mass revealed non-small cell carcinoma. Immunohistochemistry staining of the mass showed focally positive to TTF1, positive to p40, and focally positive to Mucicarmine. Morphology and immunochemistry staining of the mass confirmed for Squamous Cell Carcinoma, keratinizing. Reassessment of upper airway was done by repeat bronchoscopy using fiber optic bronchoscopy one week after. Complete ablation of the remaining tracheal mass tissue was performed. Patient was discharged stable, non-oxygen requiring. Patient underwent sessions of radiotherapy. As of writing, 6 months after the procedure, patient is alive with no noted recurrence of the mass.

Conclusion: Primary tracheal squamous cell carcinoma, presented as a stridor and progressive dyspnea in a 50 year old male smoker successfully diagnosed and therapeutically managed using Cryotherapy

PO-532

A case report of the endobronchial airway foreign body removal in Djibouti

Seif,Moaad1、Huang,Haidong2、Cheng,Qianbo3、Jiang,Chunxia2、Ning,Yunye2、Bai,Chong2、Li,Qiang4、Kaloga,Mahamane1,5、Abdullah,Ahmed5、Said,Madian5

1. Department of Respiratory and Critical Care, Djiboutian Military Hospital, Djibouti City, Djibouti
2. Department of Respiratory & Critical Care Medicine, Changhai Hospital, the Second Military Medical University, Shanghai, China
3. Department of anesthesiology, Eastern Hepatobiliary Surgery Hospital, Hospital, The Second Military Medical University, Shanghai, China
4. The Diagnostic and Therapeutic Center of Respiratory Diseases, Shanghai East Hospital, Tongji University, Shanghai, China
5. Department of anesthesiology, Djiboutian Military Hospital, Djibouti City, Djibouti

Objective: Airway foreign body is one of the common airway emergencies. Although endobronchial foreign body removal has become a routine minimally invasive technique in many developing countries, it is still a clinically rare but urgent technique in Djibouti, the horn of east Africa due to the shortage of local medical resources, endoscopic equipment and accessories, and bronchoscopy training courses. We firstly reported a successful case of endobronchial airway foreign body removal in Djibouti using the available bronchoscopic equipments .

Methods: A 13-year-old African girl complaining with airway foreign body aspiration for 6 days, coughing with hemoptysis, was admitted to the emergency room of Djibouti Millitary Hospital. The Chest images showed a metallic needle approximately 4 cm in length located in the bronchial lumen of the left lower lobe(Fig.1a,1b). The available bronchoscopic equipments, only the diagnostic flexible bronchoscope and flexible bronchoscopic biopsy forcep, were used after planning. The metallic needle located in the lumen of basal segment of left lower lobe was bronchoscopic identified through endotracheal tube under general anesthesia.

Results: The needle was clamped and lifted up into the endotracheal tube by the biopsy forcep, and eventually removed successfully out of the airway together with the endotracheal tube. No bleeding occurred during the operation The patient recovered well after the procedure.

Conclusion: Airway foreign bodies are common with serious clinical hazards in Djibouti particularly in the adolescents. We reported the first successful case of endobronchial airway foreign body removal combining the available diagnostic bronchoscope with the biopsy forcep in Djibouti. We believe that it is urgent to set a standardized and elementary hands-on training course of interventional pulmonology for the chest doctors and pediatricians in Djibouti using the available bronchoscopic equipments, so that more and more patients with the central airway diseases such as airway foreign bodies in Eastern Africa will benefit from bronchoscopy, which are minimally invasive, efficient as well as inexpensive.

PO-533

Phosphorylation of the Cytoskeletal Protein CAP1 Regulates Non-Small Cell Lung Cancer Invasion, Migration and Proliferation

Zeng,Jie1、Xie,Shuanshuan1、Li,Xuan1、Shen,Changxing1、Zhou,Guolei2、Wang,Changhui1
1. Tongji University
2. Arkansas State University， State University

Objective: Cyclase-associated protein 1 (CAP1) is a kind of cytoskeletal protein which can regulates actin dynamics. Our previous study shows the expression of CAP1 differ in different metastatic degrees of lung cancer tissues, besides, CAP1 is a kind of protein which can be phosphorylated, there are two phosphorylated sites（S307 and S309）in human CAP1. However, the underlying mechanisms of CAP1 in human lung cancer metastasis still unknown. In the present study, we aimed to investigate the mechanism of lung cancer metastasis mediated by CAP1.

Methods: We transfected lenti-virus CAP1 knock down A549 cells (sh-A549) with specific phosphorylation state plasmids, CAP1 wide type (hereafter referred to as WT), S307A/S309A (mimicking a constitutively non-phosphorylated site, hereafter referred to as AA), S307D/S309D (mimicking a constitutively phosphorylated site, hereafter referred to as DD) respectively. The MTT and colony formation assays were performed to observed cells proliferation. Transwell and wound healing experiments were performed to investigate cells metastasis. Furthermore, to confirm these in vitro results, we injected above cells into nude mice by subcutaneous or by vein respectively.

Results: Our results showed that knockdown of CAP1 in human lung cancer cells can inhibit proliferation and migration of human lung cancer cells A549. In addition, phosphorylated S307 and S309 sites in CAP1 promoted lung cancer cells migration, metastasis both in vitro and in vivo, dephosphorylated these two sites in CAP1 showed opposite phenomenon. We found out that after knockdown CAP1 in human lung cancer cells leads to an increase ratio of F-actin/G-actin. Besides, phosphorylation of CAP1 can promote EMT transformation.

Conclusion: These findings indicated that phosphorylation sites of CAP1 might be a novel target for lung cancer metastasis treatment.

PO-534

Secondary Spontaneous Pneumothorax secondary to Tuberculosis with Klebsiella and Pseudomonas co-infection: A Case Report

Ogbac,Martin Kristoffer、Rozul,Pilar Madelyn
Perpetual Help Medical Center – Las Piñas

Objective : Background Secondary spontaneous pneumothorax (SSP) develops due to an underlying lung pathology. Tuberculosis is a common cause of SSP specially in endemic areas such as the Philippines. Certain bacterial infections that can cause pneumonia were also found to play a role in the development of SSP. Among these infections, the most common species were Staphylococcus,Klebsiella, Pseudomonas, and Pneumocystisspecies. In patients with cystic fibrosis, the risk of developing SSP increases with infection with Burkholderiacepaciaor Pseudomonasspecies. The presence of tuberculosis with simultaneous bacterial respiratory infection resulting to pneumothorax has been reported but very few data exist.

Methods: Fiberoptic flexible bronchoscopy was used in this procedure.

Results: Case Summary We report a case of a 37-year-old Filipino female, who initially noted of fever,

non-productive cough, and lower back pain. She has no known comorbidities with no history suggestive of any immunocompromised status. Recent exposure to a companion on continuation phase of anti-tuberculosis medication was the only significant medical history. Initial chest radiograph revealed left-sided pneumothorax. Chest tube thoracostomy (CTT) was inserted and antibiotics were started. Computed tomography revealed massive left pneumothorax and relaxation atelectasis of the left lung with air-bronchogram. Fiberoptic bronchoscopy was done and revealed moderate mucus with no other significant findings. Bronchial aspirate revealed growth of klebsiella pneumoniae.Video-assisted thoracoscopic surgery was done after bronchoscopy and revealed 300 cc of pleural fluid with multiple septations and loculations; trapped left lower lobe by thick fibrin; 0.5 x 0.5 cm well circumscribed pleural nodule; 4 x 2 cm diaphragmatic mass. Pleural fluid revealed positive acid fast bacilli. Pleural fluid culture was positive for pseudomonas aeruginosa. Diaphragmatic and pleural nodule histopathology reported chronic granulomatous inflammation with Langhan’s type giant cells consistent with tuberculosis. Other diagnostics and monitoring did not reveal hypertension, diabetes, nor other medical condition. Antibiotics were continued and anti-tuberculosis medications were started. CTT was subsequently removed and antibiotics were completed before patient was sent home.

Conclusion: Secondary spontaneous pneumothorax (SSP) due to tuberculosis is formed as result of a diaphragmatic rupture that developed from pleural invasion of the organism with subsequent liquefactive necrosis. This mechanism may also be true of pneumothorax due to other respiratory infections. SSP secondary to tuberculosis is usually diagnosed by identification of acid fast bacilli (AFB) either in the sputum smear or in the pleural fluid. At times, diagnosis is made by high suspicion specially in endemic areas with inaccessible diagnostic studies. Limited studies have been found on cases of SSP secondary to tuberculosis with concomitant respiratory bacterial infection mainly because pleural studies and bronchoscopy with bronchial washing are not routinely done in cases of pneumothorax. Management of SSP secondary to tuberculosis with simultaneous bacterial infection is administration of both anti-tuberculosis and antibiotics together with chest tube thoracostomy. Immediate insertion of chest tube and administration of antimicrobials is important for the survival as mortality of SSP secondary to tuberculosis was noted to be 33%. Recurrence rate of SSP was also noted to be 45%. This case report of SSP secondary to tuberculosis with simultaneous respiratory bacterial infection of pseudomonas and klebsiella infections recommends the inclusion of pleural fluid culture and AFB in the routine work-up of SSP. Other diagnostic procedures such as video-assisted thoracoscopy and bronchoscopy are also advised in SSP especially in cases with more than one etiology. Essential in the management of SSP is identification of the underlying cause and prompt initiation of proper treatment to improve the patient’s condition and avoid recurrence of pneumothorax.

PO-535

Early Radiologic and bronchoscopic Modifications after Bronchial Thermoplasty in Patients with Severe Asthma

Xie,Jiaxing、Qiu,Minzhi 、Zhang,Qingling 、Wei,Shushan 、Huang,Peikai 、Wang,Zhiqiang 、Zhong,Changhao 、Chen,Yu、Lin,Xiaofeng 、Zeng,Qingsi 、Li,Shiyue 、 Zhong,Nanshan

Objective: Bronchial thermoplasty (BT) reduces airway smooth muscle mass by using radio frequency thermal energy. This study aimed to descript a case of pneumothorax directly after BT and retrospectively analyzed early radiologic and bronchoscopic modifications after BT.

Methods: Clinical data, radiologic and bronchoscopic findings of 12 severe asthmatic patients subjected to BT during 2014–2017 were retrospectively analyzed.

Results: 33 chest radiographs were performed within 18-24h after BT. Radiological abnormalities were seen in 32 radiographs as atelectasis (53.1%), peribronchial consolidations (84.4%), pleural effusion (18.8%), effusion in oblique fissures (3.1%), pleural thickening (6.3%), and pneumothorax (3.1%). One patient suffered pneumothorax after the third BT session and underwent chest drain insertion, followed by mechanical ventilation in the ICU and multiple bronchoscopic interventions which revealed extensive phlegm plugs. Six patients with worsened symptoms and lobar

atelectasis also needed bronchoscopic interventions, which revealed that phlegm plugs occluded the bronchus in the treated lobe. No bronchoscopic intervention was needed in the remaining five patients. During the 16–30 days follow-up, 95.7% of the chest radiographs were resolved.

Conclusion: We report the first case of pneumothorax following BT. Early radiologic modifications-atelectasis, peribronchial consolidations -are common after BT. Whether bronchoscopic intervention is needed for atelectasis following BT requires further investigation.

PO-536

RETROSPECTIVE ANALYSIS OF FALSE POSITIVE RATIO OF OUR PATIENTS WITH LUNG CANCER AT PET-CT SCREEN

Mutlu,Pınar1、Kapıcıbası,H.Oguz2、Mirici,N.Arzu1、Alkan,s.Aycan1
1. Çanakkale 18 Mart Universty， Faculty of Medicine
2. Çanakkale 18 Mart Universty， Faculty of Medicine，Department of Thoracic Surgery

Objective: In lung cancer, staging is necessary to give the best treatment to the patient and to estimate the best prognosis. The aim of this study was to compare the pathology results of the lung masses, mediastinal lymph nodes, and to evaluate the sensitivity and specificity values of positron emission tomography- computerized tomography (PET-CT) and to determine the maximal threshold maximum standard uptake value (SUV max).

Methods: We retrospectively evaluated the PET-CT SUV max values and pathology results of the patients who had a mass, mediastinal lymph node or scalen lymph node in our patients between 2016-2018.

Results: 51 people and 75 pathology materials were included in our study. We used the ROC CURVE analysis to determine the cut off value for SUVmax value and calculated the cut off value as 6.65. In our study, the sensitivity and specificity were calculated as 63% and 71%, respectively. We calculated the positive predictive value as 73.5% and the negative predictive value as 61%.

Conclusion: As a result; considering the common inflammatory and granulomatous diseases seen in our country, we concluded that benign diseases should be considered before malignancy in SUVmax value below 6.6. We continue to add new patients and new data to our study in order to find the most appropriate threshold SUV max value for the health values of our country.

PO-537

Survival outcomes of patients with wedge resection and segmentectomy in stage IA NSCLC and its major subtypes

Li,Guoshu、Xie,Shuanshuan 、Wang,Changhui、李国术
同济大学附属第十人民医院

Objective: Limited resection, including wedge resection (WR) and segmentectomy (SG), is increasingly being adopted for the treatment of stage IA non-small cell lung cancer (NSCLC). However, there are few comprehensive studies which limited resection is a better choice for NSCLC and its major subtypes: squamous cell carcinoma (SQCC) and adenocarcinoma (AD). We performed this study to evaluate the survival outcomes of the two limited resections for stage IA NSCLC and the two subtypes.

Methods: Using the Surveillance, Epidemiology, and End Results registry, we identified 6,149 patients with stage IA NSCLC (2,673 men and 3,476 women) who had complete clinical information between 2004 and 2015,

including 1,529 SQCC and 4,070 AD patients. We used Kaplan–Meier analysis to determine the propensity score for patients with limited resection based on the preoperative characteristics of patients. Lung cancer-specific survival (LCSS) was compared between patients treated with WR and SG after adjusting, stratifying, or matching lung cancer patients according to propensity score. In addition, we compared the effects of chemotherapy and radiotherapy on LCSS between the WR and SG groups.

Results: Overall, 4,845 (78.8%) and 1304 (21.2%) surgically managed patients with stage IA NSCLC underwent WR and SG, respectively. Kaplan–Meier analysis demonstrated that there was a statistically significant difference (log rank=0.009) in survival curves for patients with stage IA NSCLC. Further analysis of its subtypes showed that there was a statistically significant difference (log rank<0.05) in survival curves in patients with stage IA SQCC, but the difference (log rank>0.05) lost in patients with stage IA AD between the WR and SG groups. Compared with the WR group, survival in the SG group was better (HR: 0.837, 95% CI: 0.729–0.962, p=0.012) in patients with stage IA NSCLC, using a Cox model. In addition, radiotherapy and chemotherapy had adverse effects on survival (p<0.001) in stage IA NSCLC patients received limited resection.

Conclusion: Our study suggests that SG yields superior survival compared with WR in patients with stage IA SQCC. Survival following segmentectomy or wedge resection was generally equivalent in stage IA AD. This finding should be confirmed in further studies. In addition, adjuvant therapies are associated with worse survival for patients with stage IA NSCLC and its subtypes who are managed with limited resection.

PO-538

Role of Surgery in Patients with Early Stage Small-Cell Lung Cancer

Li,Guoshu、Peng,Aimei、Xie,Shuanshuan、Wang,Changhui
同济大学附属第十人民医院

Objective: Currently, systemic chemotherapy combined with thoracic radiation is the standard treatment for patients with small-cell lung cancer (SCLC). However, the treatment of early stage SCLC remains controversial. This study evaluated the survival outcomes of surgical treatments and the effect of adjuvant chemotherapy and radiotherapy on lung cancer-specific survival (LCSS) in patients with early stage SCLC.

Methods: Using the Surveillance, Epidemiology, and End Results registry, we identified 2,453 patients with early stage SCLC (1,295 women and 1,158 men) who had complete clinical information between 2004 and 2015. The Kaplan-Meier analysis was used to determine the propensity score based on the characteristics of patients with early stage SCLC. LCSS was compared between patients treated with surgery and non-surgery after adjusting, stratifying, or matching patients with early stage SCLC. In addition, we compared the effects of chemotherapy and radiotherapy on LCSS in patients with early stage SCLC.

Results: Overall, 687 (28.0%) and 1,766 (72.0%) patients with early stage SCLC did and did not undergo surgery, respectively. Kaplan-Meier analysis demonstrated a statistically significant difference in survival curves between the surgery and non-surgery groups (log-rank p<0.001). Compared with the non-surgery group, the LCSS of the surgery group was better (hazard ratio [HR]:0.494, 95% confidence interval [CI]:0.415–0.587, p<0.001) in patients with early stage SCLC when using a Cox model for multivariate analysis. There was no statistically significant difference (p=0.847) in LCSS between patients with early stage SCLC with and without chemotherapy in the multivariate analysis. Radiotherapy had favorable effects on LCSS (HR: 0.579, 95% CI: 0.500–0.671, p<0.001) in patients with early stage SCLC using multivariate analysis.

Conclusion: Our study results suggest that LCSS conferred by surgery was higher than that conferred by non-surgery and that radiotherapy is associated with better survival in patients with early stage SCLC. This study findings should be confirmed in prospective studies.

PO-539

Direct Puncture Of Esophageal Cancer By Endobronchial Ultrasound-guided Transbronchial Needle Aspiration

Lin,Xiaoling、Tan,Tiantian、Bu,Shiyi、Xie,Zhangkui、Jiang,Shanping、Xiaoling Lin
Sun Yat-Sen Memorial Hospital, Sun Yat-Sen University

Objective: The application of Endobronchial ultrasound-guided transbronchial needle aspiration (EBUS-TBNA) in esophageal cancer is mainly to evaluate mediastinal lymph node metastasis and airway invasion [1]. There are few reports on direct puncture of esophageal tumors by EBUS-TBNA [2-3]. Here we present two cases which were diagnosed with EBUS-TBNA for esophageal mass puncture instead of conventional endoscopy.

Methods: Case report 1 Case 1 was a 56-year-old man, heavy smoker (35 packs/year), with an alcohol intake of 20g/day for 30 years, who presented with dysphagia for six months. Physical examination on admission was normal. Laboratory tests were unremarkable. Computed tomography (CT) detected thickening in the thoracic esophageal wall. Endoscopy revealed stenosis in the middle of the esophagus without local mucosal abnormalities and biopsy was not available. Under the bronchoscope, no abnormalities were observed within the airway. Ultrasound bronchoscopy detected a hypoechoic lesion of esophageal wall adjacent to the lower trachea. Needle biopsy in esophageal hypoechoic area by EBUS-TBNA was performed and specimens were obtained for pathological examination. No complications were observed during or after the procedure. Later pathological findings suggested poorly differentiated squamous cell carcinoma and immunohistochemistry staining showed CK5/6(+), P40(+), P63(+), Ki67 about 50% (+), CK7(-), TTF-1(-), NapsinA (-), CD (-), CD117(-), CD56(-), CgA (-), Syn (-), EBERS in situ hybridization (-).

Results: Case report 2 Case 2 was a 56-year-old man, smoking for 40 packs/year and intaking alcohol for 4g/day over 40 years, who presented with dysphagia for one month. There were no abnormalities in physical examination and laboratory tests. CT scan detected a mass in the cervical esophageal wall. Endoscopy revealed stenosis of the upper esophagus through which the endoscope could not pass. Pathologic study of the esophageal mucosa from endoscopic biopsy showed only mildly atypical hyperplasia and no sign of malignancy. There were no abnormalities in bronchoscope examination, either. Ultrasound bronchoscopy detected a hypoechoic lesion in esophageal wall adjacent to the upper trachea. Histological examination of biopsy samples through EBUS-TBNA in the hypoechoic area revealed squamous cell carcinoma and immunohistochemistry staining showed CK5/6(+), P40(+).

Conclusion: In conclusion, direct puncture of esophageal masses through EBUS-TBNA might be an alternative way of biopsy when conventional biopsy via gastrointestinal endoscopy or esophageal ultrasound convex probe is not available. In the process of ultrasound bronchoscopy, esophageal mass, manifesting as a hypoechoic region with irregular shape in the esophageal wall, can intermittently slide along with esophageal peristalsis, by which it is convenient to distinguish from the relatively fixed mediastinal lymph nodes.

PO-540

a Rare Complication of Pseudomembrane Formation Caused by Insertion of a Dumon Stent, a Case Report

Han,Xiaopeng、Liu,Jianbo、Shao,Runxia、Wang,Qingxiu、韩校鹏
the Second Affiliated Hospital of Zhengzhou University

Objective: Here we describe a unique case of pseudomembrane formation after silicone stent insertion. In this case, an hourglass-shaped stent was inserted in a patient who was diagnosed with post-intubation tracheal stenosis to help the patient with the disease.

Methods: A 48-year-old man was admitted to our hospital, presenting progressive dyspnea, stridor and coughing lasted for 3 months. He was a former smoker (about 30 pack-years). A medical history of intubation and mechanically ventilate 6 months ago due to drug intoxication was addressed. No relevant family history. On physical examination, the patient presented tachypnea and central cyanosis. The arterial blood gas analysis showed hypoxia (pH = 7.42, PaO2 = 57 mmHg, PaCO2= 31mmHg, $HCO3^{-}$=20mmol/l, room air). The complete blood count revealed leukocytosis of 10.75×109/L (normal range:4.0–10.0×109/L). The diagnosis of post-intubation tracheal stenosis was considered firstly, and chest computed tomography was performed soon while the oxygen therapy was administrated simultaneously. A marked circumferential stenosis of the trachea was found, without any signs of extrinsic mass. Fiberoptic bronchoscopy was performed immediately to assess the airway stenosis, showing a subglottic stenosis of the trachea (Figure 1). In order to reduce the dyspnea, an hourglass-shaped silicone stent (DumonTM Silicone stent) was inserted by the means of rigid bronchoscopy subsequently, after which the bronchoscopy showed a widely patent airway(Figure 2), dyspnea was mitigated obviously. Two days later, dyspnea relapsed, and fiberoptic bronchoscopy was performed twice, found a thick, valve-like membrane above the stent (Figure 3 and Figure 4). The membrane was removed with the help of grasping forceps under bronchoscopy. The patient’s dyspnea completely resolved after its removal. The histopathological examination of the membrane demonstrated fibrin, necrotic epithelium cells and exudate. No evidence of bacteria, fungi or mycobacterium was found from the membrane.

Results: The upper airway, which can be divided into malignant obstruction and benign obstruction, is a complicated clinical problem. The former is caused by primary or secondary lung cancer, while the latter is often caused by tracheal intubation, tracheostomy and other medical treatments. The therapy principle is to alleviate the symptom to prolong the lifetime and promote the life quality. As the first time of the silicone stent was applied to the management of airway stenosis in the 1990s1, some complications accompanied, e.g. cough worsen, stent obstruction with secretion, migration, granulation2.It is rare to find an pseudomembrane after silicone stent insertion, while most cases reported before were found after tracheal intubation. The tracheal pseudomembrane patient often complains of dyspnea, hoarseness, stridor, which may occur after extubation immediately or a few hours later, and in severe case may find respiratory failure sometimes. The diagnosis and therapy of tracheal pseudomembrane rely on fiberoptic or rigid bronchoscopy. The etiopathogenesis of tracheal pseudomembrane remains unclear, and multiple hypotheses have been proposed. Sehgal and his colleagues retrospectively analyzed a series of 54 cases, and found most pseudomembrane located in the subglottic region, the narrowest part, which makes mucosa hurts most during intubation. However, not all of the cases located under the glottis3. Deslee and his colleagues make a suggestion that ischemic damage related to cuffs might be a potential reason, while this theory cannot explain the cases in whom high-volume low pressure tubes were used4. In 2013, Alvarez-Maldonado and his colleagues reported a case of pseudomembrane formation following percutaneous dilatational tracheostomy (PDT)5. In our case, tracheal pseudomembrane occurred after silicone stent insertion. Both two cases demonstrated that various factors may relate to tracheal pseudomembrane, including mechanical stimulus and local aseptic inflammation, et al.

Conclusion: Tracheal pseudomembrane is an uncommon complication after silicone stent insertion. And it might be fatal if not diagnosed timely. Bronchoscopy is integral and indispensable in the management of tracheal pseudomembrane.

PO-541

Bronchoscopic Removal of Huge bronchus-like blood clot

Ren,Siying、Zhou,Rui
The Second Xiangya Hospital. Central-South University

Objective: A large blood clot in the airway can affect the patient's lung ventilation function and directly threaten the patient's life. The timely and effective removal of the blood clot is the only way to save the patient's life. In this case, the patient is highly considered to be a tumor patient, who is in a hypercoagulable state. Although hemorrhage succeeds in stopping bleeding after biopsy, a large blood clot blocks the airway and directly endangers life. And because of the fresh blood clot, it shows that it is smooth and sticky. It is difficult to complete clamping or suction cleaning in a short time. Chooses the intracavity freezing technology to completely remove the blood clot, it will undoubtedly gain valuable time for the patient's life and reduce the risk. Potential risk of secondary bleeding during blood clots. Such a complete giant bronchial tree blood clot is rare in clinical practice.

Methods: A 38-year-old woman presented with a 3-month history of cough。Computer tomography examination found a parahilar mass in right upper lobe with corresponding distal atelectasis. Multiple nodules in the subpleural space and interlobar membrane of right lung were seen as well， suggesting the nature of lung cancer. Fibrobronchoscopy was conducted under local anesthesia. There were infiltration narrowing of right main bronchus and right middle bronchus. Sporadic nodules were seen in the opening of right middle lower lobe and basilar branch with swelling in the opening of right upper lobe that caused obstruction. Consequently mucosa biopsy was conducted at right upper lobe. She had huge hemorrhage during the procedure. A blood clot was seen stretching over the both main bronchus, which had to suction. She experienced awareness loss gradually. Her heart rate decreased to 14 and her SpO2 14%. Her blood pressure could not be measured.

Results: Intraluminal freezing techniques were used immediately to pull out the blood clot. After the pull-out, she regained her awareness and her vital sign returned stable.

Conclusion: Chooses the intracavity freezing technology to completely remove the blood clot, it will undoubtedly gain valuable time for the patient's life and reduce the risk.

PO-542

Aetiologic Diagnosis and Efficacy of Interventional Treatment in 20 Intraluminal Tracheal Spheroid Masses.

Wang,Jiwang
The first affliated hospital of Nanjing medical university

Objective: To explore the aetiologic diagnosis and clinical characteristics of and effects of interventional therapy on intraluminal tracheal spheroid masses.

Methods: The data from 20 patients with intraluminal tracheal spheroid masses were retrospectively analysed.

Results: Among the 20 patients, cough and shortness of breath were the predominant symptoms, followed by haemoptysis and fever. Aetiologic diagnoses included inflammatory granulomas (8 patients), leiomyomas (2 patients), glomus tumour, malignant melanoma metastasis, salivary gland tumour, neurilemmoma, mixed tumour, adenoid cystic carcinoma, acidophilic adenoma, foreign matter, spindle cell tumour and highly differentiated chondrosarcoma (1 patient each). The numbers of masses located in the upper, middle and lower parts of the trachea were 8, 6, and 6, respectively. High-frequency electrocautery was the most commonly used interventional therapy, followed by argon plasma coagulation and cryotherapy; stent implantation was used in 1 patient. Eight patients achieved complete response or partial response after treatment, 3 patients achieved a mild response and only 1 patient achieved no response

Conclusion: The symptoms of intraluminal tracheal spheroid masses are atypical and easily misdiagnosed or missed. Lesions are mainly located in the upper and middle portions of the trachea, benign lesions are the leading cause, and the main pathological type is inflammatory granuloma. Endoscopic intervention is an effective, safe technique.

PO-543

Clinical characteristics and efficacy of flexible endoscopic intervention for endobronchial hamartoma

Wang,Jiwang
The first affliated hospital of Nanjing medical university

Objective: This study aimed to evaluate the clinical characteristics, efficacy and safety of flexible endoscopic intervention for endobronchial hamartoma.

Methods: We retrospectively analyzed 13 patients with endobronchial hamartoma who underwent flexible endoscopic intervention at a single center. The clinical characteristics and outcomes after flexible endoscopic intervention were described.

Results: 9 patients were cured after a single flexible endoscopic intervention. Due to late tumour recurrence, 3 patients underwent the second flexible endoscopic interventions and were then cured, while 1 paitient who eventually became stable with a 40% stenosis of the airway lumen, received the third intervention because of two times of relapse. Pneumothorax occurred in 1 patient who were cured after oxygen therapy. There were no serious complications such as massive hemorrhage, airway perforation, airway ignition and suffocation, associated with the therapy.

Conclusion: Flexible endoscopic intervention appear to be safe and effective for the treatment of patients with endobronchial hamartoma.

PO-544

Diagnostic value of fluorescence quantitative TB-PCR for mediastinal lymphadenopathy in EBUS-TBNA specimens

Zhang,Haitao、Zhang,Haitao、Jin,Faguang、Gu,Xing
空军军医大学唐都医院

Objective: To evaluate the clinical value of fluorescence quantitative TB-PCR in EBUS-TBNA specimens for mediastinal lymphadenopathy

Methods: The clinical data of patients who received EBUS-TBNA in the respiratory endoscopy center of our hospital from January 2017 to May 2018 were retrospectively analyzed. The sensitivity, specificity and diagnostic accuracy of the pathological examination of biopsy specimens for lymph node tuberculosis with or without fluorescence quantitative TB-PCR were statistically analyzed.

Results: After relaxation of the standard, the sensitivity, specificity, and accuracy of EBUS-TBNA specimens for mediastinal lymphatic tuberculosis were 75%, 83.3%, and 78.9%, respectively. The sensitivity, specificity and accuracy of EBUS-TBNA specimens by fluorescence quantitative TB-PCR combined with pathological examination for the diagnosis of mediastinal lymphatic tuberculosis were 90.5%, 100%, and 94.4%, respectively.

Conclusion: The pathologic diagnosis of EBUS-TBNA specimens combined with fluorescence quantitative TB-PCR was significantly improved in sensitivity, specificity and accuracy to the diagnosis of lymph node tuberculosis, which was helpful in the differentiation of sarcoidosis and mediastinal tuberculosis and non-tuberculous mycosis, and worthy of clinical application.

PO-545

Hourglass-type silicone stent placement for the treatment of idiopathic subglottic stenosis: a report of 2 cases

Wang,Guoan、Wu,Hongcheng、Zhou,Yingyan、Ge,Ting、Wu,Shibo、Guoan Wang
Department of Pulmonary and Critical Care Medicine， Ningbo Medical Center Li Huili Hospital

Objective: To investigate the efficacy and safety of hourglass-type silicone stent placement in the treatment of idiopathic subglottic stenosis.

Methods: Retrospective analysis of clinical features, imaging findings and diagnosis and treatment of 2 patients with idiopathic subglottic stenosis

Results: We treated 2 cases of idiopathic subglottic stenosis at 2016.3~2018.5. Two were females patients. Example 1, the patient who was 55 years old, was hospitalized for shortness of breath for 1 and a half years .Pulmonary function showed severe obstructive ventilatory dysfunction and F-V curve showed inspiratory platform-like changes. Cervical chest CT shows localized stenosis of tracheal thyroid level,.Bronchoscopy suggests a narrow subglottic stenosis. At 2016-3-7, under the rigid bronchoscope, hourglass-type silicone stent (15-13-15*15-20-15mm)was placed after balloon dilation and internal and external suture fixation. No hemoptysis or pneumothorax complications occurred after operation and remove the fixed suture after 1 week. Repeated examination of the bronchoscopy showed that the position of the silicone stent was satisfactory and without displacement,the tracheal lumen was significantly enlarged, and a small amount of granulation grew at both ends of the stent. Patient with shortness of breath relief. On 2016-11-9, the hourglass silicone stent was removed under the rigid bronchoscope. Example 2，the other patient was 32 years old, was hospitalized for chest tightness and shortness of breath for 6 weeks. Cervical and thoracic CT showed substomial space occupying lesions. Pulmonary function shows moderate obstructive ventilatory dysfunction and F-V

curve has a plateau-like change in inspiratory phase. Bronchoscopy revealed subglottic stenosis, rough surface mucosa, local new organisms, hard mass, and a narrow segment of about 15 mm. Neoplasm of trachea shows mucosal chronic inflammation with massive inflammatory granulation tissue and fibrous tissue hyperplasia. At 2018-5-17, the balloon was dilated under a rigid bronchoscope and an hourglass-type silicone stent (14-12-14*15-20-15mm) was placed. No hemoptysis or pneumothorax complications occurred after operation. Repeated examination of the bronchoscopy showed that the position of the silicone stent was satisfactory and without displacement, the tracheal lumen was significantly enlarged, and a small amount of granulation grew at both ends of the stent. Patient with shortness of breath relief.

Conclusion: Hourglass-type silicone stent placement for the treatment of idiopathic subglottic stenosis is reliable and safe, and can be used as a beneficial option for interventional treatment of idiopathic subglottic stenosis.

PO-546

The Diagnostic Yield of Endobronchial Ultrasound-Guided Mediastinal Lymph Node Transbronchial Forceps Biopsies

Diab,Khalil1,2、Zhang,Chen2、Assi,Rita1、Hanna,Nasser2、Bikak,Marvi2
1. LAU Gilbert and Rose-Marie Chagoury School of Medicine
2. Indiana University School of Medicine

Objective: Diagnostic accuracy and yield of endobronchial ultrasound-guided transbronchial needle aspiration (EBUS-TBNA) is not well established in lymphoma and other mediastinal-related diseases, mainly due to challenges in obtaining satisfactory samples for histopathological review. We investigate the yield of a combined technique of EBUS-TBNA and EBUS-guided transbronchial miniforceps biopsies (EBUS-TBFB) compared to each modality alone in lymphoma and other mediastinal-related diseases.

Methods: This is a retrospective review of a prospectively collected database on cases of mediastinal lymphadenopathy of unknown etiology. After lymph nodes were identified via EBUS, a 19-gauge TBNA needle was inserted into the lymph node, the catheter sheath extended over the needle to dilate, the needle withdrawn and a miniforceps was introduced through this channel into the lymph node to obtain samples.

Results: The combined approach yielded a definitive diagnosis in 33/35 cases (94%). In 9/10 cases (90%), Hodgkin’s and Non-Hodgkin’s lymphomas were diagnosed and subtyped without further need for invasive testing. All granulomatous inflammation cases were confirmed using the combined technique. Two cases led to adequate whole genome sequencing of lung cancer, and one patient was diagnosed with de-differentiated liposarcoma despite a non-diagnostic pre-procedural mediastinoscopy. There was only one procedure-related complication, a pneumomediastinum that required no further intervention.

Conclusion: The combination of EBUS-TBFB and EBUS-TBNA provide a high yield in the diagnosis of mediastinal adenopathy of unknown etiology, especially lymphoma.

PO-547

Endobronchial ultrasound-guided transbronchial lung biopsy is useful in diagnosis of COP：a case report

Ge,Xiahui1、Guan,Wenbin2、Guo,Xuejun2、戈霞晖
1. Shanghai Seventh People’s Hospital Affiliated to Shanghai University of Traditional Chinese Medicine
2. Xinhua Hospital， Shanghai Jiaotong University School of Medicine

Objective： A 48-year-old female was admitted to our department presented with persistent cough and breathlessness for 40 days. Clubbing of finger was obvious and bibasilar inspiratory crackles could be heard. Chest computed tomography (CT) revealed bilateral ground glass opacities (GGO) and patchy consolidation and bronchial vascular bundle thickening in both lung fields. Lung function demonstrated moderate restrictive dysfunction and severe diffusion dysfunction. To obtain sufficient lung biopsy, endobronchial ultrasound-guided transbronchial lung biopsy（EBUS-TBLB）was used.

Methods EBUS-TBLB and K203 biopsy forceps were utilized under local anesthetic with conscious sedation，and ten pieces of lung tissue was safely sampled under ultrasound guidance.

Results： Finally, Cryptogenic organizing pneumonia was diagnosed based on the presence of buds of granulation tissue (Masson bodies) within alveoli and preservation of the alveolar architecture, in combination with typical clinical presentation and CT findings.

Conclusion： Therefore, EBUS-TBLB is a promising technique in ILD patient with GGO or consolidation appearance on chest CT and ultrasound image in conjunction with guide sheath ensure the TBB procedure more accurately and safely in diffuse parenchymal lung disease.

PO-548

The lengths of trachea and main bronchus in Chinese Shanghai population

Ge,Xiahui1、Yu,Lingwei2、Guo,Xuejun2、Bai,Chong3、戈霞晖
1. Shanghai Seventh People’s Hospital Affiliated to Shanghai University of Traditional Chinese Medicine
2. Xinhua Hospital Affiliated to Shanghai Jiao Tong University School of Medicine
3. Changhai Hospital of Second Military Medical University

Objective： The objective is to measure the length of trachea and left and right main bronchus in chinese Shanghai population.

Methods： A total of 153 consecutive adult patients with minor pulmonary disease in Xinhua hospital were enrolled for bronchoscopy examination. Measurements were conducted on head and neck neutral position and height, weight and age for each patient were recorded either.Student t test and multiple linear regression was used to compare means between males and females and to analyze correlation among height,weight, sexual dimorphism and the lengths of the trachea and bronchus.

Results： The lengths of the trachea and left main bronchus are significantly different between male and female patients ($p < 0.01$), but not for the lengths of right main bronchus between man and woman. Multiple linear regression analysis showed that height but not sexual dimorphism and weight correlated with the lengths of the trachea and right main bronchus.

Conclusion： The lengths of the trachea and left main bronchus are significantly longer in males than in females. Moreover, height but not sexual dimorphism and weight influenced the length of airway.

PO-549

One case of refractory massive hemoptysis

Qing,Gang1,2、HUANG,Wanxiu1、GUO,Shuliang2、青刚
1. Department of Respiratory Medicine，People’s Hospital Of Guang’an City，Guang’an，Sichuan
2. Department of respiratory and critical diseases， the first affiliated hospital of chongqing medical university，Chongqing

Objective： To further study the relevant treatment measures of massive hemoptysis through the diagnosis and treatment of a patient with intractable massive hemoptysis caused by tuberculosis.

Methods： The diagnosis and treatment of refractory massive hemoptysis were reviewed.

Results： After hemostasis with drugs, bronchial arterial embolization（BAE）and airway balloon compression, the patient still suffered from repeated hemoptysis.Finally, pulmonary lobectomy was performed in the emergency department of thoracic surgery, and postoperative hemoptysis was stopped.

Conclusion： Patients with refractory massive hemoptysis with poor lung function are difficult to treat and have a high risk of death. Therefore, a variety of methods should be used for comprehensive treatment. COPD should be standardized treatment, tuberculosis should be early diagnosis, early treatment;Avoid serious complications.

PO-550

Congenital Lung Malformation Complicated with Aspergillus Colonization

Xu,Chuancai、Ni,Chongjun、Huang,Jian'an
The First Affiliated Hospital of Soochow University

Objective： We report a case of congenital lung malformation(CLM) found by bronchoscopy and aspergillus colonization found by surgery.

Methods： The 59-year-old female patient was admitted to the hospital due to computed tomography (CT) findings of right lung lesion for more than two months. CT showed a cavity of about 4.3cm in diameter with a low-density nodule in the right upper lobe (Figure.1A). The patient had no complaint of discomfort, no history of smoking and underlying diseases.

Results： Bronchoscopy revealed a slit-like narrow opening above the right main bronchus (Figure.1B). The patient underwent thoracoscopic lobectomy for the malformed right upper lung. Histopathological examination revealed the presence of aspergillus (Figure.1C). After the procedure, the patient recovered well and is currently followed up.

Conclusion ： CLMs comprise a broad spectrum of rare anomalies, some of which result from a focal developmental abnormality, such as congenital pulmonary airway malformation, bronchopulmonary sequestration, congenital lobar emphysema, and intrapulmonary bronchogenic cyst. With concerns of recurrent infection and a possibility of malignancy, anatomical resection is recommended for CLM regardless of symptoms. The clinical manifestations of CLM vary greatly. The outcome ranged from spontaneous remission to death. The patient had no obvious symptoms, but imaging showed a fluid dark area. The pathology of the specimens removed by surgery showed aspergillus, which may be related to the patient’s abnormal airway and poor drainage.

PO-551

Values of different specimen preparation methods for the diagnosis of lung cancer by endobronchial ultrasound guided transbronchial needle aspiration

Xu,Youzu、Lin,Jian、Chen,MeiFang、徐有祖
Tai Zhou Hospital of Zhejiang Province, LinHai, Zhejiang, P. R. China

Objective: Endobronchial ultrasound guided transbronchial needle aspiration (EBUS-TBNA) has been become an important procedure for the diagnosis and staging of lung cancer. Our research identified the effects of different pathological preparation on the diagnosis of lung cancer for specimens obtained by biopsy.

Methods: Patients were clinically considered if lung cancer was accompanied by mediastinal or hilar lymph node enlargement between March 2014 and November 2017. Specimens obtained by EBUS-TBNA were treated by three methods: traditional smear cytology, liquid-based cytology (LBC) and histopathology. The diagnostic values were analyzed.

Results: Of a total of 154 puncture sites from 153 patients, the total positive rate of combination for the three pathological treatment types (histopathology, direct traditional smear, and LBC) was 77.3%. The diagnostic positive rate for histopathology was 68.6%, direct traditional smear was 65.6%, and LBC was 60.4%; there was no significant differences among the three single pathological treatment types (P=0.29), but there was a statistically significant difference between the combination of three treatments and any single pathological treatment type (P=0.01). The diagnostic sensitivities of histopathology combined with traditional smear and histopathology combined LBC were 94.4% and 92.8%, respectively, the specificities and PPVs were both 100%, and the diagnostic accuracies were 95.5% and 94.2%, respectively; the sensitivities, specificities and diagnostic accuracies above were all higher than those of single specimen treatment and lower than those of the three combined.

Conclusion: When EBUS-TBNA is used for the diagnosis and staging of lung cancer, the use of histopathological sections combined with direct cytological smear should be sufficient and is the most economical choice.

PO-552

Expert consensus for diagnosis and treatment of medical thoracoscopy in China

Jin,Faguang1、Wang ,Hongwu2、Li ,Qiang3、Li ,Shiyue4、Lai ,Guoxiang5、Huang ,Jianan6、Huang ,Yijiang7、Jiang ,Tao1、Bai ,Chong8、Li ,Shengqing9、Li,Wangping1

1. 空军军医大学唐都医院
2. 北京煤炭总医院
3. 同济大学附属东方医院
4. 广州医科大学附属第一医院
5. 福州军区总院
6. 苏州大学第一附属医院
7. 海南省人民医院
8. 海军军医大学长海医院
9. 复旦大学附属华山医院

Objective: Medicine thoracoscopy is a commonly used endoscopic technique in the diagnosis and treatment of respiratory diseases. As an invasive technique, it is mainly used in pleural effusions and pleural diseases that cannot be diagnosed by non-invasive methods. It is also of great application value in the diagnosis and treatment of certain diseases. Medical thoracoscopy can be performed under local anesthesia (or add intravenous sedative anesthesia), generally does not require general anesthesia, and can be performed in the endoscope room. The front end bendable medical electronic thoracoscopic allows for biopsy and treatment under direct vision. Therefore, compared with video-assisted thoracoscopic surgery (VATS), i.e., surgical thoracoscopic surgery, the trauma is smaller, the medical cost is lower, and the diagnosis and treatment are more efficient and less complications, and it has been widely used in clinical practice.

Methods: Any technical operation requires special skills. There must be a learning process in mastering these skills. Although the internal thoracoscopic surgery is simple, especially for respiratory specialists who have undergone thoracentesis or closed drainage. However, the current level of thoracoscopic diagnosis and treatment in domestic hospitals is uneven, and the operation methods are not uniform, and some even lead to serious complications.

Results: Therefore, the domestic thoracoscopic diagnosis and treatment technology needs to be standardized.

Conclusion: The Respiratory Professional Committee of the Integrated Medical Branch of the Chinese Medical Doctor Association organized relevant domestic experts to formulate this standard after several rounds of discussion.

"..... the H-SteriScope appears to have similar maneuverability as the reusable bronchoscope. Both the H-SteriScope and the reusable bronchoscopes performed better in all measured sectors than the current single-use bronchoscope."

" ..... Vathin H-SteriScope一次性电子支气管镜的可操作性与可重复使用的支气管镜相差无几。 Vathin H-SteriScope一次性电子支气管镜和可重复使用的支气管镜在性能测试方面的表现均优于市面上所有的一次性支气管镜。"

— George Z. Cheng, MD - UC San Diego Health

(Respiratory Care November 2020, 65 (11) 1655-1662; DOI: https://doi.org/10.4187/respcare.07574
发表于 Respiratory Care 学术杂志 2020年11月号。)

Vathin® H-SteriScope™ I Single-use bronchoscope

VATHiN Value Your Health

湖南华芯一次性支气管镜

降低风险 COST EFFECTIVE

简易操作 NO MAINTENANCE

拒绝感染 NO CROSS-CONTAMINIATION

提高效率

湖南省华芯医疗器械有限公司
HUNAN VATHIN MEDICAL INSTRUMENT CO.,LTD
湖南省湘潭九华经开区传奇西路9号创新创业服务中心12栋1楼
1/F, Building 12, Innvation and Entrepreneurship Service Center, No.9 Chuanqi west road, Jiuhua Economic Develpment Zone, Xiangtan, Hunan
TEL: +86- 21 3478 1226 FAX: +86- 21 3478 1226
Email: Marketing@vathin.com
www.vathin.com

VATHiN Value Your Health


WORLD ASSOCIATION FOR BRONCHOLOGY & INTERVENTIONAL PULMONOLOGY
中华医学会
CHINESE MEDICAL ASSOCIATION
1915
中华医学会呼吸病学分会
CTS
Chinese Thoracic Society